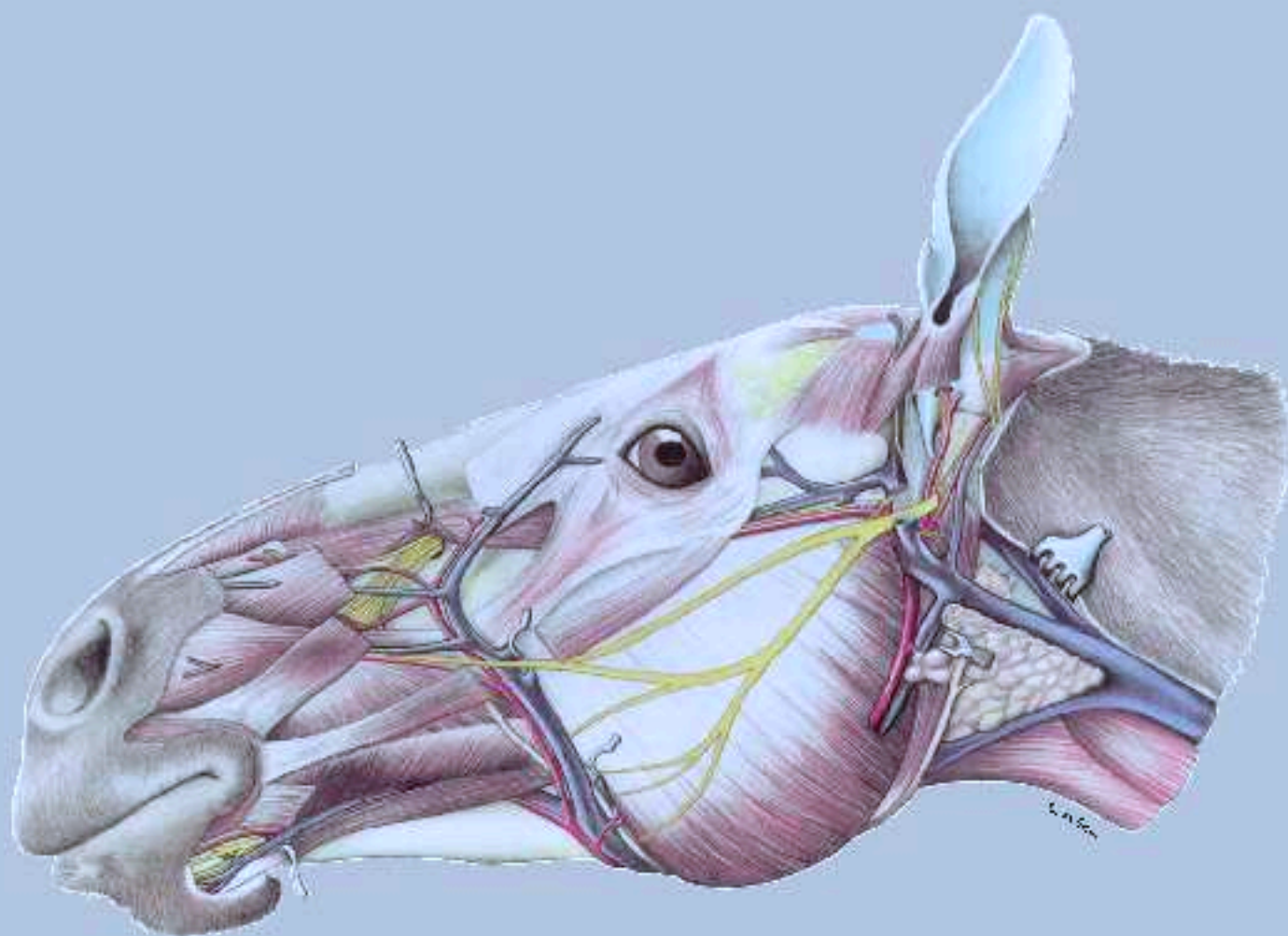


Klaus-Dieter Budras · W.O. Sack · Sabine Röck

Anatomy of the Horse

vet



with Aaron Horowitz and Rolf Berg

Fifth, revised edition

schlütersche

vet
S

Klaus-Dieter Budras · W.O. Sack · Sabine Röck

Anatomy of the Horse

Anatomy of the Horse

Fifth, revised Edition

Professor em. Klaus-Dieter Budras

Institute of Veterinary Anatomy
Free University of Berlin

Professor em. W. O. Sack †

Department of Biomedical Sciences
College of Veterinary Medicine
Cornell University, Ithaca, New York

Dr Sabine Röck

Institute of Veterinary Anatomy
Free University of Berlin

Professor Aaron Horowitz

Professor Rolf Berg

Dept. of Structure and Function
School of Veterinary Medicine
Ross University, St. Kitts, West Indies

Science Illustrator

Gisela Jahrmärker, Diemut Starke, Renate Richter

Contributors

Anita Wünsche, Christine Aurich, Jörg Aurich, Silke Buda,
Peter S. Glatzel, Hartmut Gerhards, Arthur Grabner,
Ekkehard Henschel †, Bianca Patan, Astrid Rijkenhuizen,
Harald Sieme, Bettina Wollanke

schlütersche

Co-workers on the Atlas of the Anatomy of the Horse

Fifth Edition

Cover drawing
Renate Richter

German Editions Budras/Röck 1991; 1994; 1997; 2000; 2004; 2008

English Editions Budras/Sack/Röck 1994; 2001; 2003; 2008

Japanese Editions Budras/Röck/Hashimoto 1997; 2001; 2004

Spanish Edition 2005

Dutch Edition 2005

Contributions

A. Univ.-Prof. Dr. Christine Aurich, Besamungsstation, Veterinärmedizinische Universität Wien

O. Univ.-Prof. Dr. Jörg Aurich, Klinik für Geburtshilfe, Gynäkologie und Andrologie, Klinisches Department für Tierzucht und Reproduktion, Veterinärmedizinische Universität Wien

PD Dr. Hermann Bragulla, Dept. of Biological Sciences, Louisiana State University, Baton Rouge

Dr. Silke Buda, ehem. Institut für Veterinär-Anatomie, Freie Universität Berlin

Prof. Dr. Hartmut Gerhards, Klinik für Pferde, Ludwig-Maximilians-Universität München

Prof. Dr. Peter S. Glatzel, ehem. Tierklinik für Fortpflanzung, Freie Universität Berlin

Prof. Dr. Arthur Grabner, Klinik für Pferde, Freie Universität Berlin

Prof. Dr. Ekkehard Henschel †, Institut für Veterinär-Anatomie, Freie Universität Berlin

Dr. Ruth Hirschberg, Institut für Veterinär-Anatomie, Freie Universität Berlin

Prof. Dr. Dr. h.c. Horst E. König, Institut für Veterinär-Anatomie, Veterinärmedizinische Universität Wien

Prof. Dr. Dr. h.c. Hans-Georg Liebich, Institut für Tieranatomie, Ludwig-Maximilians-Universität München

Prof. Dr. Christoph K. W. Mülling, Dept. of Comparative Biology and Experimental Medicine, Faculty of Veterinary Medicine, University of Calgary, Canada

Dr. Claudia Nöller, Klinik für Kleintiere, Universität Leipzig

Dr. Bianca Patan, Klinik für Orthopädie bei Huf- und Klauentieren, Veterinärmedizinische Universität Wien

Ass. Prof. Astrid B. M. Rijkenhuizen, Department of Equine Sciences. Surgery Faculteit Diergeneeskunde Universiteit Utrecht

Prof. Dr. Harald Sieme, Reproduktionsmedizinische Einheit der Kliniken, Stiftung Tierärztliche Hochschule Hannover

Prof. Dr. Paul Simoens, Faculteit Diergeneeskunde, Universiteit Gent

PD Dr. Bettina Wollanke, Klinik für Pferde, Ludwig-Maximilians-Universität München

© 2009 Schlütersche Verlagsgesellschaft mbH & Co. KG., Hans-Böckler-Alle 7, 30173 Hannover

Printed in Germany

ISBN 978-3-89993-044-3

A CIP catalogue record for this book is available from Deutsche Nationalbibliothek, Frankfurt — Germany.

All rights reserved. The contents of this book both photographic and textual, may not be reproduced in any form, by print, photoprint, phototransparency, microfilm, video, video disc, microfiche, or any other means, nor may it be included in any computer retrieval system, without written permission from the publisher.

Any person who does any unauthorised act in relation to this publication may be liable to criminal prosecution and vicil claims for damages.

Contents

Preface	1
Chapter 1: Skin	
1. The external Skin (common integument)	2
Chapter 2: Thoracic Limb	
1. The Skeleton of the Thoracic Limb	4
2. Topography of the Thoracic Limb (Nerves and Muscles)	6
3. Cutaneous Innervation, Blood Vessels, and Lymphatic Structures of the Thoracic Limb	8
4. Vessels, Nerves, and Deep Fascia of Carpus, Metacarpus, and Digit	10
5. The passive Stay-apparatus of the Thoracic Limb	12
6. Synovial Structures of the Thoracic Limb	14
Chapter 3: Pelvic Limb	
1. The Skeleton of the Pelvic Limb	16
2. Topography of the Pelvic Limb (Nerves and Muscles)	18
3. Skin Innervation, Blood, Vessels, and Lymphatics of the Pelvic Limb	20
4. Vessels, Nerves, and deep Fascia of Tarsus, Metatarsus, and Digit	22
5. Passive Stay-Apparatus of the Hindlimb, also Hoof and Contents	24
6. The Hoof (Ungula)	26
7. Suspensory Apparatus of the Coffin Bone (Distal Phalanx), Vessels and Nerves of the Hoof	28
8. Synovial Structures of the Pelvic Limb	30
Chapter 4: Head	
1. Skull and Dentition	32
2. Skull with Teeth and Paranasal Sinuses	34
3. Supf. Veins of the Head, Facial nerve (VII) and Muscles supplied by the Facial Nerve	36
4. Trigeminal Nerve (V-3 and V-2), Muscles of Mastication, Salivary Glands, and Lymphatic Structures	38
5. Adnexa of the Eye	40
6. The Eye	42
7. Nose and Nasal Cavity, Mouth and Tongue	44
8. Pharynx, Guttural Pouch and Larynx	46
9. Larynx and Laryngeal Muscles	48
10. Head-Neck Junction and Ear	50
Chapter 5: The Central Nervous System	
1. The Brain	52
2. The Spinal Cord	54
Chapter 6: Axial Skeleton and Neck	
1. Vertebral Column with Thorax and Nuchal Ligament	56
2. Neck and Thoracic Wall	58
3. Deep Shoulder-Girdle Muscles, the Muscles of the ventral Part of the Neck and the visceral Space they enclose	58
Chapter 7: Thoracic Cavity	
1. Thoracic Wall, Respiratory Muscles, Lungs, and Lymphatic Structures	60
2. Heart and Thymus	62
Chapter 8: Abdominal Wall and Cavity	
1. The Abdominal Wall	64
2. Topography of the Abdominal Organs and Their Relation to the Abdominal Wall	66
3. Spleen, Liver and Bile Duct, Pancreas, and Stomach with Omenta	68
4. Intestines	70
Chapter 9: Pelvis, Inguinal Region, and Urogenital Organs	
1. Bony Pelvis with Sacrosciatic Ligament, Supf. Inguinal Structures	72
2. Inguinal Area	74
3. Prepubic Tendon, Inguinal Canal of the Mare, Nerves of the Lumbar Plexus, Hypaxial Lumbar Muscles, and Udder	76
4. Lymphatics, Adrenal Glands, and Urinary Organs	78
5. Arteries, Veins, and Nerves of the Pelvic Cavity	80
6. Female Reproductive Organs	82
7. Male Reproductive Organs	84
8. Perineum, Pelvic Diaphragm, and Tail	86
Chapter 10: Selected Body Systems in Tabular Form	
1. Muscles	88
2. Lymphatic Structures	101
3. Peripheral Nervous System	104
4. Cranial Nerves	108
Contributions to Clinical-Functional Anatomy	112
List of References	185
Index	195

How to use this book

The framed introductions at the beginning of the text-pages dealing with topographical anatomy give information with respect to the dissection of the areas shown in the figures. At the same time, they can be used as abbreviated dissection instructions.

Bold

Boldface terms of anatomical structures serve for emphasis and, insofar as they are identified by numbers, they are represented on the neighboring illustration-page where they are identified by the same number.

Italics

The comparative anatomical aspects respecting the species-specific features of the horse are accentuated by using *italics*. However, if horse-specific details are continuously discussed in the text (for example, the stay apparatus of the horse), then the descriptions are written in normal lettering. The weighting of each of the anatomical details according to their significance is shown by the use of different character styles, figure captions and cross references to the section “Contributions to Clinical-Functional Anatomy”. Bold face type is used in the text for emphasis and the associated numbers refer to the figures. Less important details are not presented in the text, only in the figure legends. If a minus sign is present in the figure legends of the skeletal system (see Figs. 5, 17, 33, 35 and 74), this means that the structure is not found in the horse, but may be present in other domestic mammals.

Abbreviations

The anatomical/medical terms and expressions occurring in the text are explained and interpreted in “Anatomical Terms”. Abbreviations of anatomical terms follow the abbreviations as employed in the Nomina Anatomica Veterinaria (2005). Other abbreviations are explained in the appertaining text, and in the titles and legends for the illustrations. A few abbreviations that are not generally employed are listed here:

The **cranial nerves** (*Nervi craniales*) are designated with roman numerals I–XII.

Spinal nerves (*Nervi spinales*):

- n – Nervus spinalis
- nd – Ramus dorsalis n. spinalis
- ndl – Ramus dorsolateralis
- ndm – Ramus dorsomedialis
- nv – Ramus ventralis
- nvl – Ramus ventrolateralis
- nvm – Ramus ventromedialis
- nC – Nervus cervicalis (e. g., nC1 – first cervical nerve)
- nCy – Nervus coccygeus s. caudalis
- nL – Nervus lumbalis
- nS – Nervus sacralis
- nT – Nervus thoracicus

Vertebrae:

- vC – Vertebra cervicalis (e. g., vC₃ – third cervical vertebra)
- vL – Vertebra lumbalis
- vS – Vertebra sacralis
- vT – Vertebra thoracica

Numbers on the margin

Numbers on the margin of the text-pages refer to the “Clinical and Functional Anatomy”. The numbers in the clinical anatomy part refer to the corresponding page in the topographical anatomy; e. b., “8.2” refers to the part numbered „2“ on page 8.

Chapter 10: Selected Body Systems in Tabular Form

1. Muscles

MUSCLE	ORIGIN	INSERTION	INNERVATION	FUNCTION
MEDIAL SHOULDER AND ARM MUSCLES (p. 7)				
Teres major (7.1)	Caudal border of scapula and subscapularis	Distal tuberosity of humerus	Axillary n.	Flexes the shoulder joint
Subscapularis (7.2)	Subscapular forus of scapula	Lesser tuberosity of humerus	Subscapular and axillary nn.	Protracts and rotates humerus
Coracobrachialis (7.16)	Lateral process of acromion	Proximal end of ulna	Musculocutaneous n.	Extends of elbow joint, adducts of humerus
Biceps brachii (7.21)	Proximal to medial part of glenoid cavity	Distal of humerus	Axillary n.	Tracts shoulder capsule
Brachioradialis (7.22)	Supraglenoid tubercle	Radial tuberosity; distal ulnar styloid; via brachial lbr. on radius of anterior aspect	Musculocutaneous n.	Extends of shoulder joint; flexes of elbow joint; via brachial lbr. adducts of ulna; opposes of ulna
Brachialis (7.23)	Proximal end of humerus	Proximal end of radius	Musculocutaneous n.; lateral parts of muscle by radial n. in half the horse	Flexes of elbow joint
Triceps brachii (7.24)	Caudal border of scapula; insertion on distal of latissimus dorsi	Distal part of humerus; olecranon	Radial n.	Tracts brachium; extends elbow joint

Cross-references

The captions of the anatomical figures in the section “Contributions to Clinical-Functional Anatomy” have been deliberately kept to a minimum because the identification of anatomical details with the aid of the figure tables in the front of the book is straightforward. This effectively fulfils the goal of providing an easily memorable exercise for students. The cross-reference numbers refer to both the plate number in the topographical part of the book and the respective structure (Example: Teres major, 7.1 = Plate 7, No. 1 in the legends).

The same principle is also used in the **special anatomy tables**.

Preface

With our three-volume work on the Anatomy of the Dog (1), of the Horse (2), and of the Bovine (3), we pursue the goal to show the structure of the body by illustrations that are true to nature accompanied by a brief accompanying text. We do this in such a way that practical matters are emphasized and irrelevant clinical and functional details are only mentioned. Generally valid principles, which hold for all species with only slight species-specific differences, as for example the general anatomy of the autonomic nervous system, can be found in the *Anatomy of the Dog* (Vol. 1).

With the ever increasing importance of the horse as partner, helper, and sporting companion, we wanted with this submission of the second volume to emphasize the esthetics, grace and genial functionality of the structure of the body but also to emphasize in our book the susceptibility to diseases in all its naturalness. At the same time, we wanted to create an attractive basic contribution to animal health and a practice-related curriculum concept. In the newest edition presented here, the comprehensive and thorough revision of both the text and the figures was continued. A main objective was to join more closely the three areas, namely the topographical-anatomical main part with the clinical-functional contributions and the special anatomy in the form of tables into a uniform total concept, doing this by copious illustration and descriptive references. The well-tried didactic concept of the nexus between descriptive and illustrative elements on respective opposite pages of the book was understandably retained and further developed. In the topographical main part, additions and improvements are concentrated in the important, clinically significant, subjects such as the skin, the hoof and its suspensory apparatus with links to founder, head with pharynx and guttural pouch as well as the larynx, and arteries, veins and nerves of the pelvic cavity as also the perineal region in regards to obstetrics.

Corresponding to their increasing significance in study and practice, the contributions to clinical-functional anatomy were most intensively revised and most extensively completed. The close association between anatomy and orthopedics and their importance for equine medicine were taken into consideration by the expansion

and the completion of the chapters on the limbs. Clinically relevant subjects of the head and abdominal and pelvic cavities including the genital organs were more intensively illuminated with a view to colic and parturition. That concerns also the examination of the eye and rectal exploration of the abdominal and pelvic cavities in preparation for sonographic examination of the sex organs with attention to the sexual cycle, artificial insemination and examination for pregnancy. The clinical-functional part was enriched by excellent illustrations from our anatomical archive. By their publication in a suitable manner, the high scientific and esthetic value of the figures may be appreciated and be of use for veterinarians, students and especially for equine medical science. In the clinical-functional portion, corrections, changes, additions and the addition of color were undertaken on the archive figures. The labeling is but scarce and justified, since an identification of anatomical structures by the aid of figure tables in the main part of our book is easily possible. In this way, we attain the aim of an easily remembered exercise for the student. We thank our generous colleagues for providing valuable viewing material from sources of modern imaging methods. These sources are mentioned in the key to the figures. We are thankful for the cooperation of the following mentioned colleagues in our community of authors: Prof. Dr. Rolf Berg, Prof. Dr. Aaron Horowitz, Dr. Bianca Patan, Proff. Christine and Jörg Aurich, Prof. Dr. Astrid Rijkenhuizen, Prof. Dr. Harald Sieme, Dr. Claudia Nöller, Prof. Dr. Peter S. Glatzel, Prof. Dr. Hartmut Gerhards and Privat Dozentin Dr. Bettina Wollanke. The valuable and constructive ideas from our circle of readers, especially the students, were taken into consideration as far as possible. They are also very welcome in the future. We suffered an extremely sad loss from the passing away of our co-editor and friend, Prof. Dr. Wolfgang Sack, who masterfully shaped our former English editions. The common revision was wonderful and extremely beneficial for the improvement of our book.

Berlin, in the summer of 2008

For the authors,
Klaus-D. Budras

Chapter 1: Skin

1. The external Skin (common integument)

On the horse, the colors and markings of the skin are definite. Present markings, pigment-free and haired areas are detected. With dissection of the animal body, notice has to be taken of the variable thickness of the skin, hair coat, direction of the hairs and characteristics of the subcutaneous fat. The later dissection of the head can be used for the study of the vibrissae.

a) Generally, the **SKIN** is subdivided into 3 layers. 1. The epidermis, which is the layer of contact as well as the protective surface, 2. The corium or dermis, which assures the nutritive and sensory supply of the epidermis, and 3. The subcutis or hypodermis, which serves as a displaceable layer and fat layer (*panniculus adiposus externus*).

1. The **epidermis** (1) consists of a stratified, keratinized squamous epithelium. Where the common integument bears hairs, the epidermis is relatively thin in comparison to the different skin modifications as, for example, the hoof, where the epidermis is much thicker. The vital, living, part of the epidermis consists of a basal layer, which rests directly on the basal membrane, a spinous layer and a granular layer. The avital, non-living, part consists of the stratum lucidum, which is rarely present, and the stratum corneum, which make up the so-called cutaneous layer. Besides the cells of the epidermis, the keratinocytes, other cells of the basal layer are melanocytes (protection against ultraviolet radiation) and LANGERHANS cells in the basal and spinous layers (antigen presentation). A semipermeable epidermal barrier protects the body against the entrance of water and loss of fluid and regulates the absorption of medicaments in ointment application.

2. The **dermis** is subdivided into a **papillary layer** (2), which is found directly under the epidermis, and a **reticular layer** (2'). It consists of connective tissue, which in the papillary layer contains finer and in the reticular layer, coarser, net-like connected collagen fiber bundles. In the dermis, there are blood vessels and nerves. Besides supplying the tissues with nutrients and oxygen, the blood vessels have a thermoregulatory function, which is not inconsiderable. *The equine dermis is thinner than the bovine dermis.* The thickness varies between the different regions of the body and among the different breeds of horses.

3. The **subcutis** (3) consists of loose connective tissue with fixed and freely movable cells, adipose tissue, which *in the horse is of yellowish color and oily consistency*, and larger blood vessels. The subcutis is fixed by taut retinacula to fascia or the periosteum of underlying bone and is *distinctly more weakly developed in the horse than in the dog*. In some body regions (lips, cheeks, eyelids) the subcutis is absent.

The **nerve supply** is realized by sensory and sympathetic fibers. The sympathetic innervation of the blood vessels and sweat glands is related to thermoregulation, but is also a reflection of different states of excitement (e.g., sweating with high sympathetic tonus). Owing to the sensory innervation of the skin, it becomes the largest sense organ of the body. Besides free nerve endings, which serve as pain receptors and thermoreceptors, special receptor cells (**MERKEL cells**) and specially structured **nerve end-corpuscles** (**RUFFINI corpuscles**, **lamellar corpuscles** -4) are located in the skin. These function as pressure and tension receptors and receptors for movement.

The haired skin is characterized by the triad: hair sebaceous gland and apocrine sweat gland.

b) The **HAIRS** (*pili*) are differentiated into long hairs, ordinary hairs and wool hairs. Leading hairs are only very few in number and

irregularly distributed. *The long hairs occur in the horse on the head as the forelock (cirrus capitis —5), on the neck as the mane (juba —6) and at the root of the tail as the cirrus caudae (7). In many equine breeds a distinct tuft of hairs is present at the flexion surface of the fetlock of the thoracic or pelvic limb (cirrus pedis).* The other parts of the skin are covered with ordinary hairs and **wool hairs** (8), which are of variable character depending on the season. The roots of these hairs lie usually oblique to the surface in the dermis. **Hair tracts** are formed by this alignment. The hairs can be erected by the contraction of the smooth muscle cells (*mm. arrectores pilorum*), which are innervated by sympathetic nerves. In different regions of the body, the hair tracts form diverging (flank) or converging (forehead) hair whorls, hair sheaths (in extension of the flank fold) and hair crests. The density of the hair coat varies with the region of the body. It is most dense in the region of the head, less dense in the abdominal and inguinal regions.


The **SEBACEOUS GLANDS** (9) are holocrine secretory cutaneous glands, which release their product, the entire non-living, fat-containing cells into the hair follicle. The sebum thus secreted forms a thin fat film on the skin and hairs and ensures a sleek, glistening coat. At the body openings such as the mouth (lips), the perineal region, the udder, the vulva and prepuce relatively large, “free” sebaceous glands occur. These open onto the surface of the skin and not into a hair follicle.

APOCRINE SWEAT GLANDS (10) are associated with the presence of hairs. Their excretory ducts likewise open into the hair follicle. The secretion of the sweat glands consists of 97–99 % water, other constituents are electrolytes and proteins. Since in cases of stress up to 10 ml secretion per kg body weight per hour is given off (500 kg horse = 5 liters per hour), considerable losses of water can occur due to sweating. *Owing to the protein content of the secretion, with exercise of the animal, a very visible foamy sweat is formed.* The apocrine sweat glands are enlaced by cholinergic sympathetic nerve fibers. However, the innervation is probably limited to the blood vessels running there and to the myoepithelial cells of the glandular end-pieces.

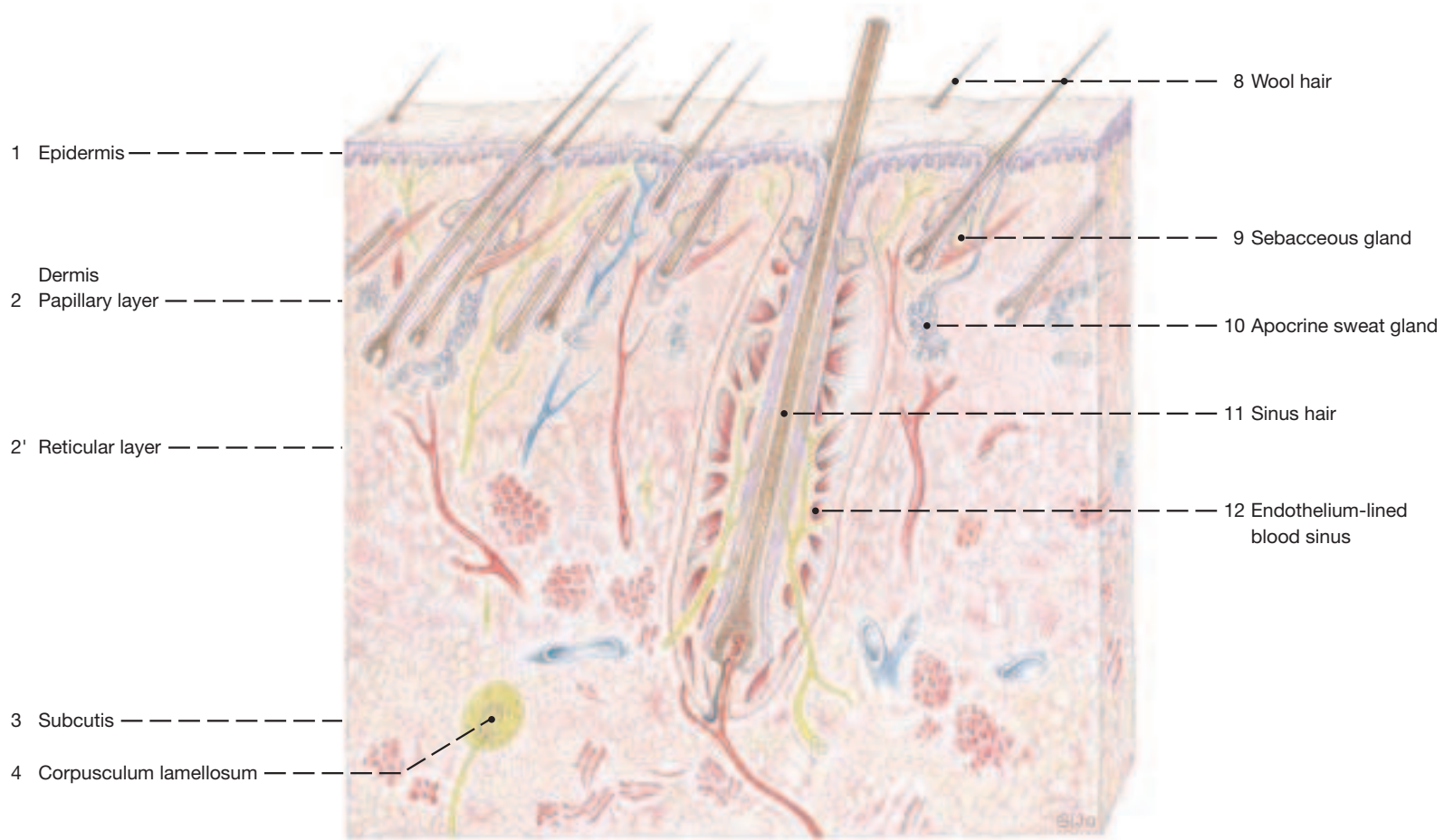
ECCRINE SWEAT GLANDS occur independent of the hairs and open freely, but they are very rare (e.g., heel (ball) segment of the hoof).

SINUS HAIRS (*pili tactiles* —11) are present on the upper and lower lip as well as on the eyelids. These tactile hairs are considerably larger than the normal hairs. The root of the hair reaches deeply, far into the reticular layer of the dermis, and is in contact with muscle fibers of the striated cutaneous musculature. The connective tissue root sheath is subdivided by an irregularly chambered **endothelium-lined blood sinus** (12) into an external and internal lamina. A distinct basal membrane and the external epithelial root sheath are associated with the internal lamina. Many **MERKEL cells**, which are in contact with (myelinated) nerve fibers, lie in the basal layer of the external epithelial root sheath. The **MERKEL cell-axon complexes** and free nerve-endings of unmyelinated nerve fibers are excited by deviation of the sinus hair. The movement of the hair and, by this, the pressure on the receptors is reinforced still more by compression of the blood sinus in the region of the hair follicle, by which a very sensitive mechanoreceptor-complex is formed. The importance of the sinus hairs for mechanoreception becomes also clear by the great number of sensory myelinated nerve fibers, which approach regularly the root of a sinus hair and are visible in the histological slide.

External Skin (common integument)



Lips



1. The Skeleton of the Thoracic Limb

1 The limbs of the horse are adapted for the well-developed ability to run fast. Compared to the plantigrade stance (newborn dog) and the digitigrade stance (adult dog), the overextended angulation at the canine carpus has been lost in the horse. The horse is an unguligrade animal and as a result of the straightening and lengthening of its limbs is capable of a long stride. The loss of rays 1 and 5, the reduction of 2 and 4, and the very well-developed digit 3 as the only one that supports the body are part of the same adaptation. The thoracic limbs in the standing horse carry about 55–60 % of the body weight. The rider, by using the reins to flex the atlanto-occipital and nearby cervical joints, “shortens” the neck and thus causes the center of gravity to move toward the hindlimbs. In horses of good conformation, the forelimbs appear straight and parallel to one another when viewed from the front. In lateral view, they should appear straight and vertical. A plumb line from the palpable **tuber** (5') on the scapular spine passes through the center of the fetlock joint and touches the caudal aspect of the hoof.

The shoulder girdle (scapula, coracoid, clavicle of other animals) is greatly reduced; the clavicle has disappeared and only a fibrous strip (clavicular intersection) is left in the brachiocephalicus.

2 a) The equine **SCAPULA** is characterized by the wide, semilunar **scapular cartilage** (14) that enlarges its dorsal border. The spine presents a palpable tuber and subsides distally opposite the neck of the bone without forming an acromion. An **infraglenoid tubercle** (20) is sometimes present.

3 b) **HUMERUS**. The **greater** (25) and **lesser** (29) **tubercles** on the lateral and medial sides, respectively, of the proximal extremity are nearly equally well developed. Both tubercles are separated by a sagittal **intertubercular groove** (28) which is wide and carries an **intermediate tubercle** (28'). The latter fits into a depression on the deep surface of the wide biceps tendon and seems to impede movement of the tendon relative to the humerus in the standing horse. The body of the bone presents the **teres major tuberosity** (32') on its medial surface about opposite the much more salient **deltoid tuberosity** (32) on the lateral surface. The distal end forms a cylindrical **condyle** (35) that transfers the weight onto the radius. The condyle presents laterally a slight sagittal ridge flanked by grooves that fit into corresponding features on radius and ulna. The **epicondyles**, **lateral** (38) and **medial** (39), as well as the **lateral supracondylar crest** (38') are palpable. The shallow **radial fossa** (41) is just proximal to the condyle on the cranial surface of the bone. The very much deeper **olecranon fossa** (40) between the two epicondyles lies opposite the radial fossa on the caudal surface. (There is no perforation in the form of a supratrochlear foramen between the two fossae.)

4; 6 c) Of the two bones, **RADIUS** and **ULNA**, that form the antrebrachial skeleton, only the radius supports the humerus in the elbow joint. The **radius** on its proximomedial aspect presents the large **radial tuberosity** (46) that serves as the insertion of the biceps tendon. At the distal end of the bone, unobtrusive **medial** (50) and **lateral** (61) **styloid processes** form the ends of the articular surface; the lateral process contains a distal remnant of the ulna.

5 The **ulna** is fused to the radius and with its olecranon limits extension of the elbow joint. Its proximal extremity (**olecranon tuber**, 52) reaches to the fifth rib. The shaft of the bone is greatly reduced and tapers to end in midforearm. The fusion of the two bones is interrupted at an **interosseous space** (62) that is situated in the proximal third of the forearm.

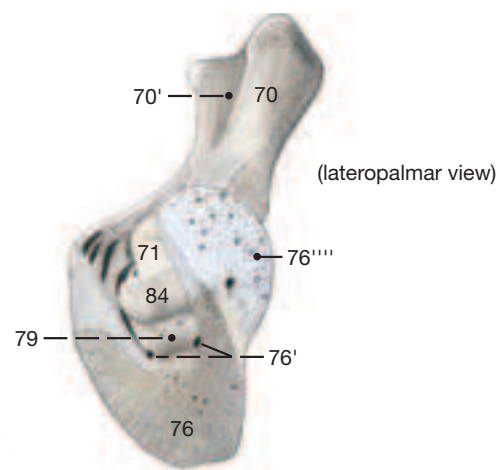
7; 8 **9** d) **CARPAL BONES**. The bones of the proximal row from medial to lateral are the **radial** (63), the **intermediate** (63'), the **ulnar** (64), and the **accessory** (65) **carpal bones**. The bones of the distal row are

numbered, **first to fourth carpal bones** (66), of which the first is small and inconstant. **10**

e) **METACARPAL BONES**. Only Mc2, 3, and 4 are present. Mc1 and 5 have disappeared and Mc2 and 4 are greatly reduced in accordance with the streamlining and lengthening of the limb for speed. **11** Mc3, also known as **cannon bone**, is well developed and carries the entire weight assigned to the limb; it is a very robust bone with a lateromedially oriented oval cross section. The caput at the distal end of the bone presents a sagittal ridge that engages a groove in the proximal phalanx. Mc2 and 4, known also as **splint bones**, are slender and about a third shorter than the cannon bone. The **proximal bases** (67) of the metacarpal bones articulate with the carpal bones (Mc2 with C2; Mc3 with C2 and 3; and Mc4 with C4). The splint bones are connected to Mc3 by fibrous tissue, their rounded distal end is an important palpable landmark. **12**

f) The proximal, middle, and distal **PHALANXES** (70, 71, 76) form the supporting skeleton of the single third digit. The **proximal phalanx**, also known as Phalanx I (PI), is the longest of the three; it presents a **triangular rough area** (70') on its palmar surface. The **middle phalanx** (PII) is half as long as the preceding bone and presents a **flexor tuberosity** (75) on its proximopalmar aspect that, in the fresh state, is enlarged proximally by a stout **complementary fibrocartilage** for the attachment of ligaments and the tendon of the supf. digital flexor. The **distal phalanx** (PIII) is also known as the coffin bone. It consists of spongy bone throughout and presents **sole foramina** (76') and **parietal grooves** (76'') as conduits for blood vessels. The medial and lateral **hoof cartilages** (76''') surmount respective **palmar processes** (76''') of the bone; they are slightly curved to conform to the curvature of the hoof. Their proximal border projects above the hoof where they can be palpated. The **articular surface** (77) of the distal phalanx makes contact principally with the middle phalanx, but has a small facet for articulation with the distal sesamoid bone. The **flexor surface** (79) of the coffin bone provides insertion for the deep flexor tendon. **13** **14** **15** **16**

Phalanges, Navicular Bone, and Hoof Cartilages with some of their Ligaments



g) The proximal and distal **SESAMOID BONES** are of considerable clinical importance in the horse. The (paired) **proximal bones** (83) articulate with Mc3, while the single distal bone, known as the **navicular bone** (84), lies within the hoof and contacts both middle and distal phalanges. **17** **18**

Thoracic Limb

Scapula

- Costal surface (1)
- Serrated surface (2)
- Subscapular fossa (3)
- Lateral surface (4)
- Scapular spine (5)
- Tuber of scapular spine (5')
- Supraspinous fossa (6)
- Infraspinous fossa (7)
- Caudal border (10)
- Cranial border (11)
- Scapular notch (12)
- Dorsal border (13)
- Scapular cartilage (14)
- Caudal angle (15)
- Cranial angle (16)
- Ventral [articular] angle (17)
- Glenoid cavity (18)
- Neck of scapula (19)
- Infraglenoid tubercle (20)
- Supraglenoid tubercle (21)
- Coracoid process (22)

Humerus

- Head of humerus (23)
- Neck of humerus (24)
- Greater tubercle (25)
- Cranial part (25')
- Caudal part (25'')
- Crest of greater tubercle (26)
- Triceps line (27)
- Intertubercular groove (28)
- Intermediate tubercle (28')
- Lesser tubercle (29)
- Cranial part (29')
- Caudal part (29'')
- Body of humerus (31)
- Deltoid tuberosity (32)
- Teres tuberosity (32')
- Crest of humerus (33)
- Brachialis groove (34)
- Condyle of humerus (35)
- Lateral epicondyle (38)
- Lateral supracondylar crest (38')
- Medial epicondyle (39)
- Olecranon fossa (40)
- Radial fossa (41)

Radius

- Head of radius (43)
- Circumferential facet (44)
- Neck of radius (45)
- Radial tuberosity (46)
- Body of radius (47)
- Trochlea of radius (48)
- Medial styloid process (50)

Ulna

- Olecranon (51)
- Olecranon tuber (52)
- Anconeal process (53)
- Trochlear [semilunar] notch (54)
- Medial coronoid process (55)
- Lateral coronoid process (56)
- Radial notch (57)
- Body of ulna (58)
- Lateral styloid process (61)
- Interosseus space (62)

Carpal bones

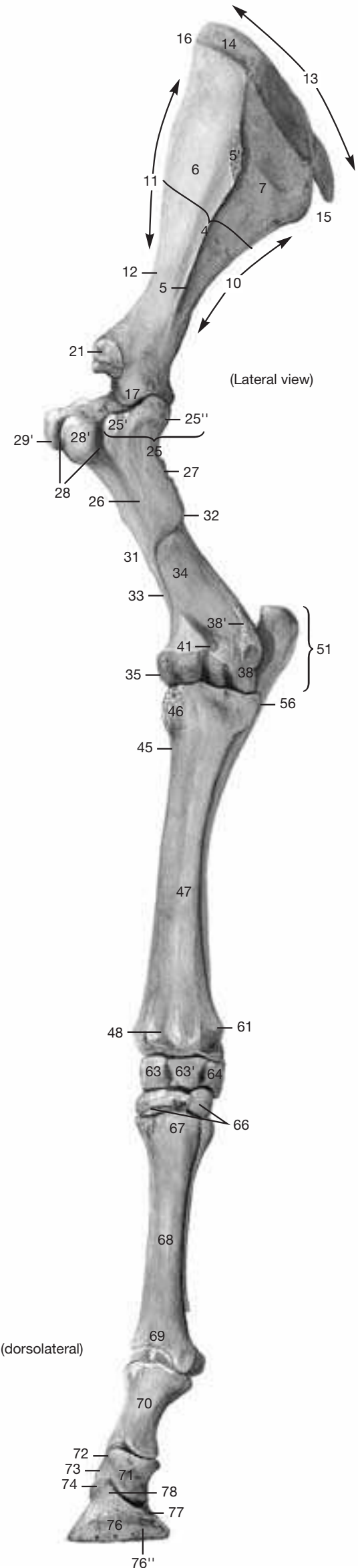
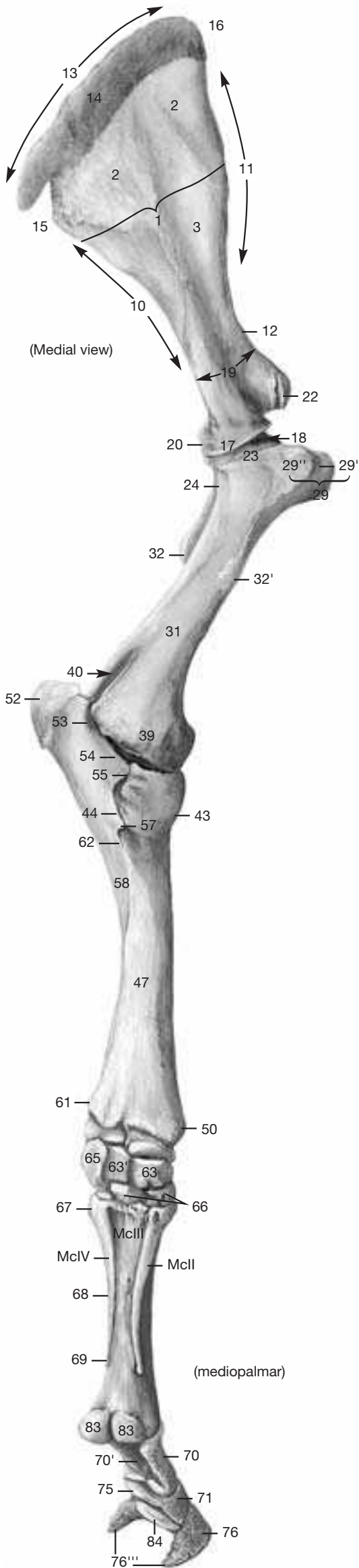
- Radial carpal bone (63)
- Intermediate carpal bone (63')
- Ulnar carpal bone (64)
- Accessory carpal bone (65)
- First, second, third, fourth carpal bones (66)

Metacarpal bones II-IV

- Base (67)
- Body (68)
- Head (69)

Digital bones

- Proximal phalanx (70)
- Triangular rough area (70')
- Middle phalanx (71)
- Base (72)
- Body (73)
- Caput (74)
- Flexor tuberosity (75)
- Distal phalanx (76)
- Sole foramen (76')
- Parietal groove (76'')
- Palmar process (76''')
- Hoof cartilage (76''')
- Articular surface (77)
- Extensor process (78)
- Flexor tuberosity (79)
- Proximal sesamoid bone (83)
- Distal (navicular) sesamoid bone (84)



The two Figures on the opposite page show the structures mentioned in the account below to best advantage. The following steps would reproduce the dissection upon which the two Figures were based:

Skin the limb to the hoof (note the chestnut, the homologue of the carpal pad, proximomedial to the carpus; the ergot, homologue of the metacarpal pad, caudal to the proximal phalanx is often hidden in long hair). Remove the **pectoral muscles** and the **subclavius** (innervated by the cranial and caudal pectoral nerves, respectively). Preserve the blood vessels throughout. Transect the **deltoideus** at the level of the shoulder joint. The tensor fasciae antebrachii and the lateral head of the triceps are transected at their middle. In mid-forearm, the flexor carpi radialis and flexor carpi ulnaris are transected.

In addition, transect the tendon of origin of the **biceps brachii** to expose the intertubercular bursa; the supf. and deep digital flexor tendons are lifted from the carpal canal after transection of the flexor retinaculum.

a) SHOULDER AND ARMS

- 1 A) The roots of the **brachial plexus** (4) arise from the ventral branches of C6 through T2.
- 2 B) The **axillary nerve** (14) innervates the **teres major** (1), the caudal segment of the **subscapularis** (3), and, on the lateral side, the **deltoideus** (6) and the relatively tendinous **teres minor** (13). The axillary nerve ends by furnishing the **cranial cutaneous antebrachial nerve** (26) which supplies the skin on the cranial aspect of the forearm. The **subscapular nerves** (3) innervate most of the subscapularis. The **suprascapular nerve** (9) crosses the cranial border of the scapula and ends in the **supra-** (5) and **infraspinatus** (10) muscles. The sharp scapular border and the absence of an acromion are thought to expose the nerve to mechanical trauma. The **thoracodorsal nerve** (2) passes caudally to innervate the **latissimus dorsi** (2). **Median** (8) and **musculocutaneous** (7) nerves join to form a loop (ansa axillaris) which supports the axillary artery as it passes into the limb. The musculocutaneous nerve, with its proximal and distal muscular branches, supplies the **coracobrachialis** (19) and **biceps** (25), and the **brachialis** (20), respectively. It ends as the **medial cutaneous antebrachial nerve** (30). The proximal muscular branch passes deep (lateral) to the coracobrachialis to reach the biceps. The **radial nerve** (11) releases a branch to the **tensor fasciae antebrachii** (21) before changing over to the lateral aspect of the arm. Proximal muscular branches are given off to the **anconeus** (24) and the **long** (15), **medial** (17), and **lateral** (16) heads of the triceps that lacks an accessory head in the horse. The nerve then crosses the lateral supracondylar crest of the humerus and splits into **supf.** (27) and **deep** (18) branches.
- 3

b) NERVES AND MUSCLES ON THE CRANIO-LATERAL SURFACE OF THE FOREARM

The supf. branch of the radial nerve gives rise to the **lateral cutaneous antebrachial nerves** (29); none of these reach the carpus—the dorsum of metacarpus and digit is supplied by the median and ulnar nerves. The deep branch of the radial nerve goes to the cranio-lateral muscles of the forearm.

The carpal and digital extensors arise from the cranio-lateral aspect of the distal end of the humerus and from the nearby lateral collateral ligament of the elbow joint. The **common digital extensor**, in

addition to its large **humeral head** (33), has a small **radial head** (34) known formerly as Phillip's muscle, whose thin tendon joins that of the lateral digital extensor to end on the proximal phalanx. (A tiny deeply placed ulnar head, formerly Thierness' muscle, is also present.) The tendon of the common digital extensor, before ending on the extensor process of the distal phalanx, attaches also on the middle phalanx and receives the extensor branches of the largely tendinous interosseus (see p. 13).

The **lateral digital extensor** (36) presents a bursa at its insertion on the proximolateral surface of the proximal phalanx.

The **extensor carpi radialis** (31) receives the lacertus fibrosus (see p. 13) and terminates on the proximodorsal tuberosity of the large metacarpal bone.

The **ulnaris lateralis** (38; m. extensor carpi ulnaris) ends on the accessory carpal bone, and with a second, longer tendon on the lateral splint bone. Only the long tendon has a tendon sheath.

The **extensor carpi obliquus** (42; m. abductor pollicis longus) ends on the proximal end of the medial splint bone; its tendon is protected by a synovial sheath and a subtendinous bursa.

c) NERVES AND MUSCLES ON THE CAUDOMEDIAL SURFACE OF THE FOREARM

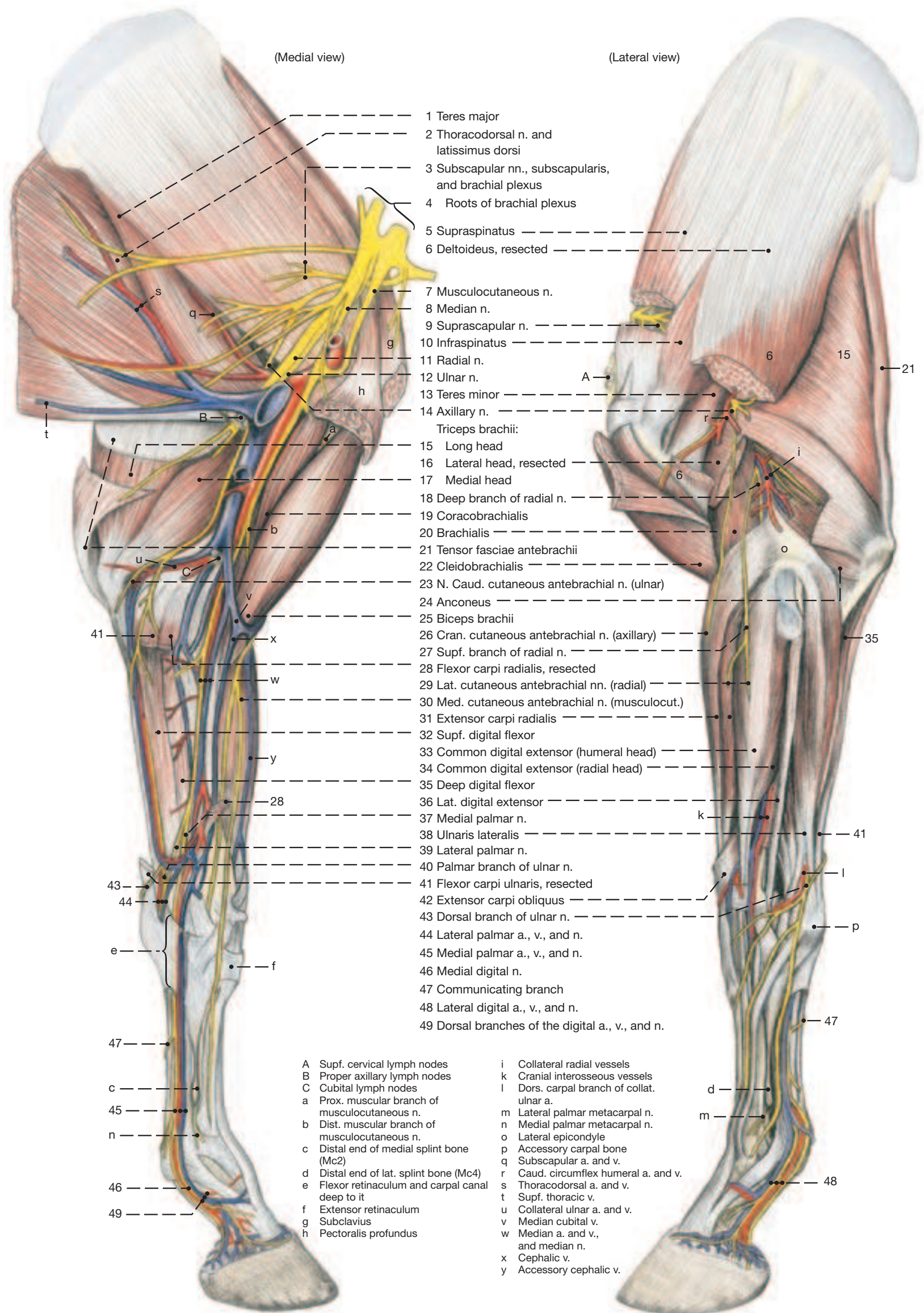
The median nerve accompanies the brachial artery and vein over the elbow joint where it releases muscular branches to the **flexor carpi radialis** (28) and to the radial and humeral heads of the **deep digital flexor** (35; see p. 13). (The pronator teres of other species has become the long part of the medial collateral ligament of the elbow joint; the pronator quadratus is absent.)

The median nerve ends in the distal half of the forearm by dividing into **medial** (37) and **lateral** (39) **palmar nerves**. The medial palmar nerve passes through the carpal canal along the medial border of the deep flexor tendon. The lateral palmar nerve crosses the musculotendinous junction of the supf. digital flexor, receives the palmar branch of the ulnar nerve, and follows the lateral border of the deep flexor tendon through the carpal canal. (The two nerves, after passing the carpal canal, may also be termed the common digital nerves II and III.)

The **ulnar nerve** (12) lies caudal to the brachial vessels and, in the distal third of the arm, releases the **caudal cutaneous antebrachial nerve** (23). After crossing the elbow joint the ulnar nerve releases muscular branches to the **flexor carpi ulnaris** (41), the **supf. digital flexor** (32), and to the ulnar head (see p. 13) and the humeral head of the deep digital flexor. The nerve then passes distally in the caudal border of the forearm. A few cm proximal to the accessory carpal it divides into dorsal and palmar branches. The **dorsal branch** (43), palpable as it becomes subcutaneous at this location, passes around the lateral aspect of the carpus to innervate the skin on the dorsolateral surface of the cannon. The **palmar branch** (40) as already mentioned joins the lateral palmar nerve of the median in the carpal canal.

The bellies of the supf. and deep flexors form a partially fused muscle mass on the caudal surface of the radius. Their tendons distal to the carpus are described on p. 13.

Thoracic Limb



3. Cutaneous Innervation, Blood Vessels, and Lymphatic Structures of the Thoracic Limb

Clinical and Functional Anatomy p. 118–119

a) CUTANEOUS INNERVATION

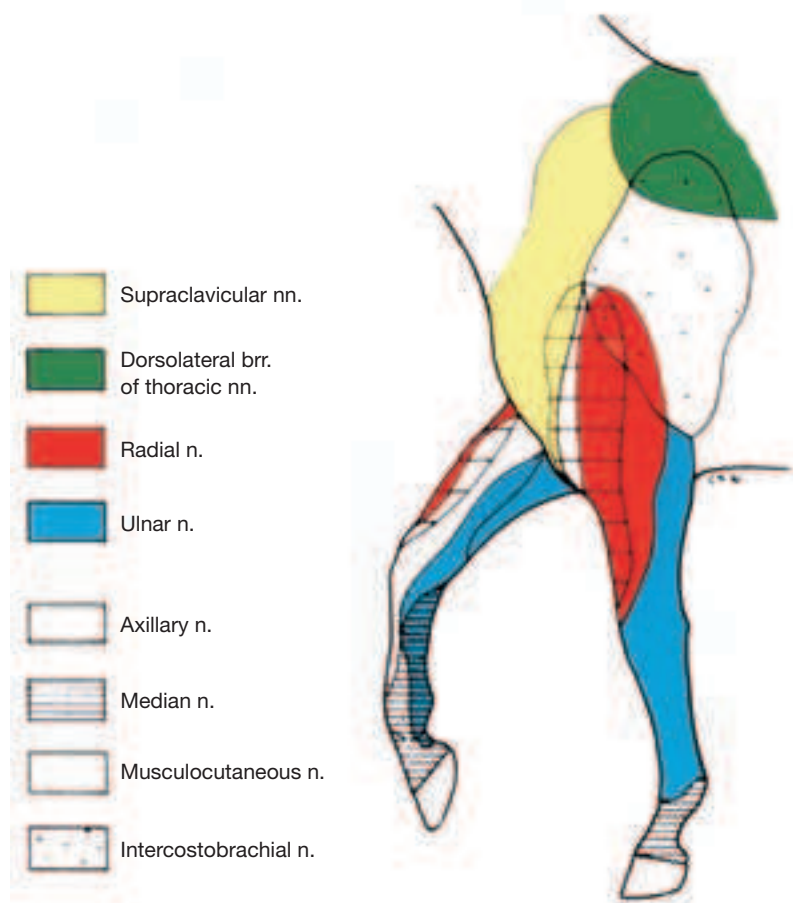
The skin of the forelimb is innervated in the region of the scapular cartilage by the dorsal branches of the thoracic nerves. The small area over the cranial border of the scapula is supplied by the ventral branch of the 6th cervical nerve (n. supraclavicularis). The large region over scapula and triceps receives its innervation from the **intercostobrachial nerve** (1; from brachial plexus and the ventral branches of T2 and T3) which carries also motor fibers for the m. cutaneus omobrachialis.

The cranial region of distal arm and forearm receives skin sensation from the **cranial cutaneous antebrachial nerve** (axillary; 24). The lateral skin region of distal arm and forearm is supplied by the **lateral cutaneous antebrachial nerve** (radial; 27). The **caudal cutaneous antebrachial nerve** (ulnar; 9) innervates the caudal, and the **medial cutaneous antebrachial nerve** (musculocutaneous; 29) the medial surface of the forearm.

Carpus and metacarpus receive skin innervation from the **medial cutaneous antebrachial nerve** (29) for the dorsomedial surface, from the **dorsal branch of the ulnar nerve** (14) for the dorsolateral surface, and from the **medial** (16) and **lateral** (15) **palmar nerves** for the palmar surface.

The medial surface of the digit is innervated by the **medial digital nerve** (median n.; 17), while the lateral surface receives a mixed innervation (median and ulnar nn.) from the **lateral digital nerve** (see pp. 7 and 11).

Cutaneous Nerves of the Thoracic Limb (craniolateral view)



b) BLOOD VESSELS

The **subclavian artery** (19), before becoming the **axillary artery** (20), gives off the **supf. cervical artery**. The deltoid branch of the latter accompanies the **cephalic vein** (23) through the groove between brachiocephalicus and pectoralis descendens. (The cephalic vein arises from the external jugular vein.) The axillary vessels (a. and v.) give rise, either directly or indirectly, to the **external thoracic vessels** (21) to the pectoral muscles, the **suprascapular vessels** (18) to the lateral scapular muscles, the **subscapular vessels** (2) to the caudal border of the like-named muscle, the **thoracodorsal vessels** (4) to

the latissimus dorsi, and the **caudal circumflex humeral vessels** (3) which anastomose with the cranial circumflex humeral vessels, the last branches of the axillary vessels before the stem artery becomes the brachial artery. (The thoracodorsal and caudal circumflex humeral arteries are branches of the large subscapular artery and therefore indirect branches of the axillary.) The **cranial circumflex humeral artery** (22) accompanies the proximal muscular branch of the musculocutaneous nerve deep to the coracobrachialis to the biceps, while the often double satellite vein can cross the coracobrachialis on either surface. The **supf. thoracic (spur) vein** (5) arises from the initial segment of the thoracodorsal vein, passes caudally, and drains the ventral part of the trunk.

The **brachial vessels** (7) in midarm give off the **deep brachial vessels** (6) to the triceps, and more distally the **bicipital vessels** (25) to the biceps. The **transverse cubital vessels** (26), the next branches, pass deep to the biceps. From the caudal surface of the brachial vessels arise the **collateral ulnar vessels** (8) which follow the ulnar nerve. The last branches are the **common interosseous vessels** (28) which pass to and through the interosseous space. They often are continued by the cranial interosseous vessels.

At the level of the elbow, the brachial vein gives off the **median cubital vein** (10) which provides an anastomosis to the cephalic vein. After leaving the groove between brachiocephalicus and pectoralis descendens, the **cephalic vein** (23) descends on the medial surface of the forearm. Already at the elbow joint it releases the **accessory cephalic vein** (30) which parallels the cephalic vein, but inclines more cranially to end on the dorsal surface of the carpus.

The **median artery and vein** (11) continue the brachial vessels in the forearm in close mediocaudal proximity to the radius. The vein is often double. The median vessels give off one or two **deep antebrachial vessels** (12) which supply the caudomedial antebrachial musculature. Proximal to the carpus they give rise to the proximal radial artery and the **radial vessels** (31). The radial vein receives the cephalic vein and as the **medial palmar vein** (16) passes subfascially over the mediopalmar aspect of the carpus. The **palmar branch** (13) of the median vein receives the collateral ulnar vein and as the **lateral palmar vein** (15) continues over the lateropalmar surface of the carpus.

The median artery after giving off its palmar branch passes through the carpal canal. After that it is joined by a branch from the radial artery, and as the **medial palmar artery** (16) (the largest artery in this area) passes toward the digit.

The small **lateral palmar artery** (15) originates from the union of the palmar branch of the median artery with the collateral ulnar artery proximal to the carpus.

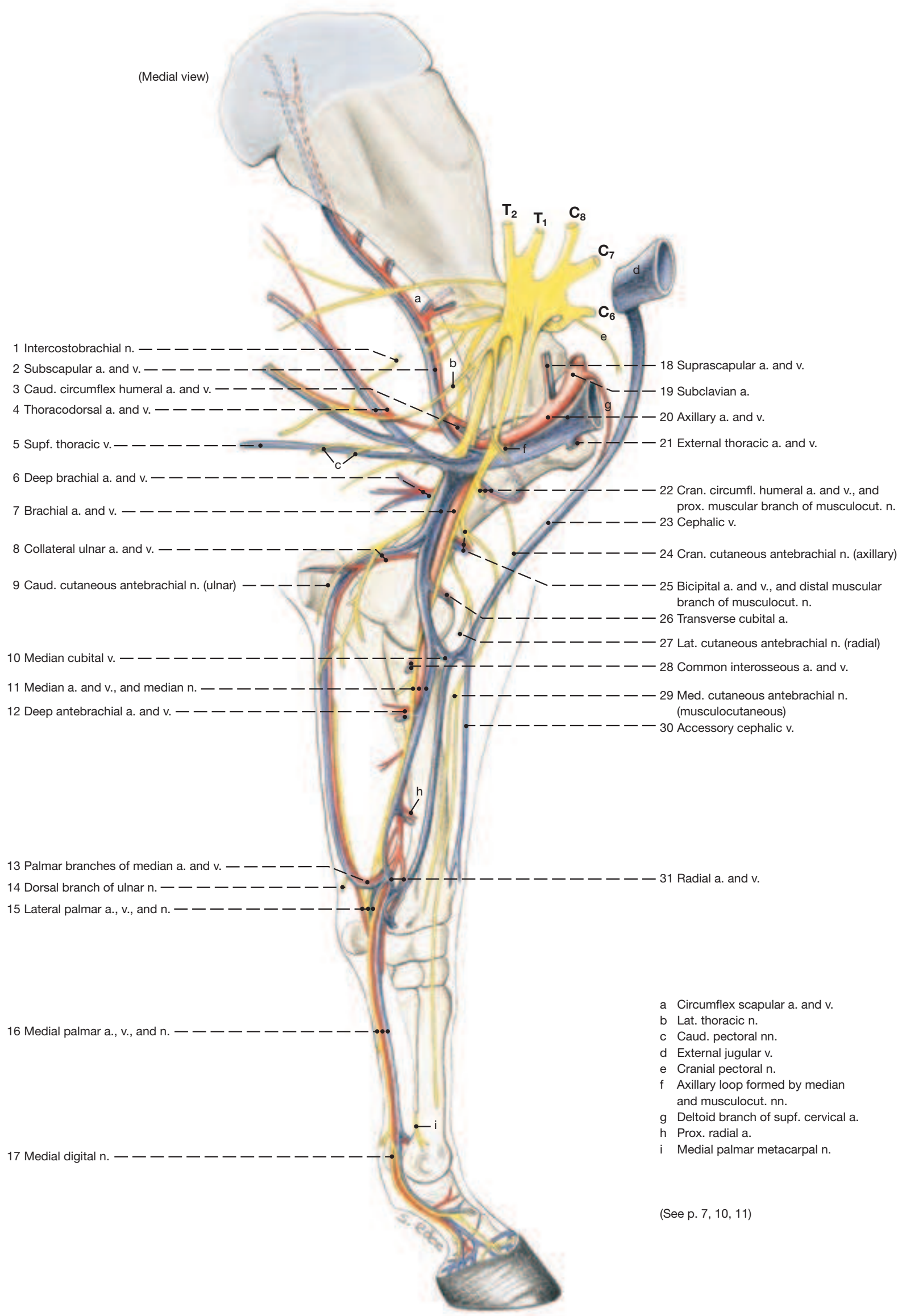
The median and lateral palmar metacarpal arteries descend on the axial surface of the splint bones. They arise distal to the carpus from the deep palmar arch that is formed by branches of the median and radial arteries.

c) LYMPHATIC STRUCTURES

Lymph from the hoof is collected in several vessels that become dissectable proximal to the coronet. At first evenly spaced around the digit, they converge on each side to form one to three vessels. Those on the lateral side change over to the medial side a few cm proximal to the proximal sesamoid bones. They do so either deeply between the interosseus and the deep flexor tendon or subcutaneously. The lymphatics then accompany the medial palmar vessels and nerve and ascend (predominantly through the carpal canal) to the medial aspect of the forearm and thence to the **cubital lymph nodes** (see p. 7.C) that lie just proximal to the elbow joint. From here the lymph passes to the **axillary nodes** (see p. 7.B) on the distal end of the teres major.

From the axillary nodes the lymph passes via the caudal deep cervical nodes to the veins at the thoracic inlet. Lymph, especially from the proximal and lateral areas of the forelimb, is channeled to the **supf. cervical nodes** (see p. 7.A), not to the axillary ones.

Arteries, Veins and Nerves of the Thoracic Limb



- 1 a) Just distal to the carpus the **MEDIAL PALMAR ARTERY, VEIN AND NERVE** (2) lie next to each other in this dorsopalmar sequence (VAN). Artery and nerve have just passed through the carpal canal; the vein crossed the carpus supf. to the flexor retinaculum. In the metacarpus, the three structures, retaining this sequence, lie medial to the interosseus and deep flexor tendon. (There are no corresponding dorsal vessels and nerves.)

At the fetlock joint the medial palmar vessels and nerve become the **medial digital vessels and nerve** (7). These release several **dorsal branches** (9) that serve the dorsal surface of the digit. Opposite the pastern joint they give off a branch to the **digital cushion** (10).

The **lateral palmar artery, vein, and nerve** (3) pass the carpus near the tip of the accessory carpal. They are markedly thinner than their medial counterparts, especially the artery. Vein and nerve lie next to each other, and deep to them lies the small artery. They are succeeded at the fetlock by the **lateral digital vessels and nerve** (8). There are no real differences in distribution from the same structures on the medial side. The prominent **communicating branch** (4) connecting the medial and lateral palmar nerves must be taken into account when nerve blocks are performed.

For the deeper-lying palmar metacarpal nerves we need to return to the carpal level. Here the median nerve (g) splits into medial and lateral palmar nerves (c and b; or 2 and 3 that were followed into the

digit just now). The ulnar nerve (a) also splits: its **dorsal branch** (1) supplies the skin over the dorsolateral aspect of carpus and metacarpus, while its **palmar branch** (d) joins the lateral palmar nerve. Soon after receiving the branch of the ulnar, the lateral palmar nerve gives off a deep branch that innervates the interosseus and is continued by the **medial and lateral palmar metacarpal nerves** (5; 6). These are deeply placed and run along the axial surfaces of the two splint bones where they are accompanied by equally thin arteries.

b) The **DEEP FASCIA** on the dorsal surface of the carpus forms the **extensor retinaculum** (see p. 7.f) that guides the extensor tendons over the joint. On the palmar surface it furnishes the **flexor retinaculum** (see p. 7.e) that extends from carpal bones on the medial side to the accessory carpal forming the carpal canal with these bones. At the level of the fetlock joint the deep fascia is again thickened to form the **annular ligament of the fetlock joint** (A in Figure below) that is most prominent at the palmar aspect where it connects the abaxial borders of the proximal sesamoid bones and holds the flexor tendons in place. Distal to this the deep fascia forms the **proximal digital annular ligament** (B). This resembles the letter X and holds the flexor tendons against the ligaments on the palmar surface of the proximal phalanx. Its four corners insert on the medial and lateral borders of the bone, the distal two attachments being weaker than the proximal, as the ligament here blends also with the two branches of the supf. flexor tendon. The **distal digital annular ligament** (C) arises from the medial and lateral borders of the proximal phalanx and descends to the distal phalanx between the deep flexor tendon and the digital cushion. It is crossed medially and laterally by the ligament of the ergot (not shown), subcutaneously, connects the ergot with the hoof cartilage.

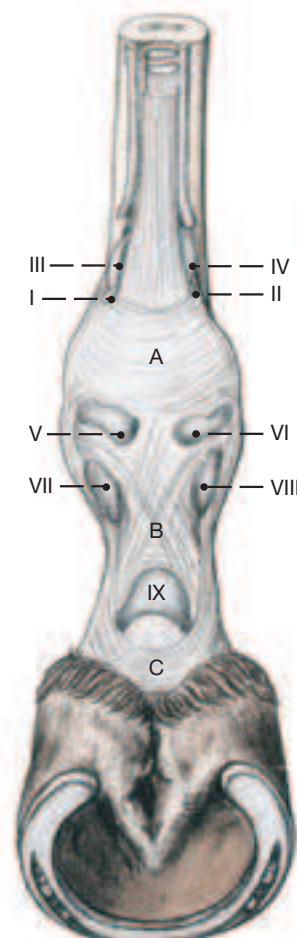
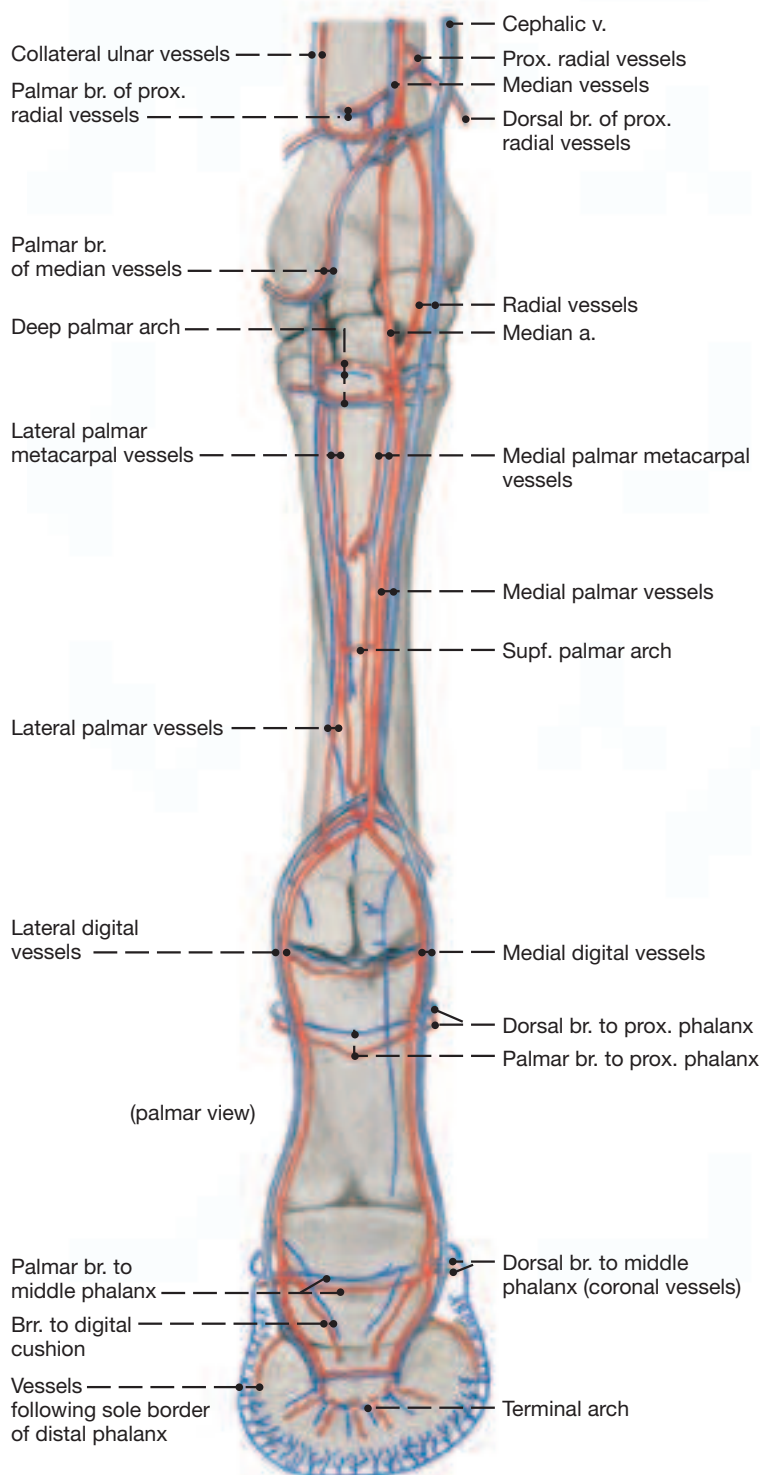
The **digital synovial sheath** surrounds the flexor tendons and facilitates their movements against each other and over the three bearing surfaces on the palmar surface of the digit.

Inflammation may cause the sheath to swell and to pouch out in any of the nine places where it is not bound down by the annular ligaments just described: Four pouches occur proximal to the annular ligament of the fetlock joint; two (I and II) medial and lateral to the supf. flexor tendon and two (III and IV) medial and lateral to the interosseus. The remaining more discrete single pouches are as shown in the next figure below.

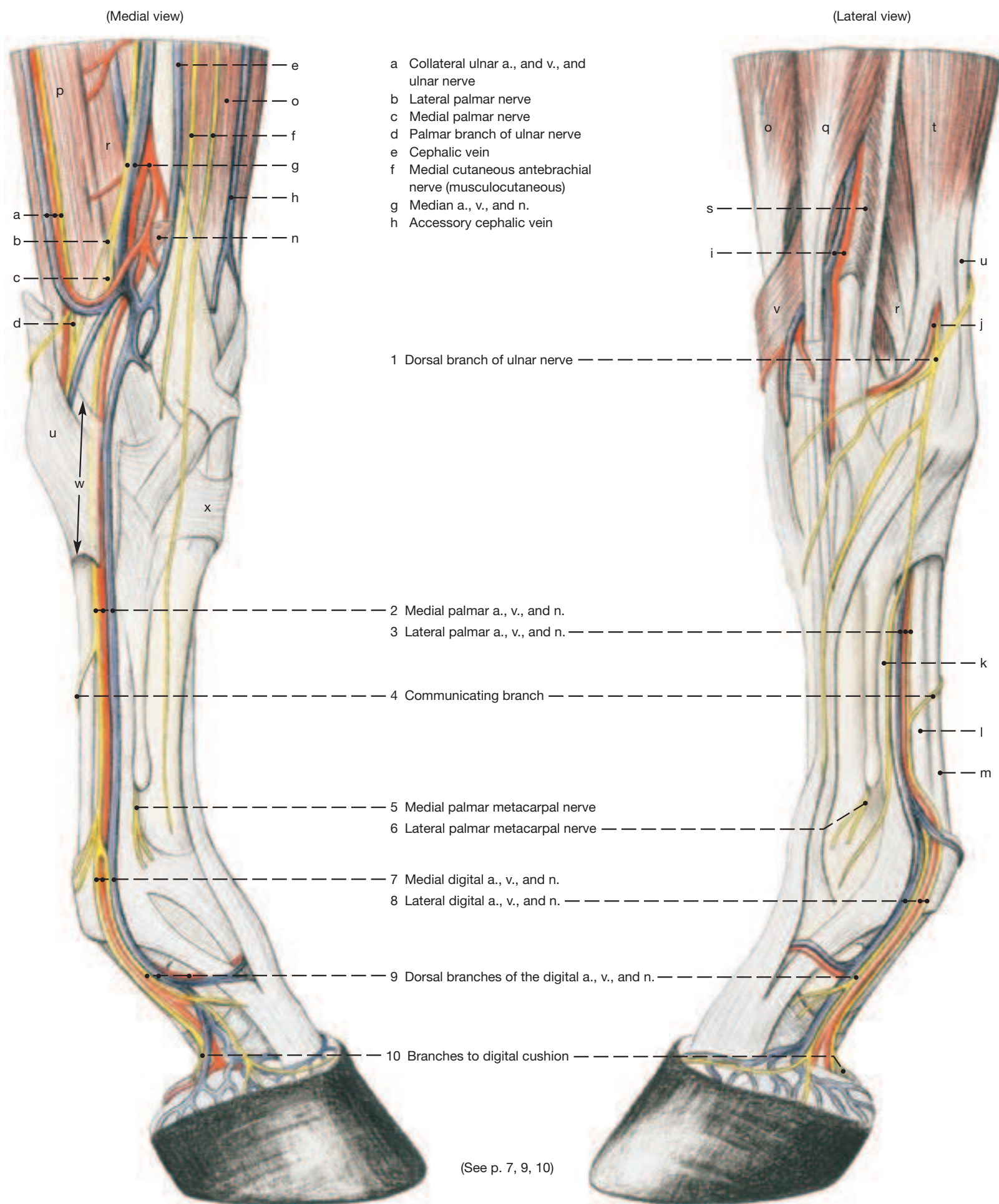
Palmar View of Fetlock and Digit

(For explanation see text above.)

Arteries and Veins of the Left Distal Forelimb



Arteries, Veins, and Nerves of the Distal Forelimb



The structures making up the **PASSIVE STAY-APPARATUS** are shown on the opposite page schematically and on two dissections. The latter show the actual structures to best advantage and were made by the following steps. The limb is skinned to the hoof, and the pectoral muscles, subclavius, and rests of the trapezius and brachiocephalicus are removed. Blood vessels and nerves can be discarded (and removed) throughout. The extensor carpi radialis is resected at the level of the elbow, preserving the lacertus fibrosus as shown. Then the brachialis is resected. At the level of the fetlock and digit, the palmar annular ligament and the prox. digital annular ligament are transected axially, and the sleeve formed by the supf. digital flexor around the deep digital flexor tendon is opened by a similar but deeper cut. The deep flexor tendon is transected in midmetacarpus and lifted out of the sleeve so it can be reflected distally.

The **PASSIVE STAY-APPARATUS** of both fore- and hindlimbs enables the horse to be on its feet for long periods with a minimum of muscular effort. Older subjects actually doze (perhaps sleep) while standing, although for a refreshing sleep horses lie down, usually at night when they are unobserved. By being on its feet most of the time, the horse, a rather nervous and excitable animal that uses flight as its principal means of defense, appears to be in perpetual readiness to run away from danger.

The four limbs that carry the body of a quadruped are angulated bony columns that would collapse were they not prevented from doing so by the activity of the intrinsic limb muscles. Active muscles soon tire and become painful, which signals the animal to lie down. The effort of the intrinsic limb muscles of horses is greatly reduced by the non-tiring tendons and ligaments of the stay-apparatus, which stabilizes the joints in a position suitable for the support of the body. In most joints stabilization means preventing them from flexing. Pastern and fetlock joints in the standing horse, however, are extended and overextended, respectively; their stabilization requires them not to overextend further so as to prevent the fetlock from sinking to the ground.

1. The fleshy attachment (**synsarcosis**) of the forelimb to the trunk is not part of the stay-apparatus, though the serratus ventralis that serves as the principal **weight-bearing** connection is heavily interlaced with non-tiring tendinous tissue.

2. Though no collateral ligaments are present, the movements in the **shoulder joint** are restricted largely to flexion and extension in the sagittal plane by the subscapularis medially and the infraspinatus and (to a lesser degree) the supraspinatus laterally.

The principal stabilizer of the shoulder joint in the standing horse is the biceps tendon pressing against the cranial (extensor) surface of the joint. The way the tendon caps the intermediate tubercle of the intertubercular groove suggests a partial locking of the joint. The shoulder joint is further prevented from collapsing (flexing) by the internal tendon of the biceps that anchors the muscle to the most proximal part of the radius and, via the lacertus fibrosus and extensor carpi radialis, to a similar point on the large metacarpal bone. Thus the weight of the trunk acting on the proximal end of the scapula, tenses the biceps-lacertus-extensor carpi “rigging” just mentioned. This causes a cranial “pull” on the elbow joint (i. e., an extension of the joint) and “pressure” on the extensor surface of the carpal joint that tends to prevent flexion in that joint.

3. The **elbow joint** is stabilized (i. e., prevented from flexing) principally by tension in a group of carpal and digital flexors that arise on the medial and lateral epicondyles of the humerus and contain much fibrous tissue. Eccentrically placed collateral ligaments inhibit flexion to a lesser degree. The principal extensor of the joint, the triceps, seems inactive by its flabbiness in the quietly standing horse, although some workers believe that its tonus alone would prevent collapse of this key joint. The “pull” on the flexor surface by the

biceps insertion that would tend to keep the joint extended has already been mentioned.

4. The **carpal joint** is stabilized (prevented from flexing) by the (dorsal) “pressure” of the extensor carpi radialis tendon already alluded to. The flexor carpi ulnaris and ulnaris lateralis ending on the accessory carpal and being tensed by the weight of the trunk via scapula, fixed shoulder joint, and humerus, “pulls” on the flexor surface of the carpal joint in an attempt to keep the joint extended. The accessory ligaments of the supf. and deep digital flexors attaching on the palmar surface of radius and large metacarpal bone above and below the carpus tend to supply a similar “pull”, again by the weight of the animal, but in the opposite direction—distally. Some workers ascribe a similar potential to the interosseus.

5. The **fetlock joint** needs to be stabilized by being prevented from further overextending, i. e., sinking toward the ground. This is accomplished by three elements: the suspensory apparatus associated with the interosseus, and the supf. and deep digital flexor tendons. These attach to the palmar surface of the limb skeleton proximal and distal to the joint and are tensed when the weight of the horse overextends the joint. Their elastic properties “carry” the joint in a yielding, anticoncussive manner that is best observed in slow-motion films of a horse at speed.

The **suspensory apparatus** consists again of three parts: interosseus, proximal sesamoid bones, and sesamoidean ligaments. The interosseus arises from the carpus and proximal end of the large metacarpal bone and ends on the two sesamoid bones. (Before doing so it sends extensor branches around the proximal phalanx to the common extensor tendon.) The proximal sesamoid bones articulate with the distal end of the large metacarpal bone to reduce friction between the suspensory apparatus and the palmar surface of the fetlock joint. Collateral ligaments tie the sesamoid bones to the cannon bone and proximal phalanx, while a thick palmar ligament unites the sesamoid bones and forms a smooth bearing surface for the digital flexor tendons. The tension in the interosseus is continued distal to the joint by four sesamoidean ligaments (short, cruciate, oblique, and straight) of which the first three end on the proximal, and the last on the middle phalanx.

The **supf. digital flexor tendon** assists the suspensory apparatus by providing a tendinous support extending (via its accessory [check] ligament) from the radius above the fetlock joint to the proximal and middle phalanges below the joint.

The **deep flexor tendon** and its accessory (check) ligament provide added and similar support; the accessory ligament arises with the interosseus from the caudal aspect of carpus, the tendon itself ends on the distal phalanx.

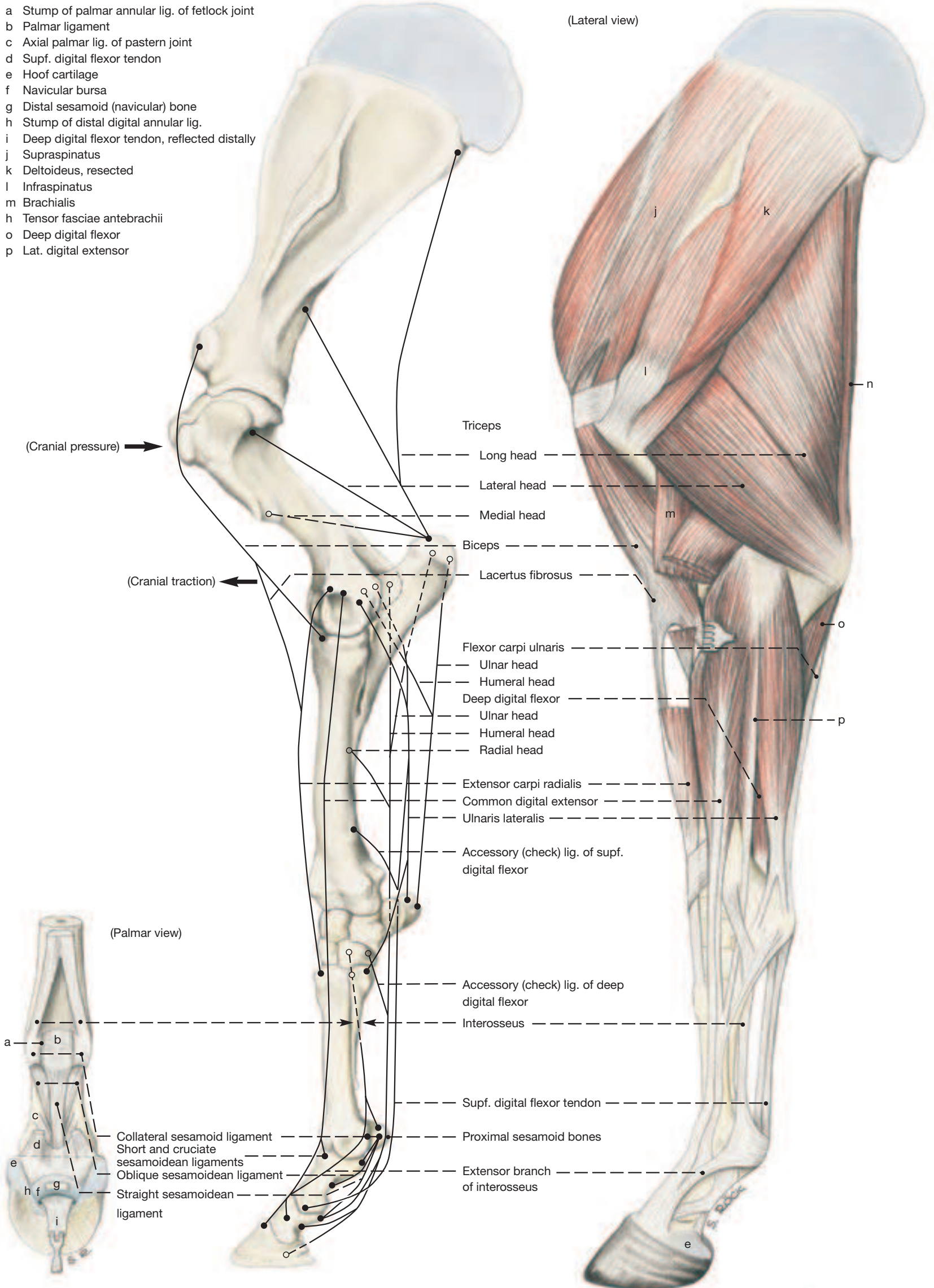
6. The **pastern joint** is prevented from overextension by four pastern ligament that connect the two bones that form the joint on the palmar surface. The straight sesamoidean ligament of the suspensory apparatus and the supf. and deep flexor tendons give additional support.

The proximopalmar border of the middle phalanx carries a complementary fibrocartilage into which the supf. flexor tendon and the ligaments reaching the bone from above insert. The cartilage and part of the bone form the second bearing surface over which the deep flexor tendon changes direction.

7. The **coffin joint** actually flexes when the fetlock sinks under weight and can be disregarded in the consideration of the stay-apparatus. On its palmar surface lies the distal (navicular) sesamoid bone suspended by proximal (collateral) and distal ligaments. It provides the third bearing surface for the deep flexor tendon which here is protected from wear by the navicular bursa.

Musculature of the Thoracic Limb

- a Stump of palmar annular lig. of fetlock joint
- b Palmar ligament
- c Axial palmar lig. of pastern joint
- d Supf. digital flexor tendon
- e Hoof cartilage
- f Navicular bursa
- g Distal sesamoid (navicular) bone
- h Stump of distal digital annular lig.
- i Deep digital flexor tendon, reflected distally
- j Supraspinatus
- k Deltoideus, resected
- l Infraspinatus
- m Brachialis
- n Tensor fasciae antebrachii
- o Deep digital flexor
- p Lat. digital extensor



1 a) JOINTS OF THE THORACIC LIMB

Name/Fig.	Bones involved	Type of joint	Function	Remarks
2 I. Shoulder Joint / 1–3	Glenoid cavity of scapula and head of humerus	Simple spheroidal joint	Restricted to flexion and extension by tendinous components of subscapularis and supra- and infra-spinatus muscles	Site of injection Cranial border of palpable infra-spinatus tendon, 2 cm proximal to greater tubercle, to a depth of about 5 cm
3 II. Elbow Joint / 4–6		Composite joint		
a) Humeroulnar articulation	a) Condyle of humerus and ulna	a) Simple hinge joint	a–b) Flexion and extension	Initial flexion of the joint is impeded by eccentrically placed collateral ligaments. The long part of the medial collateral ligament corresponds to the pronator teres of other animals
b) Humeroulnar articulation	b) Condyle of humerus and head of radius	b) Simple hinge joint		
c) Proximal radioulnar articulation	c) Articular circumference of radius and radial notch of ulna	c) Simple pivot joint	c) No movement	
III. Distal radioulnar joint (absent)				
CARPAL AND DIGITAL JOINTS				
4 IV. Carpal joint / 7, 8		Composite joint (in the wider sense)		
a) Radiocarpal joint	Trochlea of radius and carpal bones	Composite condylar joint	a) Flexion and extension up to 90°	a) Site of injection: Between lateral digital extensor and ulnaris lateralis into the proximal pouch when the carpus is flexed a–d) The fibrous layer of the joint capsule is common to all articulations in the carpus. The synovial layer is divided to enclose the three individual articulations separately. The midcarpal capsule communicates with that of the carpometacarpal articulation.
b) Midcarpal joint	Proximal and distal rows of carpal bones	Composite condylar joint	b) Flexion and extension up to 45°	
c) Carpometacarpal joint	Carpal bones II–IV and metacarpal bones II–IV	Composite plane joint	c) Little movement	
d) Intercarpal joints	Carpal bones of the same row	Composite plane joint	d) Little movement	
5 V. Fetlock (metacarpophalangeal) joint / 9, 10	Metacarpal 3, prox. phalanx, and prox. sesamoid bones	Composite hinge joint	Flexion and extension	Site of injection: Into the prox. palmar pouch between large metacarpal bone and interosseus
6 VI. Pastern (prox. interphalangeal) joint / 9, 10	Proximal and middle phalanx	Simple saddle joint	Flexion and extension, also slight side-to-side and rotational movements	Site of injection: Into the prox. dorsal pouch under the lateral border of the common extensor tendon
7 VII. Coffin (dist. interphalangeal) joint / 10	Middle phalanx, distal phalanx, with hoof cartilage, and navicular bone	Composite saddle joint	Flexion and extension, also slight side-to-side and rotational movements	Site of injection: Into the prox. dorsal pouch under the lateral border of the common extensor tendon

The three **digital joints** are the fetlock, pastern, and coffin joints. The proximal sesamoid bones and their ligaments are part of the fetlock joint, and the navicular bone and its ligaments are part of the coffin joint (page 12 and 13, and the Figure on page 4, respectively). The sesamoids receive part of the body weight when the limb is bearing weight. The capsules of the three digital joints present dorsal and palmar pouches which extend proximally; some of them are the sites for puncturing the joints.

b) IMPORTANT SYNOVIAL BURSAE

The **infraspinatus bursa** (1) lies between the tendon of the infraspinatus and the caudal part of the greater tubercle of the humerus.

8 The **intertubercular bursa** (4) underlies the biceps tendon between the greater and lesser tubercles of the humerus. It corresponds to the recess (of the shoulder joint capsule) that surrounds the biceps tendon in most other domestic mammals. Its inflammation can produce shoulder lameness.

9 The **subcutaneous olecranon bursa** (4) over the olecranon tuber is inconstant. Its hygromatous enlargement is known as capped elbow.

10 A **subcutaneous (precarpal) bursa** (7) on the dorsal surface of the carpus can develop after repeated injury in small box or trailer stalls.

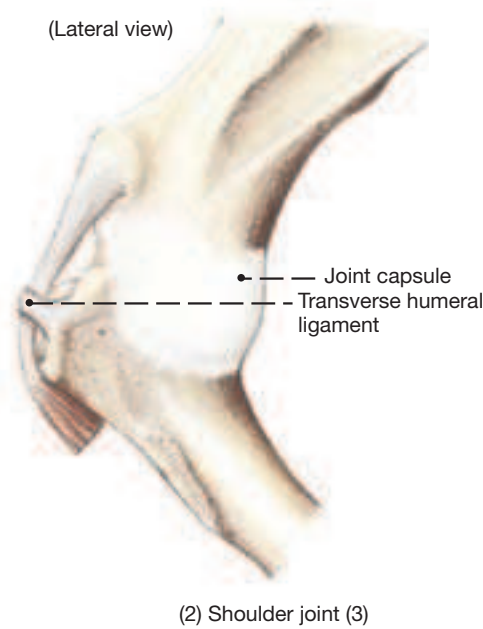
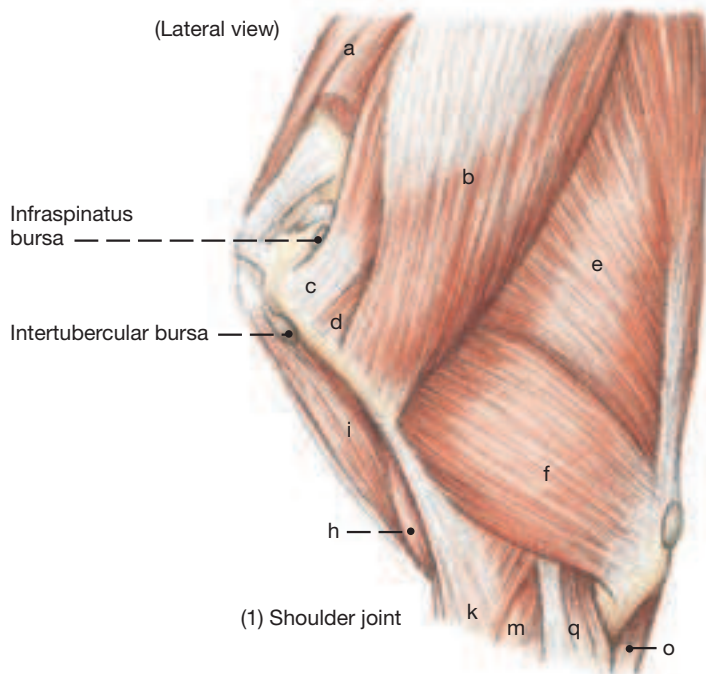
The subtendinous bursa of the common and lateral digital extensors (9) lies between the cannon bone and the tendons of these muscles.

The **navicular bursa** (10) provides frictionless movement of the deep flexor tendon over the navicular bone.

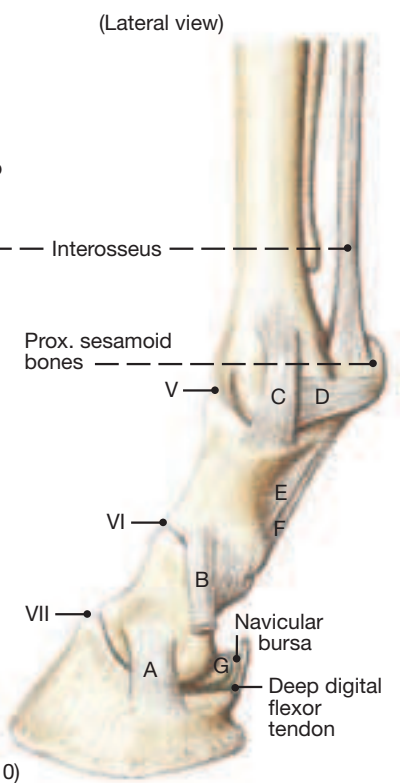
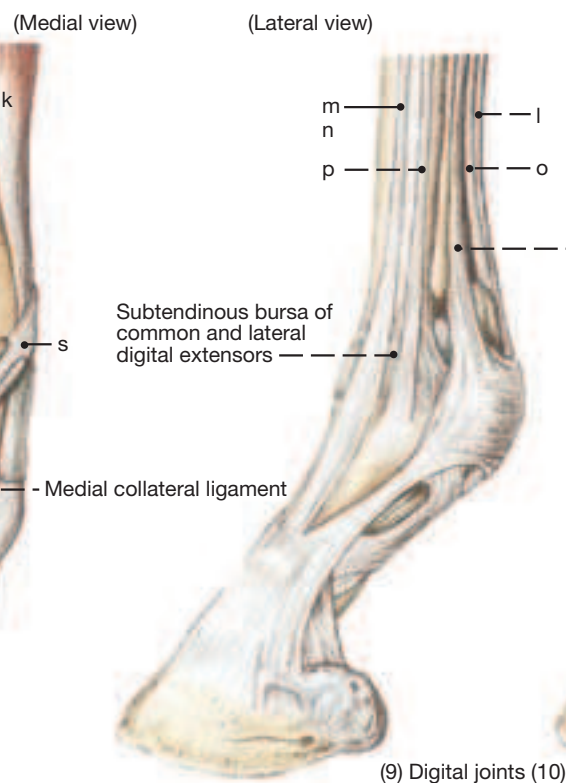
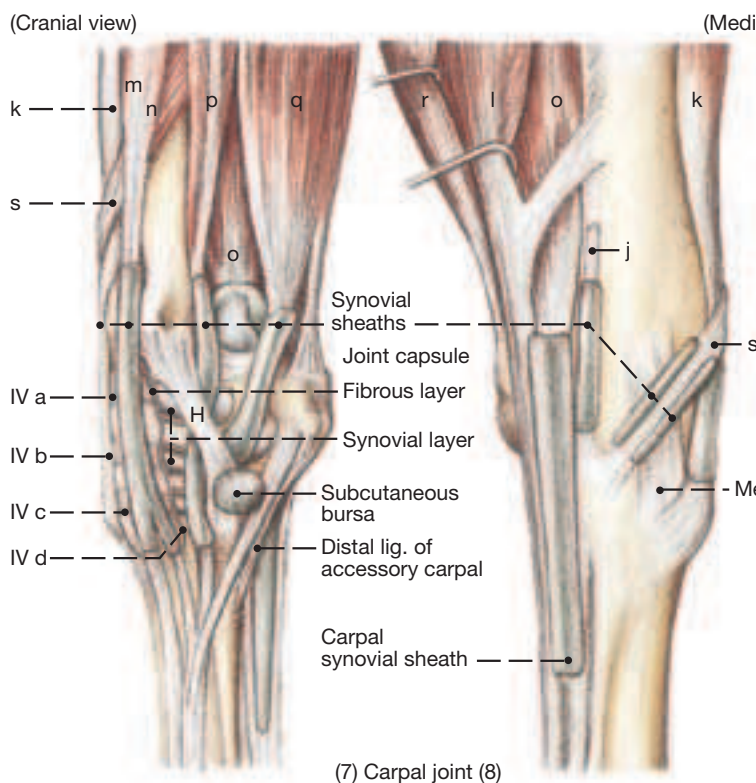
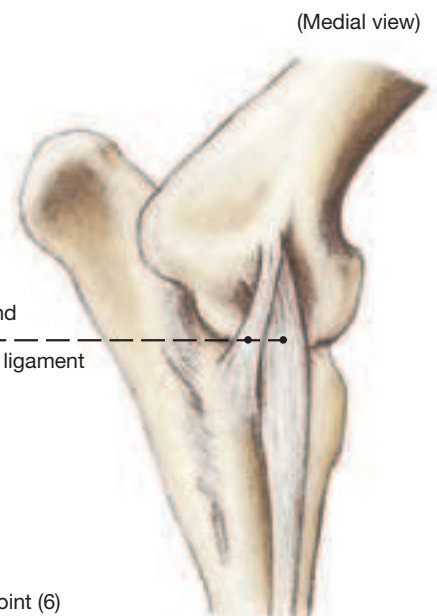
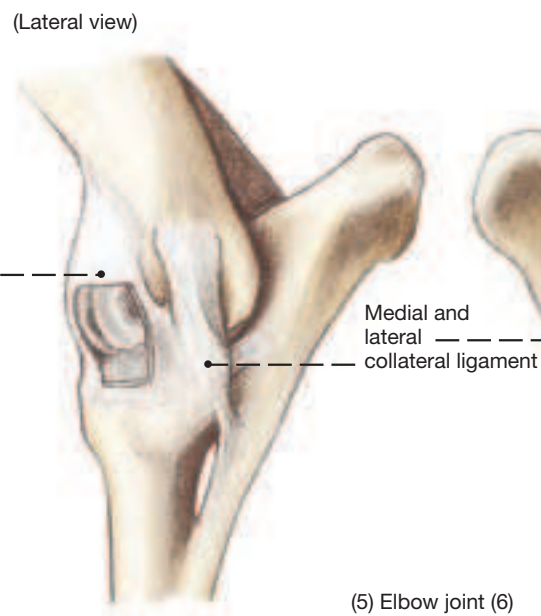
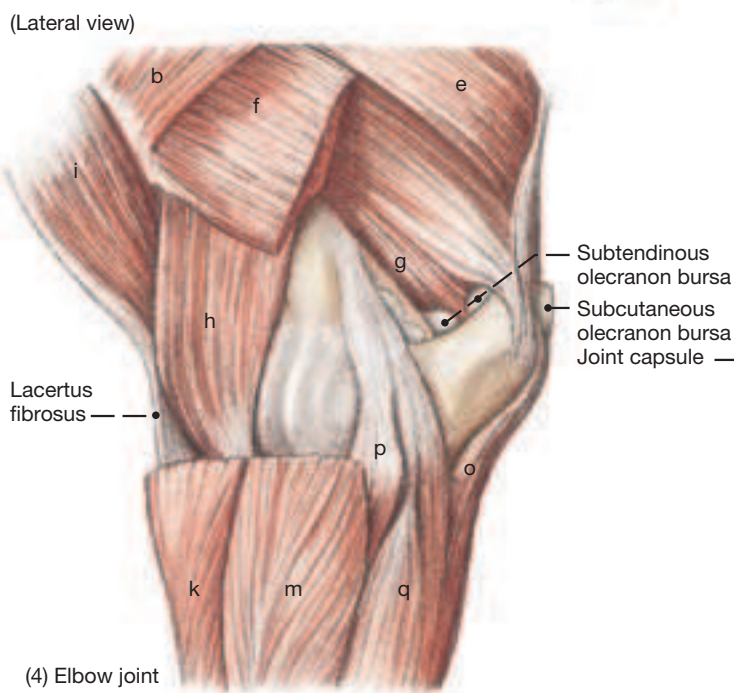
c) TENDON SHEATHS

Synovial tendon sheaths are thin walled, but double-layered, fluid-filled tubes surrounding stretches of tendons; they protect the tendons where they are exposed to wear. Synovial sheaths surround the **tendons passing over the carpus** (7), except for the short tendon of the ulnaris lateralis and that of the flexor carpi ulnaris. One of these is known as the **carpal sheath** (8); it serves both supf. and deep flexor tendons as they pass the carpus in the carpal canal. A similar sheath for both these tendons is the digital sheath which extends from above the fetlock joint to the middle of the middle phalanx. In both sheaths, the deep flexor tendon is wholly, but the supf. flexor is only partly surrounded. Only at the proximal extremity of the digital sheath is the supf. flexor tendon nearly completely enclosed. Except for the nine outpouchings illustrated on page 10, the palmar surface of the digital sheath is covered by the annular ligament of the fetlock joint and by the proximal and distal digital annular ligaments.

Joints, Bursae, and Synovial Sheaths



- a Supraspinatus
- b Deltoideus, resected
- c Infraspinatus
- d Teres minor
- Triceps brachii:
- e Long head
- f Lateral head, resected
- g Medial head
- h Brachialis
- i Biceps brachii
- j Flexor carpi radialis, resected
- k Extensor carpi radialis
- l Supf. digital flexor
- m Common digital extensor (humeral head)
- n Common digital extensor (radial head)
- o Deep digital flexor
- p Lat. digital flexor
- q Ulnaris lateralis
- r Flexor carpi ulnaris, resected
- s Extensor carpi obliquus

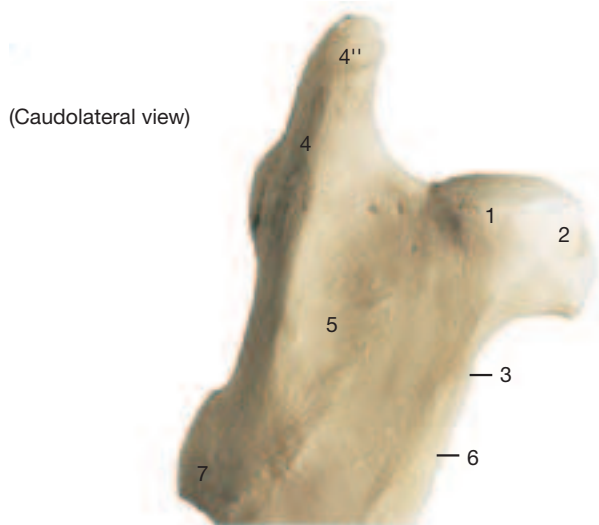


- A Lateral collateral lig. of coffin joint
- B Collateral lig. of navicular bone
- C Lateral collateral lig. of fetlock joint
- D Lateral collateral lig. of prox. sesamoid bones
- E Oblique sesamoidean ligament
- F Straight sesamoidean ligament
- G Navicular bone
- H Lateral collateral lig. of carpal joint

1. The Skeleton of the Pelvic Limb

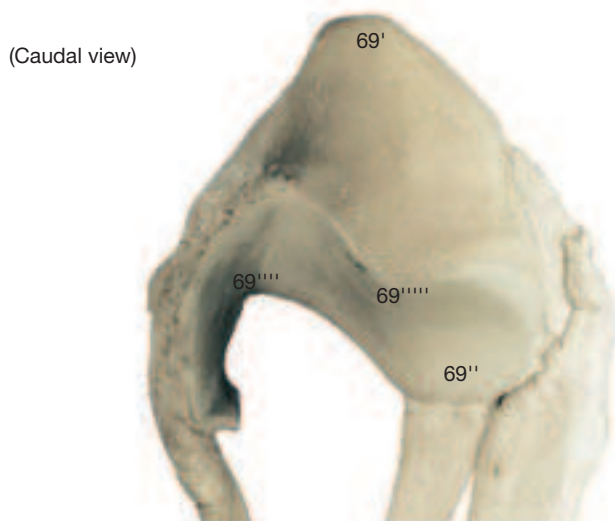
The skeleton of the pelvic limb actually includes the bones of the pelvic girdle: ilium, pubis, and ischium, known together as the hip bone (os coxae). For didactic and applied-clinical reasons the hip bone, in fact the entire bony pelvis, is considered with the pelvic organs.

a) The **FEMUR** presents on its **head** (1) a relatively large, triangular **fovea** (2). The apex of the fovea lies near the center of the femoral head and its base is close to the medial border of the femoral head. The fovea, devoid of articular cartilage, gives attachment in the vicinity of its apex to the ligament of the head of the femur and, closer to its base, to the accessory ligament that arises from the prepubic tendon with most of its fibers originating from the insertion tendon of the rectus abdominis. The **neck of the femur** (3) is no real constriction in the horse; it is continuous laterally with the **greater**



trochanter (4) which is divided into a **cranial** (4') and a more salient **caudal** (4'') part. The caudal part extends considerably above the head of the femur, but more ventrally contributes also to the lateral border of the **trochanteric fossa** (5). The medial border of the fossa is formed by the **lesser trochanter** (6). The prominent **third trochanter** (7) projects from the lateral border of the femur at the junction of its proximal and middle thirds. The **supracondylar fossa** (13) is on the caudal surface of the bone at the junction of middle and distal thirds where it provides origin for the supf. digital flexor. From the fossa's raised lateral edge, known as the lateral supracondylar tuberosity, arises the lateral head of the gastrocnemius. The **medial** (14) and **lateral** (17) **condyles** at the distal end of the femur are separated by a roomy **intercondylar fossa** (20). Both condyles extend cranially to the **trochlea** (21) whose **medial ridge** (21') is markedly larger than the lateral ridge and drawn out proximally to provide a tubercle which plays a critical role in the locking mechanism of the stifle joint (see p. 24). The trochlea presents an extensive gliding surface for articulation with the **patella** (69).

The latter, roughly triangular, presents a **base** (69') proximally and an **apex** (69'') distally. The medial border is drawn out by the **patellar fibrocartilage** (69'''). The **articular surface of the patella** (69''''') is divided by a sagittal ridge that occupies the groove between the two ridges of the trochlea. Both patellar and trochlear articular sur-

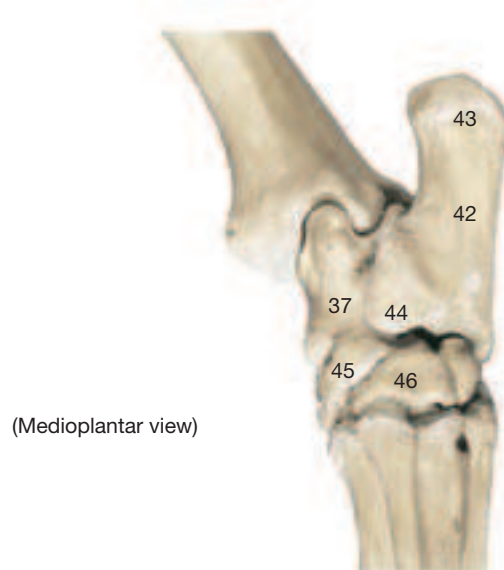


face are further divided by less distinct transverse ridges into large gliding and small resting surfaces; the resting surface of the trochlea is proximal to the gliding surface, that of the patella is distal to it. When both resting surfaces are in contact, the patella “rests” on the proximal end of the trochlea as is the case when the standing horse is bearing weight equally on both hindlimbs.

b) **BONES OF THE LEG.** Of these the fibula is rudimentary, so the weight on the limb is carried by the tibia alone.

I. The **proximal articular surface** (22) of the **tibia** is roughly triangular; from its center arises the prominent **intercondylar eminence** (24). The apex of the triangle is formed by the **tibial tuberosity** (29) which receives the three patellar ligaments that constitute the insertion tendon of the quadriceps. The craniolateral border of the triangle is interrupted by the deep **extensor groove** (27), while the base of the triangle (which faces caudally) is divided by the popliteal notch that leads to the prominent **popliteal line** (27') on the caudal surface of the bone. The popliteal line runs obliquely from proximalateral to distomedial and gives attachment to the popliteus muscle. Only the craniomedial surface of the tibia is subcutaneous; the remaining surfaces are covered by muscle. The distal end of the bone forms the **cochlea** (30). This consists of two oblique grooves separated by a ridge and bounded on each side by the medial and lateral malleoli.

II. The **fibula** articulates with its expanded **head** (32) with the **lateral condyle of the tibia** (25). The slender body of the bone ends about half-way down the tibia. The distal end of the fibula is represented by the **lateral malleolus** (35) that has been incorporated in the tibia.



c) The **TARSAL BONES** are arranged in three rows.

Talus (37) and **calcaneus** (42) furnish the proximal row. The robust **trochlea** (39) of the talus consists of two oblique ridges that articulate with the cochlea of the tibia. The **calcaneus** (42) is slightly expanded proximally (**calcanean tuber**; 43), presents in its middle portion the prominent **sustentaculum tali** (44) for the principal deep flexor tendon, and articulates distally with the fourth tarsal bone. The middle row of tarsal bones is provided by the **central tarsal** (45). The distal row comprises **tarsal bones 1–4** (46) of which the first and second are fused, the third rests on the large metatarsal bone, and the fourth is lateral and projects proximally into the level of the middle row.

d) The **METATARSAL BONES, PHALANXES AND SESAMOID BONES** are similar to corresponding bones in the forelimb (see p. 4). Mt3 has a round cross section, while that of Mc3 is a lateromedially oriented oval.

Pelvic Limb

Femur

- Head (1)
 - Fovea of femoral head (2)
- Neck (3)
- Greater trochanter (4)
 - Cranial part (4')
 - Caudal part (4'')
- Trochanteric fossa (5)
- Lesser trochanter (6)
- Third trochanter (7)
- Body of femur (8)
 - Rough surface (9)
 - Lat. border of rough surface (10)
 - Med. border of rough surface (11)
 - Popliteal surface (12)
 - Lat. supracondylar tuberosity (fossa) (13)
- Medial condyle (14)
 - Medial epicondyle (16)
- Lateral condyle (17)
 - Lateral epicondyle (19)
- Intercondylar fossa (20)
- Trochlea (21)
 - Tubercle of med. trochlear ridge (21')

Tibia

- Proximal articular surface (22)
- Medial condyle (23)
- Intercondylar eminence (24)
- Lateral condyle (25)
 - Articular surface for fibula (26)
- Extensor groove (27)
 - Popliteal line (27')
- Body of tibia (28)
 - Subcutaneous surface (28')
- Tibial tuberosity (29)
- Cranial border (29')
- Cochlea (30)
- Medial malleolus (31)

Fibula

- Head (32)
- Articular surface (33)
- Body of fibula (34)
- Lateral malleolus (35)
- Interosseous space (36)

Tarsal bones

- Talus (37)
 - Body of talus (38)
 - Trochlea (39)
 - Head (41)
- Calcaneus (42)
 - Calcanean tuber (43)
 - Sustentaculum tali (44)
- Central tarsal bone (Tc - 45)
- Tarsal bone 1+2, 3, 4 (46)

Metatarsal bones II-IV

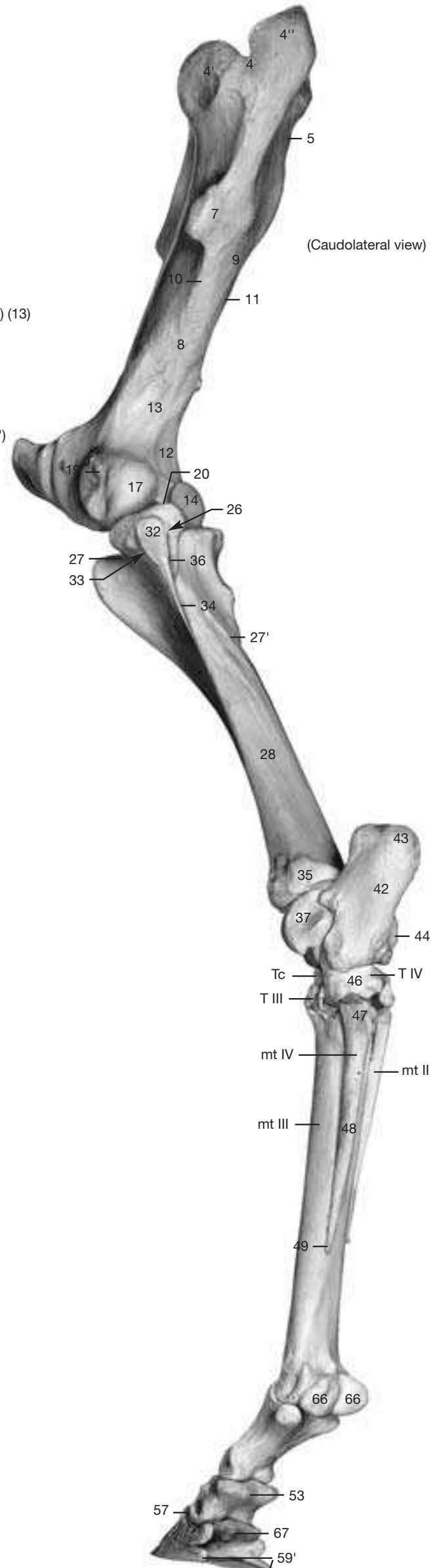
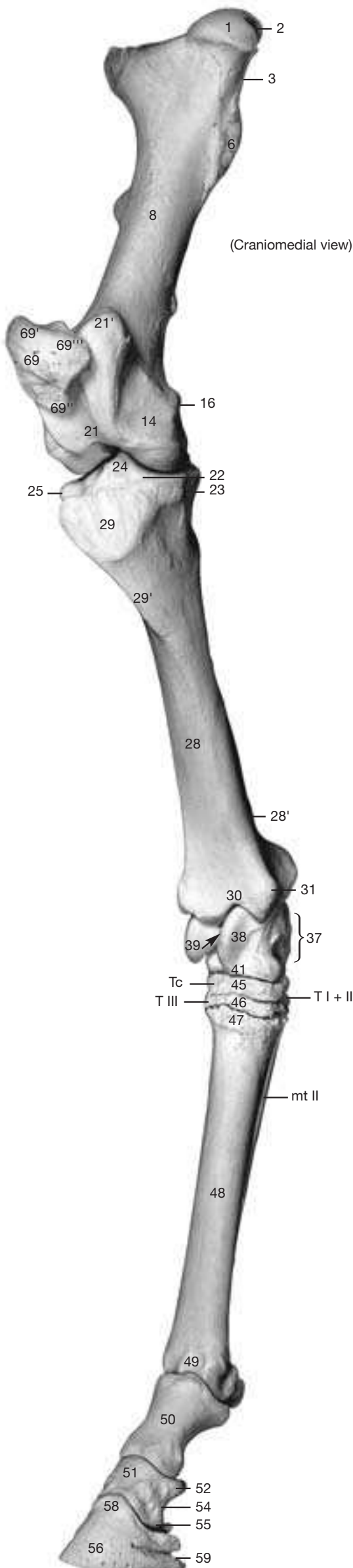
- Base (47)
- Body (48)
- Head (49)

Digital bones

- Proximal phalanx (50)
- Middle phalanx (51)
 - Base (52)
 - Flexor tuberosity (53)
 - Body (54)
 - Head (55)
- Distal phalanx (56)
 - Articular surface (57)
 - Extensor process (58)
 - Parietal groove (59)
 - Plantar process (59')

Sesamoid bones

- Proximal sesamoid bones (66)
- Distal (navicular) sesamoid bone (67)
- Patella (69)
 - Base (69')
 - Apex (69'')
 - Cartilage process (69''')
 - Patellar fibrocartilage (69''''')
 - Articular surface (69''''')



The two Figures on the opposite page show the structures mentioned in the account below to best advantage. The following steps would reproduce the dissection upon which the two Figures were based.

The limb is skinned to midmetatarsus, preserving the subcutaneous veins and the larger nerves (see p. 21). Dorsolaterally on the croup, the large **gluteus medius** (3) is transected at the level of the coxal tuber, and again where it inserts on the greater trochanter, so that the muscle between these cuts can be removed. The **gluteus accessorius** (9), deep to it and covered by a glistening aponeurosis, remains in place. At the latter's caudal border, the **gluteus profundus** (6) comes into view. The **gluteus superficialis** (11) and **tensor fasciae latae** (20) are detached at their origin (coxal tuber) and termination. Most of the **biceps femoris** (22) is removed, leaving in place its vertebral and pelvic origins, and its termination on the crural fascia, and its tarsal tendon. The lateral head of the **gastrocnemius** (26) is detached from the femur to expose the **supf. digital flexor** (31). The **gracilis** (21), on the medial surface is fenestrated.

- 1 a) **MEDIAL SIDE OF THE THIGH.** The obturator and femoral nerves innervate the muscles in this region.

The **obturator nerve** (5) courses along the medial surface to the shaft of the ilium, exits from the pelvic cavity through the obturator foramen, and sends branches to the muscles described below.

The **external obturator** muscle arises from the ventral surface of the pelvic floor in the vicinity of the obturator foramen and ends together with the gemelli, quadratus femoris, and the internal obturator in the trochanteric fossa. The **pectineus (and long adductor; 14)** takes origin from the contralateral iliopectic eminence so that its tendon of origin crosses the median plane. The tendon of origin, and that of the pectineus of the other side, thus form the bulk of the prepubic tendon. The spindle-shaped belly of the pectineus ends at the middle of the medial border of the femur. The **adductor (magnus et brevis; 19)** is a large fleshy muscle; it arises from pelvic symphysis and symphyseal tendon. It ends on the caudal surface and the medial epicondyle of the femur. The **gracilis** (21) originates from the pelvic symphysis and the symphyseal tendon. It ends largely on the crural fascia.

The **femoral nerve** (12) leaves the abdominal cavity together with the sartorius muscle, gives off the **saphenous nerve** (25) (see further on) and innervates the sartorius, the quadriceps, and (with a sensory branch) also the stifle joint.

The **sartorius** (10) arises from the iliac fascia covering the iliopsoas, exits from the abdominal cavity by passing caudal to the inguinal ligament, and ends on the medial aspect of the stifle.

The rectus femoris of the **quadriceps** (15) takes origin from the body of the ilium, while vastus lateralis, intermedius, and medialis come from the upper end of the femur. The insertion tendon partially encloses the patella and terminates via the intermediate **patellar ligament** (15) on the tibial tuberosity.

The **femoral triangle** (16) is bounded cranially by the sartorius and caudally by the gracilis and pectineus; its medial wall is the external abdominal oblique aponeurosis. The apex of the triangle points ventrally; the vascular lacuna forms the (dorsal) base. The triangle contains the **femoral vessels** (18), the saphenous nerve, and the **deep inguinal lymph nodes** (B).

- b) **LATERAL SIDE OF THE THIGH AND CROUP.** The innervation of the muscles in this region comes from the cranial and caudal gluteal, the sciatic, and the tibial nerves.

- 2 The **cranial gluteal nerve** (8) supplies the **tensor fasciae latae** (20) and the glutei: **gluteus profundus** (6), **accessorius** (9), **medius** (3), and **superficialis** (11). These muscles arise variously from the coxal tuber, the gluteal surface of the ilium, and from the gluteal fascia. The gluteus accessorius is considered to be a deep part of the gluteus medius. The gluteus superficialis is partly fused with the tensor fasciae latae; both arise from the coxal tuber but also from the gluteal fascia.

The **caudal gluteal nerve** (2) supplies the vertebral heads of biceps, semitendinosus, and semimembranosus (the hamstring muscles).

Their ischial heads are served by the tibial nerve.

The **sciatic nerve** (4) leaves the pelvic cavity by the greater sciatic foramen and passes, medial to the greater trochanter, around the caudal aspect of the hip joint. Here it releases branches to the group of insignificant hip rotators (gemelli, int. obturator, quadratus femoris, and the ext. obturator which, however, is innervated by the obturator nerve). It is possible, already at the level of the hip joint, to separate the sciatic nerve into tibial and common peroneal nerves.

The **tibial nerve** (13) sends proximal muscular branches to the ischial heads of the hamstring muscles and in mid-thigh gives off the **caudal cutaneous sural nerve** (30), which accompanies the lateral saphenous vein along the common calcanean tendon and ends on the lateral surface of the tarsus. The hamstring muscles arise with their ischial heads from the ischial tuber. The **biceps** (22) ends laterally on patella, lateral patellar ligament, crural fascia, and with its tarsal tendon on the calcanean tuber. The other two hamstrings end on the medial aspect of the limb: the **semitendinosus** (1) on the tibia and with its tarsal tendon also on the calcanean tuber, the **semimembranosus** (23) with two insertion tendons on the medial condyle of femur and tibia.

c) **LEG (Crus).** Opposite the stifle the tibial nerve gives off distal muscular branches to the extensors of the hock and flexors of the digit described in the next paragraph. The nerve then descends between the two heads of the gastrocnemius and along the medial surface of the common calcanean tendon to give rise, before reaching the hock, to the **lateral** (35) and **medial** (38) **plantar nerves**.

The **gastrocnemius** (26) arises from the supracondylar tuberosities on the caudal surface of the femur and ends as part of the common calcanean tendon on the calcanean tuber. The insignificant **soleus** (28) extends obliquely from the head of the fibula to the common calcanean tendon; it forms, together with the two heads of the gastrocnemius, the m. triceps surae. The nearly tendinous **supf. digital flexor** (31) takes origin from the (lateral) supracondylar fossa. Its tendon winds around that of the gastrocnemius and widens to form a cap over the calcanean tuber to the sides of which it is attached. The cap is easily demonstrated by cutting one of the attachments. This opens the large subtendinous calcanean bursa. (The distal course of the tendon is similar to that of the same muscle in the forelimb; see p. 12.) The deep digital flexor comprises three muscles: medial and lateral digital flexors and the tibialis caudalis. The tendon of the **medial digital flexor** (29) passes the medial surface of the hock to join the combined tendon of the other two muscles below the hock. The combined tendon of the **lateral digital flexor** (34) and **tibialis caudalis** (33) pass the hock caudally by passing over the sustentaculum tali. The **popliteus** (27) lies deep to the preceding muscles on the caudal surface of the tibia; it arises from the lateral femoral condyle and is also supplied by the tibial nerve.

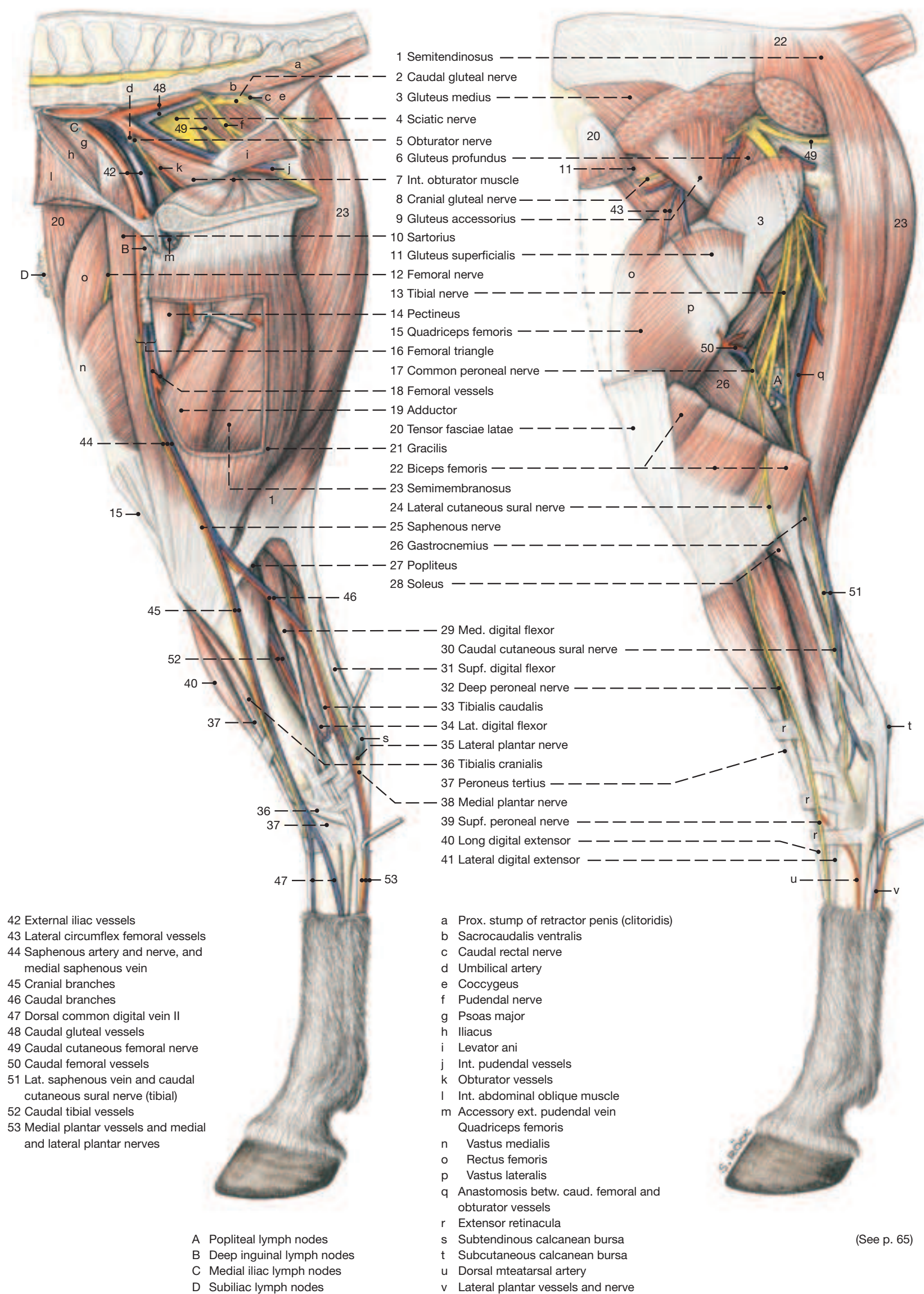
The **common peroneal nerve** (17) crosses the lateral head of the gastrocnemius where it releases the **lateral cutaneous sural nerve** (24). The latter emerges distally between middle and caudal divisions of the biceps. Distal to the stifle, the common peroneal nerve splits into **supf.** (39) and **deep** (32) **peroneal nerves** which innervate the flexors of the hock and the extensors of the digit described in the next paragraph. The two nerves then descend between the lateral and long digital extensors to the dorsal and lateral surfaces of the metatarsus (see p. 21).

The entirely tendinous **peroneus tertius** (37) divides on the dorsal surface of the hock joint into four terminal branches at the origin of which it also forms a ring-like tunnel for the passage of the tibialis cranialis. It terminates with wide medial and dorsal branches on Mt3, Tc, and T3, and with supf. and deep lateral branches on the calcaneus and T4 (see p. 31). The tendon of the **tibialis cranialis** (36), after emerging from the peroneus tunnel, splits to insert with a dorsal branch on Mt3 and a medial branch (cunean tendon) on T1 and 2. The **long digital extensor** (40), guided by the three extensor retinacula, passes the hock dorsally and ends on the distal phalanx with secondary attachments also on the other phalanges. The **lateral digital extensor** (41) ends by joining the tendon of the long extensor below the hock. (The insignificant m. extensor brevis needs no further mention.)

Pelvic Limb

(Medial view)

(Lateral view)



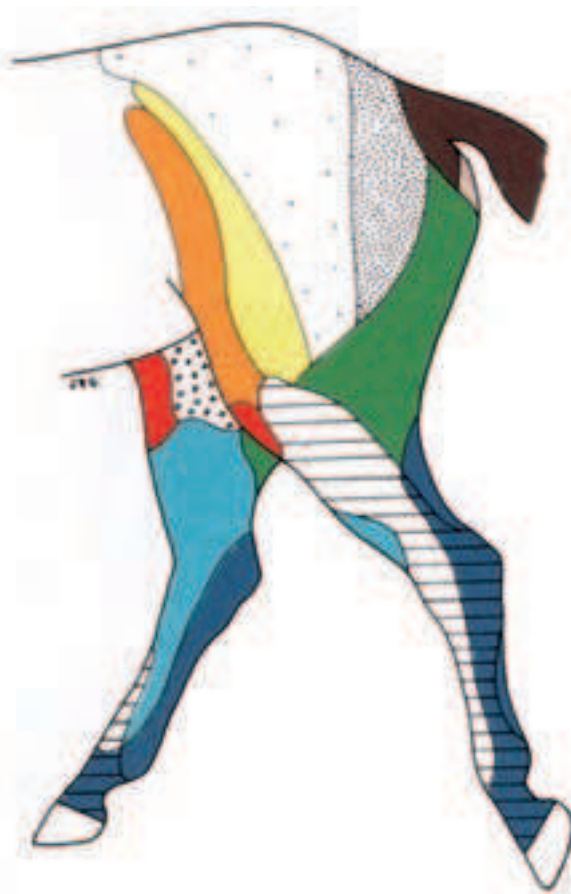a) SKIN INNERVATION

The skin over the dorsal and lateral regions of the croup is innervated by cranial, middle, and caudal clunial nerves that arise from the lumbar, sacral, and caudal spinal nerves, respectively; one of them is recognized as the **caudal cutaneous femoral nerve** (17). The craniolateral surface of the thigh receives cutaneous innervation from the ventral branches of the **first (L1; 2) and second (L2; 3) lumbar nerves**. The craniomedial surface is supplied by the **lateral cutaneous femoral nerve** (6), the medial surface by the **genito-femoral nerve** (5), and the caudal surface by the **caudal cutaneous femoral nerve** (17).

The skin of the leg (crus) is supplied medially by the **saphenous nerve** (9); craniolaterally by the common peroneal nerve, especially the **lateral cutaneous sural nerve** (21); and caudomedially by the tibial nerve, especially its **caudal cutaneous sural nerve** (23).

The medial surface of metatarsus and digit receives its skin innervation from the saphenous nerve and farther distally by a mixture of tibial and peroneal nerve branches. The dorsal surface is supplied by the **dorsal metatarsal nerves** (15) which are branches of the deep peroneal nerve, and the plantar surface is supplied by the **medial and lateral plantar nerves** (26) and their continuations, the **medial and lateral digital nerves** (27).

Cutaneous Nerves of the Pelvic Limb



	Cranial clunial nn.		Caudal rectal n
	Middle clunial nn.		Caudal cutaneous femoral n.
	Genitofemoral n.		Lateral cutaneous femoral n.
	Ventral br. of L1		Peroneal n.
	Ventral br. of L2		Saphenous n.
	Caudal nn.		Tibial n.

b) BLOOD VESSELS

Blood supply to, and return from, the pelvic limb flows predominantly through the external iliac vessels, though the internal iliac vessels are also involved.

The **internal iliac vessels** (1) release the **cranial** (18) and **caudal** (16) **gluteal vessels** to the croup and thigh. The cranial gluteal artery gives off the obturator artery, while the satellite obturator vein is a branch of the external iliac vein.

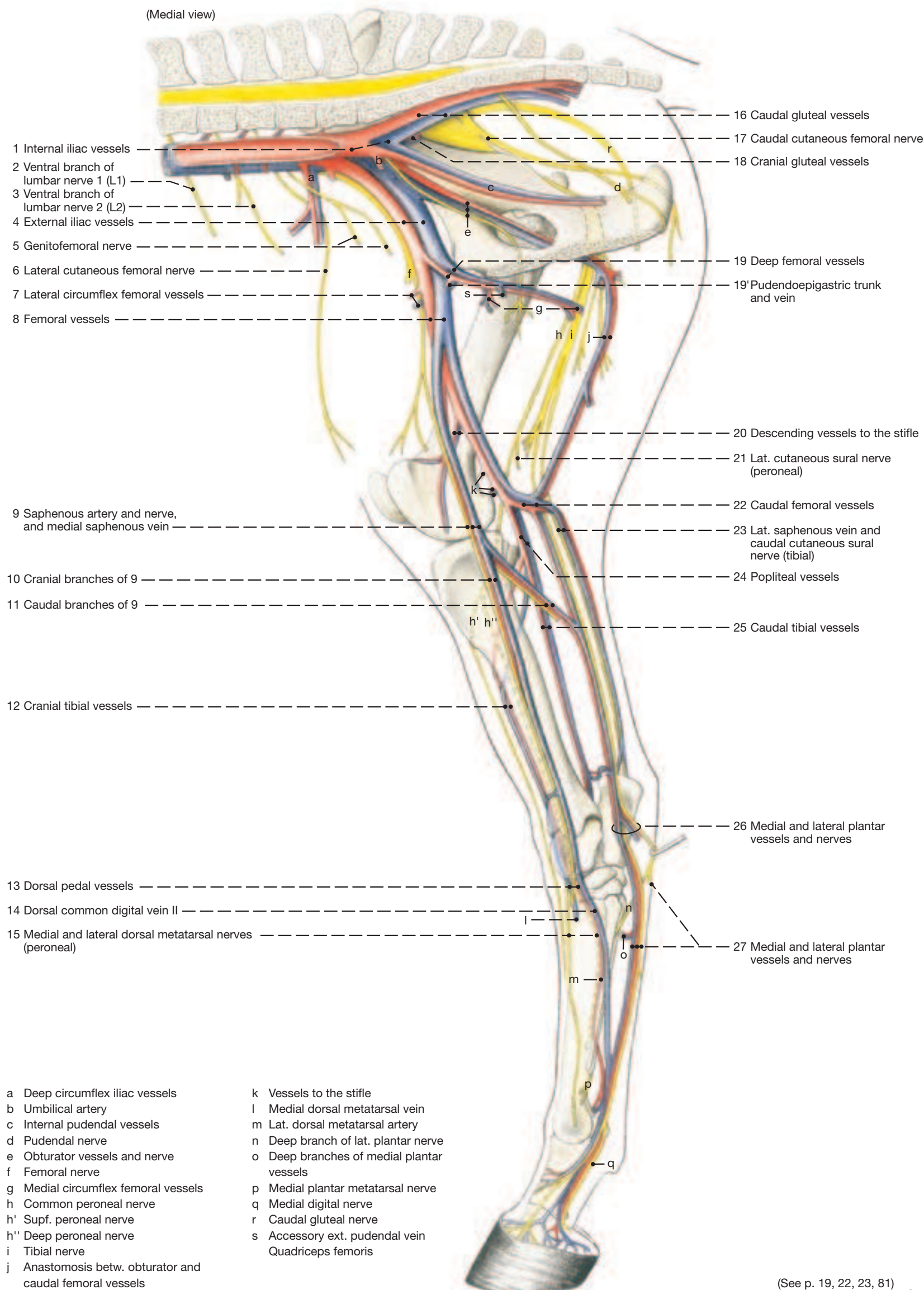
As the **external iliac vessels** (4) enter the thigh by passing caudal to the inguinal ligament, they become the **femoral vessels** (8). These at once give rise to the **deep femoral vessels** (19) which in turn release the **pudendoepigastic trunks** (19'). As the femoral vessels traverse the femoral triangle they give off the **lateral circumflex femoral vessels** (7) that enter the quadriceps between rectus femoris and vastus medialis, and the **saphenous vessels** (9) of which the vein is very much larger than the artery; these accompany the like-named nerve and in the proximal third of the leg divide into **cranial** (10) and **caudal** (11) **branches**. The cranial branch of the vein passes the tarsus dorsomedially to become the **dorsal common digital vein II** (14) in the metatarsus. This crosses the large metatarsal bone obliquely and unites with the medial plantar vein (see p. 22). The caudal branches of the medial saphenous vein and artery pass distally in the groove cranial to the common calcanean tendon. The vein anastomoses proximal to the hock with the **caudal tibial vein** (25) and with the **lateral saphenous vein** (23) and passes the hock plantaromedially where it divides into **medial and lateral plantar veins** (26). The saphenous artery anastomoses with the **caudal tibial artery** (25; see further on) and gives rise to the **medial and lateral plantar arteries** (26).

In the distal third of the thigh the femoral vessels release the **descending artery and vein** of the stifle (20) and other vessels to that joint. Some of the latter arise from the **popliteal vessels** (24; see further on) that continue the femoral vessels at this level. The last branches of the femoral artery and vein are the **caudal femoral vessels** (22). The large caudal femoral vein releases the **lateral saphenous vein** (23) which follows the caudal border of the gastrocnemius distally to anastomose proximal to the hock with the **caudal branch** (11) of the medial saphenous vein and with the **caudal tibial vein** (25; see above). Opposite the head of the fibula, the popliteal vessels bifurcate to give rise to the **cranial** (12) and the smaller **caudal** (25) **tibial vessels**. The caudal tibial vessels descend caudal to the tibia. The cranial tibial vessels, however, pass cranially between tibia and fibula, follow the tibia craniolaterally, and at the hock become the short **dorsal pedal vessels** (14). The continuation of the pedal artery, the **dorsal metatarsal artery**, is the largest artery in the metatarsus. It passes over the lateral surface of the cannon bone, then between this bone and the distal end of the lateral splint bone to the plantar surface where it receives the thin plantar metatarsal arteries that descend on the plantar aspect of the metatarsal bones.

c) LYMPHATIC STRUCTURES

Numerous lymph vessels leave the hoof and, similar to the forelimb (see p. 8), unite proximal to the fetlock joint to form a small number of larger lymphatics. Most of these lie on the medial aspect of the metatarsus between the flexor tendons; they ascend medial to hock and leg until they reach the **popliteal lymph nodes** (see p. 19.A). These lie caudal and proximal to the stifle between biceps and semitendinosus. From here the lymph travels to the **deep inguinal nodes** (see p. 19.B) which occupy the femoral triangle, and finally to the **medial iliac nodes** (see p. 19.C). The deep inguinal nodes receive lymph also from the medial surface of leg and thigh that does not pass through the popliteal nodes. Croup and cranial thigh drain to the **subiliac nodes** (see p. 19.D) which lie on the cranial border of the thigh between coxal tuber and patella. From here the lymph travels first to the lateral and then to the medial iliac nodes. A portion of the lymph from the medial aspect of the thigh passes to the supf. inguinal lymph nodes.

Arteries, Veins, and Nerves of the Pelvic Limb



- 1 a) The **LATERAL AND MEDIAL PLANTAR ARTERIES, VEINS AND NERVES** continue the caudal branches of the saphenous artery and medial saphenous vein, and the tibial nerve, respectively, and as such accompany the deep flexor tendon over the sustentaculum into the metatarsus (see p. 21). The medial vessels and nerve follow the medial border, and the lateral vessels and nerve the lateral border, of the deep flexor tendon to the fetlock joint, whereby vein and nerve usually lie supf. to the corresponding artery (10, 11). In the digit, the medial and lateral digital veins, arteries, and nerves (15, 16) lie next to each other in this (dorsoplantar) sequence (VAN).

As in the forelimb the medial and lateral plantar nerves are connected by the subcutaneous **communicating branch** (12). The branch leaves the medial nerve in midmetatarsus, passes laterodistally over the supf. flexor tendon, and joins the lateral nerve a few cm proximal to the fetlock joint. The communicating branch is palpable in thin-skinned horses, about 5 cm more distally than that of the forelimb. Opposite the fetlock joint, the medial and lateral plantar nerves are succeeded by the medial and lateral digital nerves and detach one or two **dorsal branches** (17) to the dorsal surface of the digit, and opposite the pastern joint a **branch to the digital cushion** (18).

The **medial** (13) and **lateral** (14) plantar metatarsal nerves, as in the forelimb, arise from the deep branch of the lateral plantar nerve and distribute themselves as their counterparts in the forelimb. That is to say, they pass along the axial surfaces of the splint bones, innervate (part of) the fetlock joint and the skin on the dorsal surface of the proximal phalanx. The **medial** (8) and **lateral** (9) **dorsal metatarsal nerves** are terminal branches of the **deep peroneal nerve** (1). The lateral nerve accompanies the dorsal metatarsal artery along the lateral splint bone, while the medial nerve obliquely crosses the medial surface of the cannon bone and descends along the medial surface of the digit. There are no supf. dorsal digital nerves since the **supf. peroneal nerve** (2), from which such nerves would derive, ends already in the metatarsus. Both the **saphenous** (5) and the **caudal cutaneous sural nerve** (6) take part in supplying the skin on the medial and lateral surfaces (respectively) of the metatarsus.

As the medial and lateral plantar vessels enter the metatarsus they give rise to deep plantar arterial and venous arches from which the insignificant medial and lateral plantar metatarsal vessels take origin (see text Fig.). Close to the fetlock joint, the thin medial and lateral plantar metatarsal arteries join the medial and lateral digital arteries that result from the bifurcation of the **dorsal metatarsal artery** (9) which has come around to the plantar aspect of the metatarsus. The dorsal metatarsal artery continues the short **dorsal pedal artery** (4) which in turn extends the **cranial tibial artery** (3) onto the dorsal surface of the hock; cranial tibial, dorsal pedal, and dorsal metatarsal arteries provide the principal blood supply to the digit and hoof.

2 The **dorsal common digital vein II** (7) crosses the medial surface of the cannon bone obliquely in the same direction as the dorsal metatarsal artery does on the lateral surface. In the distal third of the metatarsus the dorsal common digital vein II joins the medial plantar vein shortly before the latter becomes the medial digital vein at the fetlock joint. At this level, the medial plantar vein sends a large anastomosis (distal deep plantar arch) to the lateral plantar vein (see text Fig.).

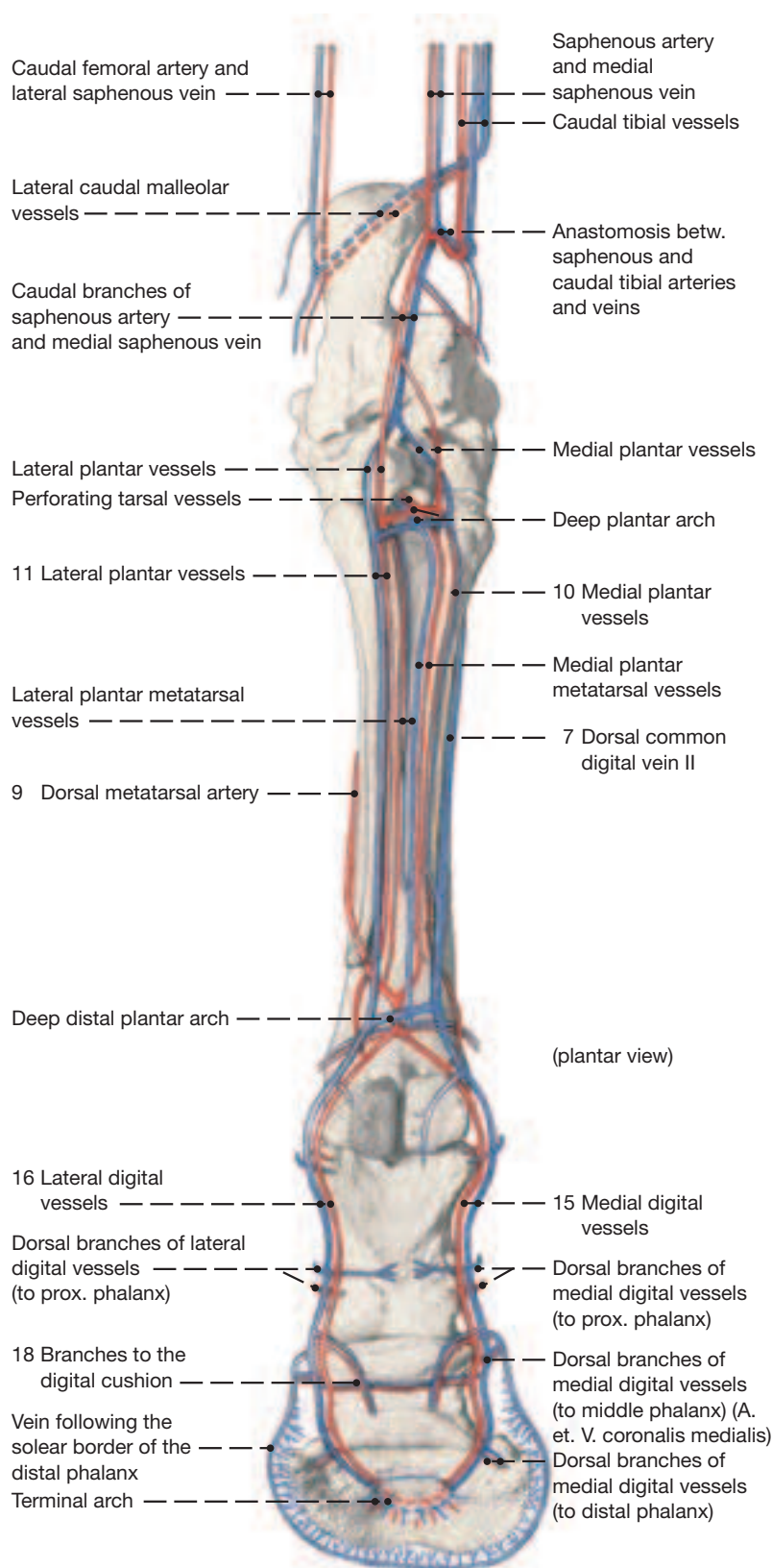
The lateral and medial digital arteries descend on the sides of the digit where they detach dorsal and plantar branches to each of the proximal and middle phalanges. These anastomose on their respective surfaces with their counterparts from the opposite side and in so doing form arterial circles around each bone. At the distal phalanx, the lateral and medial digital arteries send a dorsal branch through the foramen (or notch) in the plantar process and onto the parietal surface of the bone where the branch occupies the parietal groove. The digital arteries continue to the sole surface of the distal phalanx where they enter their respective sole foramen and anastomose within the bone forming the terminal arch. Branches from the latter run in osseous canals to the parietal surface to supply the laminar dermis. Branches that emerge close to the sharp margin (margo solearis) that forms the junction of parietal and sole surfaces of the bone anastomose to form an artery that follows the margin.

While the **digital veins** are satellite to the arteries to and into the distal phalanx, not all arterial branches are accompanied by veins. However, there is a dense venous plexus in the coronary and lami-

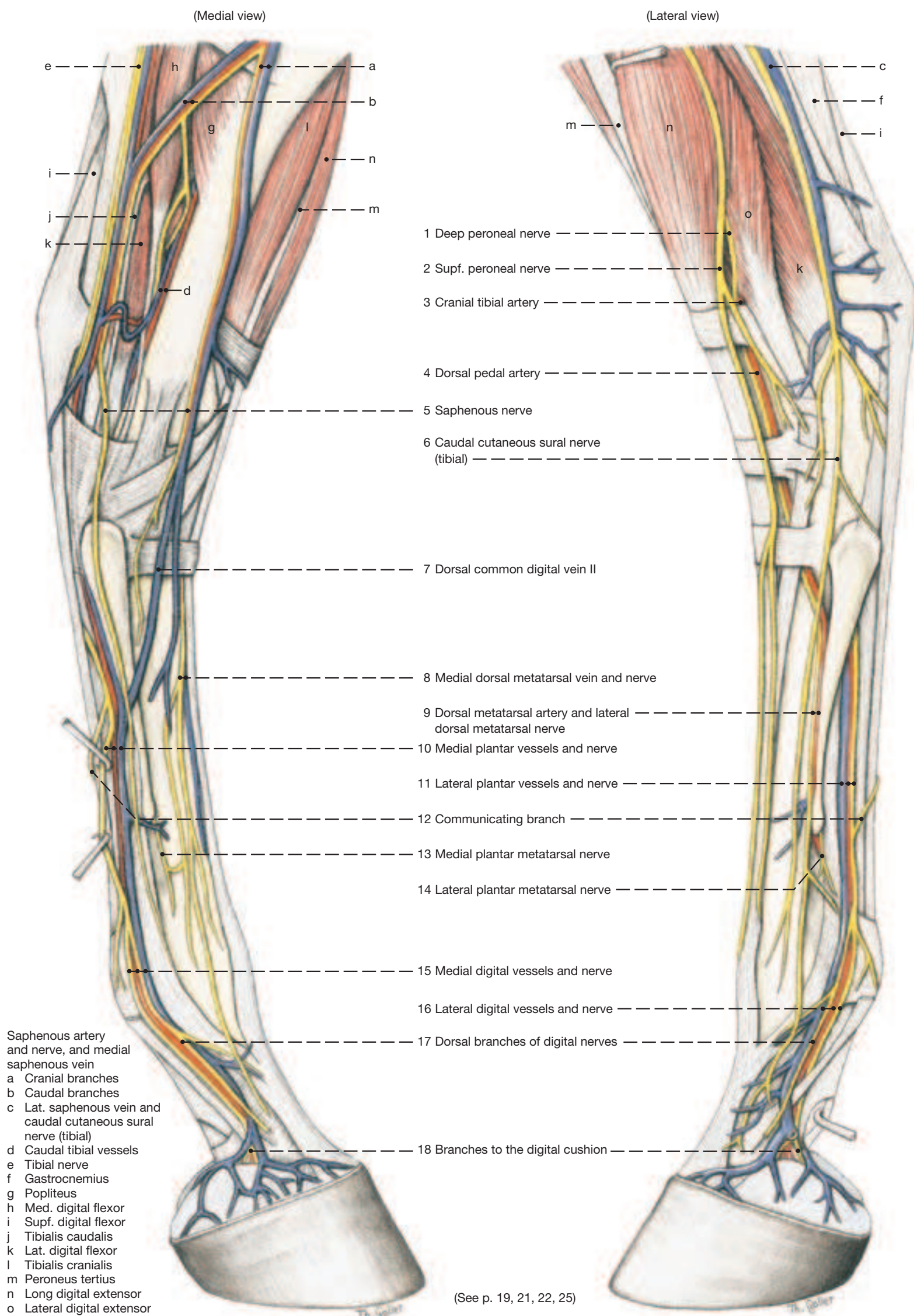
nar dermis and in the dermis of the sole that collects the post-capillary blood. The venous plexus drains into the medial and lateral digital veins via a large number of converging, midsize veins. Most of these lie under the skin just proximal to the hoof, others reach the digital veins directly from the axial surface of the hoof cartilages.

- b) See p. 10 for the **DISPOSITION OF THE DEEP FASCIA** of metatarsus and digit.

Arteries and Veins on the Distal Part of the Hindlimb

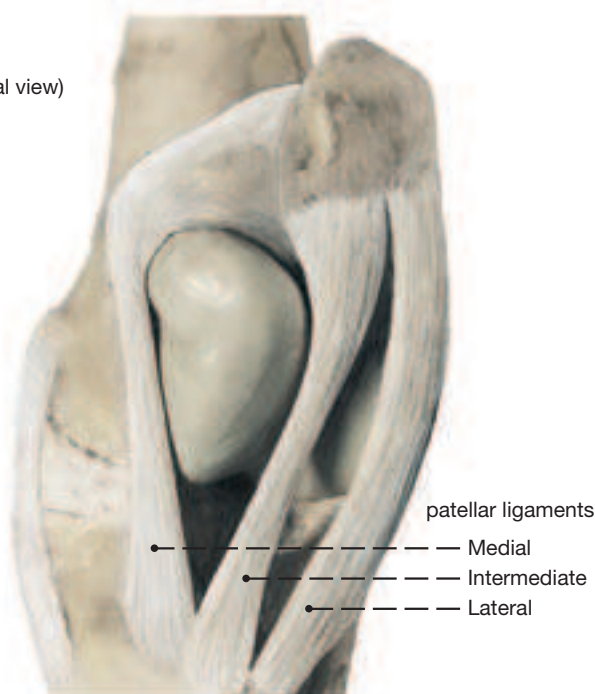


Arteries, Veins, and Nerves of the Distal Hindlimb



- 1** The **PASSIVE STAY-APPARATUS** prevents collapse of the hindlimb with only a minimum of muscular effort. That is to say, it prevents flexion in stifle and hock joints and overextension in the fetlock and phalangeal joints. These joint movements are opposed by the various components of the stay-apparatus (which include the deep fascia) and by the horse's ability to lock the stifle joint. When horses stand quietly for extended periods they support the hindquarters with only one hindlimb while resting the other (relaxed) on the toe of the hoof with the pelvis tilted slightly toward the “shorter”, non-supporting limb. The horse itself appears relaxed and comfortable with the three-legged support. (It cannot rest one of the forelimbs, however.)

(Craniomedial view)



- 2** An important part of the passive stay-apparatus is the so-called **reciprocal mechanism** that links the actions of stifle and hock joints. This is accomplished by the tendinous peroneus tertius muscle and the nearly tendinous supf. digital flexor muscle, both crossing the joint spaces of the two joints. The **peroneus tertius** arises (by a common tendon with the long digital extensor) from the lateral condyle of the femur and, passing cranial to the tibia, ends by complex attachments on certain tarsal bones and the proximal end of the large metatarsal bone. The **supf. digital flexor** lies caudal to the tibia and connects the caudal surface of the femur with the calcaneal tuber. The schematic representation of the stay-apparatus on the opposite page shows that stifle and hock must move in unison and, if the stifle joint is locked, that the hock joint is also rendered incapable of movement.

The fetlock and phalangeal joints are supported as in the forelimb by the interosseus and the supf. and deep flexor tendons with the fetlock joint slightly overextended in the standing animal. The tendinous **interosseus** arises proximal to the fetlock, attaches on the proximal sesamoid bones, and is functionally continued by the **distal sesamoidean ligaments** that attach on the plantar surface of the proximal two phalanges. The **supf. and deep flexor tendons** also attach proximal and distal to the fetlock and lend further support. The tendinous structures are under tension when weight is on the overextended fetlock joint and support the joint by preventing it from overextending further.

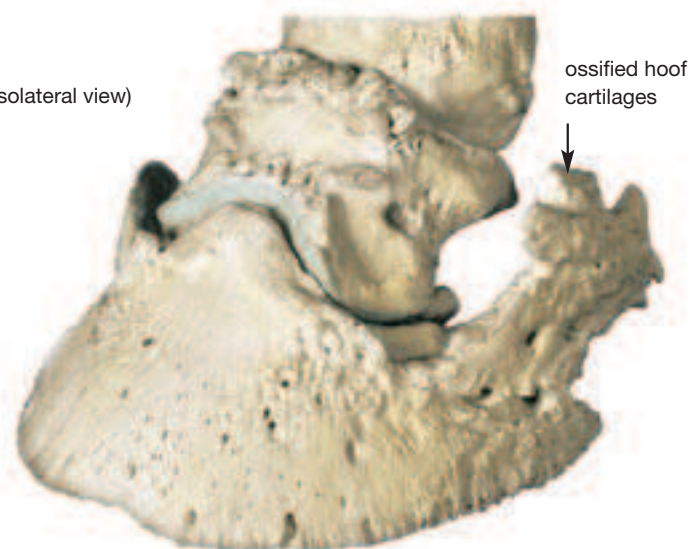
- 4** There are two differences from the arrangement in the distal part of the forelimbs. (1) The accessory (check) ligament of the deep flexor is much thinner and may be absent. (2) The supf. digital flexor tendon has no accessory ligament, but this is compensated for in the hindlimb by its firm attachment on the calcaneal tuber: its attachment proximal and distal to the fetlock joint still helps to prevent overextension in this joint when the limb is supporting weight.

By being able to lock the stifle, the horse converts the jointed column of its hindlimb into a weight-bearing pillar. This is accomplished by the very asymmetrical femoral trochlea, the patella, and two of the three patellar ligaments. The medial ridge of the trochlea is larger than the lateral and is prolonged proximally to form a rounded tubercle (see p. 17.21'). The medial patellar ligament connects to the medial border of the patella via the patellar fibrocartilage, while the intermediate patellar ligament attaches directly on the patellar apex. The two ligaments therefore diverge from a common origin on the tibial tuberosity and with patella and its fibrocartilage form a loop that embraces the tubercle on the medial trochlear ridge. When the horse is standing squarely on both hindlimbs the patella rests at the proximal end of the trochlea, without the loop fully embracing the tubercle. Perhaps only the tonus in the muscles attaching on the medial and lateral patellar ligaments (gracilis, sartorius; biceps, tensor fasciae latae) keeps the patella in place. When the horse rests one hindlimb on the toe of the hoof, the patella in the supporting limb rotates medially (about 15 degrees) and the fibrocartilage and medial patellar ligament slide farther caudally on the tubercle, fully locking the stifle.

Thus, the locking of this key joint enables the horse to stand with little muscular activity. Some effort must be required, however, because the horse tires after a few minutes and shifts its weight to the other hindlimb.

Distal Phalanx (coffin bone) with ossified Hoof Cartilages

(dorsolateral view)

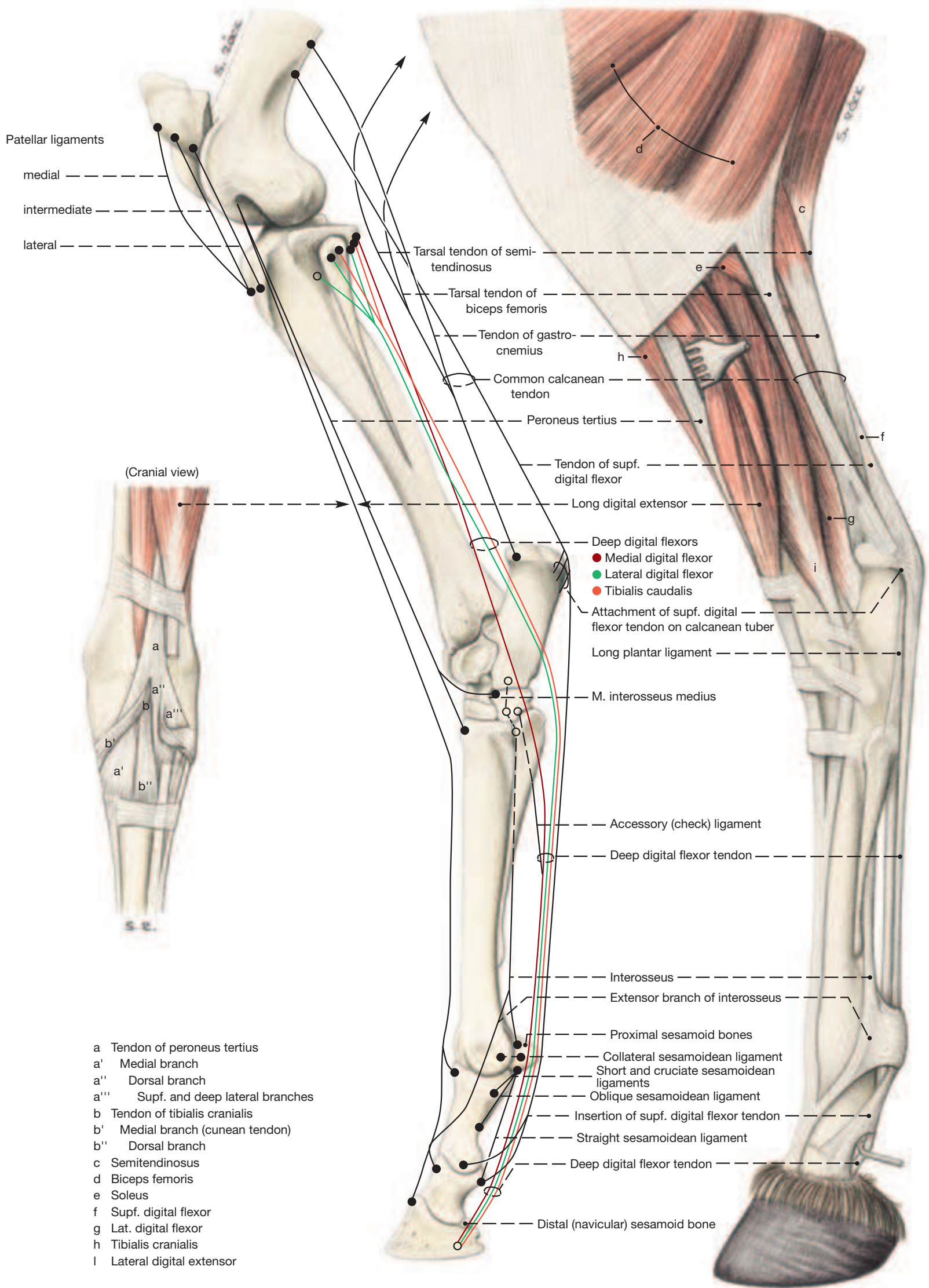


The **HOOF AND ITS CONTENTS** are popularly known as the foot of the horse, although this structure in no way corresponds to the human foot. The supporting structures enclosed by the hoof include the following: the distal portion of the middle phalanx, the distal phalanx with the insertions of the extensor and flexor tendons, the coffin joint with its capsule and collateral ligaments (see p. 15), the navicular bone and the medial and lateral hoof cartilages. These lie against the concave deep surface of the hoof but project with their dorsal borders above the coronary border of the wall. Several ligaments attach the hoof cartilages to the three phalanges and to the navicular bone. The latter forms part of the plantar (palmar) wall of the coffin joint capsule, articulating with both middle and distal phalanges. It is suspended from the distal end of the proximal phalanx by the collateral navicular ligaments, and distally it is connected by a short but wide distal navicular ligament to the plantar surface of the distal phalanx; the last-named ligament strengthens the coffin joint capsule at his location.

The deep flexor tendon changes direction as it passes over the navicular bone. The **navicular bursa** between the two structures provides frictionless movement of the tendon over the bearing surface provided by the bone. Navicular bone, bursa, and the tendon are of great clinical importance (see p. 14).

Certain Muscles of the Pelvic Limb

(Lateral view)



UQLjXbVxUmAVqC+HnIZ4uaraA==|1288006624

6. The Hoof (Ungula)

Cursorial specialization for speed—the hallmark of horses—has lengthened the horse's limbs during phylogeny and has raised the animal on the tip of only a single digit (and hoof) on each of its limbs. Compared to the weight of horse, the ground surface of a hoof is exceedingly small. In addition to transmitting and cushioning this weight, the hoof must protect the underlying soft tissues: two reasons for the complexity of this structure, which in some parts of the world is referred to as the digital “organ”.

- 1** a) **DEFINITION OF THE HOOF:** The hoof, in a narrow sense, is nothing more than modified skin covering the tip of a digit. In a wider sense, the hoof includes also the structures it encloses and protects, such as the distal phalanx (coffin bone), hoof cartilages, distal interphalangeal (coffin) joint, distal sesamoid (navicular) bone, tendons, ligaments, blood vessels, and nerves. (This in the jargon of horse owners, is known as “the foot of the horse”, although it bears, no resemblance to the human foot, for instance.) The remarkable skin modification that has taken place involves the three layers of the skin: epidermis, dermis, and subcutis, but not uniformly in all parts of the hoof. Characteristic for the hoof is, that it has no hair, no sebaceous and sweat glands (except for some associated with the frog), and that it has a firm outer epidermis that must be trimmed (like a fingernail) as its wear with the ground does not keep pace with its growth; or conversely, it needs metal shoes if its growth does not keep pace with wear on man-made surfaces.

- 2; 3** **4** For its study the hoof is best macerated. This grossly separates the hard hoof epidermis from the underlying dermis by destroying the soft basal and spinous layers, but leaving the stratum corneum (the actual hoof capsule) intact. The two upper left Figures on the opposite page illustrate that the interior of the hoof capsule can be likened to the (negative) imprint of the (positive) dermis-covered foot from which the capsule was removed.

The **hoof capsule*** consists of wall, sole, frog and bulb. The **wall** (10, 11) is the part visible in the standing horse. It comprises a **toe** in front, **quarters** on the sides, and medial and lateral heels (30) at the back, where the wall reflects on itself to form medial and lateral **bars** (24, 25) that flank the frog from which they are separated by **paracuneal grooves** (29). The **sole** (22, 23) fills the space between the wall and frog; its parts between quarters and bars are its **angles**. The triangular **frog** (27, 28) projects into the sole from behind and closes the gap between the heels. Its two curar at the back of the hoof, thicken, spread upwards, an overhang the heels as the bulbs of the **heels** (26). The bulbs of the heels together with the frog are the homologues of the digital pad.

- 5** The dermis of the hoof bears papillae (1, 2, 4, 5) which in the large wall segment (see further on) are represented by dermal lamellae (3). The mitotically active cells in the basal and spinous layer of the hoof epidermis—the ones that maceration destroyed—produce the horn (stratum corneum) of the hoof by passing through processes of keratinisation and cornification until they die as mature horn cells. The epidermis overlying to consist of horn tubules embedded in intertubular horn. The same cells overlying the dermal lamellae produce epidermal lamellae which interdigitate with their dermal neighbors and make possible the movement of the wall toward the ground.

- 6** b) For further description the hoof may be divided into **FIVE SEGMENTS** which are most easily recognized in the upper left drawing on the opposite page. The horn produced in the first three segments forms the wall of the hoof. The respective skin modifications will be described for each segment.

I. The arrow **perioplic segment (Limbus)** circles the hoof adjacent to the haired skin. It widens on the palmar/plantar aspect of the hoof where it merges with the fifth (frog/Bulb) segment. (The junction between skin and periople is known as the Coronet.) The **perioplic dermis** (1) has short dermal papillae, which increase in length distally. These are covered by ¹the **periople (epidermis limbi —9)**

which is unpigmented, soft horn and appears whitish on the intact hoof. It descends as the external layer of the hoof wall but fails to reach the ground because it dries and gets worn away. The subcutis underlying the perioplic dermis is a slightly thickened ring known as the **perioplic cushion** (33).

II. The wider **coronary segment (Corona)** follows the perioplic segment distally and is separated from it by a shallow groove. The **coronary dermis** (2) is studded with papillae which are longest distally where they can be made out with the naked eye. The **coronary epidermis** (10) forms the middle layer of the hoof wall. This horn is hard, pigmented, and is pushed toward the ground by the growth of its living basal and spinous layers covering the coronary dermis. The coronary horn consists of many **horn tubules** (17) which can be detected on the surface of the wall as proximodistally directed fine lines. The subcutis is present in the form of a ring-like **coronary cushion** (34) that causes the overlying coronary dermis to bulge and allows its papillae to be directed toward the ground.

III. The **wall segment (Paries)** lies deep of the hoof wall and extends from the coronary segment to the ground. The **parietal dermis** (3, 3') lies directly on the distal phalanx (39) and on the external surface of the hoof cartilages. The parietal dermis consists of primary and secondary dermal lamellae present only in this segment. The crests of the dermal lamellae give rise, near their proximal and distal ends, to small **cap papillae** which are directed distally. Similarly, the distal ends of the dermal lamellae bear a short row of **terminal papillae** (3') that also continue in the direction of the lamellae toward the ground. The living epidermal cells on the dermal lamellae produce **epidermal lamellae** (11) which interdigitate with the dermal lamellae; their centers are cornified (**horny lamellae —19**) and it is these that are visible on the internal surface of the wall of the hoof capsule. The living epidermal cells of the wall segment by their continuous mitotic activity make possible the slow, distal migration of the hoof wall. The horn produced over the cap and terminal papillae presents horn tubules that are better developed and visible only in the terminal horn near the ground where they can be made out in the **white line (zona alba —18, —20)** as faint dots between the horny lamellae.

The horn produced over the parietal dermis is covered by, and is continuous with, the thick plate of horn produced over the coronary dermis and becomes visible only at the white line of the intact hoof. The width of the white line is taken into consideration in the diagnosis of hoof diseases, for example in laminitis. The subcutis is absent in the wall segment.

Dermis and epidermis of the wall segment transfer part of the weight upon the limb to the inside of the wall through the following structures: distal phalanx, to the dermal lamellae, by interdigitation to the horny lamellae of the wall, and through the sole border of the wall to the ground.

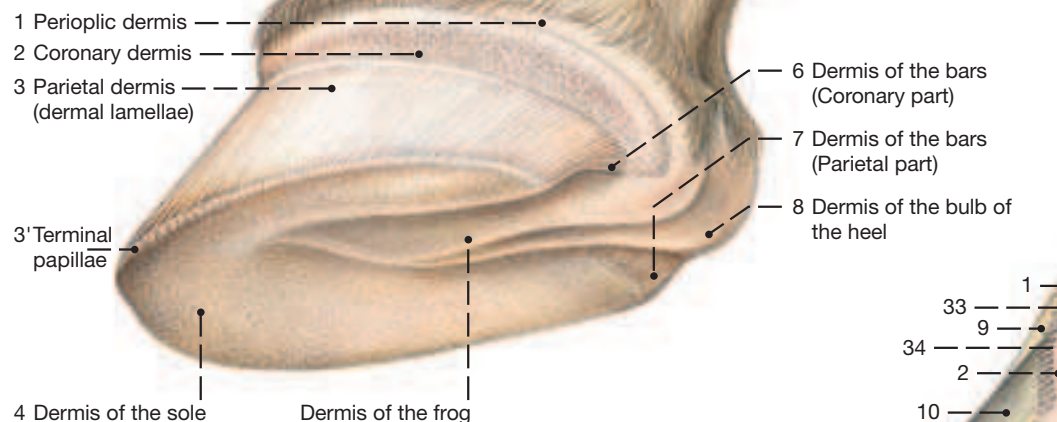
IV. The slightly concave **sole segment (Solea)** occupies the space between the sole border of the wall and the frog/bulb segment. The **dermis of the sole** (4) lies directly on the sole surface of the distal phalanx and presents short dermal papillae. The horn of the sole is hard tubular horn. A subcutis is absent.

V. The **frog/bulb segment** forms part of the ground- and the palmar/plantar surface of the hoof. The **dermis of the frog/bulb segment** (8, 5) presents papillae which spiral in the bulbar part while being straight where they underlie the frog. The horn produced by the overlying **epidermis** (13, 16) has spiralling horn tubules and is soft in the bulbar part of the segment and in the center of the frog; close to the sole the horn of the frog is hard. The subcutis deep to the frog is a thick wedge that occupies the space between the deep flexor tendon and the hoof cartilages; it is a feltwork of fibrous connective- and adipose tissue known as the **digital cushion** (35, 36).

Hoof

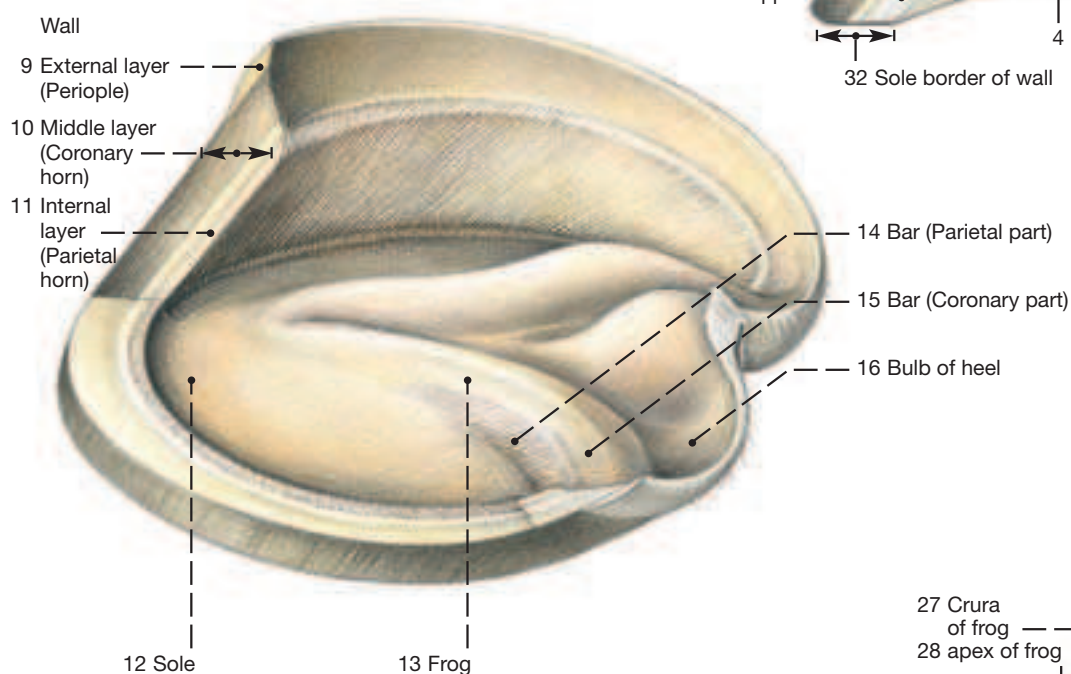
Hoof dermis

(Proximolateral view)



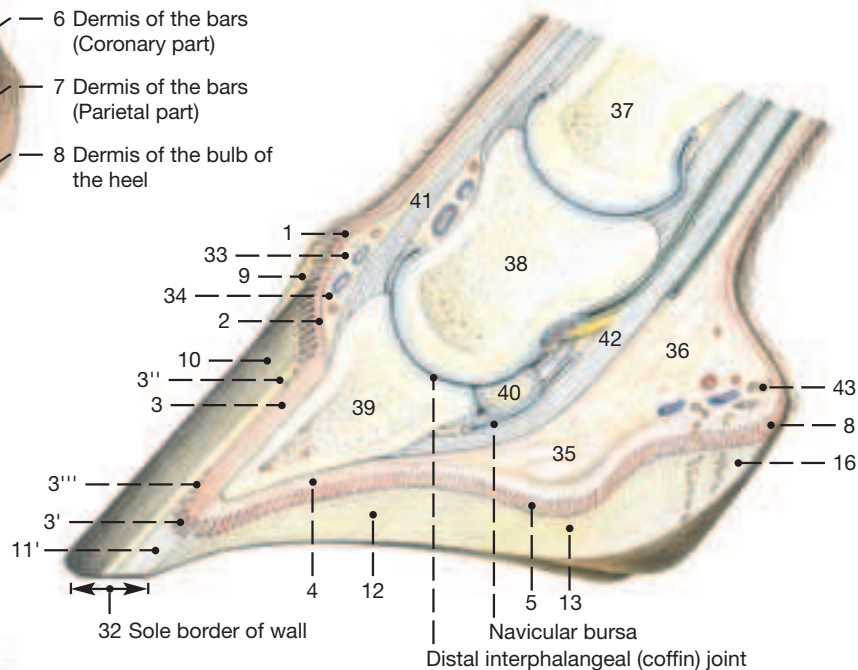
Hoof capsule

(Distolateral view)

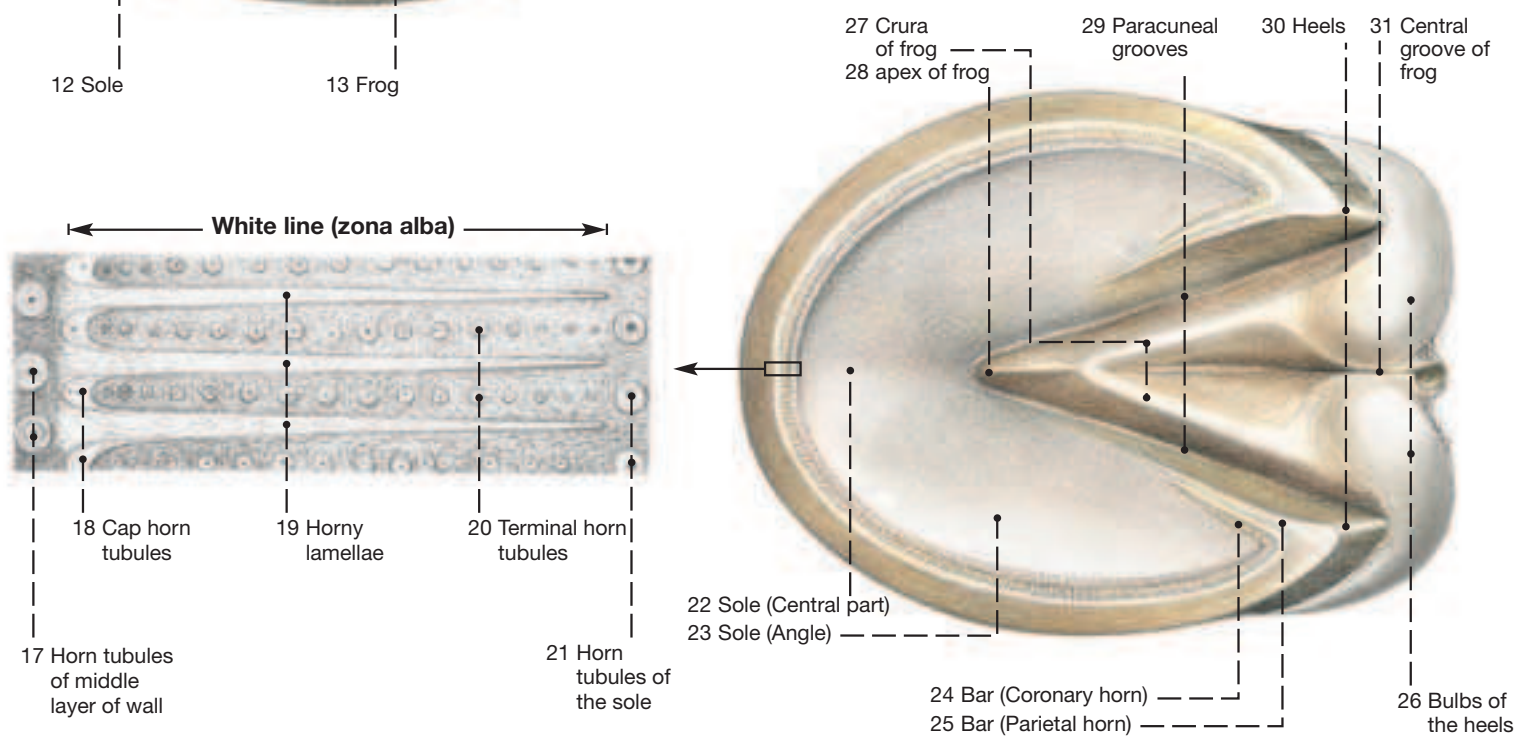


- 33 Periopic cushion
- 34 Coronary cushion
- 35, 36 Digital cushion
- 37 Proximal phalanx
- 38 Middle phalanx
- 39 Distal phalanx
- 40 Navicular bone
- 41 Common digital extensor tendon
- 42 Deep digital flexor tendon
- 43 Glands of the frog

Median section



Ground surface



7. Suspensory Apparatus of the Coffin Bone (Distal Phalanx), Vessels and Nerves of the Hoof

Clinical and Functional Anatomy p. 138–141

The horse is an animal walking *on the border of the tip of the toe*. That means that its body weight rests predominantly on the **solear border** (*margo solearis*—5) of the hoof; whereas, its modified digital pad, the **sole** (*solea ungulae*) and the **frog** (*cuneus ungulae*) of the hoof, depending on the character of the ground-surface, bear only a small part of the body weight. This is in contrast to the claw (see Atlas of Bovine Anatomy). Within the hoof, the body weight of a horse is transferred from the **coffin bone** (*os ungulae*) to the hoof plate by the **suspensory apparatus of the coffin bone** (*apparatus suspensorius ossis ungulae*) and by this to the solear border of this hoof plate.

I. DEFINITION OF THE SUSPENSORY APPARATUS OF THE COFFIN BONE.

The suspensory apparatus of the coffin bone is a constituent of the equine hoof. The concept, suspensory apparatus of the coffin bone, comprises all connective tissue and epithelial structures in the wall segment as a functional unit of the hoof, which transfers the body weight. The body weight rests as a pressure-force on the **coffin bone** (*os ungulae*—3) and is transferred as a tensile force onto the hoof plate. The **wall corium** (*dermis parietis*—2) and the **wall epidermis** (*epidermis parietis*—1) are part of this suspensory apparatus.

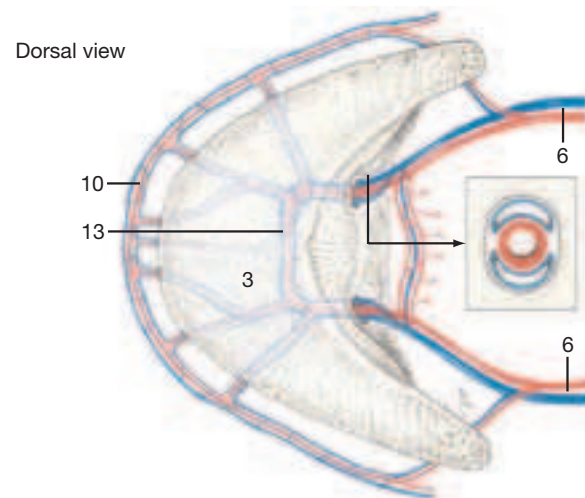
a) The wall corium is a taut, collagen-fibered connective tissue, conducting blood vessels and nerves. The collagen fiber-bundles originate at the parietal surface of the coffin bone. Proximodistally running bony crests are characteristic for the parietal surface of the coffin bone, at which—and less between them—the collagen fiber-bundles of the wall dermis arise directly in the bone tissue by way of a chondroapophyseal insertion. The coffin bone has no periosteum in this insertional zone of the connective tissue part of the suspensory apparatus of the coffin bone. Moreover, partially calcified fibrocartilage is embedded here. The collagen fiber-bundles of the wall corium exchange fibers with each other, and by this a dense network of fibers, the **reticular layer** (2") (*stratum reticulare*) of the wall corium is formed. The collagen fiber-bundles then run radially, obliquely distoproximally in direction into the primary and secondary **dermal lamellae** (*stratum lamellatum dermidis parietis*—2') and insert on the basal membrane that joins the parietal dermis and parietal epidermis together.

b) The parietal epidermis with its primary and secondary laminae is interlocked with those of the dermis. With the putting down (weight-bearing) of the hoof, the tensile force acting on the secondary lamellae is transferred via the basal membrane onto the basal and spinous cells in the secondary epidermal lamellae. These are connected via hemidesmosomes on the basal membrane or via desmosomes to each other and via finger-like processes to horn cells within the primary epidermal lamellae. These primary epidermal lamellae or horny lamellae pass over continuously into the intertubular horn of the coronary horn and wind around the coronary horn tubules in a basket-like manner. By these intensive connections in the form of intercellular junctions and interdigitating cell processes, the tensile force is finally transferred to the coronary horn in the epidermal part of the suspensory apparatus of the coffin bone. This then rests as a pressure force on the solear border of the hoof plate.

II. The vessels that supply the hoof originate from the **lateral and medial plantar (palmar) digital arteries** (6) and **veins**. Functionally it should be noted that the lateral and medial digital arteries are multiply connected with each other by their branches (**coronal artery** [*a. coronalis*—7], **dorsal branch of the distal phalanx** [*r. dorsalis phalangis distalis*—9], **terminal arch** [*arcus terminalis*—13]), by which the blood supply is assured in variable loading of the hoof. In the same manner the lateral and medial veins are connected with each other, especially with their **venous plexuses** (*plexus ungularis*—11) that lie axial and abaxial to the **ungular cartilage** (*cartilago ungulae*—4). These venous plexuses, working together with the hoof mechanism, have a special importance for the drainage from the hoof. The superficial and deep arteriovenous anastomoses, which are described in the haired skin, lie in the corium of the hoof at the base of the **dermal papillae** or, respectively, at the base of a primary **dermal lamella**. It is by these that the blood can be drained in the papillary body of the modified ungular skin with by-passing of the terminal network of subepidermal capillaries.

The **medial and lateral plantar (palmar) digital arteries** (6) extend distally in the company of the same named veins and nerves on the sides of the deep flexor tendon. The **artery of the digital cushion** (*ramus tori ungulae* 12) branches from the plantar (palmar) digital

artery at the level of the proximal border of the ungular cartilage. It gives off a branch peripherally into the bulb of the heel and an axial branch to the crus of the frog. The **coronal artery** (7) arises from the abaxial wall of the plantar digital artery closely above the proximal border of the hoof capsule. It gives off dorsal branches and branches for the quarter region. Shortly before the plantar (palmar) digital artery enters the axial solear foramen or, respectively, the abaxial solear foramen there arises from its abaxial side a short common trunk for the **artery of the hoof wall** (*ramus dorsalis phalangis distalis*—9) and the **artery of the coffin bone** (*ramus plantaris phalangis distalis*—9'). These two arteries run on the surface of the bone and each gives off proximal as well as distal branches. The proximal branches of the *ramus dorsalis phalangis distalis* are connected to the distal branches of the coronal artery. Arterio-arterial anastomoses are also found at the distal border of the coffin bone and its plantar (palmar) processes. Here, the distal branches of the *ramus dorsalis phalangis distalis* and *ramus plantaris (palmaris) phalangis distalis* are connected with each other arcade-like to form the **artery of the solear border** (*a. marginis solearis*—10), which again anastomoses with distal branches of the *ramus tori ungulae* and those of the **terminal arch** (*arcus terminalis*) of the plantar (palmar) digital arteries. The terminal arch is the terminal part of the anastomosing lateral and medial plantar digital arteries and veins in the semicircular bony canal of the coffin bone (see text-figure, 13). The arterial pulse wave is transferred to the accompanying veins, by which the blood drainage from the hoof is enhanced.



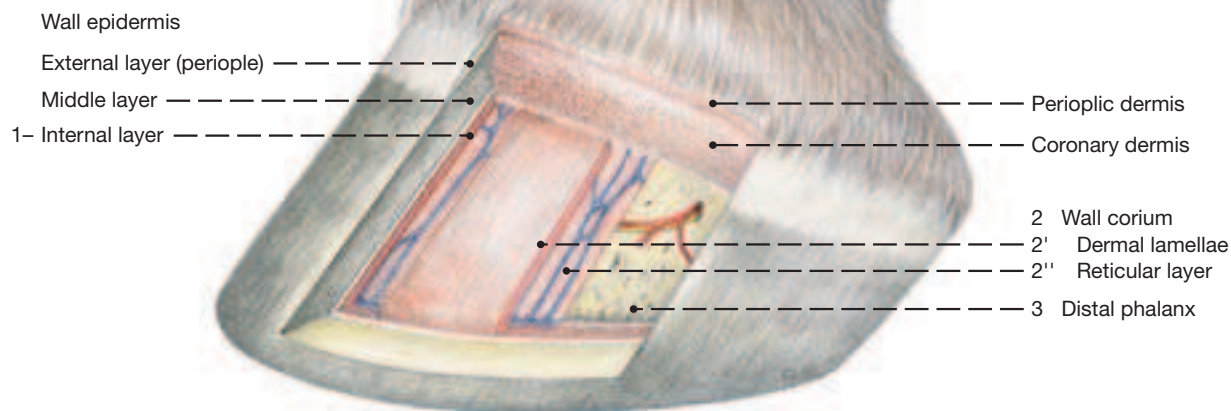
The subcutaneous arteries form a network from which the dermal vessels (*rete dermale parietale*—8) proceed. These ramify within the dermis just below the surface of the papillary body in a subepidermal capillary vascular plexus, from which originate the draining venules and veins. These veins again form a superficial, dermal, and deep, subcutaneous, (excluding the wall and sole segment) vascular plexus, from which the draining veins originate at the coronary and solear borders of the hoof. The venous drainage from the hoof in the subcutaneous venous plexus that lies axial and abaxial to the ungular cartilages is facilitated by the hoof mechanism in placing the foot down (weight-bearing) and lifting it up (pressure-suction pump).

III. The nerves of the hoof originate from the **lateral and medial plantar (palmar) digital nerves** (6). The latter nerves run lateral or, respectively, medial to the deep flexor tendon distally to the hoof and accompany the same-named arteries deep to the ligament of the ergot to the axial aspect of the ungular cartilage. Proximoplantar (-palmar) to the ungular cartilage a **branch of the digital cushion** (*ramus tori ungulae*) branches off from the digital nerve of each side. The continuing digital nerve turns dorsodistally axial to the plantar (palmar) process of the coffin bone, gives off branches for the coffin joint axially and enters the solear foramen to reach the solear canal of the coffin bone. In its semicircular course through the solear canal, proximal and distal nerve branches are given off. These together with arteries and veins penetrate the bone in a radiating manner. On the parietal surface of the coffin bone they enter the parietal dermis proximally and distally. Here again they branch into proximal and distal branches. These branches form a deep dermal network. From the branches of the deep dermal network, nerves branch off at the base of a lamella. Nerve end-corpuscles (tactile corpuscles) lie predominantly in the subcutis of the frog and heel. They appear moreover in the subcutaneous cushion of the periople and coronary dermis.

Suspensory Apparatus of the Coffin Bone

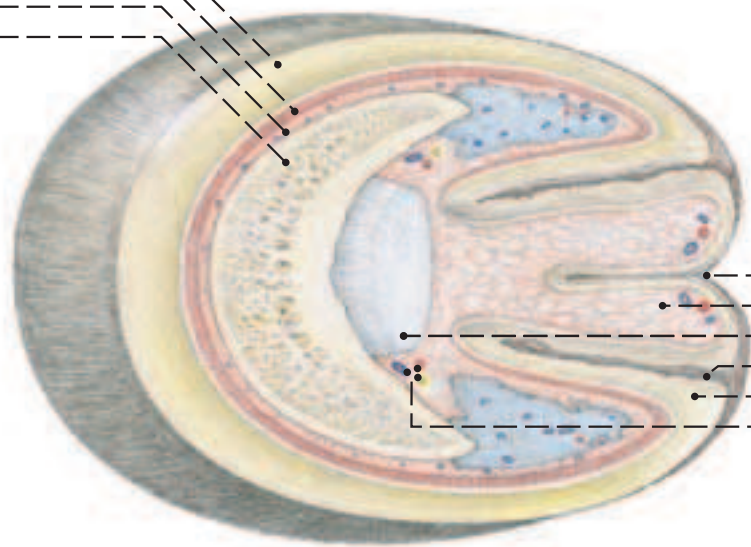
Hoof capsule and dermis, distal phalanx

(Dorsolateral view)

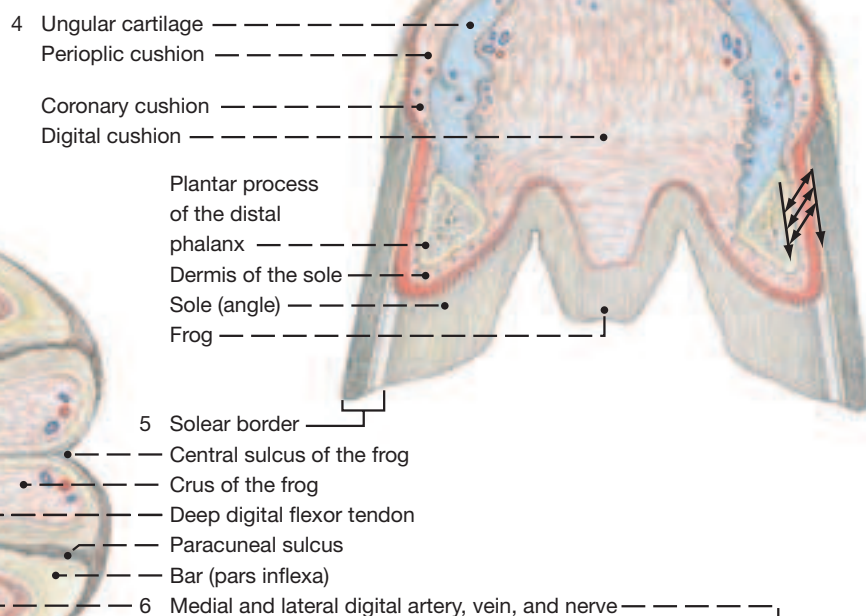


Horizontal section

Coronary epidermis
1
2
3



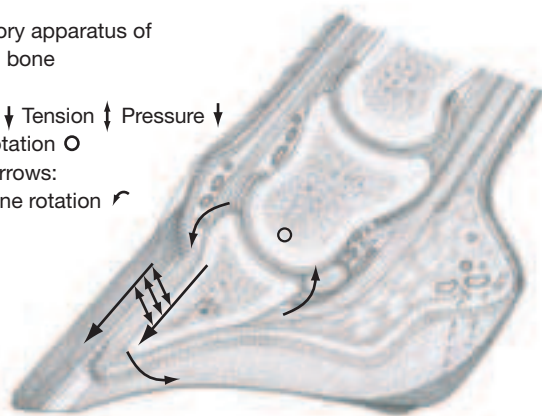
Transverse section



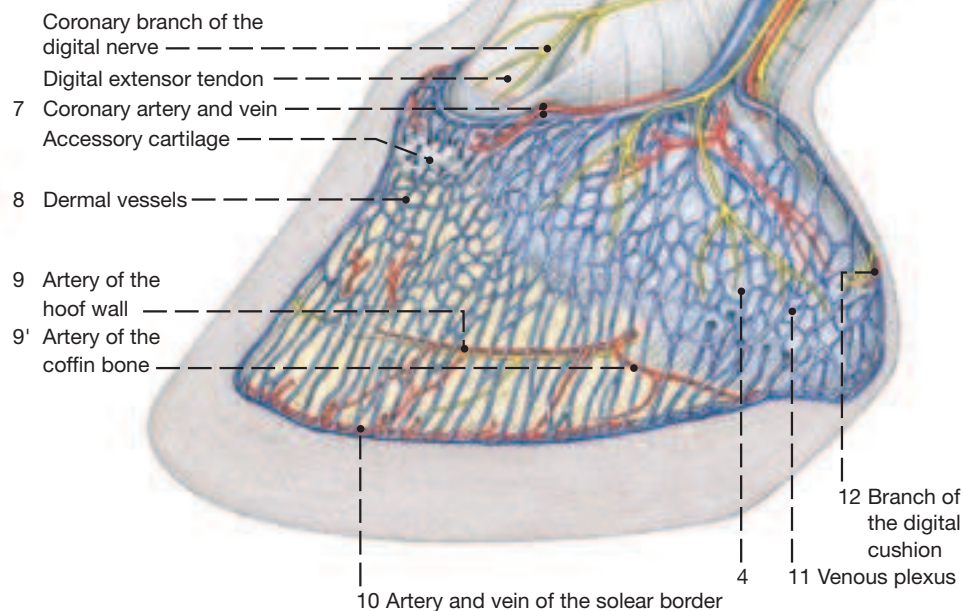
Median section

Suspensory apparatus of the coffin bone

Arrows:
Pressure ↓ Tension ↑ Pressure ↓
Axis of rotation ○
Curved arrows:
Coffin bone rotation ↻



(Dorsolateral view)



a) JOINTS OF THE PELVIC LIMB

Name/Fig.	Participating Bones	Type of the joint	Function	Remarks
1. Sacroiliac joint				see p. 165/166 (56.3.)
I. Hip joint	Ilium, pubis, ischium within acetabulum with the head of the femur	composite spheroidal joint	Mainly flexion and extension; little ab- and adduction	Ligaments: transverse acetabular; of femoral head; accessory; articular labrum deepens acetabulum
II. Art. genus (Kniegelenk)		Composite joint		Ligaments of the femorotibial joint: attach menisci to tibia and femur; cran. and caud. cruciates; med. and lat. collaterals
a) Femorotibia joint	a) Femur with med. and lat. condyles	a) Simple condylar joint	a) Mainly flexion and extension; tightening ligts. slow movement	
b) Femoropatellar joint	b) Femoral trochlea with patella	b) Simple gliding joint	Gliding	Ligaments of the femoropatellar joint: med., intermediate, and lat. patellars; med. and lat. femoropatellars
c) Proximal tibiofibular joint, communicates with the femorotibial joint				
III. Hock joint (tarsal joint)		Composite joint		
a) Tarsocrural joint	a) Cochlea of tibia with trochlea of talus	Simple cochlear joint	Springy “snap” joint allowing only flexion and extension	The two collateral and the long plantar ligts. have functional and clinical significance; many small ligts. are incorporated in the fibrous joint capsule
b) Prox. intertarsal	b) Talus and calcaneus with central and fourth tarsals	Composite plane joint	Minimum movement	
c) Distal intertarsal	c) Central tarsal with first to third tarsals Mt II–IV und prox. Ossa tarsalia I–IV	Composite plane joint	Minimum movement	
d) Tarsometatarsal joint	d) First to fourth tarsals with second to fourth metatarsals	Composite plane joint	Minimum movement	
e) Intertarsal joints: vertical joints between tarsal bones				

1 Hip joint: The acetabulum is deepened by the fibrous labrum along its rim. The ligament of the femoral head extends from the depth of the acetabulum to the central part of the fovea. The accessory ligament, a peculiarity of the horse, arises mainly from the terminal tendon of the rectus abdominis and to a lesser extent from the external abdominal oblique muscle and the yellow abdominal tunic covering it. It is part of the prepubic tendon and inserts in the peripheral part of the fovea. Both ligaments pass through the acetabular notch where they cross dorsal to the transverse acetabular ligament.

2 The femorotibial joint of the stifle is incompletely divided by the two crescent-shaped menisci into upper and lower compartments. These communicate freely through the open centers of the menisci where the condyles of femur and tibia are in direct contact. The menisci are tough, fibrocartilaginous structures that compensate for the incongruity of the articular surfaces; they are said to reduce concussion in the joint. Their thick outer margins are firmly attached to the fibrous joint capsule, and their ends are anchored mainly on the tibia, but with one ligament also to the femur. The joint cavity is divided into medial and lateral sacs. Whether the (axial) synovial membranes completely separate the two has not been firmly established. (Both may communicate with the femoropatellar joint cavity.) The two sacs are punctured using the collateral ligaments as palpable landmarks. The cruciate ligaments in the center of the joint cannot be palpated. They are important for the stability of the stifle. The combined tendons of origin of the long digital extensor and peroneus tertius are underlain by an extension of the lateral femorotibial joint cavity to lessen friction with the tibia.

The **femoropatellar joint** moves in unison with the femorotibial joint. The patella is anchored to the femur by medial and lateral femoropatellar ligaments and to the tibia by three patellar ligaments. The medial patellar ligament contains tendinous elements of the sartorius and gracilis muscles, the intermediate ligament is the principal termination tendon of the rectus femoris, and the lateral patellar ligament contains tendinous tissue from the biceps femoris and tensor fasciae latae. (For the loop formed by the medial and intermediate ligaments that locks the stifle see p. 24.)

The (proximal) **tibiofibular joint** allows little movement. Its cavity communicates with the lateral femorotibial joint. (There is no distal tibiofibular joint in the horse.)

3 The hock joint has four levels of articulation of which the distal

three permit almost no movement. The medial and lateral (long) collateral ligaments arise from their respective malleoli on the tibia and terminate on the proximal extremities of the corresponding splint bones. Between these points they attach also to some of the tarsal bones they cross. The long plantar ligament extends from the calcaneus distally to the proximoplantar surface of the metatarsal bones and, as the preceding ligaments, connects also to the intervening tarsal bones. The fibrous joint capsule extends from the tibia to the metatarsal bones and is firmly attached to various parts of the tarsal skeleton. The synovial membrane, however, is divided into the four joint cavities of which a and b (of the Table), and sometimes c and d, communicate. The capacious capsule of the tarsocrural joint has a dorsal and two plantar pouches; these are areas where the fibrous capsule is weak and free to bulge when the joint cavity is distended by synovia.

b) IMPORTANT SYNOVIAL BURSAE

The **trochanteric bursa** lies between the tendon of the gluteus accessorius and the low part of the greater trochanter.

The **proximal infrapatellar bursa**, a peculiarity of the horse, lies deep to the proximal end of the intermediate patellar ligament; the **distal infrapatellar bursa** lies under the distal end of the same ligament.

The **subtendinous calcanean bursa** is situated between the calcanean tuber and the “cap” of the supf. flexor tendon that attaches here. An inconstant **subcutaneous calcanean bursa** lies in the same position but under the skin (capped hock).

The **subtendinous bursa of the medial tibialis cranialis tendon** facilitates movement of the tendon over the medial collateral ligament of the hock.

The **navicular bursa** between the deep flexor tendon and the navicular (distal sesamoid) bone is similar to that of the forelimb (Figs. on pp. 13 and 15).

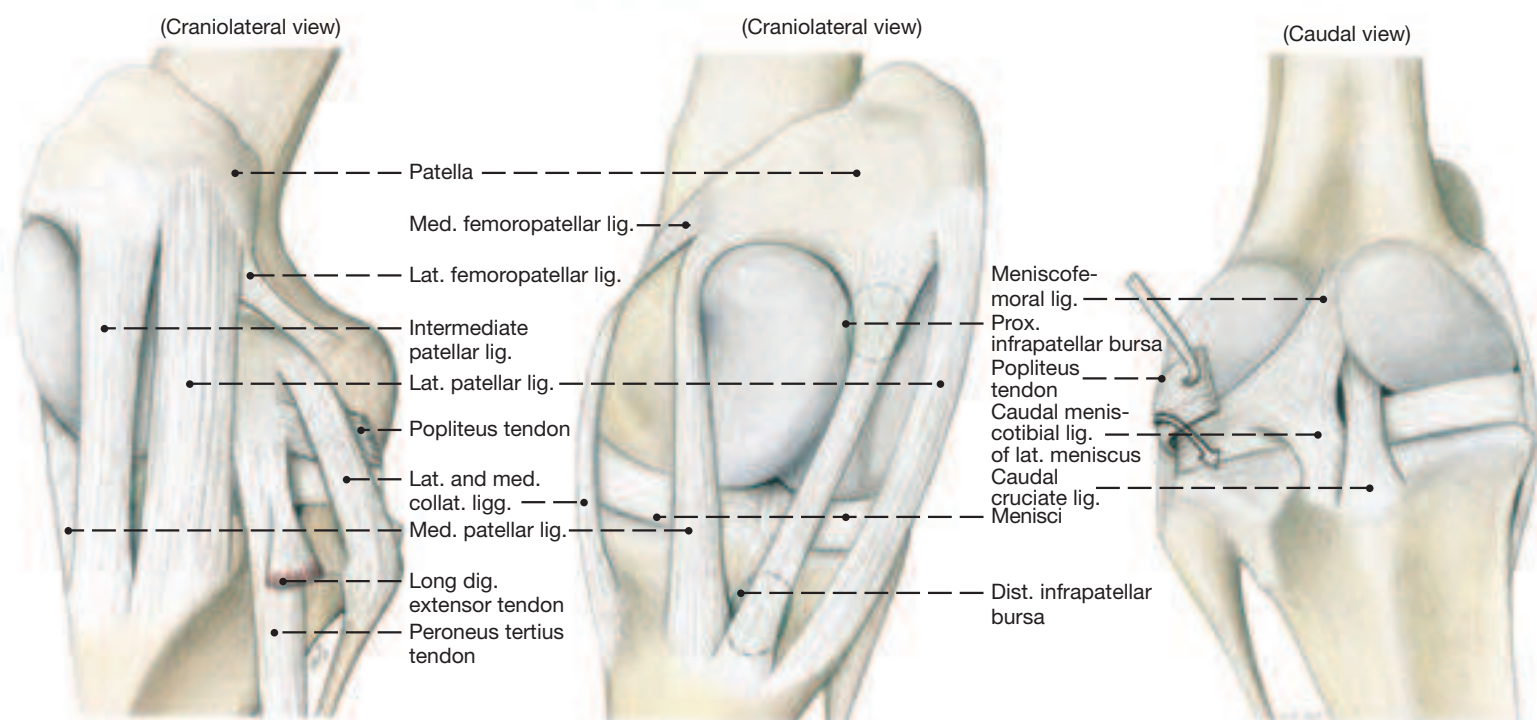
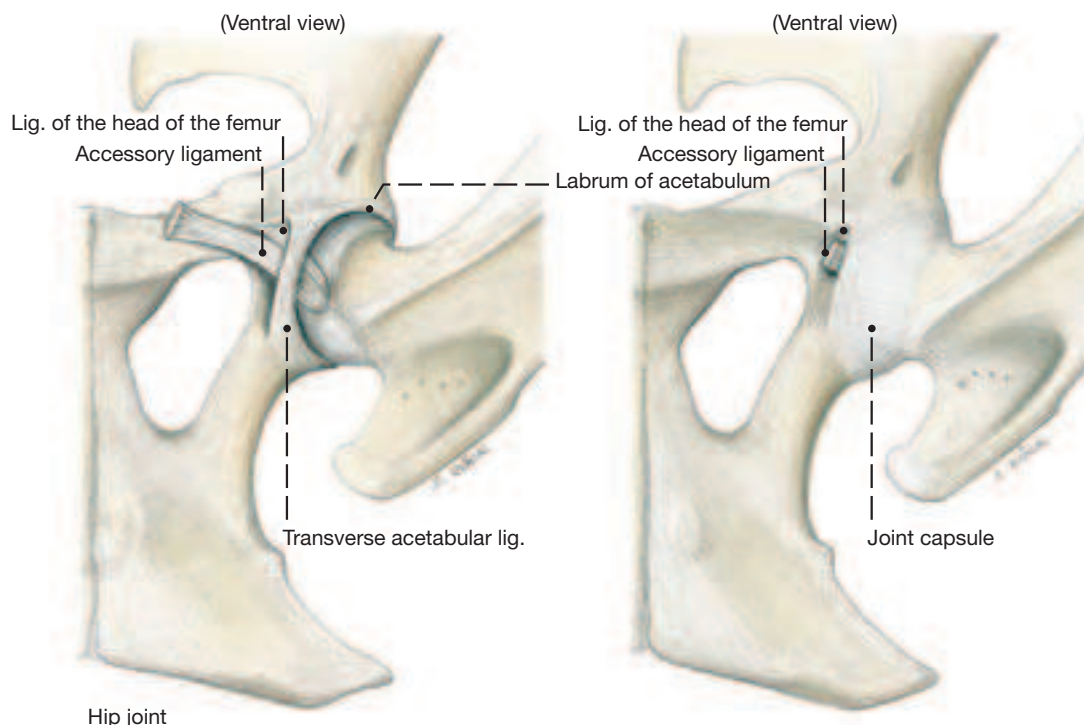
c) TENDON SHEATHS

The tendons passing over the hock are furnished with synovial sheaths, with the exception of the supf. flexor tendon whose passage over the calcanean tuber is eased by a bursa.

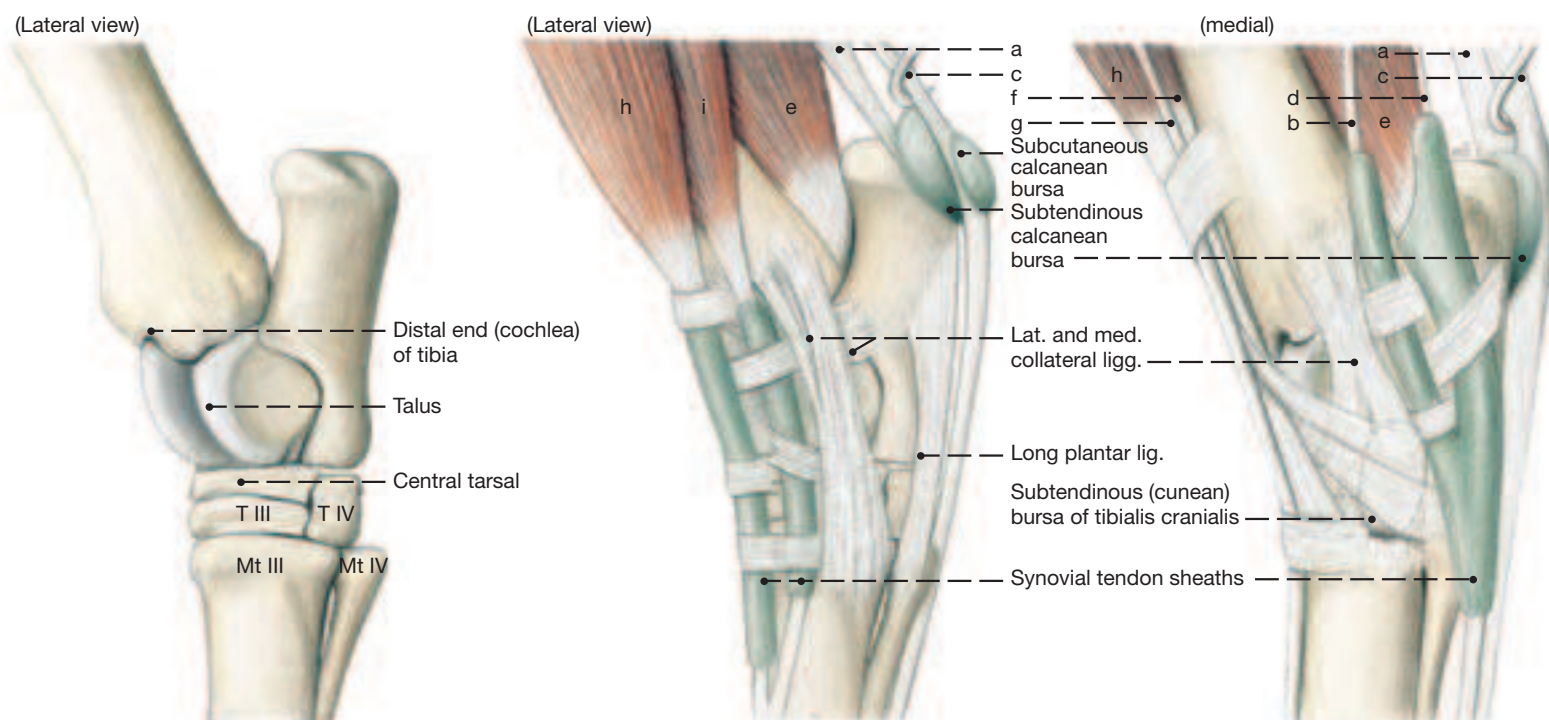
The digital sheath is like that of the forelimb (see pp. 10 and 15).

Joints (Articulations), Bursae and Synovial Sheaths

- a Gastrocnemius
- b Medial digital flexor
- c Superficial digital flexor
- d Tibialis caudalis
- e Lateral digital flexor
- f Tibialis cranialis
- g Peroneus tertius
- h Long digital extensor
- i Lateral digital extensor



Stifle joint



Hock joint

* The *Nomina Anatomica Veterinaria* (NAV) define hoof capsule as only the stratum corneum of all hoof segment.

1. Skull and Dentition

a) The **SURFACE FEATURES** of the skull such as processes, crests, and notches are helpful landmarks during palpation, while deeper skeletal features serve the same purpose when examining radiographs. The orbit lies between the facial and cranial parts of the skull and has a complete bony rim, since the **zygomatic process of the frontal bone** (1) is long enough to reach the zygomatic arch. The **tympanic bulla** (17) is unobtrusive and situated medial to the **styloid process** (10') of the temporal bone. The distinct **external occipital protuberance** (31) for the attachment of the nuchal ligament lies in the midline half way between the **nuchal crest** (m) and the **foramen magnum** (38). The lateral surface of the skull's facial part is characterized by the **facial crest** (57') that extends from the maxilla to the zygomatic arch. Between the **nasal process** (69) of the incisive bone and the nasal bone is the **nasoincisive notch** (X.), an easily palpated landmark. Midway between the rostral end of the facial crest and the nasoincisive notch lies the palpable **infraorbital foramen** (59) which is a landmark for a nerve block.

b) The more deeply situated **FORMINA** may be used for orientation on radiographs, and certain others are occasionally used to block nerves emerging from them.

A prominent foramen is the **foramen lacerum** (45') on the base of the skull between sphenoid, temporal, and occipital bones. Its rostral portion is sculpted to present an **oval notch** (45) and an **carotid notch** (p') which are separate foramina in the dog, for example. The caudal part of the foramen lacerum narrows to form the **jugular foramen** (q). The roof of the cranium presents a series of **dorsal apertures** (h') for veins which connect with the temporal meatus. The **supraorbital foramen** (1') transmits the frontal nerve that arises in the orbit.

The notch for the facial vessels on the ventral border of the mandible is an important landmark in the horse for taking the pulse (see p. 35.77').

c) The **DENTITION OF THE HORSE** is characterized by almost all teeth being hypsodont (they are tall and continue to grow in length after erupting), by a molarization of the premolars to form a continuous grinding surface with the molars, and by the two rows of lower cheek teeth standing closer together than the two rows of cheek teeth in the upper jaw. Distinct lateral masticatory movements cause the cheek teeth to obtain a flat, though very rough, occlusal surface. The horse, as the other domestic mammals, has a heterogeneous dentition that consists of incisors (I), canines (C), premolars (P), and molars (M) of which the two last-named are similar and because of this are referred to simply as cheek teeth.

The **dental formula** for the deciduous teeth is

$$2 \left(Di \frac{3}{3} Dc \frac{0}{0} Dp \frac{3}{3} \right) = 24$$

or more simply $\frac{3-0-3}{3-0-3}$

That for the permanent teeth is

$$2 \left(I \frac{3}{3} C \frac{1}{1} p \frac{3 \text{ or } 4}{3} M \frac{3}{3} \right) = 40 \text{ or } 42$$

or again more simply $\frac{3-1-3 \text{ (4) } -3}{3-1-3 \text{ } -3}$

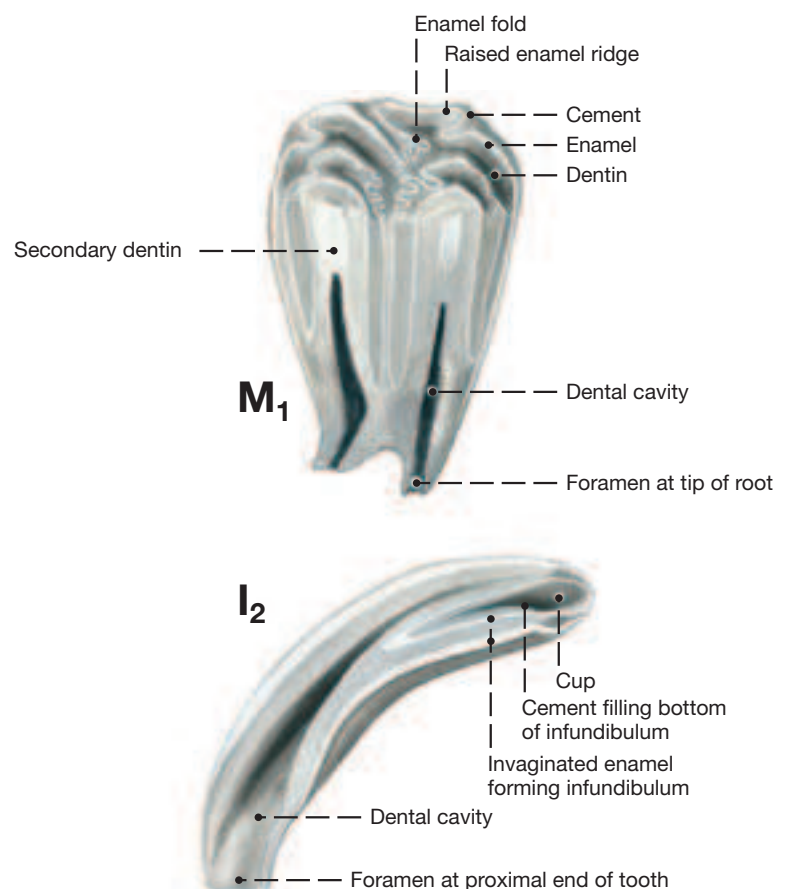
A further characteristic of the equine dentition is that the canine teeth are fully developed only in the male, and that the first premolar (P1) is a vestige ("wolf" tooth) that not always erupts. These

two teeth are brachydont which means that they are fully formed when erupted and do not increase in length as do the remaining hypsodont teeth. The growth of the horse's hypsodont teeth ceases about seven years following eruption. At that time short roots form on the cheek teeth while the foramen at the proximal end of the incisors gets increasingly smaller. Such teeth have to last the horse until death. Deposition of cement and bone at the bottom of the tooth sockets now pushes the teeth out of the jaws; this proceeds at the rate of wear at the occlusal surface which for the cheek teeth is 2–3 mm per year. Another feature of the cheek teeth is the extreme folding of their enamel casing. There is also invagination of the enamel at the occlusal surface producing infundibula. Both the folding and the invagination results in multiple raised enamel ridges on the occlusal surface separated by the softer dentin. Combining these features with the horizontal chewing movements of the mandible makes for a very efficient grinding mechanism. The enamel of the incisors is also invaginated at the occlusal surface (forming one infundibulum) resulting in two raised enamel rings when the tooth is in wear. Cement surrounds the enamel casing of both types of teeth while dentin fills the space between the enamel and the dental cavity within the tooth.

The surfaces of the teeth are known as mesial (facing the median plane along the dental arch), distal (the opposite surface), vestibular, and lingual; and the occlusal or working surface. The usual division of a (brachydont = short) tooth into crown, neck (at the gum line), and root (in the socket and clothed by cement) is not applicable to the horse's teeth. The reason is the growth at the proximal end of the teeth and their continuous extrusion from the jaw. Therefore, the part showing in the mouth may be called clinical crown, and the hidden, much longer portion, the body of the tooth.

Permanent Teeth in Longitudinal Section

Secondary dentin



Cranium

- External lamina (a)
- Diploe (b)
- Internal lamina (c)
- Osseous tentorium cerebelli (d)
- Temporal meatus (e)
- Canal for transverse sinus (f)
- Groove for transverse sinus (g) (not shown)
- Retroarticular foramen (h) ★ ●
- Dorsal apertures (h') ►
- Temporal fossa (j) ►
- External frontal crest (k) ►
- External sagittal crest (l) ►
- Nuchal crest (m) ►
- Temporal crest (m') ►
- Carotid notch (p') ★
- Jugular foramen (q) ★
- Petrooccipital fissure (q') ★

Neurocranial bones

I. Frontal bone ★ ►

- Zygomatic process (1) ★ ● ►
Supraorbital foramen (1') ►
Ethmoidal foramina (2) ★

IV. Temporal bone ★ ● ►

- a. Petrosal part (6) ★
- Mastoid process (7) ★
- Internal acoustic meatus
 - Internal acoustic orifice (8)
- Facial canal (9)
 - Stylomastoid foramen (10) ★
- Stylohyoid process (10') ★
- Petrotympic fissure (12) ★
- Cerebellar [floccular] fossa (13)
- Canal for trigeminal nerve (14)

- b. Tympanic part (15) ★
 External acoustic meatus
 External acoustic orifice (16) ★
 Tympanic bulla (17) ★ ●
 Tympanic opening of auditory tube (17'') ★ ●
 Muscular process (17'') ★

- c. Squamous part (18) ★ ►
Zygomatic process (19) ★ ►
Mandibular fossa (20) ★ ●
Articular surface (21) ★ ●
Retroarticular process (22) ★ ●

VI. Occipital bone ●

- Squamous part (30) ●
 External occipital protuberance (31) ●
 Tentorial process (31')
 Lateral part (32) ●
 Occipital condyle (33) ●
 Canal for hypoglossal nerve (35) ★ ●
 Paracondylar process (36) ★ ●
 Basilar part (37) ●
 Foramen magnum (38) ●
 Muscular tubercle (49) ●

VII. Sphenoid bone ●

Basisphenoid

- Body (41) ●
Sella turcica (42)
Wing (43) ★ ●
Foramen rotundum (44)
Oval notch (45) ★
Foramen lacerum (45') ★ ●
Pterygoid crest (46) ★
Alar canal (47) ★ ●
Rostral alar foramen (48) ★
Small alar foramen (48') ★
Caudal alar foramen (49) ★ ●

Prephenoid

- Body (50) ●
Wing (51) ★ ●
Optic canal (52) ★
Orbital fissure (53) ★

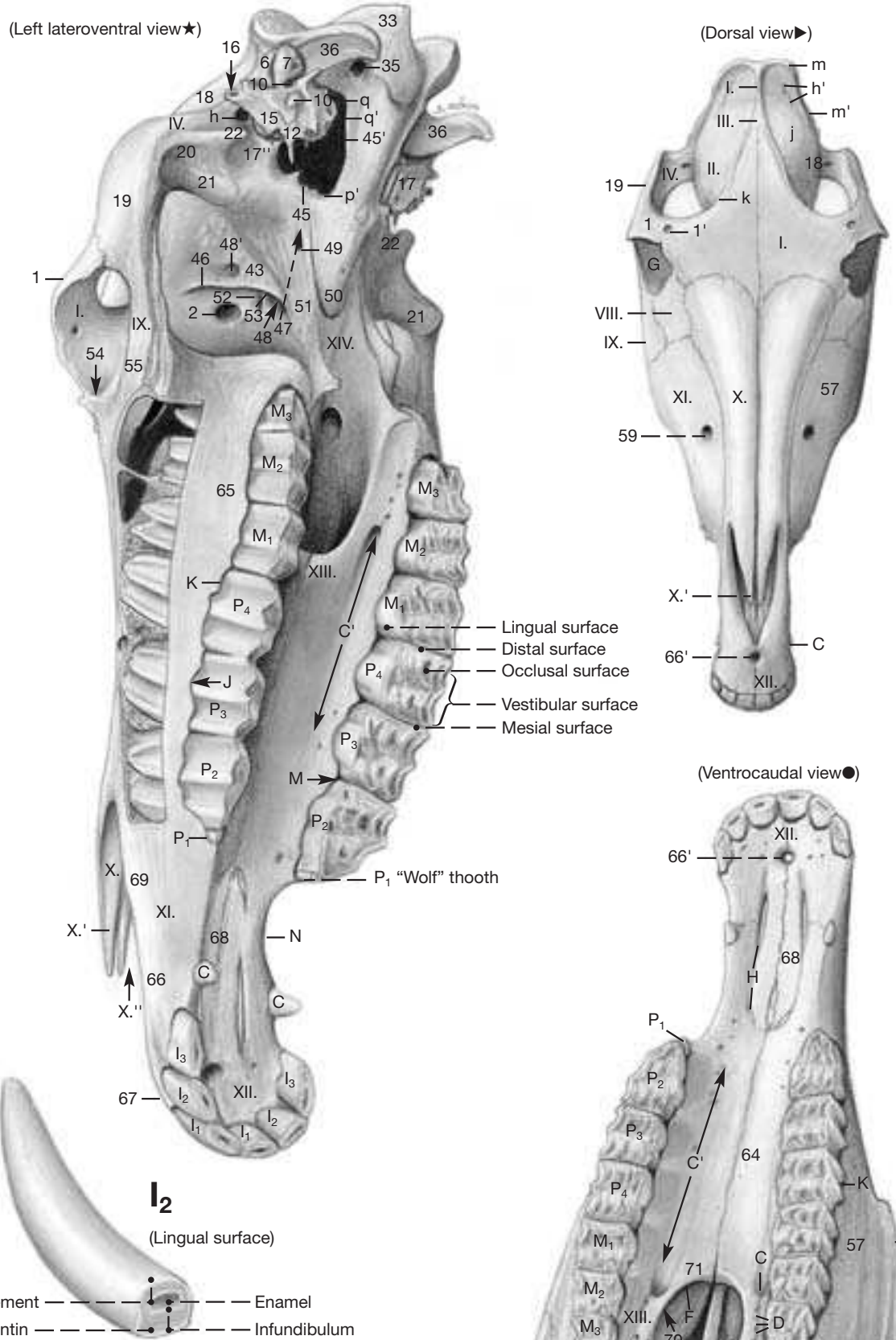
Face

- Pterygopalatine fossa (A) ●
Major palatine canal ●
Caudal palatine foramen (B) ●
Major palatine foramen (C) ●
Minor palatine canals ●
Caudal palatine foramen (B) ●
Minor palatine foramina (D) ●
Sphenopalatine foramen (E) ●
Choanae (F) ●
Orbit (G) ●▶
Palatine fissure (H) ●
Dental alveoli (J) ★
Alveolar ridges (K) ★●
Alveolar canals (L)
Interalveolar septa (M) ★
Diastema (N) ★

Facial bones

- VIII. Lacrimal bone** ★ ● ►
Fossa for lacrimal sac (54) ★

- IX. Zygomatic bone** ★ ●
Temporal process (55) ★



X. Nasal bone ★

- Rostral process (X.) ★
Nasoincise notch (X.) ★

XI. Maxilla ★ ►

- Body (57) ●►
 Facial crest (57'') ►●
 Infraorbital canal
 Maxillary foramen (58) ●
 Infraorbital foramen (59) ►
 Zygomatic process (63) ●
 Palatine process (64) ●
 Alveolar process (65) ★

XII. Incisive bone ★ ●

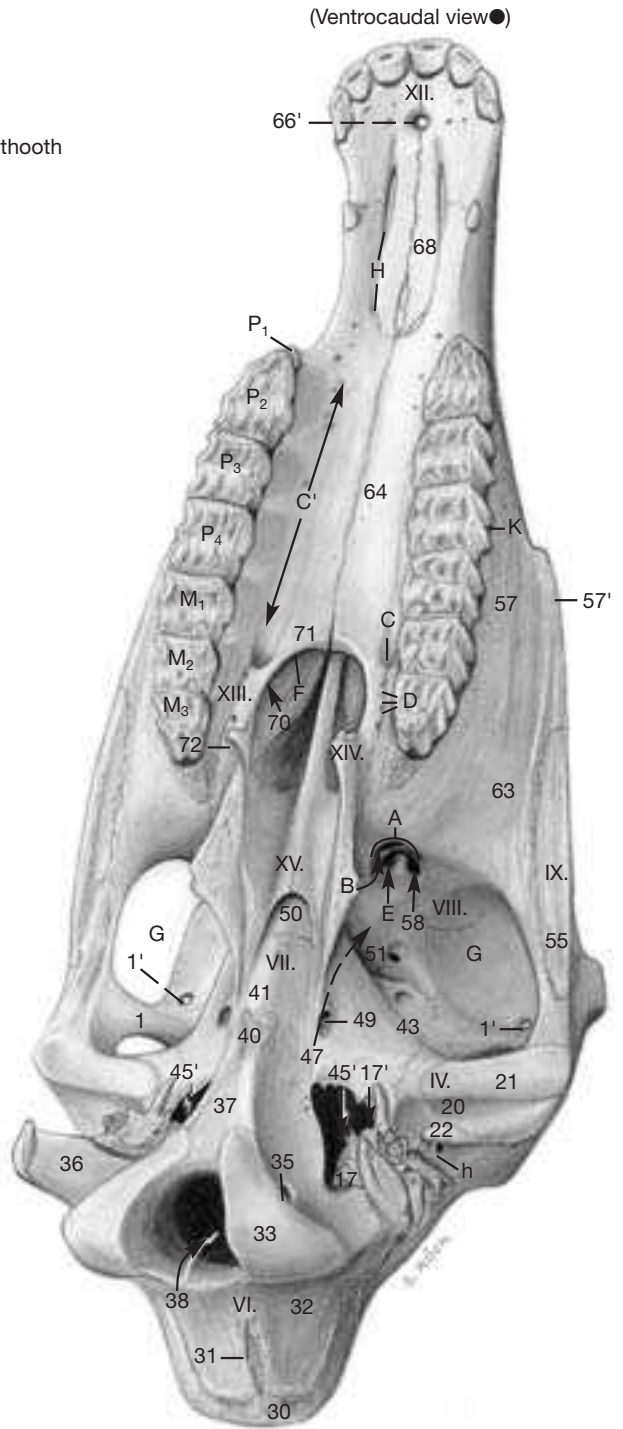
- Body (66) ★
Alveolar process (67) ★
Palatine process (68) ★ ●
Nasal process (69) ★

XIII. Palatine bone ★ ●

- Perpendicular plate (70) ●
- Horizontal plate (71) ●

XIV. Pterygoid bone ★ ●

- Hamulus (72) ●
- XV. Vomer ●**
- Septal groove (



2. Skull with Teeth and Paranasal Sinuses

a) The deciduous (milk) **TEETH** are white compared to the more ivory or yellowish color of the permanent teeth.

The **incisors (I)** of the deciduous set are shovel-shaped and have an indistinct neck. The recently erupted permanent incisors are 5–7 cm long, have a single root (body), and an oval occlusal surface that is oriented transversely. Their transverse section below the gums is more rounded and at the proximal end again oval but with the oval oriented longitudinally, i.e., from labial to lingual. (This change in shape is mirrored on the occlusal (working) surface as the teeth are worn down by the abrasive fodder and when the teeth are extruded to compensate for the loss at the crown; see Aging 32.2) The three incisors of a side are known popularly as central, intermediate, and corner incisors (I1–I3). During mastication, cement and dentin are worn away more readily than the harder enamel, leaving the latter to stand proud as **enamel crests** that can be perceived by running a fingernail across the working surface.

The **infundibulum** is partly filled with cement, leaving a small cavity, the cup, that is blackened by food deposits. Wear at the occlusal surface at first eradicates the cup (“cup-gone”), leaving the proximal end of the infundibulum known as the enamel spot in the center of the tooth. Secondary dentin, known as the dental star, appears on the labial aspect of the receding cup. The slightly darker secondary dentin is laid down at the distal end of the dental cavity before wear at the working surface of the tooth would open the cavity and expose its contents to infection. When also the enamel spot has been worn away, the now round dental star occupies the center of the occlusal surface.

The **canine teeth (C)** are fully developed only in the permanent dentition of the male. They are brachydont (short) teeth that are not extruded further following eruption. Mares lack them or show only peg-like rudiments, mostly in the lower jaw.

The rudimentary “wolf” **teeth (P1)** are seen mesial to P2, more often in the upper jaw. They fall out again or are pulled by horse owners for fear that they can cause pain to the animal by interfering with the bit.

1 The **premolars (P2–P4)** are four-cornered pillars (except P2 whose transverse section is triangular) which carry three roots in the upper jaw and two in the lower. Apart from the longitudinally folded enamel casing, the upper premolars present two infundibula visible on the working surface. Before such a tooth comes into wear the enamel of the outer casing is continuous with that forming the infundibula. Upon wear, this connection is lost. The infundibula, like those of the incisors, are filled with cement. Inside the outer enamel casing and surrounding the infundibula is dentin. Since the dentin and the cement wear more readily than the enamel, the working surface acquires a rasplike quality.

The last three cheek teeth, the **molars (M1–M3)**, are similar to the premolars, and have also three roots in the upper and two in the lower jaw.

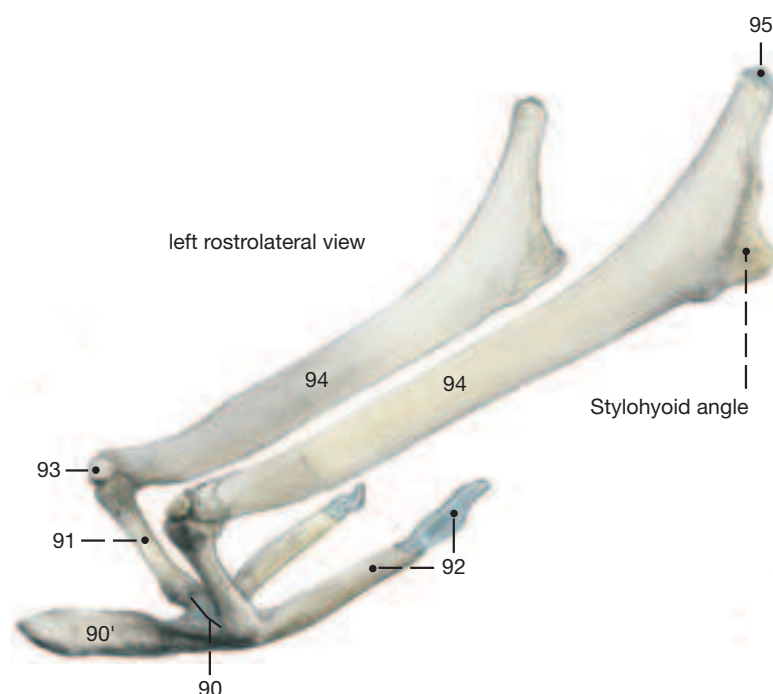
2 b) The **PARANASAL SINUSES** expand into the diploe of certain facial bones and, by remaining open to the nasal cavity, are lined with a thin respiratory epithelium. The expansion begins in the fetus and proceeds from the middle nasal meatus where throughout the life of the animal the **nasomaxillary aperture (α)** maintains communication into the rostral and caudal maxillary sinuses. These are separated by an oblique **septum (β)** that is inconstant in its position, but most often proceeds dorsocaudally from a point about 5 cm caudal to the rostral end of the facial crest. Though the septum separates

the two maxillary sinuses, its dorsal part is so thin that it can be dissolved by pus from an aggressive purulent sinusitis. The **rostral maxillary sinus (γ)** is significantly smaller than the capacious **caudal maxillary sinus (δ)**. The rostral maxillary sinus communicates over the infraorbital canal with the **ventral conchal sinus (ε)** located in the caudalmost portion of the ventral nasal concha. The ventral conchal sinus thus lies medial to the sagittal bony plate that supports the infraorbital canal. The roots of P4 and M1 covered by a thin plate of bone extend into and form the floor of the rostral maxillary sinus.

The floor of the caudal maxillary sinus is formed in part by the proximal ends of the last two cheek teeth (M2 and M3). Ventromedially, the caudal maxillary sinus communicates with the **sphenopalatine sinus (κ')** which excavates palatine and sphenoid bones ventral to the orbit; dorsomedially, the sinus communicates through a large oval **frontomaxillary opening (ζ)** with the conchofrontal sinus. The latter consists of the large **frontal sinus (η)** which lies dorsal to the orbit, and the smaller **dorsal conchal sinus (θ)** which lies rostromedial to the orbit. (Again, only the caudal portion of the dorsal nasal concha furnishes the dorsal conchal sinus; the rostral portion of both dorsal and ventral nasal conchae are scrolls surrounding recesses of the nasal cavity; see p. 45.)

c) The **basihyoid (90)**, the central bone of the **HYOID APPARATUS**, presents a prominent **lingual process (90')** that is embedded in the root of the tongue. The **thyrohyoid (92)** that projects caudodorsally from the basihyoid articulates with the thyroïd cartilage of the larynx. Dorsally, the basihyoid is succeeded by the **ceratohyoid (91)**. The small **epihyoid (93)** sits at the junction of cerato- and stylohyoids and fuses with the latter. The long and flat **stylohyoid (94)** articulates via a short cartilaginous **tympanohyoid (95)** with the **styloid process (10')** at the base of the skull.

Hyoid apparatus



Cranium

- External lamina (a) o
- Diploe (b) o
- Internal lamina (c) o
- Osseous tentorium cerebelli (d) o
- Temporal meatus (e) o
- Canal for transverse sinus (f) o
- Groove for transverse sinus (g) (not shown)
- Retroarticular foramen (h)
- Dorsal apertures (h')
- Temporal fossa (j)
- External frontal crest (k)
- External sagittal crest (l)
- Nuchal crest (m) o
- Temporal crest (m')
- Carotid notch (p') o
- Jugular foramen (q) o
- Petrooccipital fissure (q') o

Cranial cavity

- Rostral fossa (r) o
- Ethmoidal fossae (s) o
- Groove for chiasma (t) o
- Middle fossa (u) o
- Hypophysial fossa (v) o
- Piriform fossa (w) o
- Caudal fossa (x) o
- Pontine impression (y) o
- Medullary impression (z) o

Neurocranial bones

I. Frontal bone o

- Zygomatic process (1)
- Supraorbital foramen (1')
- Ethmoidal foramina (2)

II. Parietal bone o

- Tentorial process (4) o

III. Interparietal bone o

- Tentorial process (5) o

IV. Temporal bone o

- a. Petrosal part (6) o
- Mastoid process (7)
- Internal acoustic meatus
- Internal acoustic orifice (8) o
- Facial canal (9) o
- Stylomastoid foramen (10)
- Styloid process (10')
- Petrotympenic fissure (12)
- Cerebellar [floccular] fossa (13) o
- Canal for trigeminal nerve (14) o
- b. Tympanic part (15)
- External acoustic meatus
- External acoustic orifice (16)
- Tympanic bulla (17)
- Tympanic opening of auditory tube (17')
- Muscular process (17'') o
- c. Squamous part (18)
- Zygomatic process (19) o
- Mandibular fossa (29)
- Articular surface (21)
- Retroarticular process (22)

V. Ethmoid bone o

- Lamina cribrosa (23) o
- Crista galli (24) o
- Perpendicular plate (24') o
- Ethmoid labyrinth (25) o
- Ethmoturbinates
- Ectoturbinates (26) (not shown)
- Endoturbinates (27) o
- Dorsal nasal turbinate (28) o
- Middle nasal turbinate (29) o

VI. Occipital bone o

- Squamous part (30)
- External occipital protuberance (31) o
- Tentorial process (31') o
- Lateral part (32) o
- Occipital condyle (33)
- Canal for hypoglossal nerve (35) o
- Paracondylar process (36)
- Basilar part (37)
- Foramen magnum (38)
- Muscular tubercle (40)

VII. Sphenoid bone o

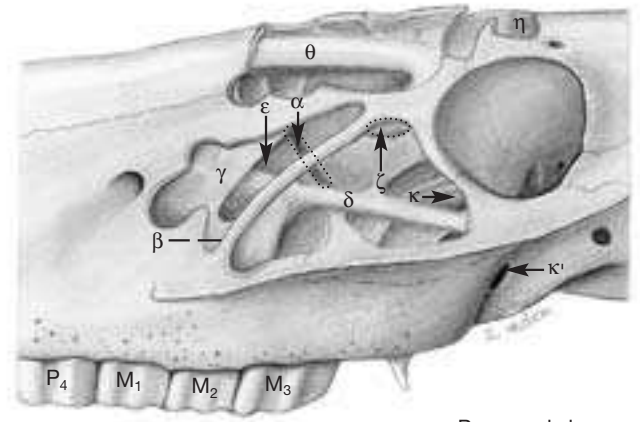
Basisphenoid

- Body (41) o
- Sella turcica (42) o
- Wing (43) o
- Foramen rotundum (44) o
- Oval notch (45) o
- Foramen lacerum (45') o
- Pterygoid crest (46)
- Alar canal (47) o
- Rostral alar foramen (48)
- Small alar foramen (48')
- Caudal alar foramen (49)

Presphenoid

- Body (50) o
- Wing (51) o
- Optic canal (52) o
- Orbital fissure (53) o

(Paramedian section o)



Paranasal sinuses

Face

Facial bones o

XII. Incisive bone o

- Body of incisive bone (66) o
- Alveolar process (67) o
- Palatine process (68) o
- Nasal process (69) o

XIII. Palatine bone o

- Perpendicular plate (70)
- Horizontal plate (71) o

XIV. Pterygoid bone o

- Hamulus (72) o

XV. Vomer o

- Septal groove (73)

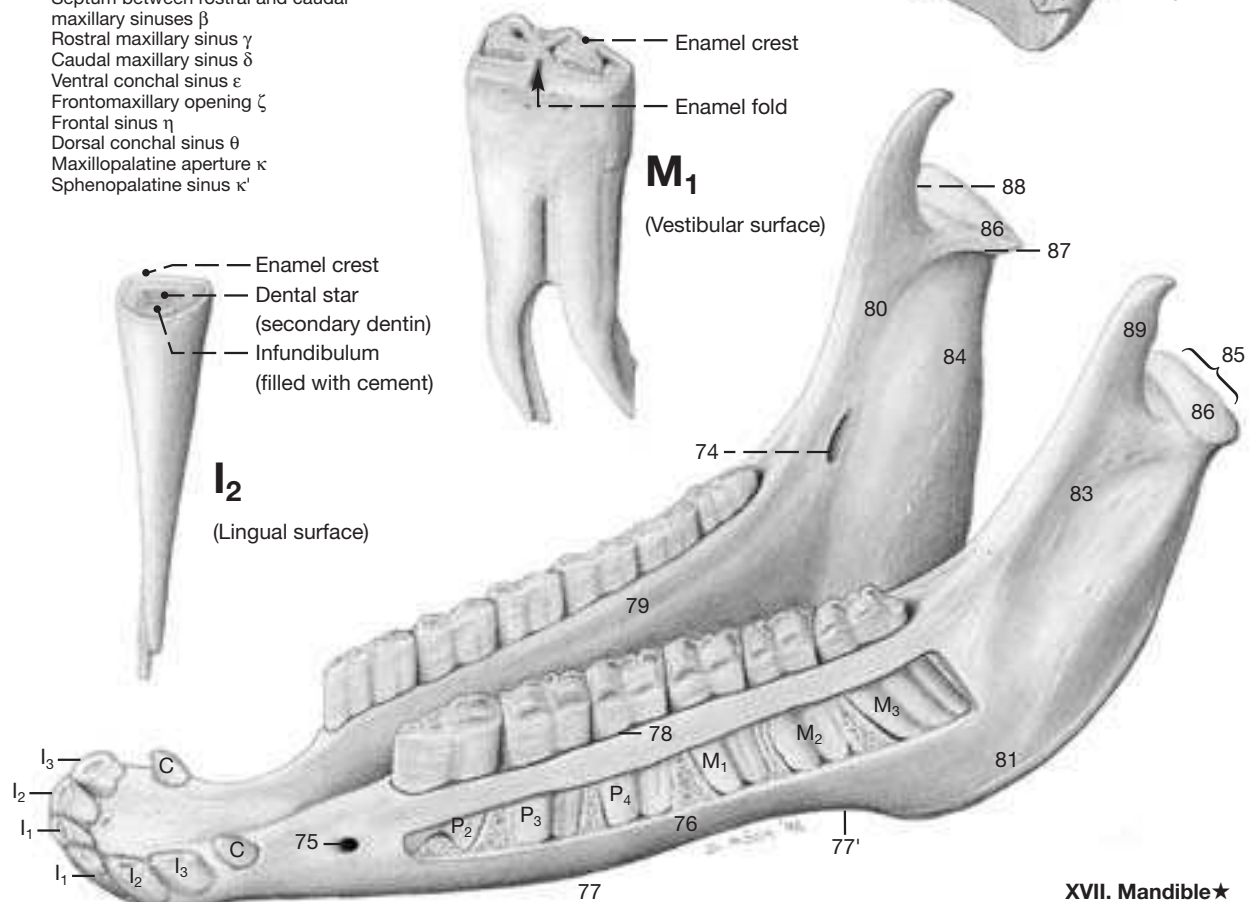
XVI. Ventral (nasal) turbinate o

XVII. Mandible*

- Mandibular canal
- Mandibular foramen (74) ★
- Mental foramen (75) ★
- Body of mandible (76) ★
- Ventral border (77) ★
- Vascular notch (77') ★
- Alveolar border (78)
- Mylohyoid line (79) ★
- Ramus of mandible (80) ★
- Angle of mandible (81) ★
- Masseteric fossa (83) ★
- Pterygoid fossa (84) ★
- Condylar process (85) ★
- Head of mandible (86) ★
- Neck of mandible (87) ★
- Mandibular notch (88) ★
- Coronoid process (89) ★

XVIII. Paranasal sinuses

- Nasomaxillary aperture α
- Septum between rostral and caudal maxillary sinuses β
- Rostral maxillary sinus γ
- Caudal maxillary sinus δ
- Ventral conchal sinus ε
- Frontomaxillary opening ζ
- Frontal sinus η
- Dorsal conchal sinus θ
- Maxillopalatine aperture κ
- Sphenopalatine sinus κ'



XVII. Mandible★

3. Supf. Veins of the Head, Facial nerve (VII) and Muscles supplied by the Facial Nerve

Clinical and Functional Anatomy p. 149

In order to show these structures to best advantage (Fig. on opposite page), the skin, cutaneous muscle, and the portion of the parotid gland dorsal to the maxillary vein are removed. The parotid lymphnodes under the cranial border of the gland should be preserved.

a) The **SUPF. VEINS** of the head are branches of the **external jugular vein** (21) whose prominent bifurcation at the angle of the mandible embraces the ventral end of the parotid gland and, more deeply, part of the mandibular gland (see p. 39.10) as well. The **linguofacial vein** (20) forms the ventral limb of the bifurcation; after releasing the lingual and sublingual veins, it becomes the **facial vein** (11) which crosses the ventral border of the mandible to ascend across the face. At the level of the lower cheek teeth the facial vein gives off the **buccal vein** (10) which passes deep to the masseter where it presents a dilated segment (see p. 39.3) before it joins the maxillary vein. At the level of the upper cheek teeth, the facial vein gives off the **deep facial vein** (8) that is similarly dilated (see p. 39.2) under the masseter; it passes into the orbit where it penetrates the periorbita.

The **maxillary vein** (32) is the other terminal branch of the external jugular vein. It gives off the **occipital vein** (31) which passes deeply under the wing of the atlas, and the **caudal auricular vein** (30) which remains superficial. Near the sternomandibularis (sternocephalicus) insertion arises the **ventral masseteric vein** (17) which passes almost ventrally into the masseter. Before the maxillary vein turns rostrally medial to the ramus of the mandible, it releases the **supf. temporal vein** (16). This vessel, after a short course to the level of the temporomandibular joint, sends the **transverse facial vein** (14) rostrally along the ventral aspect of the zygomatic arch. The transverse facial vein, near its origin, gives off the **dorsal masseteric vein** (25) and then is dilated (see p. 39.1) for a few cm before joining the facial vein ventral to the cranial end of the facial crest. The transverse facial vein supplies also the **inferior and superior palpebral veins** (24) to the eyelids.

b) The intraosseous course of the **FACIAL NERVE** (18) conforms to the general mammalian pattern. As the nerve emerges from the stylomastoid foramen it releases the **caudal** (30) and **internal** (27) **auricular nerves**, the latter penetrating the auricular cartilage to gain the inner surface of the auditory meatus. Next, a branch to the digastricus and occipitomandibularis is given off ventrally, and dorsally the **auriculopalpebral nerve** (15) to the ear and eyelids. The

facial nerve, now on a rostral course, receives a contribution from the **transverse facial branch** (26; of the auriculotemporal nerve, from V-3) and splits into **dorsal** (12) and **ventral** (13) **buccal branches** that cross the masseter in the direction of the mouth, being palpable (and visible) in thin-skinned horses.

c) The **MUSCLES SUPPLIED BY THE FACIAL NERVE** (with minor exceptions) are known as the muscles of facial expression, or the mimetic muscles; they activate muzzle, cheeks, eyelids, and ear.

The **levator nasolabialis** (4) splits distally to provide passage to the caninus. Its ventral part crosses the supf. surface of the caninus and ends in the upper lip by joining the **orbicularis oris** (1), while the dorsal part passes deep to the caninus to reach the nostril and upper lip. The **levator labii superioris** (6) arises rostroventral to the orbit. Its belly covers the infraorbital foramen—and has to be displaced dorsally when the foramen is to be palpated. The muscle ends with a long tendon (provided with a tendon sheath) that unites with its fellow from the other side and descends into the upper lip between the nostrils; it raises the lip in the “flehmen” reaction. The **caninus** (3) extends from the facial crest to the lateral aspect of the nostril by passing between the two parts of the levator nasolabialis. The **depressor labii inferioris** (2) arises from the coronoid process of the mandible and passes forward deep to the masseter and along the ventral border of the buccinator to the lower lip where its tendon covers the mental foramen. The **buccinator** (7) itself forms the muscular base of the cheek between upper and lower jaws and extends from the coronoid process to the angle of the mouth; its caudal portion lies deep to the masseter. The **zygomaticus** (5) arises ventral to the facial crest at the level of the orbit and passes to the angle of the mouth.

The muscles of the eyelids are thin and delicate; they include the **levator anguli oculi medialis** (22), the **orbicularis oculi** (23), and the **malaris** (9).

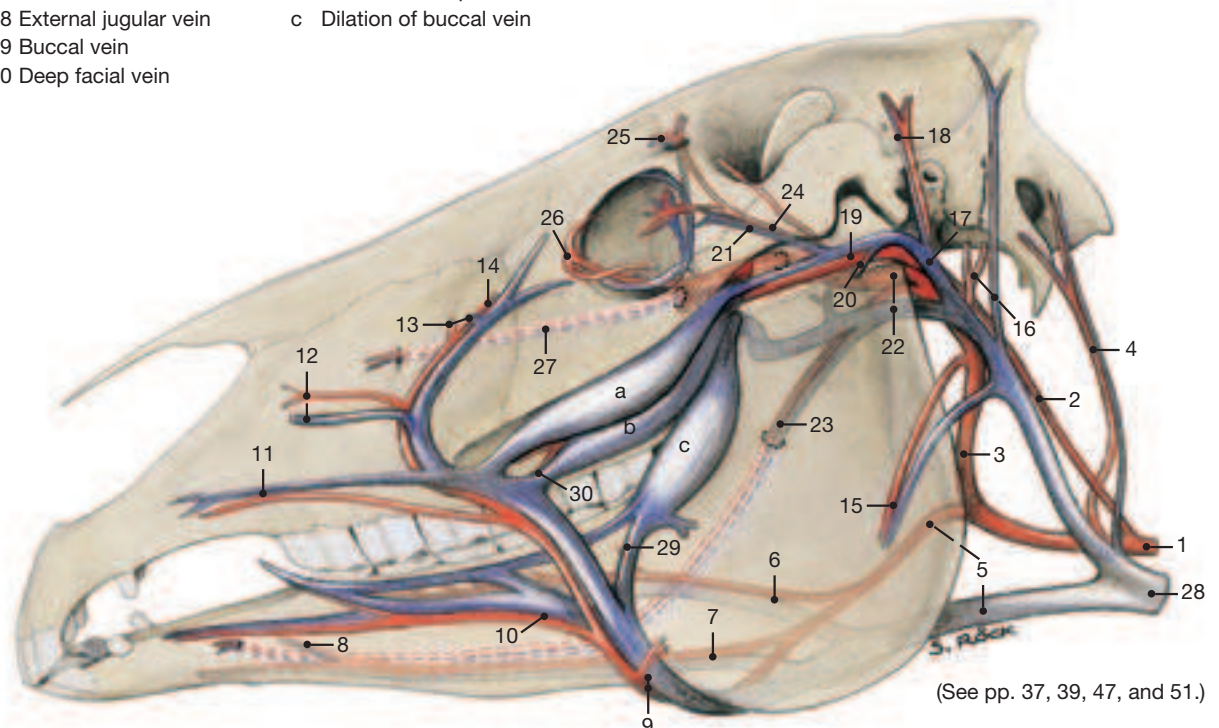
Only two of the numerous ear muscles warrant mention. The long **parotidoauricularis** (28) lies on the lateral surface of the parotid gland and passes dorsally to the auricular cartilage. The **cervicoauricularis supf.** (29), caudomedial to the ear, is innervated by both the facial (VII) and the great auricular (C2) nerves. This is important in the diagnosis of facial paralysis; the ear, contrary to expectation, remains elevated by the activity of the muscle from its partial supply by the second cervical nerve.

Blood Vessels of the Head

- 1 Common carotid a.
- 2 Internal carotid a.
- 3 External carotid a.
- 4 Occipital a. and v.
- 5 Linguofacial a. and v.
- 6 Lingual a. and v.
- 7 Submental a. and sublingual v.
- 8 Sublingual a.
- 9 Facial a. and v.
- 10 Inferior labial a. and v.
- 11 Superior labial a. and v.
- 12 Lateral nasal a. and v.
- 13 Dorsal nasal a. and v.
- 14 Angularis oculi a. and v.
- 15 Masseteric a. and v.
- 16 Caudal auricular a. and v.
- 17 Supf. temporal vein
- 18 Rostral auricular a. and v.
- 19 Transverse facial a. and v.
- 20 Dorsal masseteric vein
- 21 Inferior and superior lateral palpebral veins
- 22 Maxillary a. and v.
- 23 Inferior alveolar a. and v.
- 24 External ophthalmic a.
- 25 Supraorbital a. and v.

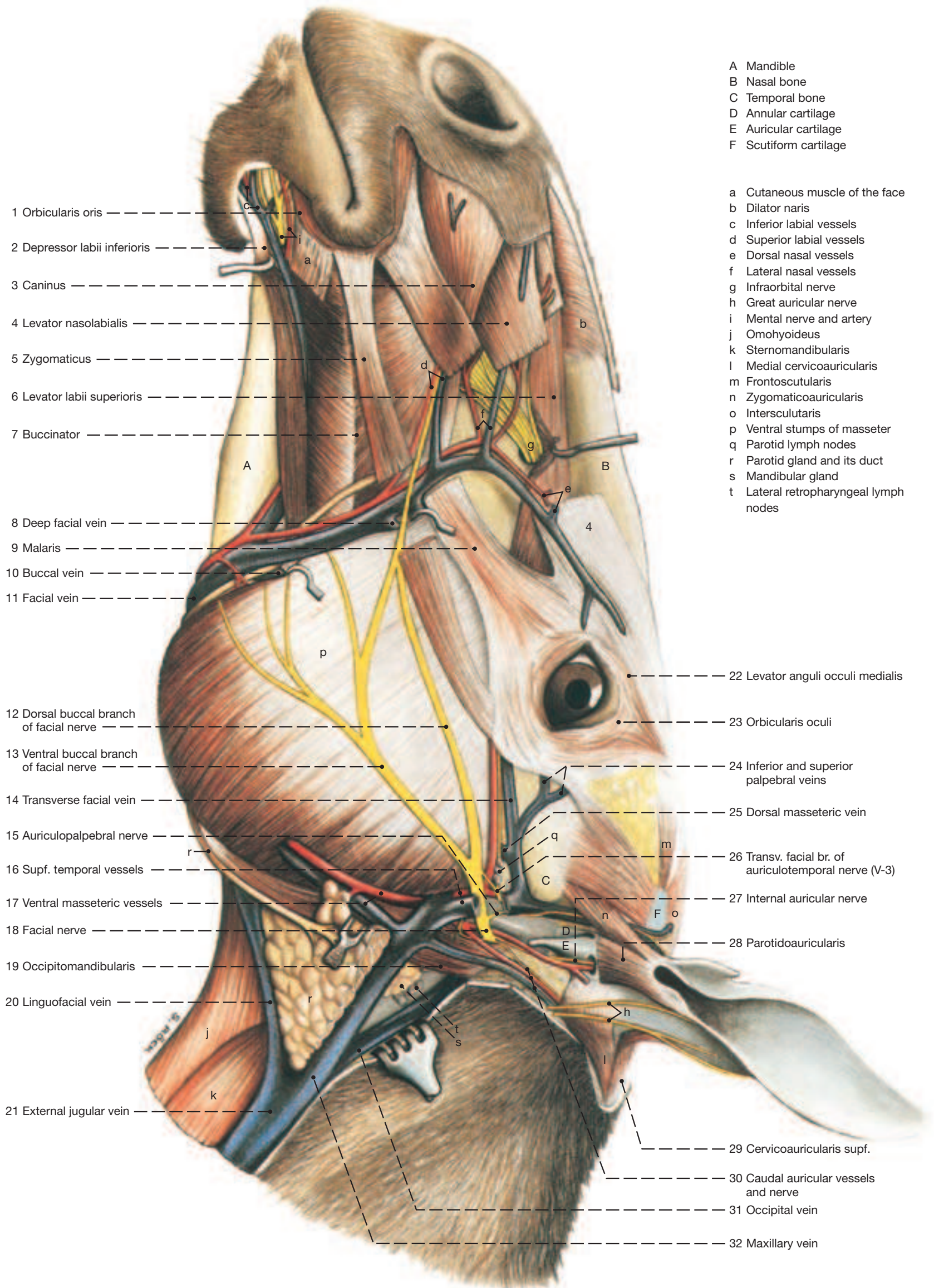
- 26 Malar a.
- 27 Infraorbital a. and v.
- 28 External jugular vein
- 29 Buccal vein
- 30 Deep facial vein

- a Dilation of transverse facial vein
- b Dilation of deep facial vein
- c Dilation of buccal vein



(See pp. 37, 39, 47, and 51.)

Supf. Structures of the Head



4. Trigeminal Nerve (V-3 and V-2), Muscles of Mastication, Salivary Glands, and Lymphatic Structures

Clinical and Functional Anatomy p. 149–150

To duplicate the dissections on the opposite page that show the structures to be described most advantageously, one has to proceed as follows. The vessels and nerves and the muscles innervated by the facial nerve that overly the temporalis and masseter are removed. The masseter is removed in layers to demonstrate its oblique and vertical fibers, its prominent internal tendon sheets, and its innervation (masseteric nerve, from V-3) entering the muscle from immediately rostral to the temporomandibular joint. This exposes the dilated segments of the **buccal (3)**, **deep facial (2)**, and **transverse facial (1) veins**. The zygomatic arch is removed following three transverse saw cuts: I. At the temporomandibular joint, II. ventral to the orbit, and III. through the zygomatic process of the frontal bone. Before disarticulating the temporomandibular joint, the temporalis muscle is detached from the coronoid process of the mandible when the innervation of the muscle by the deep temporal nerves will be noted. The mandible is transected at the level of the first cheek tooth. All structures attaching on the medial surface of the mandible are cut close to the bone and the mandible is forcefully lifted laterally and disarticulated by cutting the joint capsule of the temporomandibular joint. The **articular disc (22)** of the joint is thick and compensates for the incongruency of the articular surfaces while permitting considerable movement to the joint. The temporomandibular joint lies several cm dorsal to the occlusal surface of the cheek teeth, enhancing the lever action of the masticatory muscles.

a) The **TRIGEMINAL NERVE** conforms to the general mammalian pattern regarding its distribution, fiber types, and additions of parasympathetic fibers (see p. 108/109).

2 The **mandibular nerve (V-3; 23)** innervates the skin and the oral mucous membrane, and in contrast to the first two principal trigeminal branches (V-1 and V-2) carries also motor fibers which give rise to the following nerves: The masticatory nerve divides into the **deep temporal (6)** and **masseteric nerves (7)** for the respective muscles of mastication. The medial and lateral pterygoid muscles, the tensor tympani and tensor veli palatini also receive like-named nerves from the mandibular nerve. The **mylohyoid nerve (15)** supplies the mylohyoideus and the rostral belly of the digastricus, and with a cutaneous branch supplies the skin in the vicinity of the chin. The following branches of the mandibular nerve do not contain motor fibers to skeletal muscles: The **buccal nerve (28)**, with both sensory and parasympathetic fibers (the latter from N.IX via the otic ganglion), passes to the mucous membrane of the mouth and to the buccal glands. The **auriculotemporal nerve (21)** passes caudally to temporal skin and parotid gland to supply sensory and parasympathetic (from N.IX via the otic ganglion) innervation. The sensory **lingual nerve (13)** receives sensory and parasympathetic additions via the **chorda tympani (26)**; it innervates the rostral two thirds of the tongue and, from the parasympathetic inflow, the sublingual and mandibular salivary glands. The purely sensory **inferior alveolar nerve (25)** enters the mandibular canal on the medial surface of the mandible. It supplies the lower teeth and, after emerging from the mental foramen, innervates the skin of the lower lip and chin (mental nerve; see p. 37.i).

3 The **maxillary nerve (V-2; 27)** is sensory but receives parasympathetic fibers from the facial nerve via the pterygopalatine ganglion. It gives rise to the zygomatic nerve (see p. 41), the greater and lesser palatine nerves, and the caudal nasal nerve. Its rostral continuation is the very large **infraorbital nerve (27')** that, still within the infraorbital canal, detaches branches for the upper teeth. After emerging from the infraorbital foramen (site for nerve block), the infraorbital nerve with large branches supplies sensory innervation to the lips, nostrils, and the nasal vestibule. (For the **ophthalmic nerve (V-1)** of the trigeminal nerve see p. 41.)

7 b) The **MUSCLES OF MASTICATION** and several **SUPF. MUSCLES OF THE INTERMANDIBULAR SPACE** are innervated by the mandibular nerve (V-3). (The digastricus in addition receives supply from the facial nerve.) Of the external masticatory muscles, the **masseter (9)**, regarded as the strongest muscle of this group, is more robust than the **temporalis (11)**. Its origin lies considerably lateral to its termination on the mandible, while its supf. fibers run obliquely caudoventrally but deeper ones run nearly vertically. These features are responsible for the lateral and rotational chewing movements of the horse, especially when only the masseter of one side is active at the time. The relative "looseness" of the temporomandibular joint favors these mandibular excursions. Regarding masticatory move-

ments and unilateral action, the same can be said for the **medial and lateral pterygoideus muscles (12)** on the medial surface of the mandible.

The group of **supf. muscles occupying the intermandibular space** comprises the **mylohyoideus (15)**, **digastricus (17)**, and the **occipitomandibularis (24)**. The last-named, extending from the paracondylar process to the caudal border of the mandible, may be regarded as a part of the caudal belly of the digastricus; both are innervated by the facial nerve. As they separate, the caudal digastricus belly is succeeded rostrally by an intermediate tendon that passes through a split in the termination of the **stylohyoideus (14)**. The tendon then joins the cranial belly which is innervated by the mandibular nerve (V-3) and which ends on the ventral border of the mandible opposite the last three cheek teeth.

c) The **MAJOR SALIVARY GLANDS** comprise the parotid, mandibular, sublingual (polystomatic), and the buccal glands.

The **parotid gland (8)** is the largest salivary gland of the horse. It occupies the space between the caudal border of the mandible, the wing of the atlas, and the base of the ear, and ventrally it extends to the linguofacial vein. Its lateral surface is covered by fascia that gives origin to the band-like parotidoauricularis (see p. 37.28). The (serous) secretion of the gland is collected by several radicles which combine to form the **parotid duct (8)**. This accompanies the facial artery and vein, and with them winds around the ventral border of the mandible to gain the lateral surface of the face. The duct opens into the oral vestibule opposite the 2nd or 3rd upper cheek tooth. The deep relations of the parotid gland are the maxillary vein; the internal and external carotid arteries; the facial, glossopharyngeal, and hypoglossal nerves, as well as the vagosympathetic trunk; and the guttural pouch. Some of the vessels and nerves are actually imbedded in the tissue of the gland. One of the surgical approaches to the guttural pouch is through Viborg's triangle which is defined on p. 46.

The thin **mandibular gland (10)** extends in a curve from the basi-hyoid to the atlantal fossa and is covered laterally by the parotid gland, the insertion tendon of the sternomandibularis, the digastricus, and the maxillary vein. Its medial relations include the larynx, common carotid artery and vagosympathetic trunk (with branches), and the guttural pouch. The **mandibular duct (10)** leaves the concavity of the gland and passes onto the deep surface of the mylohyoideus where it follows the medial aspect of the sublingual gland to the sublingual caruncle on the floor of the mouth a few cm caudal to the incisors.

The (polystomatic) **sublingual gland (18)** lies directly under the oral mucosa between the tongue and the medial surface of the mandible from the level of the chin to about the third cheek tooth. Its many small excretory ducts open on small papillae below the tongue. A monostomatic sublingual gland is absent in the horse.

The **buccal glands (4)** form two rows along the dorsal and ventral borders of the buccinator muscle. The numerous microscopic **lesser salivary glands** are located in the lips, tongue, and soft palate.

d) The **LYMPHATIC STRUCTURES** of the head are peculiar in that lymph collected by the parotid and lateral retropharyngeal nodes is refiltered by the medial retropharyngeal ones, and lymph passing through the medial retropharyngeal and mandibular lymph nodes is refiltered by the cranial deep cervical nodes before it travels along the trachea (tracheal trunk) to the large veins at the thoracic inlet.

The **parotid lymph nodes (5)** lie ventral to the temporomandibular joint under the rostral border of the parotid gland.

The **mandibular lymph nodes (16)** of both sides form an easily palpable, large V-shaped mass (open caudally) in the intermandibular space a little caudal to the level where the facial artery crosses the ventral border of the mandible.

The **lateral retropharyngeal lymph nodes (19)** lie deep to the parotid gland between the dorsal end of the mandibular gland and the occipitomandibularis against the lateral surface of the guttural pouch.

The **medial retropharyngeal lymph nodes (20)** continue the chain of the preceding nodes ventrally and cranially; they lie dorsolateral on the pharynx and deep to the stylohyoid bone.

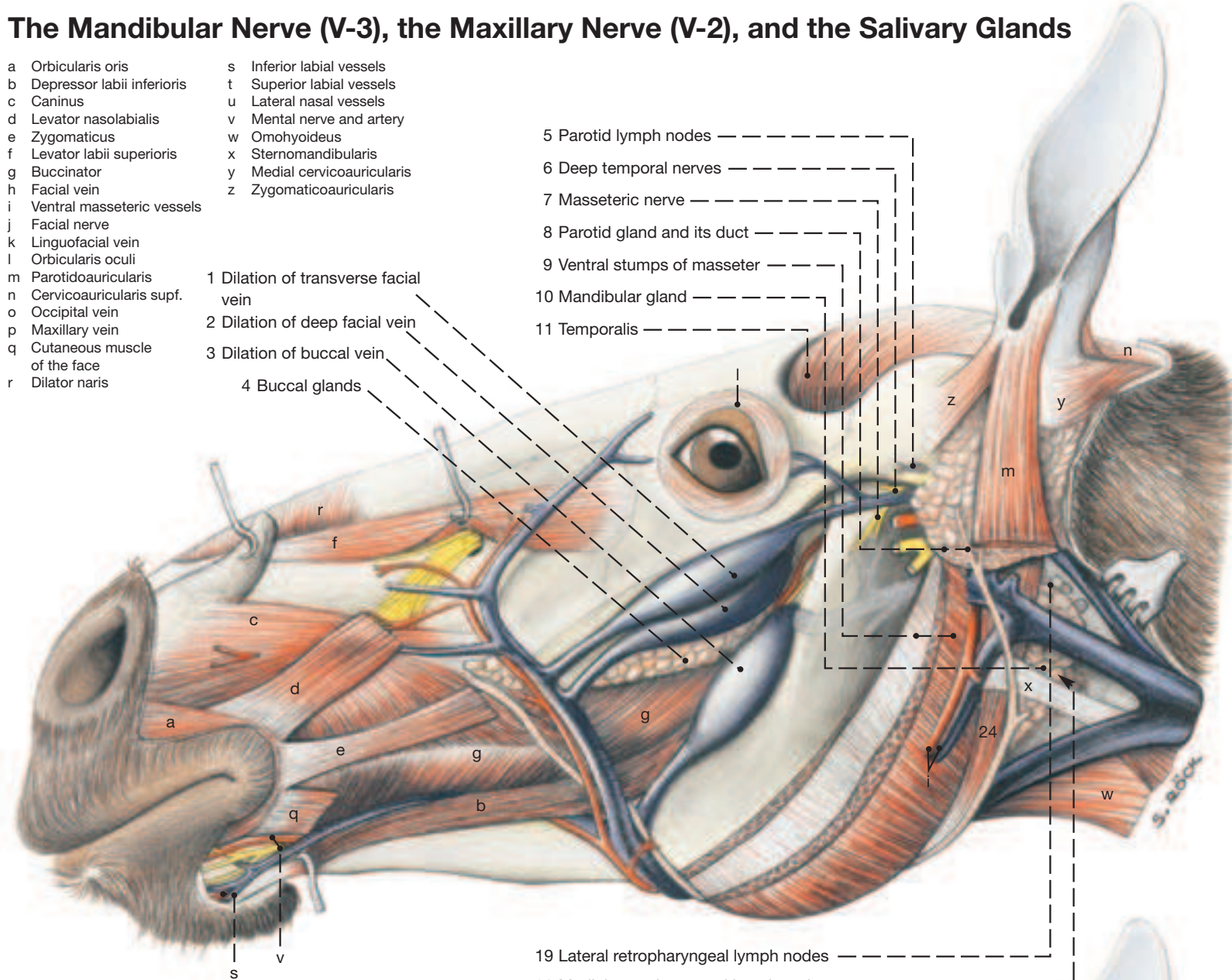
The Mandibular Nerve (V-3), the Maxillary Nerve (V-2), and the Salivary Glands

- a Orbicularis oris
- b Depressor labii inferioris
- c Caninus
- d Levator nasolabialis
- e Zygomaticus
- f Levator labii superioris
- g Buccinator
- h Facial vein
- i Ventral masseteric vessels
- j Facial nerve
- k Linguofacial vein
- l Orbicularis oculi
- m Parotidoauricularis
- n Cervicoauricularis supf.
- o Occipital vein
- p Maxillary vein
- q Cutaneous muscle of the face
- r Dilator naris

- s Inferior labial vessels
- t Superior labial vessels
- u Lateral nasal vessels
- v Mental nerve and artery
- w Omohyoideus
- x Sternomandibularis
- y Medial cervicoauricularis
- z Zygomaticoauricularis

- 1 Dilation of transverse facial vein
- 2 Dilation of deep facial vein
- 3 Dilation of buccal vein
- 4 Buccal glands

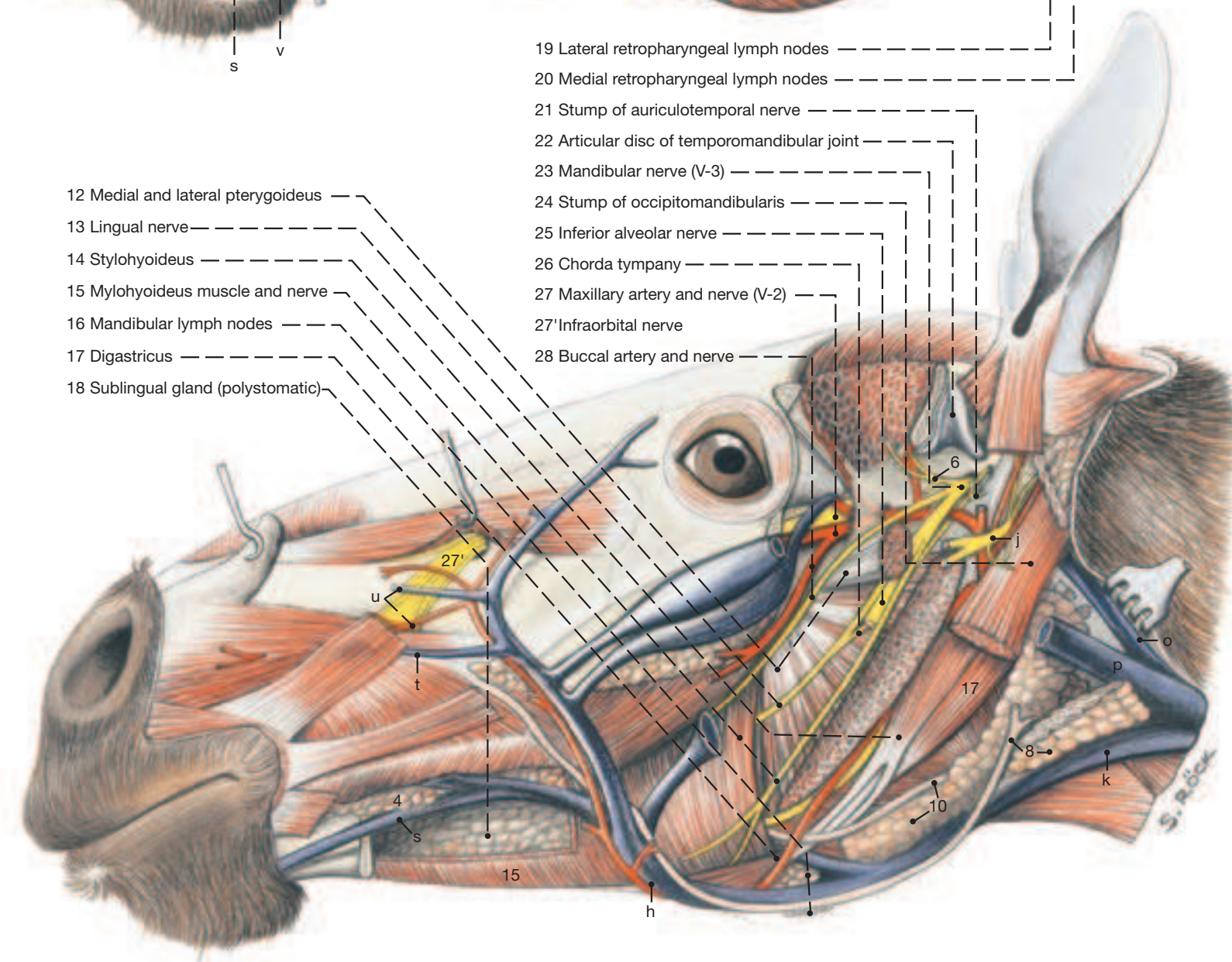
- 5 Parotid lymph nodes
- 6 Deep temporal nerves
- 7 Masseteric nerve
- 8 Parotid gland and its duct
- 9 Ventral stumps of masseter
- 10 Mandibular gland
- 11 Temporalis



- 19 Lateral retropharyngeal lymph nodes
- 20 Medial retropharyngeal lymph nodes

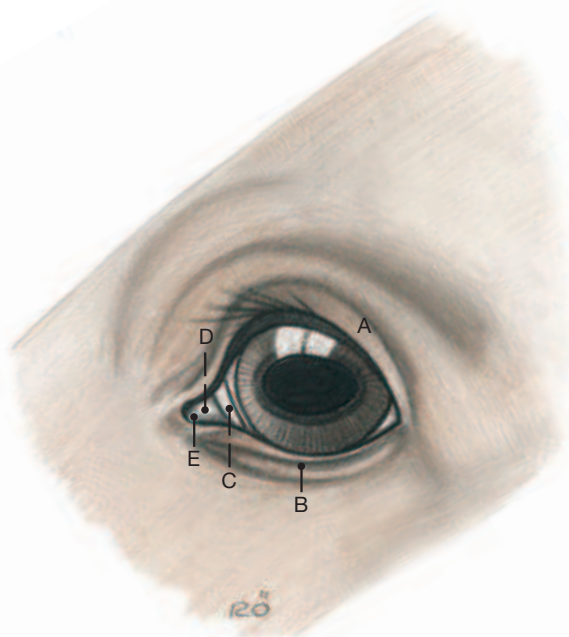
- 12 Medial and lateral pterygoideus
- 13 Lingual nerve
- 14 Stylohyoideus
- 15 Mylohyoideus muscle and nerve
- 16 Mandibular lymph nodes
- 17 Digastricus
- 18 Sublingual gland (polystomatic)

- 21 Stump of auriculotemporal nerve
- 22 Articular disc of temporomandibular joint
- 23 Mandibular nerve (V-3)
- 24 Stump of occipitomandibularis
- 25 Inferior alveolar nerve
- 26 Chorda tympany
- 27 Maxillary artery and nerve (V-2)
- 27' Infraorbital nerve
- 28 Buccal artery and nerve



5. Adnexa of the Eye

- 1 The **ADNEXA** of the eye comprise the ocular muscles and orbital fasciae, the eyelids and conjunctiva, and the lacrimal apparatus.
- 2
- 3 I. The **eyelids** (A, B in the text Fig. below) consist of three layers. The outermost is skin, covered with short hairs. In the middle is a fibromuscular layer that includes the striated orbicularis oculi, the orbital septum and fibrous tarsus, the smooth tarsal muscle, and (only in the upper lid) the aponeurosis of the levator palpebrae. The deep layer which touches the eyeball is the palpebral **conjunctiva** that, with the bulbar conjunctiva and the cornea, lines the **conjunctival sac**. The upper and lower limits of the conjunctival sac are the **fornices** situated roughly opposite the base of the respective lid (see also p. 43).
- 4 The **third eyelid** (C) occupies the medial angle of the eye. It consists of a T-shaped plate of cartilage that is covered on both of its exposed surfaces with conjunctiva. The stem of the T lies between the eyeball and the medial wall of the orbit while the crossbar stiffens the free edge of the lid.
- 5



II. The **lacrimal apparatus** (see Fig. below) conforms to the general mammalian plan. The **lacrimal gland** (2) lies dorsolateral on the eyeball and between it and the zygomatic process of the frontal bone, which reaches the zygomatic arch to complete the bony orbital margin. The largest accessory lacrimal gland is the **gland of the third eyelid** that surrounds the stem of the T-shaped cartilage medial to the eyeball. Minute ducts direct the lacrimal fluid into the dorsal fornix and into the space between the third eyelid and the globe. Blinking movements spread the fluid over the cornea to keep it moist, after which the fluid drains to the medial angle where it forms the so-called **lacrimal lake** (E) that surrounds, moat-like, a prominent **lacrimal caruncle** (D). From here the lacrimal fluid is conveyed via upper and lower **lacrimal puncta** (J, K), **lacrimal canaliculi** (I), **lacrimal sac** (H); and finally through the long **naso-lacrimal duct** (G) to the **nasolacrimal orifice** (F) in the floor of the nostril.

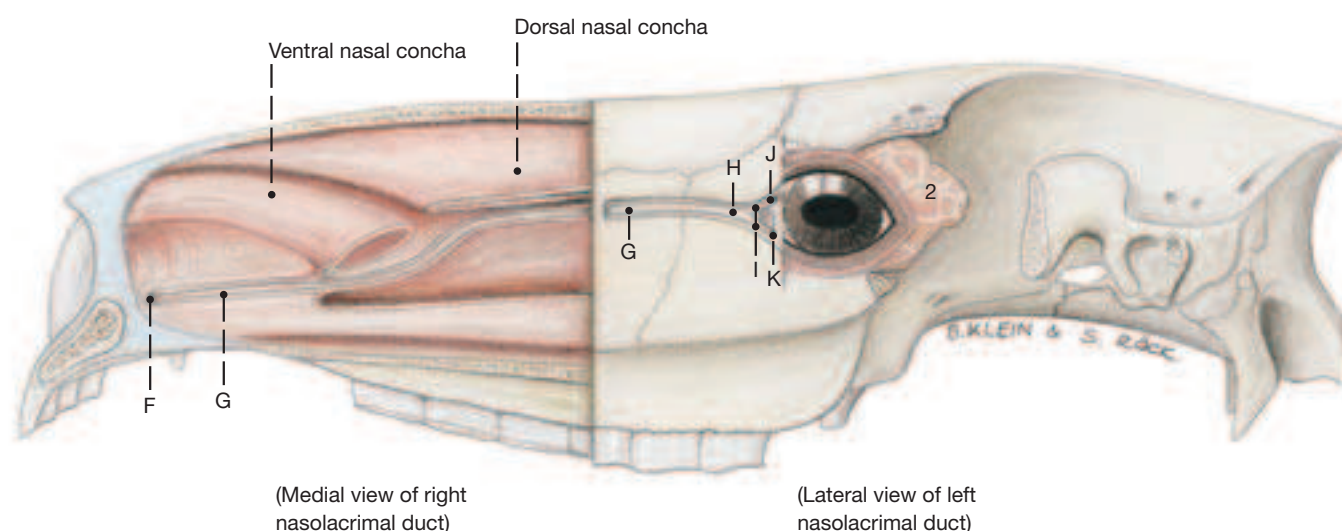
III. The cone of **ocular muscles** is surrounded by the fibroelastic **periorbital** (18) which on its interior surface presents the trochlea that redirects the dorsal oblique muscle. The **zygomatic nerve** (V-2) courses ventrolateral to the ocular muscles and after leaving the orbit becomes the **zygomaticofacial nerve** (16) that supplies the lower eyelid and a little adjacent skin. According to most authors, the **zygomaticotemporal nerve** (10) arises from the ophthalmic nerve, sends a branch to the **lacrimal nerve** (V-1), and passes caudally deep to the zygomatic process of the frontal bone; other authors consider it a branch of the **maxillary nerve** (V-2).

The ophthalmic nerve (V-1) gives off the mostly double **lacrimal nerve** (12), the **nasociliary nerve** (21), and the **frontal nerve** (9). The nasociliary in turn branches into **infratrochlear** (19), **ethmoidal** (20), and **long ciliary nerves** (22); the frontal, after emerging from the supraorbital foramen as the **supraorbital nerve** (8), supplies the area of the forehead between the eyes.

The muscles of the eye arise deep in the orbit from the vicinity of the optic foramen, except the ventral oblique which takes origin from a depression in the ventromedial wall of the orbit. They end on the sclera near or slightly anterior to the equator, but the levator palpebrae leaves the orbit and ends in the upper lid.

The majority of the ocular muscles are innervated by the **oculomotor nerve** (N III). They are the **medial** (14), **ventral** (6), and **dorsal** (4) **rectus muscles**, the **ventral oblique** (7), the **levator palpebrae** (3) and most of the cone-shaped **retractor bulbi** (13). The **dorsal oblique** (1) is supplied by the **trochlear nerve** (N IV; 11); and the **lateral rectus** (5) and part of the retractor bulbi are activated by the **abducent nerve** (N VI; 23).

Lacrimal Apparatus, exposed by sculpting certain facial bones



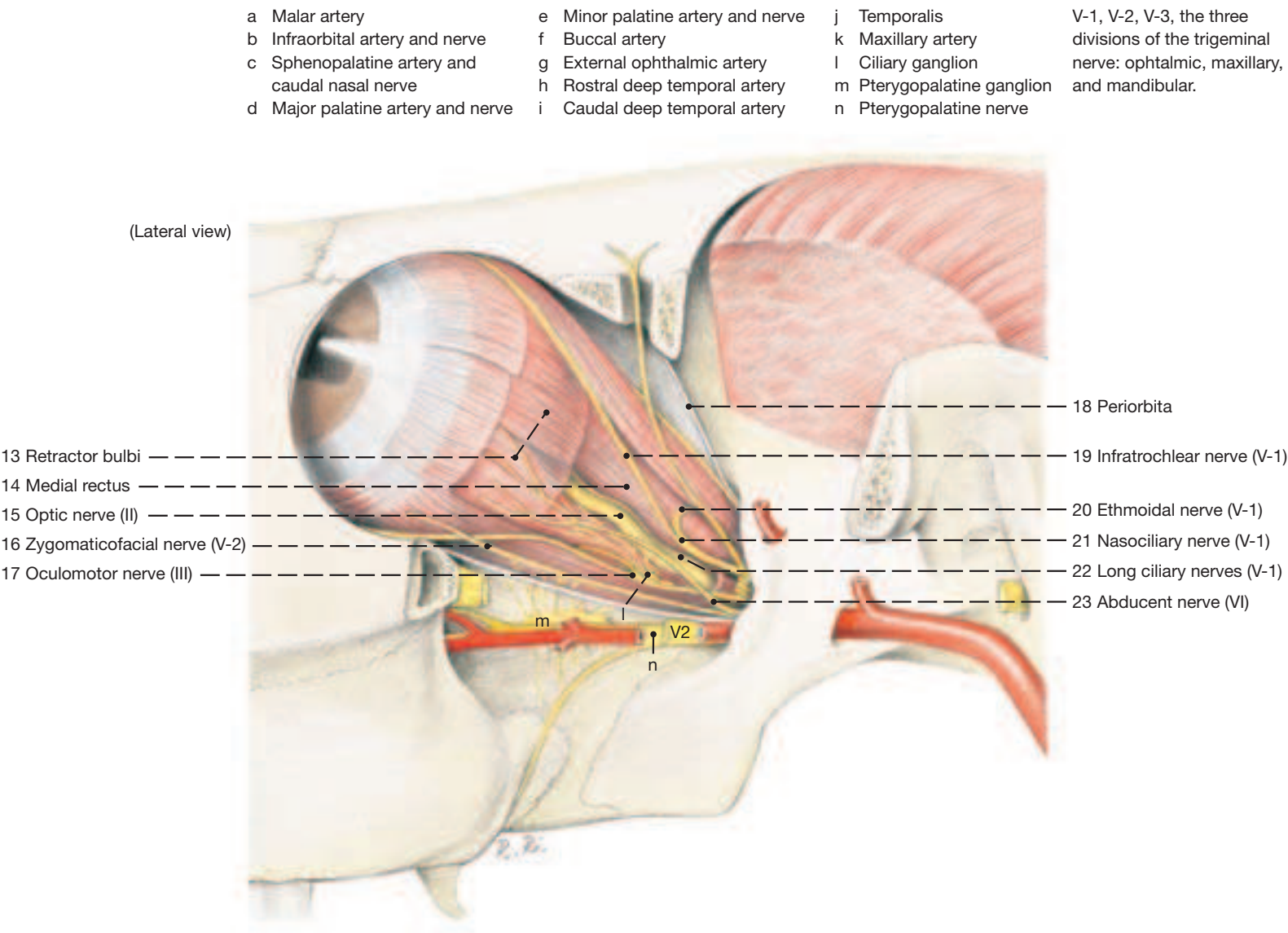
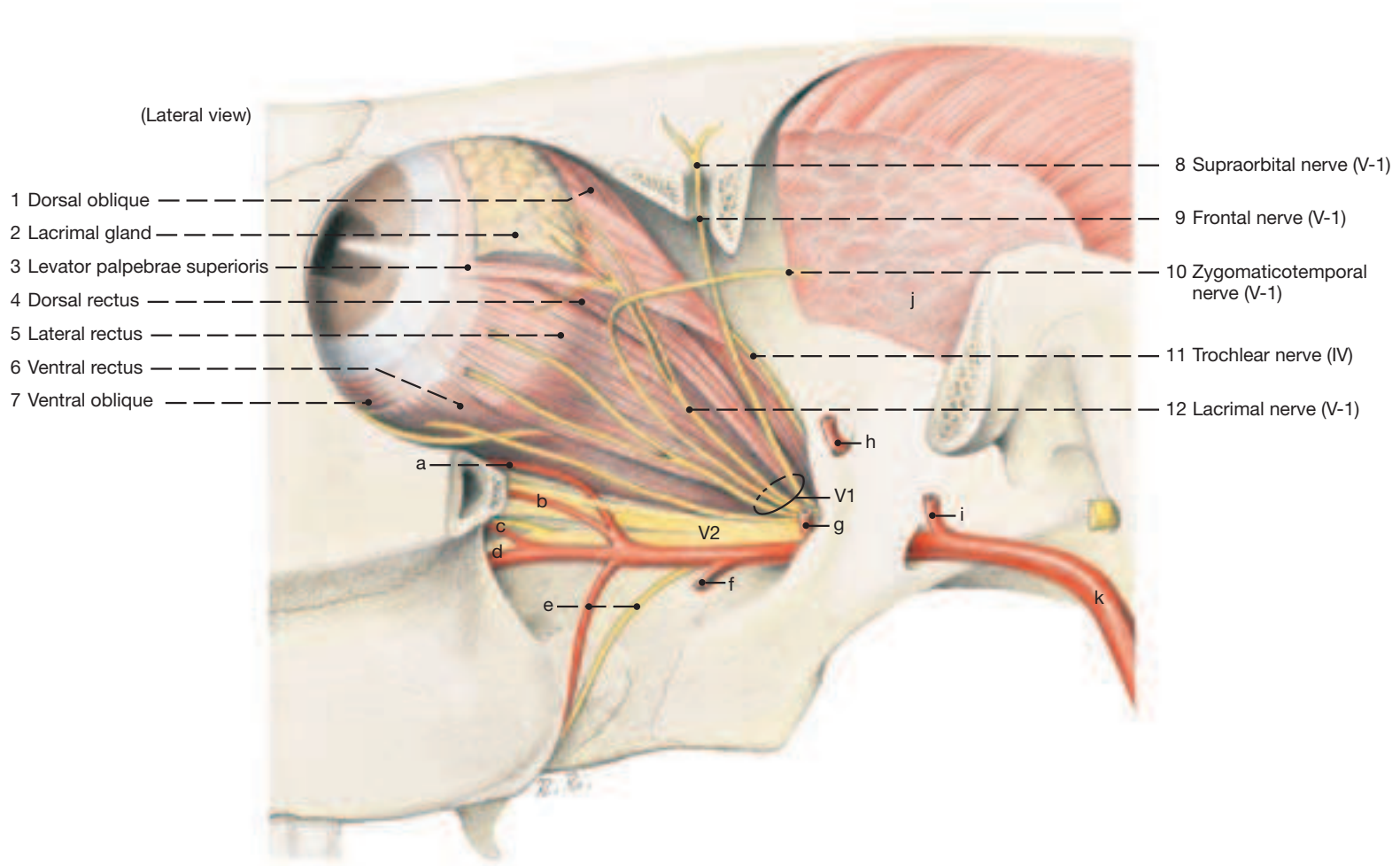
A Upper lid
B Lower lid
C Third eyelid

D Lacrimal caruncle
E Lacrimal lake
F Nasolacrimal orifice

G Nasolacrimal duct
H Lacrimal sac
I Lacrimal canaliculi

J Upper punctum lacrimale
K Lower punctum lacrimale
2 Lacrimal gland

Muscles of the Eyeball and Cranial Nerves II, III, IV, V-1*, V-2*, and VI



6. The Eye

The eyeball of the horse is rostrocaudally compressed. For spatial orientation, the pupil and the optic nerve (among others) are used as reference points. The pupil is transversely elliptical. Prominent, dark projections (**iridic granules** –5) protrude from the upper and lower margins of the pupil; those on the lower margin are markedly smaller. The granules are covered on their posterior surface by the pigmented blind part of the retina and are vascularized by vessels from the stroma of the iris. The optic nerve emerges ventral and temporal to the posterior pole of the eyeball.

One eye sectioned on the equator and meridionally, one can study the external (fibrous) tunic, the middle (vascular) tunic, and the internal tunic (retina).

I. The **external (fibrous) tunic** consists of sclera and cornea. The **cornea** (3) is the translucent part that bulges the anterior pole of the globe forward, while the opaque bluish-white **sclera** (1) forms the much larger posterior part of the eye. Where the two meet is a slight indentation known as the **limbus** (2).

The sclera is a tough, collagenous mantle which gives the eyeball its constant shape, an important requirement for acute vision. Though “hard” to the touch and unyielding, the sclera does not break or shatter, but in accidents it can be punctured or cut allowing the gelatinous interior to escape.

The healthy cornea is translucent. Should it dry out, because of the lack of lacrimal fluid, it becomes opaque. This also happens when its posterior epithelial layer is injured and allows aqueous humor to permeate superficial layers. Following death, the cornea turns gray and loses its translucency.

II. The **middle (vascular) tunic** is firmly attached to the internal surface of the sclera; it comprises three zones: choroid, ciliary body, and iris.

The **choroid** (20) lines considerably more than the posterior half (fundus) of the eye. It consists of an outer layer of large vessels and a thin inner layer of capillaries. Over the dorsal part of the fundus the choroid forms the roughly triangular light-reflecting **tapetum lucidum** (21). This is a compact and regularly arranged fibrous layer that causes light to be fractioned into a yellowish- or bluishgreen iridescence. The border of the tapetum is dark brown.

The **ciliary body** is the anterior continuation of the choroid. It forms a peripheral **ring** (13) which has numerous small **folds** (14) and is markedly narrower nasally, and a central **crown** (15) of larger processes (16) which give rise to the **zonular fibers** (12) that suspend the lens. The ciliary body produces the aqueous humor. Between the ciliary body and the sclera is the weak **ciliary muscle** (k) that acts on the suspensory apparatus of lens and causes accommodation (increase in thickness and convexity of the lens in order to focus an object on the retina).

The third and smallest zone of the vascular tunic is the **iris** (4) which lies in front of the lens. Its anterior surface is usually brown in horses, and its stroma contains the sphincter (j) and dilator (i) of the pupil – muscles derived from ectoderm – that regulate the size of the **pupil** (6) and thus the amount of light admitted into the eye. The already mentioned iridic granules as well as the ciliary body, because of their rich blood supply, are well suited to produce the aqueous humor. The granules, in addition, help protect the eye from bright sunlight and thus assist the sphincter of the pupil.

III. The **internal tunic** of the eyeball is known as the **retina** which lines the interior of the eyeball from the pupil to the optic disc where the fibers that form the optic nerve pass through the sclera. The portion of the retina on the posterior surface of iris and **ciliary body** and extending to a vague line known as **ora serrata** (17) is “blind” (**pars ceca**; –18) because it is devoid of photoreceptors and direct light does not reach it. The remaining **pars optica** (19) extends from the ora serrata to the optic disc. It has nine layers and contains the light-sensitive cells, in the form of rods and cones. The grayish optical part can be lifted off the external (tenth) layer of the retina consisting of a heavily pigmented epithelium that colors the fundus of the opened eye dark brown. The pigmented epithelium over the

tapetum lucidum of the choroid is free of pigment however, allowing light to strike the tapetum. This produces the “shine” in the eyes of horses when they face a light at night such as the headlights of an oncoming car.

The **optic disc** (26) lies in the lower temporal quadrant of the fundus. It is here that the axons of the optical part of the retina pass through the sclera to form the **optic nerve** (24). The axons, before penetrating the sclera, are still without myelin sheaths and thus translucent. They receive their sheaths in the optic disc and are tightly packed leaving no room for light receptors. This is why the optic disc is also referred to as the blind spot. As the now myelinated nerve leaves the eyeball, it is covered by two meningeal sheaths that are embedded in fat and surrounded by the retrobulbar eye muscles. Because nerve and eyeball are outgrowths of the diencephalons, the nerve as a continuation of the brain is also covered by the meninges. The tough external sheath (dural component) and the delicate internal sheath (pia mater component) merge directly with the sclera and are separated by an intervaginal space which corresponds with the subarachnoidal space. The ensheathed nerve is slightly undulating to permit movement of the eye. After passing the optic canal right and left optic nerves meet inside the cranial cavity in the optic chiasm. About 80 % of the axons cross here to the other side and accompany the non-crossing fibers of the ipsilateral side in the optic tract to the diencephalon.

IV. The **interior of the eye** presents the anterior and posterior chambers in front of the lens and the vitreous body behind the lens.

IV. The **lens** (7) is suspended enclosed in a **capsule** (8) which is thickest at its equator where the zonular fibers are secured that hold the lens in place. The substance of the lens consists of regularly disposed curved lens fibers whose ends are cemented to neighboring fibers on the anterior and posterior surfaces where these junctions form little stars (radii lentis) that are best observed on fresh specimens.

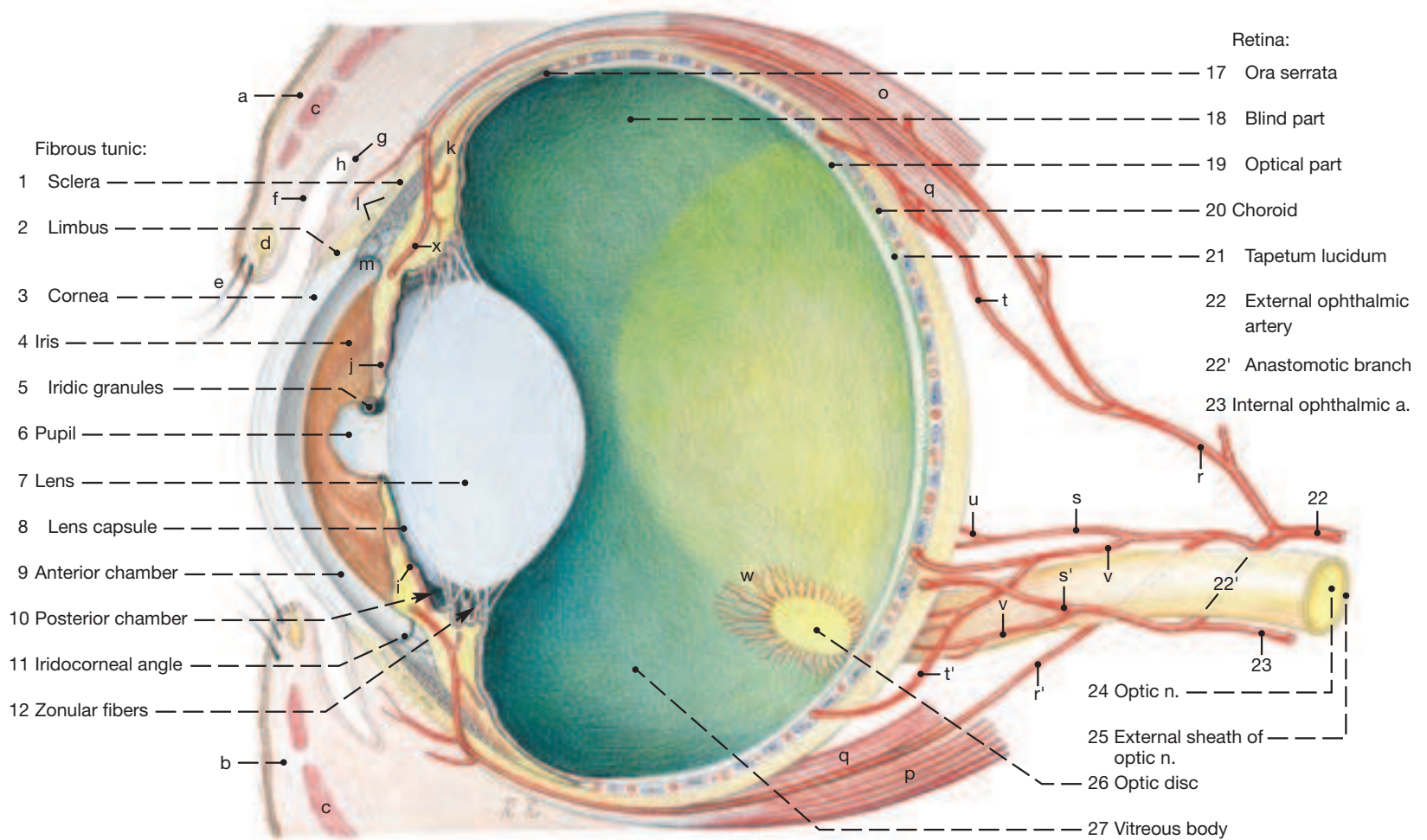
The **anterior chamber of the eye** (9) is relatively large and lies between cornea and iris. It communicates via the pupil with the much smaller **posterior chamber** (10) which is the narrow space between the iris and the lens and the structures that suspend it. Both anterior and posterior chambers are filled with aqueous humor which is produced by the vascular tunic, especially its ciliary body. Production and resorption balance each other in the healthy eye so that the interior pressure of the eyeball is kept constant. The fluid leaves the system through the **iridocorneal angle** (11) and reaches the blood stream via an intrascleral circular venous plexus near the limbus.

The **vitreous body** (27) fills the space posterior to the lens. It is a gel-like mass, consisting mainly of water, but with a translucent stroma of minute fibers. These are condensed into a membrane at the surface. The water content of the vitreous body determines, together with the pressure of the aqueous humor, the intraocular pressure.

V. The **blood supply** of the eye comes from the external and 7 internal ophthalmic arteries which are connected about 3 cm behind the posterior pole of the eyeball by a substantial anastomotic branch. The external **ophthalmic artery** (22) arises from the maxillary artery and, in addition to the anastomosis, gives rise also to the muscular branches for the eye muscles, as well as the lacrimal artery for the lacrimal gland and eyelids. The small **internal ophthalmic artery** (23) comes from the arterial circle of the brain and supplies only the optic nerve which it accompanies through the optic canal. The **anastomotic branch** (22') releases several anterior and posterior ciliary arteries, (r, r', s s', t, t', u) for the choroids, ciliary body, and iris, as well as small choroidoretinal arteries (v), which travel within the external sheath of the **optic nerve** (25) to the posterior pole and detach fine branches to the nearby choroids and minute, short branches to the retina adjacent to the optic disc.

The **principal venous drainage** of the eye uses the anterior ciliary, vorticosae, and choroidoretinal veins which leave the eye next to the limbus, equator, and near the posterior pole, respectively.

Right Eye



a Upper eyelid
b Lower eyelid
c Orbicularis oculi
d Tarsal glands
e Cilia
f Palpebral conjunctiva
g Bulbar conjunctiva
h Fornix

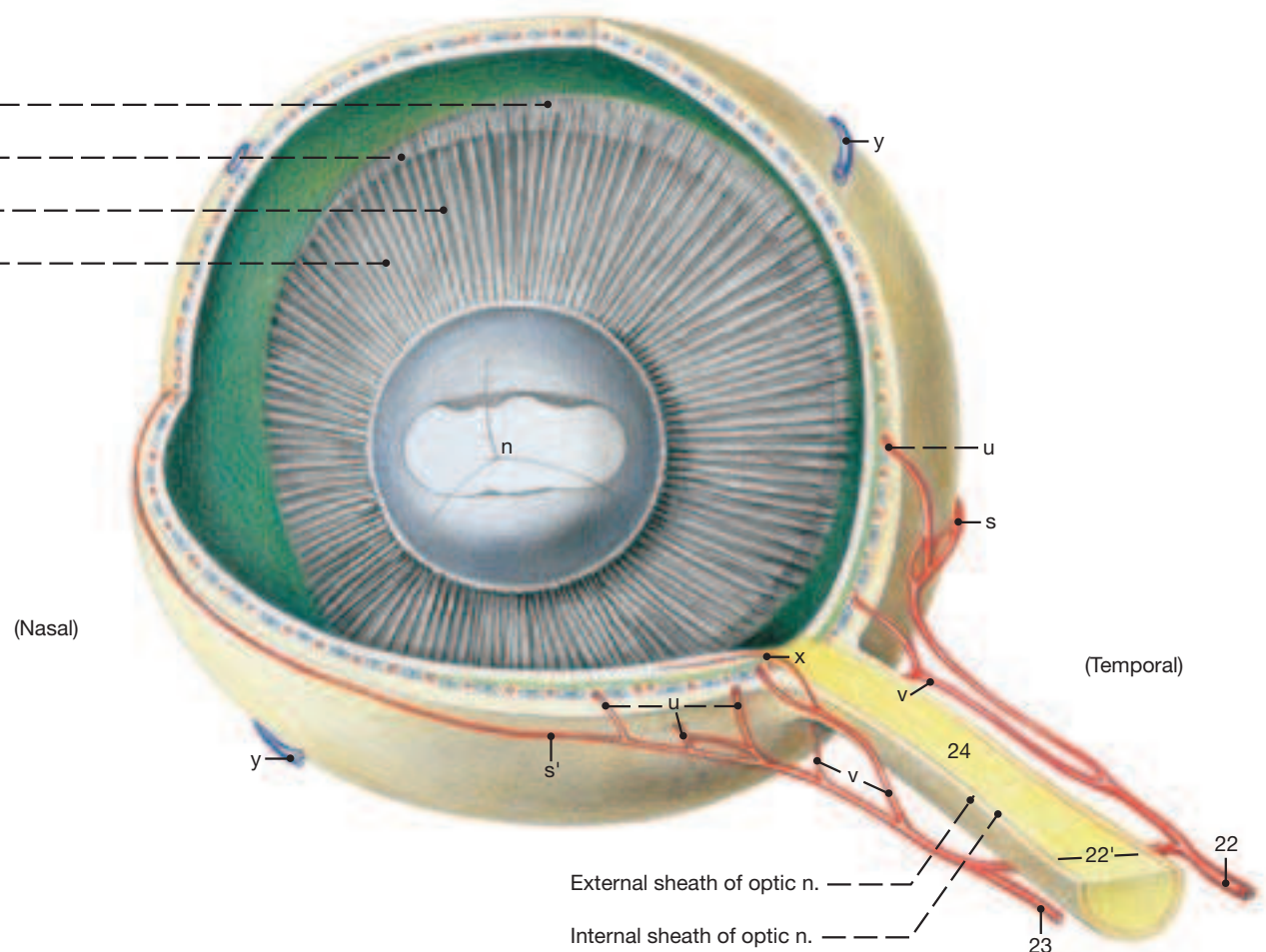
i Dilator of the pupil
j Sphincter of the pupil
j Scleral venous plexus
k Ciliary muscle
l Venous plexus of the sclera
m Pectinate lig. of iridocorneal angle
n Radii lentis
o Dorsal rectus

p Ventral rectus
q Retractor bulbi
r Dorsal anterior ciliary a.
r' Ventral anterior ciliary a.
s Lateral long posterior ciliary a.
s' Medial long posterior ciliary a.
t Dorsal posterior ciliary a.
t' Ventral posterior ciliary a.

u Short posterior ciliary aa.
v choroidoretinal a.
w Retinal vessels
x Major arterial circle of iris
y Vorticose veins

Ciliary body:

- 13 Ciliary crown
- 14 Ciliary folds
- 15 Ciliary crown
- 16 Ciliary processes



a) NOSE

1 I. The **nostrils** (nares) are comma-shaped and widely spaced. They dilate to become spherical in outline when breathing is strenuous. Their medial border is supported by a cartilage (n) while the lateral border is soft and allows for the dilation (p. 45, left lower corner). The nostril is divided by the alar fold (see further on) into a blind-ending **nasal diverticulum** (20) dorsally, and the actual entrance to the nasal cavity, ventrally. The nasal diverticulum is about 8 cm long and occupies the nasoincisive notch. Ordinary skin covered with short fine hairs surrounds the nostrils.

3 II. The **nasal vestibule** (1) leads from the nostril into the paired **nasal cavity**. On its floor about 5 cm internal to the entrance is the **orifice of the nasolacrimal duct** (l) which occasionally is accompanied further caudally by an accessory duct opening. The lining of the vestibule is partly skin with fine hairs and partly mucous membrane; the nasolacrimal orifice is found near the junction of the two.

A longitudinal indentation in the middle third of the dorsal nasal concha hints at an internal division. The rostral end of the concha projects into the nasal vestibule as the **straight fold** (3). The rostral part of the ventral nasal concha divides to form **alar** (4) and **basal** (5) **folds** of which the former, as already mentioned, partitions off the nasal diverticulum dorsal to it. The nasal cavity proper is lined with thick and very vascular respiratory mucosa. Its caudalmost part (fundus) harbors the **ethmoidal conchae** (13) and is lined to a relatively small extent with olfactory epithelium. The caudal portions of the **dorsal** (10) and **ventral** (11) **nasal conchae** are free of interior subdivisions (bullae, cells) and instead are converted caudal to an interior oblique septum to **conchal sinuses** (35.e; θ). The **nasal meatuses** (dorsal (9), middle (7), ventral (6), and common (8) hold to the common pattern.

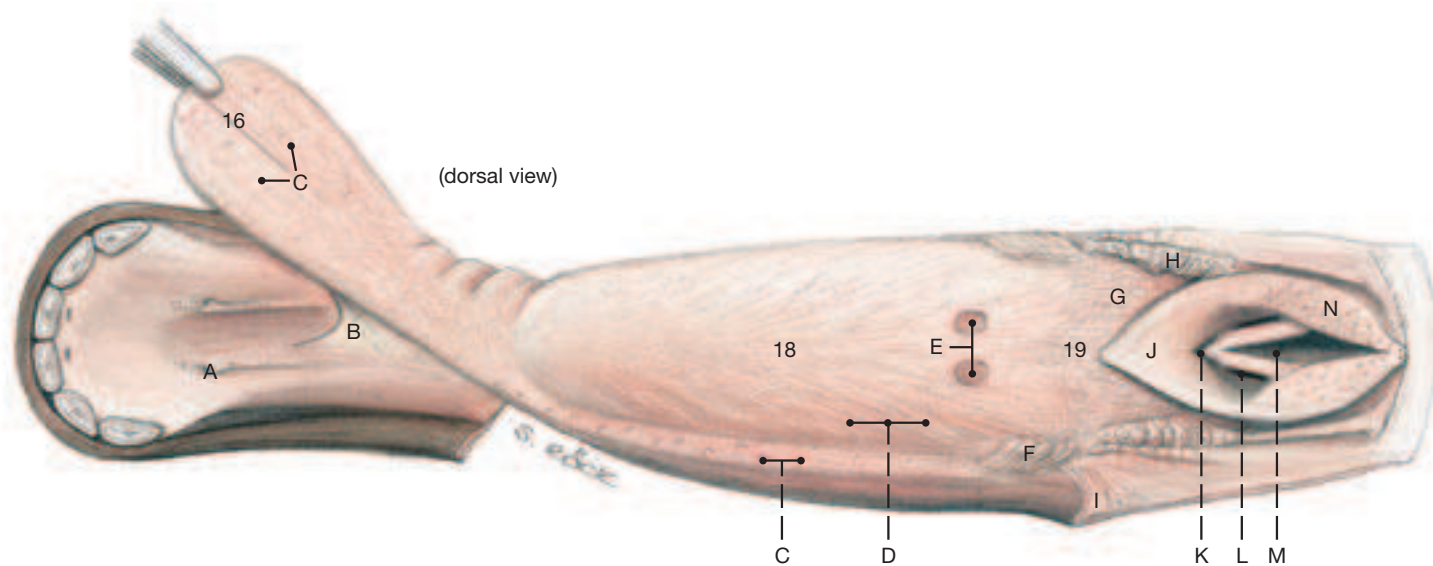
7 The composition of the partly membranous, cartilaginous, and osseous **nasal septum** (2) is shown on p. and the hard palate lies the

paired **vomer** **nasal organ**. (The paranasal sinuses are described on p. 34.)

9 b) The entrance to the **MOUTH** is formed by the very mobile and sensitive lips used by the horse in the selection and prehension of food. The lips are rather short, placing the angle of the mouth forward on the face. This reduces the extent to which the mouth may be opened. Below the lower lip is a ventral elevation (chin) consisting of muscle and adipose tissue. When the mouth is closed, the **oral vestibule** (14) communicates with the **oral cavity proper** (17) via the diastema, the large space on both jaws between the last incisor (I3) and the first cheek tooth in which the male animal carries the canines. The hard palate presents about 18 **transverse ridges** (15) deep to which is a thick venous plexus. This is especially salient near the incisors, and during their replacement is congested with blood; although this swelling is a normal occurrence, it gives some horse owners cause for concern. The **floor of the mouth** (Fig. on this page) is divided caudally by the **lingual frenulum** (B) and more rostrally presents the **sublingual caruncle** (A) upon which the mandibular (salivary) duct opens.

11 c) The **TONGUE** (see Figs. on this and on the opposite page) is remarkably long and has a spatula-shaped **apex** (16). The **body** (18) is thick dorsoventrally while the **root** (19) begins at the level of the **palatoglossal arch** (I) and slopes toward the base of the epiglottis. Numerous **filiform papillae** (D) impart a velvety feel to body and apex. **Fungiform papillae** (C) are present on the dorsal surface of the apex, and in quasi rows also on the lateral surfaces of the body. The two distinct **vallate papillae** (E) mark the junction of body and root, and the **foliate papillae** (F) are situated just rostral to the palatoglossal arches on each side of the tongue. Below the mucous membrane over the body of the tongue lies the median dorsal lingual cartilage that is about 15 cm long and 0.5 cm in diameter.

Tongue



(See p. 47 and 51)

A Sublingual caruncle
B Lingual frenulum
C Fungiform papillae
D Filiform papillae
E Vallate papillae

F Foliate papillae
G Lingual tonsil
H Palatine tonsil
I Stump of palatoglossal
J Epiglottis

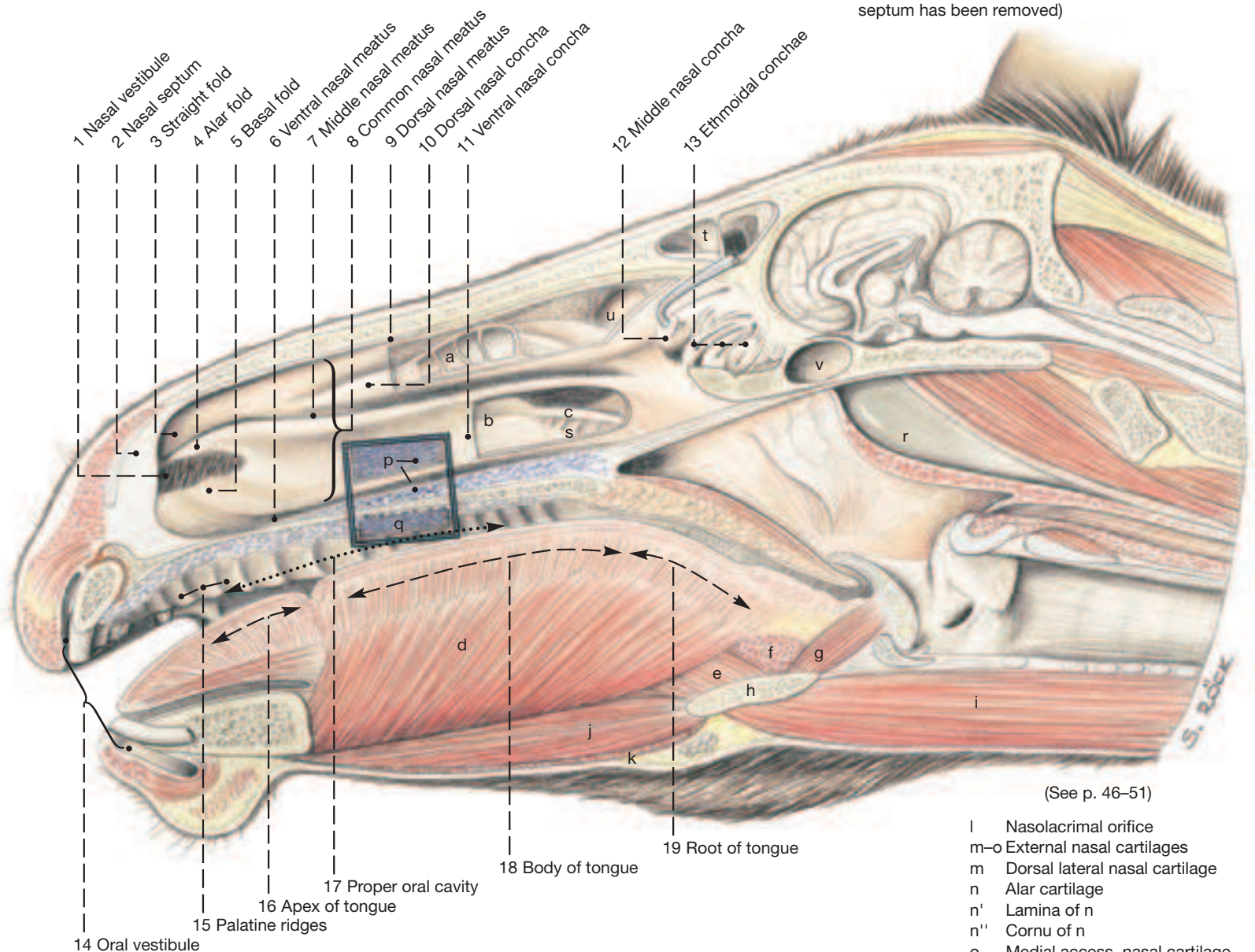
K Median laryngeal recess
L Laryngeal ventricle
M Glottic cleft
N Corniculate process of arytenoid cartilage

16 Apex of tongue
18 Body of tongue
19 Root of tongue

The Nose, Nasal Cavity, and Oral Cavity

- | | |
|--|-------------------------------------|
| a Subdivisions (bullae, cellulae) within dorsal nasal concha | f Hyoideus transversus |
| b Ventral conchal sinus | g Hyoepiglotticus |
| c Infraorbital canal | h Basihyoid and its lingual process |
| d Genioglossus | i Sternohyoideus |
| e Hyoglossus | j Geniohyoideus |
| | k Mylohyoideus |


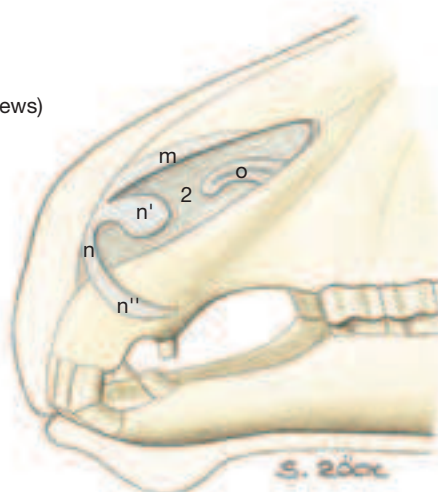
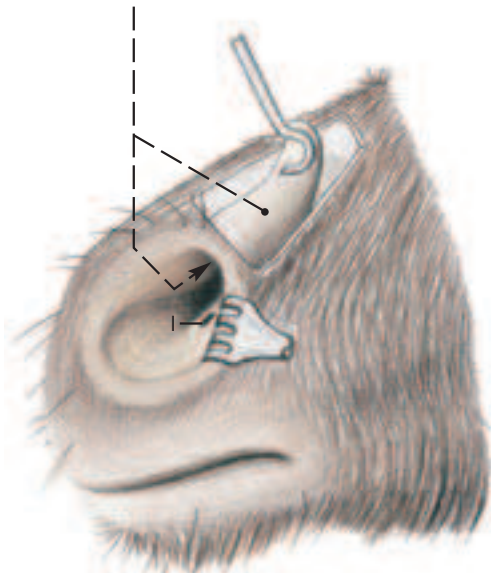
(Median section, the nasal septum has been removed)



(See p. 46-51)

20 Nasal diverticulum

(Lateral views)



8. Pharynx, Guttural Pouch and Larynx

Clinical and Functional Anatomy p. 160–161

These structures need to be studied from both medial and lateral aspects. The guttural pouch is best opened and explored on a median section of the head. This shows its interior and certain vessels and nerves on its surface to best advantage. To examine position and extent of the guttural pouch and of the pharyngeal constrictors, the pterygoids, digastricus, stylohyoideus, occipitomandibularis, and occipitohyoideus are partly, and the mandibular and parotid glands are completely removed.

- 1 a) The **PHARYNX**, following the common plan, comprises an oropharynx, a laryngopharynx, and a nasopharynx. The **oropharynx** (B) continues the oral cavity at the level of the glossopalatine arch and extends to the base of the epiglottis. The **laryngopharynx** (C) continues the oropharynx around the rostral parts of the larynx to be continued itself by the esophagus. It is open dorsally via the **intraparyngeal opening** to the **nasopharynx** (A). During normal breathing the intraparyngeal opening allows the rostral parts of the larynx to protrude into the nasopharynx.

The nasopharynx is dorsal to the soft palate where it continues the ventral nasal meatus through the choanae. It communicates via the **pharyngeal openings of the auditory tubes** (2), the auditory tube itself, and the guttural pouch (see further on) with the middle ear.

- 3 The **soft palate** (3) is about 12 cm long and during normal breathing extends with its free border to the base of the epiglottis. This circumstance makes it very difficult for horses to breathe through their mouth or to vomit. For the same reason vomitus is expelled through the nose. (The reason why vomiting is so rare in horses is related principally to the structure of the stomach; p. 68.)

I. The **pharyngeal muscles**, their innervation and that of the pharyngeal mucosa by the pharyngeal branches of cranial nerves IX and X follow the common pattern (see also p. 51). The muscles of the soft palate are **tensor veli palatini** (7) and **levator veli palatini** (8). The rostral pharyngeal constrictors, which arise on the skull, are **pterygopharyngeus** (9) and **palatopharyngeus** (11). The middle pharyngeal constrictor (from the thyrohyoid) is the **hyopharyngeus** (12). And the caudal pharyngeal constrictors, which arise from the larynx, are **thyropharyngeus** (13) and the **cricopharyngeus** (14). The only dilator of the pharynx is the **stylopharyngeus caudalis** (10).

II. The tonsils concentrated in the pharynx include palatine, pharyngeal, lingual, tubal, and those residing in the soft palate. The **palatine tonsil** (5) is an elongated slightly raised structure, about 10 cm long and 2 cm wide, on the floor of the oropharynx lateral to the median glossoepiglottic fold. The **pharyngeal tonsil** (1) is in the dorsolateral wall of the nasopharynx near the pharyngeal opening of the auditory tube. The **lingual tonsil** (6) is spread over the root of the tongue, and the **tonsil of the soft palate** (4) is a slightly raised area rostrally on the ventral surface of the soft palate. The tubal tonsil, not a discrete organ, is diffuse lymphoid tissue in and around the pharyngeal opening of the auditory tube.

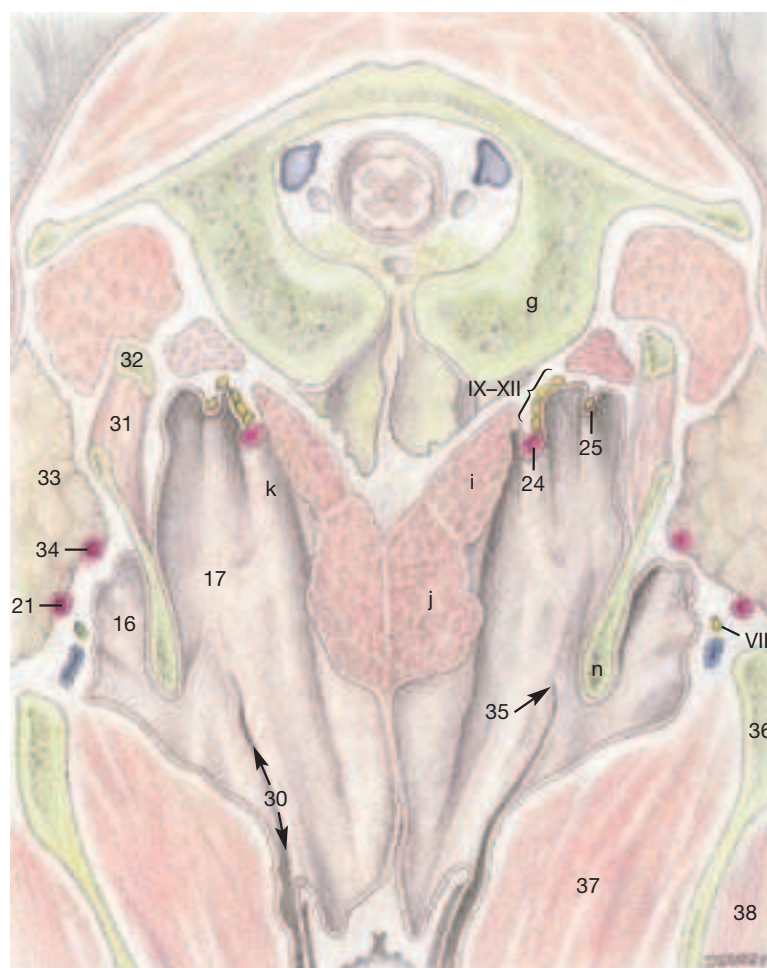
III. The **auditory tube** opens into the lateral wall of the nasopharynx (A) opposite the lateral angle of the eye. The opening is covered medially by the most rostral part of the **tubal cartilage** (15), a flap that is drawn medially by the tensor and levator veli palatini during swallowing. The opening leads into the auditory tube supported by the rest of the tubal cartilage (shaped like an inverted trough) and into the guttural pouch, which is a great expansion of the unsupported ventral wall of the tube. The caudal end of the auditory tube is in addition supported by bone and opens into the tympanic cavity forming the middle ear.

- 5 b) The **GUTTURAL POUCH** is a paired airfilled space with a capacity of 300 to 500 ml. It extends from the base of the skull and the atlas to the nasopharynx. The two pouches touch each other ventral to

the longus capitis muscles where they are separated by a median membrane. The pouch is reflected around the dorsal border of the **stylohyoid bone** (n) which divides it into a small **lateral recess** (16) and a larger **medial recess** (17). The lateral recess is related laterally to the ramus of the mandible, while the medial recess is related laterally to the mandibular and parotid glands. Surgical access to an enlarged pouch is possible through Viborg's triangle. This is formed cranially by the caudal border of the mandible (see p. 39.24), dorsally by the insertion tendon of the sternomandibularis (see p. 37.k), and ventrally by the linguofacial vein (see p. 37.20). Vessels and nerves touching or even indenting the pouch wall, as well as adjacent lymph nodes are of clinical significance. Thus the dorsal wall of the medial recess is related to the **glossopharyngeal nerve** (IX; 28) the **vagus** (X; 26), the **accessory nerve** (XI; 23) and the **hypoglossal nerve** (XII; 29)—as well as the pharyngeal branches of the first two of these nerves—the **sympathetic trunk** (25) with the cranial cervical ganglion, and the **internal carotid artery** (24). The **lateral retropharyngeal lymph nodes** (22) contact the lateral wall of the medial recess; and the **medial retropharyngeal lymph nodes** (27) contact its ventral wall. The dorsocaudal wall of the lateral recess forms relations with the **maxillary vessels** (20), the **external carotid artery** (21) and the **facial nerve** (VII).

Guttural Pouch

(View of the dorsal wall)



- | | |
|-------------------------|---|
| 30 Auditory tube | 35 Tympanic ostium of the auditory tube |
| 31 Occipitohyoideus m. | 36 Ramus of the mandible |
| 32 Paracondylar process | 37 Pterygoideus |
| 33 Parotid gland | 38 Masseter |
| 34 Caudal auricular a. | |

Pharynx, Guttural Pouch, and Larynx

(Brain, see p. 54)

- a Cerebrum
- b Cerebellum
- c Medulla oblongata
- d Spinal cord
- e Nuchal ligament
- f Rectus capitis dorsalis minor
- g Atlas
- h Axis
- i Rectus capitis ventralis
- j Longus capitis
- k Neurovascular fold
- l Longus colli

(Median section)

- 1 Pharyngeal tonsil
- 2 Pharyngeal opening of auditory tube
- 3 Soft palate
- 4 Tonsil of soft palate
- 5 Palatine tonsil
- 6 Lingual tonsil
- 15 Cartilage of auditory tube
- 16 Lateral compartment of guttural pouch
- 17 Medial compartment of guttural pouch
- 18 Laryngeal ventricle
- 19 Median laryngeal recess

- Pharyngeal cavity**
- A Nasopharynx
 - B Oropharynx
 - C Laryngopharynx
 - D Entrance to esophagus

- Laryngeal cavity**
- E Laryngeal vestibule with vestibular fold
 - F Glottis and vocal fold
 - G Infraglottic cavity

- m Palatine glands
- n Stylohyoid bone
- o Thyroid gland
- p Internal parathyroid gland

(Lateral view)

- 7 Tensor veli palatini
- 8 Levator veli palatini
- 9 Pterygopharyngeus
- 10 Stylopharyngeus caudalis
- 11 Palatopharyngeus
- 12 Hyopharyngeus
- 13 Thyropharyngeus
- 14 Cricopharyngeus
- 20 Maxillary artery
- 21 External carotid artery
- 22 Lateral retropharyngeal lymph nodes
- 23 Accessory nerve (XI)
- 24 Internal carotid artery
- 25 Sympathetic trunk
- 26 Vagus (X)
- 27 Medial retropharyngeal lymph nodes
- 28 Glossopharyngeal nerve (IX)
- 29 Hypoglossal nerve (XII)

(See p. 37, 39, 45, 50, and 51)

1 9. Larynx and Laryngeal Muscles

The **LARYNX** is ventral at the head-neck junction, anchored in position by the hyoid bone (thyrohyoideum). It fulfills the functions of closing the airway and of enabling the animal to form its voice. In swallowing, the entrance to the larynx is safeguarded by retroflexion of the **epiglottis** (*epiglottis* —3). In coughing, to clear the lower airway (see the text-figure), the glottic cleft is first closed and, utilizing the abdominal press, suddenly opened to allow the thrust of air to expel exudate, particulate, and other material. In the operation of the abdominal press, the glottic cleft is closed, in which case the inspiratory position of the diaphragm in the thoracic cavity serves as an opposing pressure-clushion to the increase in pressure in the abdominal cavity. The formation of sound by the larynx is associated with the vocal folds (*plicae vocales* —V), which surround the glottic cleft and are underlain by the vocal muscle (*m. vocalis* —11). Owing to the intensity of the air-stream, the vocal folds vibrate and in this way the tone (pitch) of the voice arises. The more that the vocal folds are stretched, the higher is the pitch.

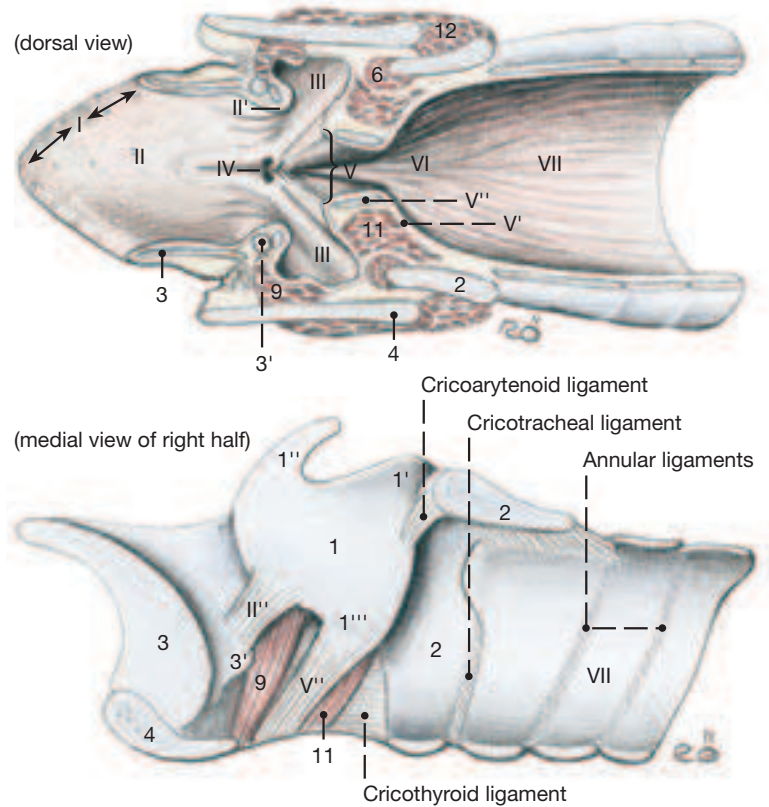
The equine larynx (see text figures) is characterized by possessing **laryngeal ventricles** laterally (III, see page 49.10) and a single median recess (IV); otherwise, it follows the common mammalian plan. The following features of its interior and its cartilages are shown in the two figures on this page and the two figures on page 49: **laryngeal vestibule** (II), **vestibular fold** containing the **vestibular ligament** (II'') and the **ventricularis muscle** (9), the **glottis** (see page 47.F) and the **glottic cleft** (V), which is the space between right and left components of the glottis. See the **vocal fold** (page 47.F) which contains the **vocal ligament** (V') and the **vocalis muscle** (11), and the **infra-glottic cavity** (page 47.G).

The **epiglottic cartilage** (3) has right and left **cuneiform processes** (3'), which project dorsally from its base; the **arytenoid cartilage** (1) presents **corniculate** (1'') and **vocal** (1''') processes and, on its lateral surface, a muscular process. The **thyroid cartilage** (4) is deeply notched ventrally, creating the thyroid notch. The notch is open caudally and bridged by the **cricothyroid ligament**. The lamina of the **cricoid cartilage** (2) overhangs the first tracheal cartilage.

The **JOINTS OF THE LARYNX** are the **cricothyroid** (4'''), hinge-like movements that tilt the thyroid cartilage and, in that way, vary the tension on the vocal folds), **cricoarytenoid** (4''''', for craniocaudal gliding movements) as well as the **hyohyoid articulation** (4'', the connection to the hyoid bone).

Of the **LARYNGEAL MUSCLES** the **cricoarytenoideus dorsalis** (7), the only dilator of the glottis, is important in “roaring.” The **sphincters** of the glottis-cricothyroideus (12), **cricoarytenoideus lateralis** (6), **vocalis** (11), **ventricularis** (9), and the **arytenoideus transversus** (5) – as well as the innervation of the larynx by the cranial and recurrent laryngeal nerves follow the common mammalian pattern. Occasionally, one finds an **accessory thyroarytenoideus** that ex-

Ventral half of Larynx



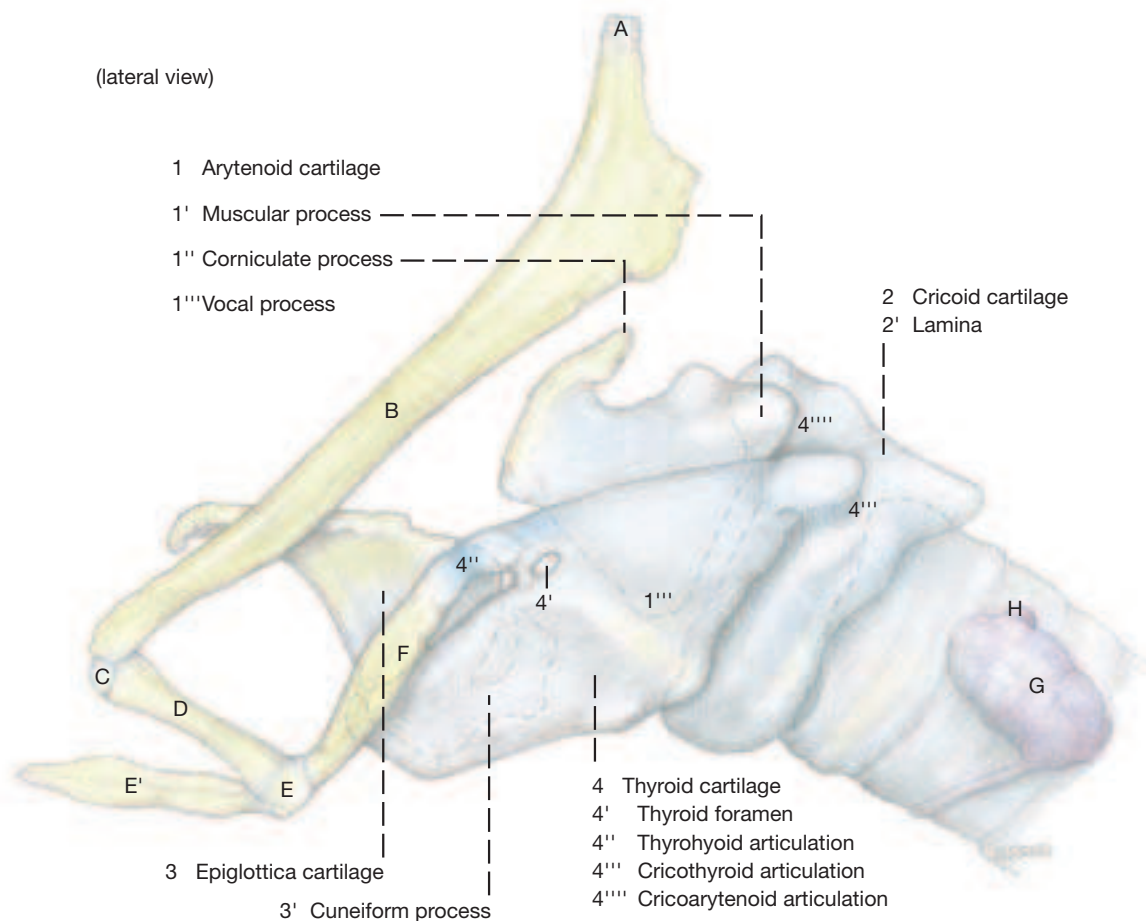
tends from the muscular process of the arytenoid cartilage to the dorsal border of the thyroid cartilage, or a **tensor of the laryngeal ventricle** that begins on the cuneiform process of the epiglottis and fans out to end on the laryngeal ventricle.

INNERVATION. The laryngeal muscles are innervated by the cranial and caudal laryngeal nerves, both branches of the vagus, of which the former is dispatched at the head-neck junction and the latter in the thorax. The **cranial laryngeal nerve** enters the larynx by the thyroid foramen but before doing so detaches an external branch (b) to the cricothyroideus. The **caudal laryngeal nerve** (8) is the continuation of the recurrent laryngeal nerve after that nerve's tracheal and esophageal branches have been given off in its ascent of the neck. The caudal laryngeal nerve is distributed to the remaining laryngeal muscles. The two nerves also innervate the laryngeal mucosa: the cranial nerve by its **internal branch** (afferent limb of the cough reflex), which supplies the area up to the glottic cleft. The caudal nerve supplies the area caudal to the glottic cleft.

Larynx

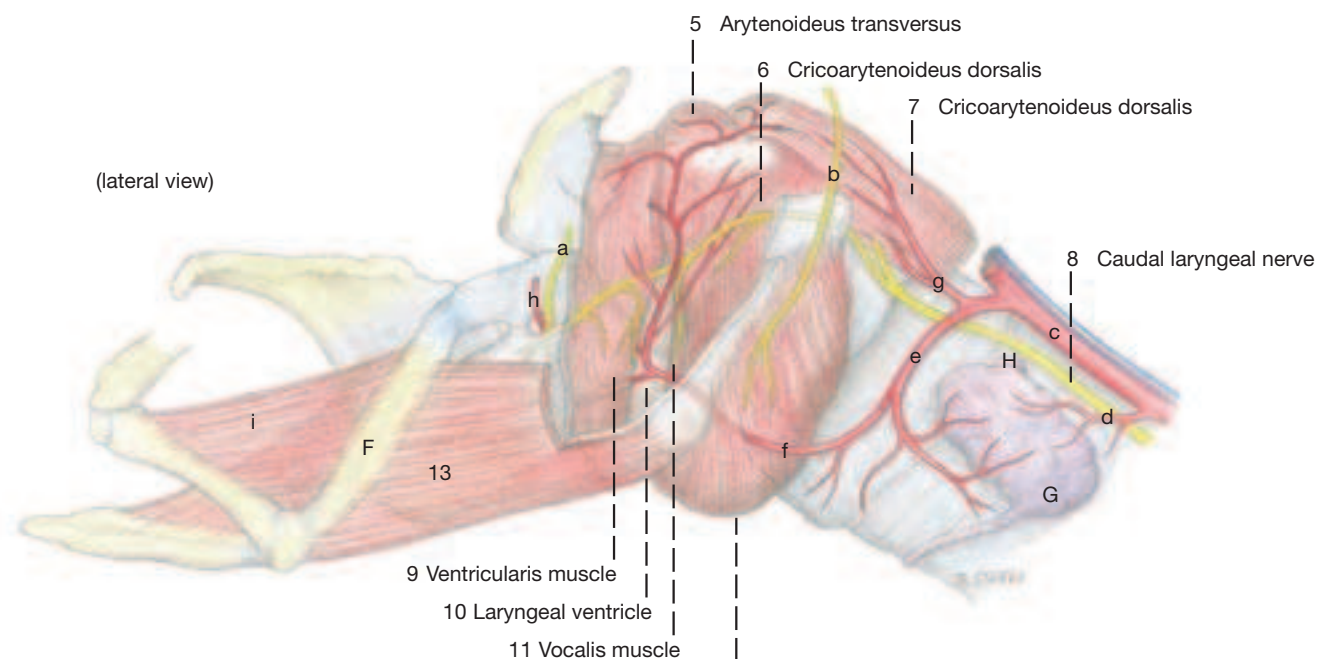
(lateral view)

- A Tympanohyoid cartilage
- B Stylohyoid bone
- C Epihyoid bone
- D Ceratohyoid bone
- E Basihyoid bone
- E' Lingual process
- F Thyrohyoid bone
- G Thyroid gland
- H Parathyroid gland

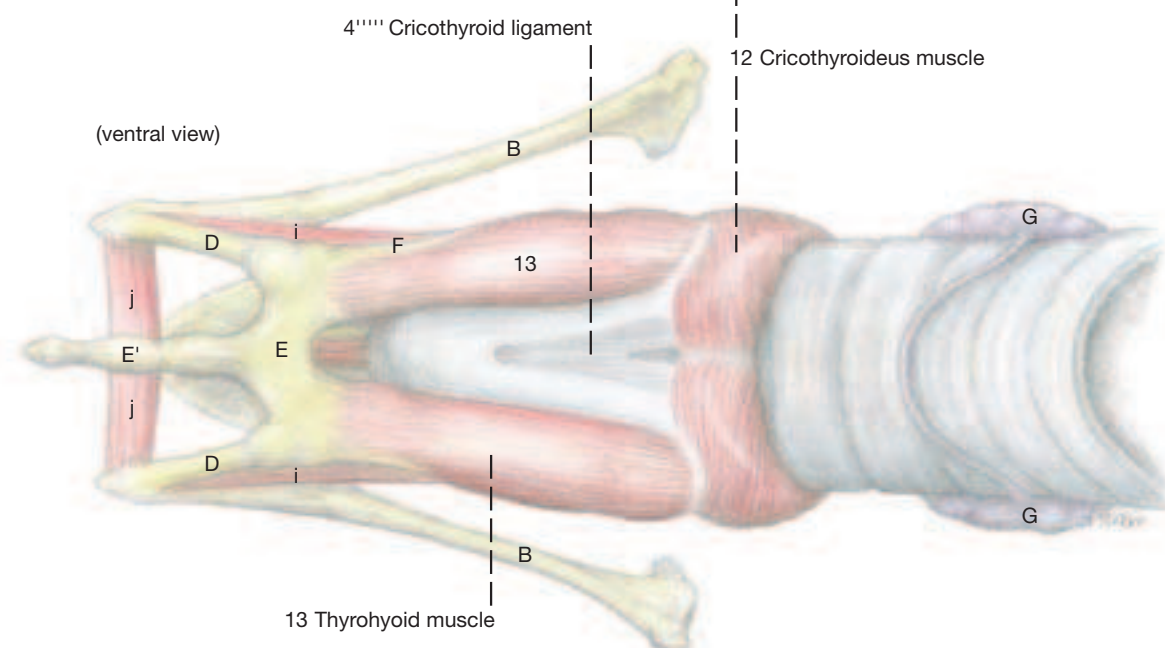


(lateral view)

- Cranial laryngeal nerve
- a Internal branch
- b External branch
- c Common carotid a.
- d Caudal thyroid a.
- e Cranial thyroid a.
- f Laryngeal branch
- g Ascending pharyngeal a.
- h Cranial laryngeal a.
- i Ceratohyoid m.
- j Transverse hyoid m.



(ventral view)



10. Head-Neck Junction and Ear

Clinical and Functional Anatomy p. 162–163

The cranial nerves IX through XII and the deeper arteries of the head may be demonstrated both from the side (lateral approach) and, on a split head, from the medial surface. In the former, and in continuation of the dissection, rests of the parotid gland and the guttural pouch (except its median septum) are removed, and so is the proximal (dorsal) third of the stylohyoid and the occipitohyoideus muscle attaching to it. In the more advantageous medial approach the rectus capitis ventralis and longus capitis are taken out so as to demonstrate the neurovascular structures associated with the guttural pouch (see p. 46 and 47).

- 1 a) The **EAR** can be subdivided into the external ear (*auris externa*), middle ear (*auris media*) and internal ear (*auris interna*). See the text-figures.

The **EXTERNAL EAR** consists of the auricle with the auricular muscles and scutiform cartilage (*scutulum*, see page 37) as well as the external acoustic meatus with its cartilaginous part (*cartilago auriculae et cartilago anularis*; see page 37, D and E) and an osseous part.

The **external acoustic meatus** (*meatus acusticus externus* —a) ends at the **tympanic membrane** (b), the cutaneomembranous border between the external and middle ear. The tympanic membrane consists externally of a cutaneous layer, which is aglandular, hairless, and lacks pigment. It is followed by a middle connective tissue layer. On its side toward the middle ear, the tympanic membrane is clothed with a simple squamous epithelium.

The **MIDDLE EAR** consists of the *pars tympanica* of the petrous bone with the tympanic bulla and the auditory ossicles, nerves and muscles contained within it. In the horse, radially arranged bony lamellae form characteristic *cellulae tympanicae* (d) around the *anulus tympanicus* (c). The auditory ossicles transmit the sound waves striking the tympanic membrane mechanically to the internal ear. The handle of the **hammer** (*malleus*, e) is directly fused with the tympanic membrane. Its head articulates with the body of the **incus** (f). With its long crus, the incus transmits the sound waves further to the **stapes** (g), whose two crura connect via the footplate with the vestibular window of the internal ear. The footplate is joined to the margin of the window by the anular ligament. By way of the **tensor tympani muscle** (h), the tympanic membrane can be tensed and pulled toward the interior of the tympanic cavity. The **stapedius muscle** (i) alters the position of the incus and by that favors the transfer of the higher frequencies. On the other hand at normal tonus the stapedius muscle, precisely as does the tensor tympani muscle, prevents damage to the auditory system due to nonphysio-

logical sound effects (intense noise). On the connection of the middle ear with the pharynx by the auditory tube with the expansion of the guttural pouch, see page 46.

The **INTERNAL EAR** lies totally in the petrous part of the temporal bone. It consists of a system of osseous and membranous canals and is subdivided into the auditory organ with the cochlear duct (*ductus cochlearis*, j) and the vestibular apparatus (*apparatus vestibularis*, k) or organ of equilibration with the vestibule and the three semicircular ducts that stand perpendicular to one another. Both organs are supplied by the sensory **vestibulocochlear nerve** (VIII).

2 b) The deep **ARTERIES OF THE HEAD** begin with the **common carotid** (21) which, together with the vagosympathetic trunk, ascends the neck dorsolateral to the trachea. Opposite the second cervical vertebra the common carotid gives off the **cranial thyroid artery** (18) which sends the **ascending pharyngeal artery** (g) to the pharynx and, as **cranial laryngeal artery** (h), curves around the cranial pole of the thyroid gland. Slightly more cranially, the common carotid splits into **internal** (13) and **external** (1) carotid arteries. The latter, as it turns dorsally, releases a **masseteric branch** (2) and the **linguofacial trunk** (7) which, medial to the mandible, bifurcates to form **lingual** (8) and **facial** (9) arteries. The last-named vessel and its satellite vein are joined by the parotid duct and together they obliquely cross the ventral border of the mandible to gain the face. The pulse may be taken here on the artery by pressing it against the medial surface of the mandible. (See p. 36 for the veins of the head.)

3 c) The convex **THYROID GLAND** (20) is palpable and lies with its right and left lobes dorsolaterally on the trachea immediately caudal to larynx. The lobes are occasionally united ventral to the trachea by a connective tissue isthmus.

d) The **PARATHYROID GLANDS** are only a few mm in diameter; the external ones lie on the trachea but at a considerable distance from the thyroid glands, about 10 cm cranial to the thoracic inlet. The **internal parathyroid glands** (19) are either in contact with their respective thyroid lobe or lie within a 1 cm range from it.

e) The **ESOPHAGUS** continues the pharynx dorsal to the larynx; opposite the fourth cervical vertebra it slips to the left lateral surface of the trachea, and shortly before the thoracic inlet may even gain its ventral surface. It may be divided for description into cervical, thoracic, and (a short) abdominal parts.

f) The **TRACHEA** continues the infraglottic cavity of the larynx at the cricoid cartilage; its initial portion is covered ventrally by the omohyoideus. It consists of cervical and thoracic parts.

g) The **CRANIAL NERVES IX–XI** leave the cranial cavity by the jugular foramen and conform to the general pattern.

I. The **glossopharyngeal nerve** (3), among others releases a **lingual branch** (5) to the tongue and a **pharyngeal branch** (4) to the pharynx.

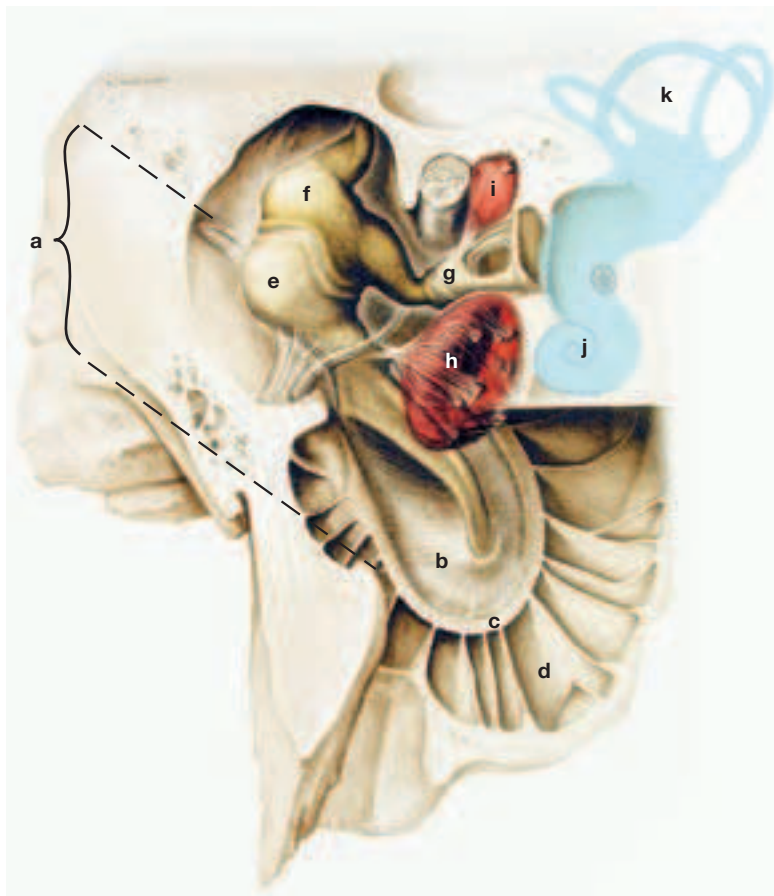
II. The **vagus** (16) also releases a pharyngeal branch and, in addition, the **cranial laryngeal nerve** (6) to the thyroid foramen through which it enters the larynx. Before doing so it sends a branch to the cricothyroideus. The vagus passes down the neck within the vagosympathetic trunk and in the thorax it gives off the **recurrent laryngeal nerve** (22). This reascends to the area of the larynx ventral to the common carotid artery on the dorsolateral aspect of the trachea and enters the larynx by passing deep to thyroid lamina. It innervates all laryngeal muscles (except the cricothyroideus) and the mucosa caudal to the glottis.

III. The **accessory nerve** (15) splits opposite the atlas into **dorsal** (r) and **ventral** (q) branches which innervate trapezius and sternocleidomastoid, respectively.

h) The **HYPOGLOSSAL NERVE** (14) enters the region under discussion through the hypoglossal canal and pursues a rostroventral course. It crosses the medial aspect of the accessory nerve and the lateral aspects of vagus and external carotid artery on its way to supply the intrinsic and the following extrinsic tongue muscles: **styloglossus** (10), **hyoglossus** (11), and **genioglossus** (see p. 45.d). The **geniohyoide** (see p. 45.j) and **thyrohyoideus** (12), of the group of hyoid muscles, receive their innervation from the first cervical nerve (C1) which forms the **ansa cervicalis** (f) with the hypoglossal nerve.

i) The dissection also exposes parts of the **AUTONOMIC NERVOUS SYSTEM** such as the sympathetic trunk (17) and the cranial cervical ganglion (17).

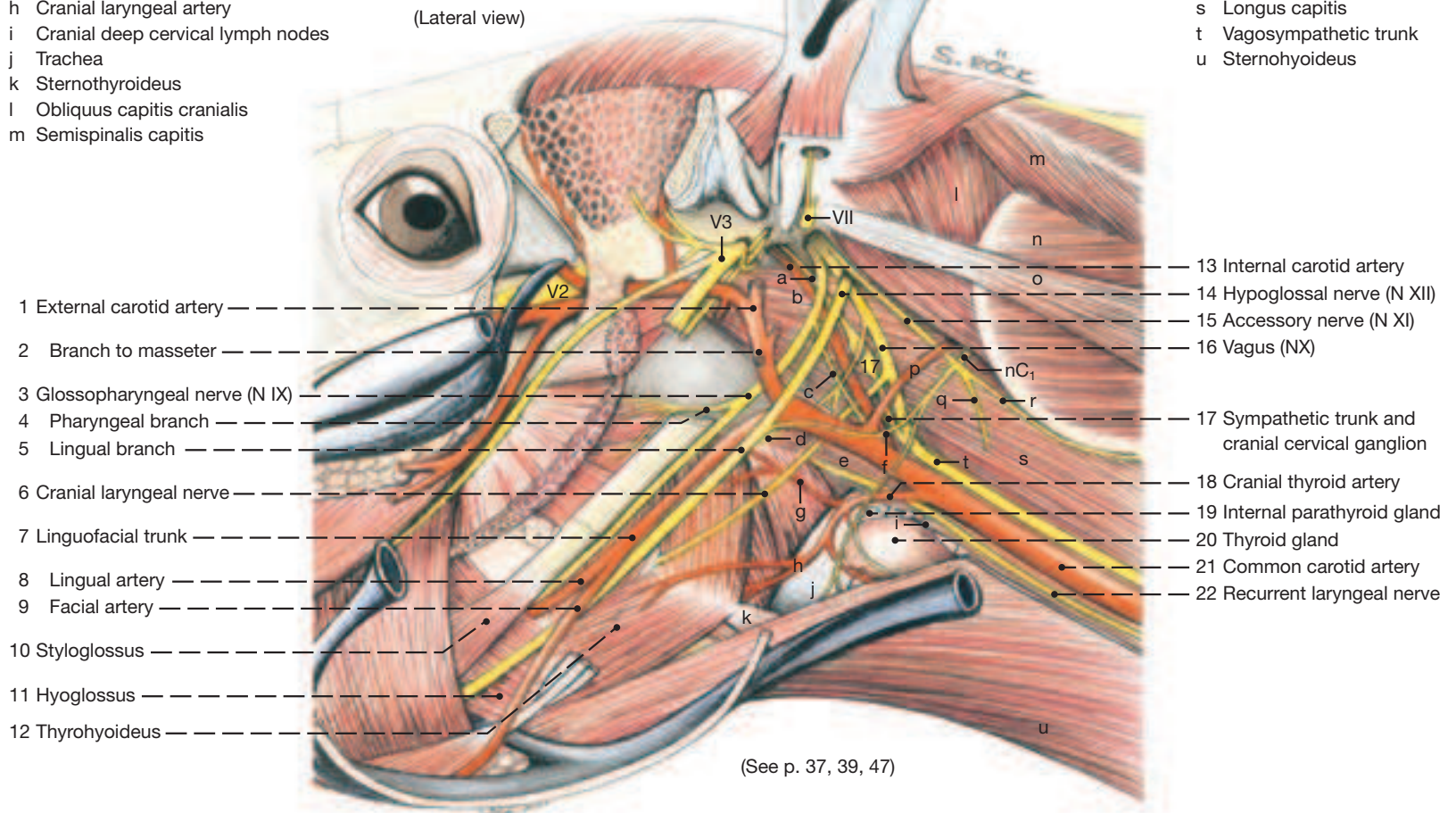
Middle ear and internal ear*



Arteries and Cranial Nerves IX, X, XI, and XII of the Head

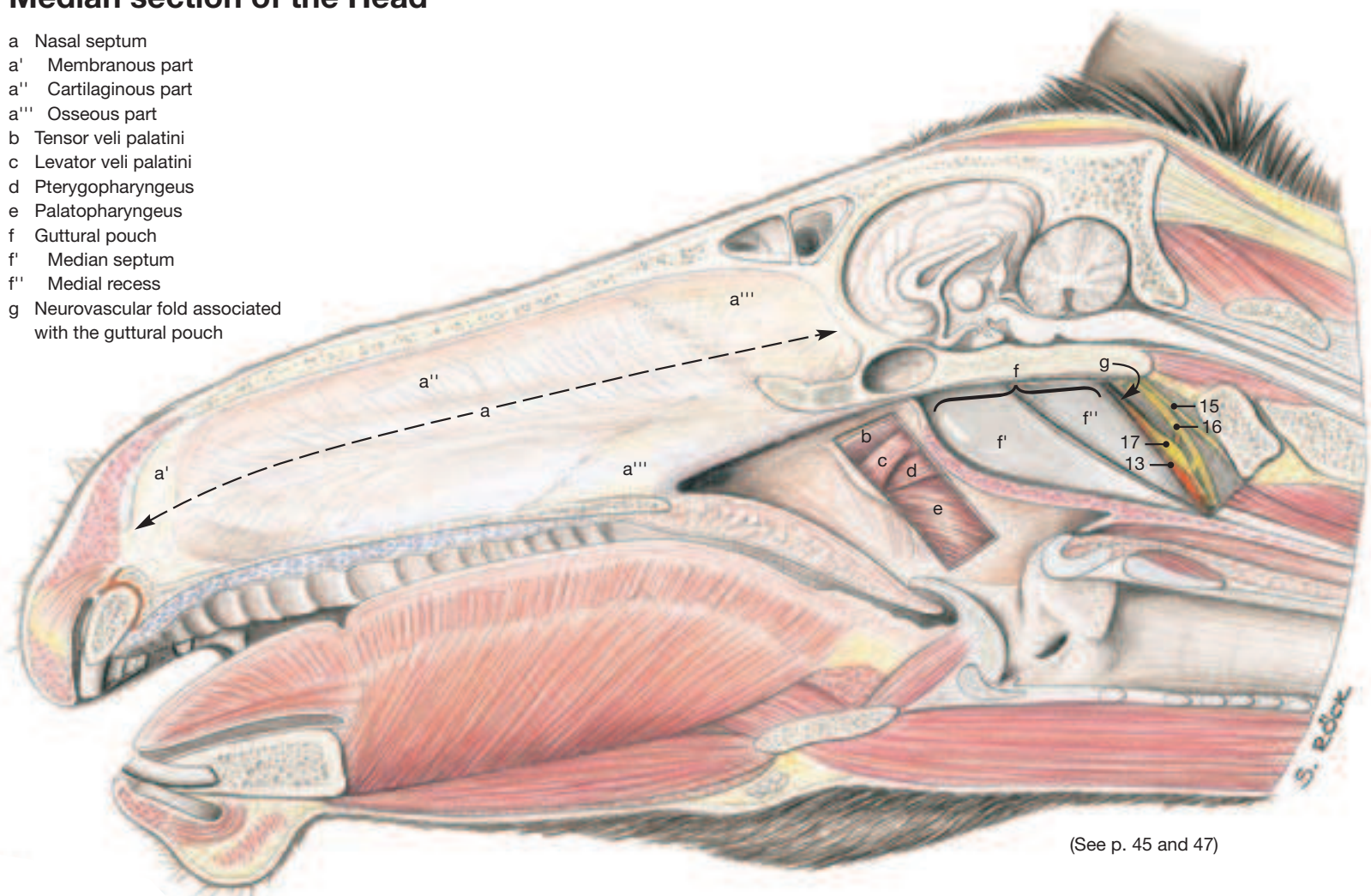
- a Internal carotid nerve of sympathetic trunk
- b Rectus capitis ventralis
- c Branch of glossopharyngeal nerve to carotid sinus
- d Pharyngeal branch of vagus
- e Esophagus
- f Ansa cervicalis (C1)
- g Ascending pharyngeal artery
- h Cranial laryngeal artery
- i Cranial deep cervical lymph nodes
- j Trachea
- k Sternothyroideus
- l Obliquus capitis cranialis
- m Semispinalis capitis

- n Obliquus capitis caudalis
- o Longissimus capitis
- p Occipital artery
- q Ventral branch of accessory nerve
- r Dorsal branch of accessory nerve
- s Longus capitis
- t Vagosympathetic trunk
- u Sternohyoideus



Median section of the Head

- a Nasal septum
- a' Membranous part
- a'' Cartilaginous part
- a''' Osseous part
- b Tensor veli palatini
- c Levator veli palatini
- d Pterygopharyngeus
- e Palatopharyngeus
- f Guttural pouch
- f' Median septum
- f'' Medial recess
- g Neurovascular fold associated with the guttural pouch



Chapter 5: The Central Nervous System

1. The Brain

The structure of the brain cannot be studied unless it is removed from its membranous and bony (brain case) enclosure. This is more easily accomplished when the head is first split in the median plane, although this divides the brain into right and left halves. Compensation is found, however, in that the division exposes some of the brain's interior and that two groups of students can study a symmetrical half, as shown in the Figure on this page. Since it is important during the removal of the brain to preserve the cranial nerves as they leave the brain, it is best to proceed in the following manner. The spinal cord and medulla oblongata are the first to be elevated. The **hypoglossal nerve (N XII)** is transected midway between its emergence from the medulla oblongata (lateral to the crossing of the pyramidal tracts) and the hypoglossal canal through which it leaves the skull. The **accessory nerve (N XI)** can be identified by its prominent spinal root that lies on the lateral border of the spinal cord; its thin cranial root joins the spinal root just before the nerve exits via the foramen lacerum where it should be cut. This cut most likely detaches also the **vagus (N X)** and **glossopharyngeal nerves (N IX)** which share the same exit from the skull with the accessory nerve. **Vestibulocochlear (N VIII)** and **facial (N VII)** nerves also lie close together and are cut between the trapezoid body (just caudal to the pons) and the internal acoustic meatus through which they enter the petrous temporal bone. The thin **abducent nerve (N VI)** is cut next; it arises at the same level as the preceding nerves but more ventromedial from between the pyramid and the trapezoid body, also just caudal to the pons. The large **trigeminal nerve (N V)** is cut where it passes rostrally from the lateral aspect of the pons. The next two nerves arise from the midbrain: the thin **trochlear (N IV)** is the only nerve to emerge on the dorsal surface of the brain stem, caudal to the caudal colliculus; it usually tears before it can be transected. The much larger **oculomotor nerve (N III)** is cut where it arises from the crus cerebri caudolateral to the bisected hypophysis which also has to be lifted carefully from its bed. The **optic nerve (N II)** is cut distal to the optic chiasm which can be seen rostral to the hypophysis. Finally, to free the half brain completely, the olfactory bulb with its **olfactory nerve (N I)** bundles will have to be lifted away from cribriform plate with a flat instrument.

a) According to Dyce, Sack, and Wensing (1987) the BRAIN of the horse weighs between 400 and 700 grams; compared to body weight, a ratio of 1:800. The ratio for the dog is about 1:100. It is fair to say therefore that the horse has a relatively small brain. Species-specific features of the equine brain compared to the brains of the other domestic mammals are of little significance. Hence, the illustrations on this and the following pages should be given more weight than the accompanying text.

I. The dorsal part of the **rhombencephalon**, the **cerebellum (20)**, has a surface contour, formed by winding lobes, that is more irregular and complex than that of the human cerebellum. The median vermis is more salient than the hemispheres flanking it.

II. The **mesencephalon**, or midbrain, is overhung by cerebrum and cerebellum, and thus is best viewed from below or on a median section. Its upper part (**tectum**) presents four swellings (**colliculi; 14, 15**) which are of about equal size in the horse.

III. The **diencephalon**, the most rostral part of the brain stem, is connected dorsally to the large cerebral hemispheres by fiber tracts, and is thus completely hidden except ventrally. The ventral portion is the **hypothalamus (9)** which, between optic chiasm and mammillary body, presents the **infundibulum (11)** that connects the **hypophysis (10)** with the brain.

IV. The **telencephalon**, comprising in the main the cerebral hemispheres, is the largest part of the brain. Its surface is fissured in a complex manner by alternating ridges (gyri) and grooves (sulci). Rostral to the hemispheres are the **olfactory bulbs** which are bent

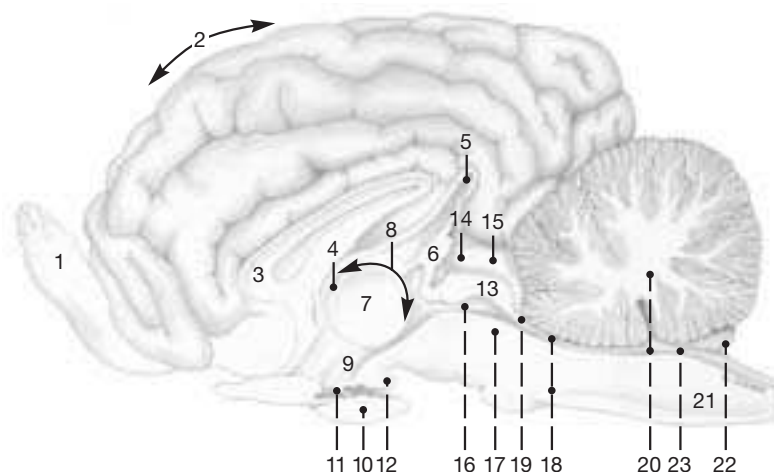
Clinical and Functional Anatomy p. 163–164

dorsally. They are at the ends of the **olfactory peduncles**. These, followed caudally, divide into lateral and medial **olfactory tracts** between which lies the so-called **olfactory triangle**.

b) The **VENTRICULAR SYSTEM**, or the lumen of the brain, reaches from the interior of the olfactory bulbs via a complicated array of ventricles and interconnecting ducts to the spinal cord where it is continued by the central canal of that structure. The **fourth ventricle (23)**, situated ventral to the cerebellum, presents a lateral evagination (choroid plexus; a vascular, fringe-like fold of pia mater that secretes cerebrospinal fluid) which is visible on each side between cerebellum and brain stem. The **third ventricle and its choroid plexus (8)** lie rostral to the **pineal gland (6)** and by a **suprapineal recess (5)** extend beyond the end of the gland as shown in the Figure on this page. The two lateral ventricles send extensions into the olfactory bulbs.

c) The **BLOOD SUPPLY** to the brain comes from the ventral surface (as shown on the opposite page) and in its larger branches is remarkably constant among the domestic mammals. The venous sinuses that drain the blood away lie within the dura and consist of dorsal and ventral systems which are not interconnected in the horse. The sagittal sinus in the dorsal system divides caudally into right and left transverse sinuses that course within the membranous tentorium cerebelli. The two transverse sinuses, more caudally, are connected by a communicating sinus that occupies the osseous tentorium cerebelli. The ventral system is connected rostrally to veins outside the cranial cavity only through the orbital fissure. The system is drained caudally into the internal vertebral venous plexus.

Median Section of the Brain



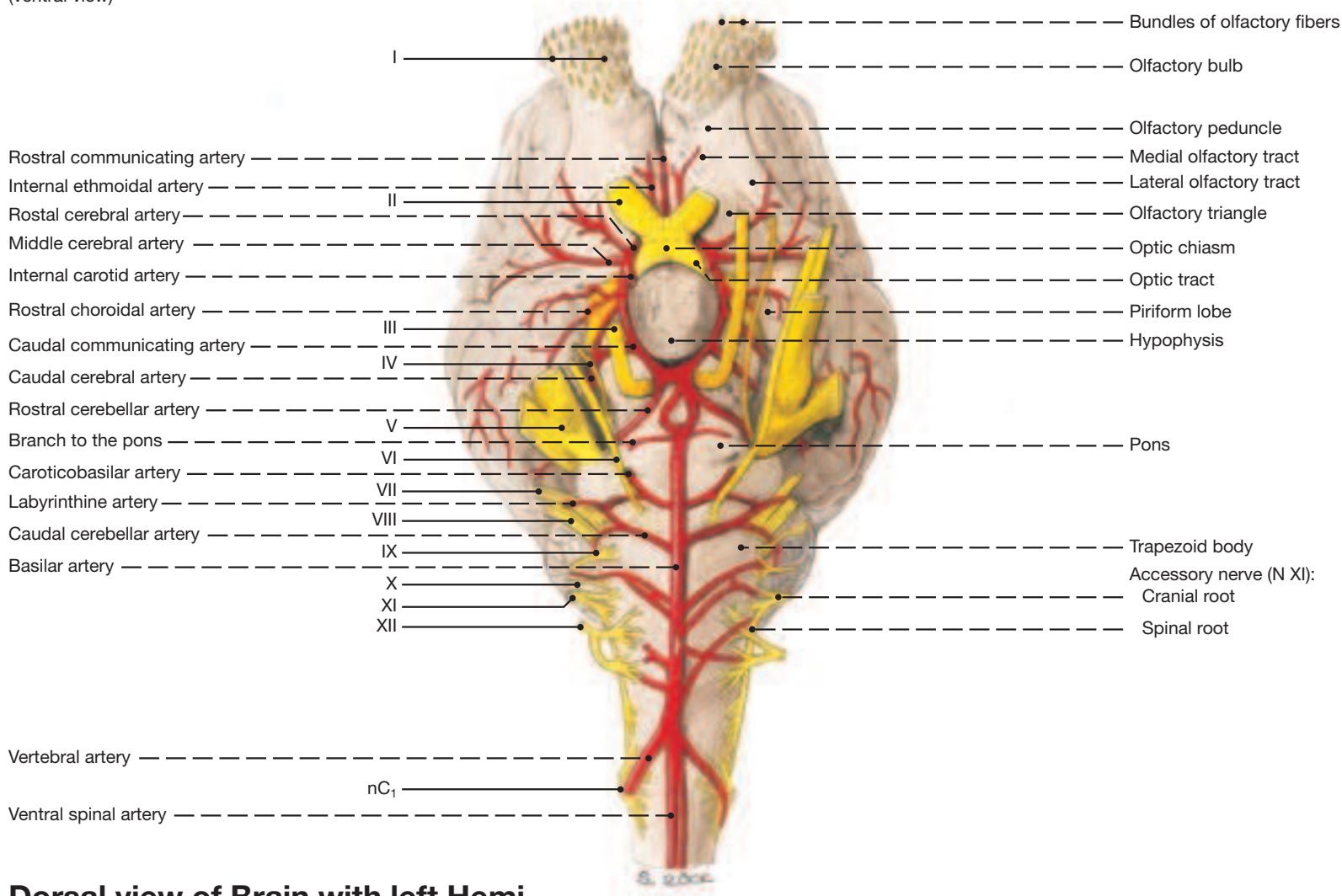
Telencephalon:
1 Rhinencephalon
2 Cerebrum
3 Corpus callosum

Diencephalon:
4 Thalamus
5 Suprapineal recess
6 Pineal gland and pineal recess
7 Interthalamic adhesion
8 Third ventricle and its choroid plexus
9 Hypothalamus
10 Hypophysis
11 Infundibulum
12 Mamillary body

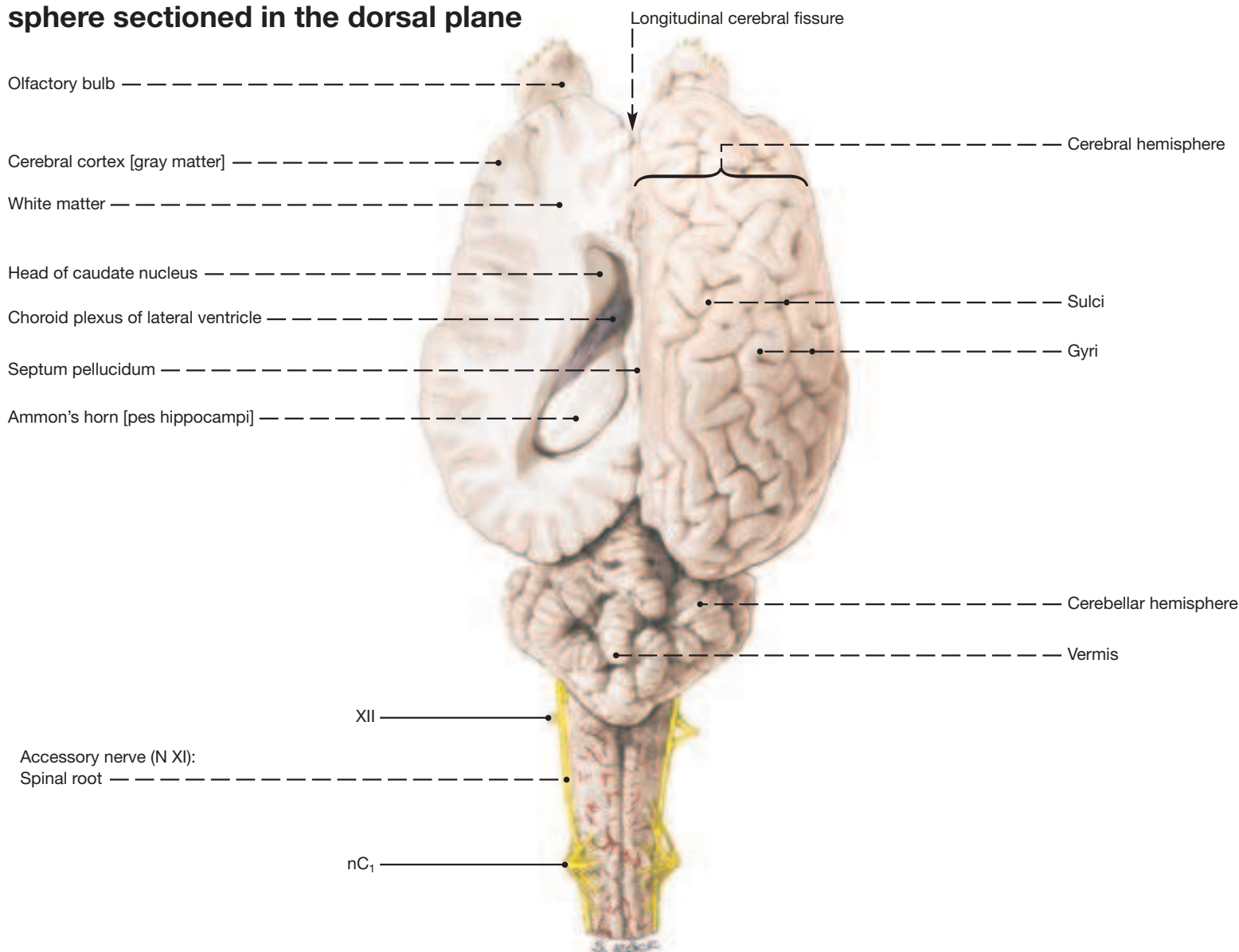
Mesencephalon:
Tectum:
13 Lamina tecti quadrigemina
14 Rostral colliculus
15 Caudal colliculus
16 Aqueduct
17 Tegmentum
Rhombencephalon:
18 Metencephalon
19 Rostral medullary velum
20 Cerebellum and recess in the roof of the fourth ventricle
21 Medulla oblongata
22 Caudal medullary velum
23 Fourth ventricle and its choroid plexus

Brain and Cranial Nerves

(ventral view)



Dorsal view of Brain with left Hemisphere sectioned in the dorsal plane



2. The Spinal Cord

The spinal cord is best demonstrated from the dorsal aspect, *in situ*. The arches of the vertebrae and portions of the meninges are removed as shown on the opposite page. (The lower case n preceding the segmental designations stands for nerve.) For the study of the cord's gray and white substances, central canal, and commissures the cord needs to be transected. Few species-specific features other than size that distinguish the equine spinal cord from those of other domestic mammals. The dissections on the opposite page are from a young, few-months-old horse in which the shortening of the cord (ascensus medullae) in relation to the vertebral canal was still going on. This is why the extents given above for the adult animal do not agree with those in the Figures.

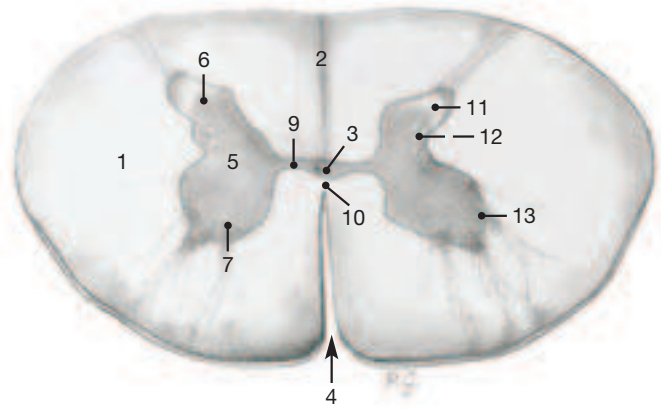
1; 2 The **SPINAL CORD** is surrounded and protected by the meninges and with them it occupies the vertebral canal. The end of the cord (**conus medullaris**; 20) in the adult horse extends relatively far caudally, to the first sacral vertebra; the **filum terminale** (21), which prolongs the cord, reaches the fourth sacral segment. Both conus and filum, together with the spinal nerves that flank them for various distances, form the **cauda equina** (C) which in adult horses begins at the lumbosacral junction.

4 The central canal on transverse section is a nearly dorsoventrally flattened oval; in the sacral segment, however, it is slightly flattened from side to side. At its caudal end the canal is slightly expanded (**ventriculus terminalis**; 19) and communicates dorsally with the subarachnoid space. (There is a possibility that both the ventriculus and its communication are artificial post mortem changes.) The number of spinal nerves equals that of the thoracic, lumbar, and sacral vertebrae. In the cervical segment are 8 nerves as in the other domestic mammals, and there are normally only 5 caudal spinal nerves for the innervation of the tail.

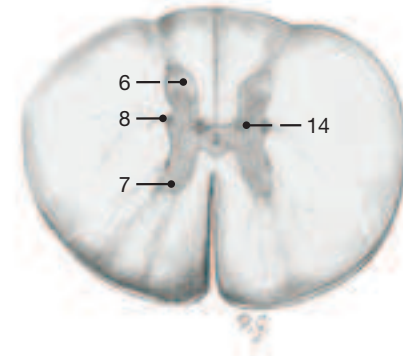
- | | |
|----------------------------|----------------------------------|
| 1 White matter | 12 Reticular formation |
| 2 Dorsal median septum | 13 Motor nuclei |
| 3 Central canal | 14 Thoracic nucleus |
| 4 Median fissure (ventral) | 15 Epidural space |
| 5 Gray matter | 16 Dura mater |
| 6 Dorsal horn | 17 Arachnoid and subdural spaces |
| 7 Ventral horn | 18 Pia mater |
| 8 Lateral horn | 19 Ventriculus terminalis |
| 9 Gray commissure | 20 Conus medullaris |
| 10 White commissure | 21 Filum terminale |
| 11 Substantia gelatinosa | 22 End of dura mater |

Transverse Sections of the Spinal Cord*

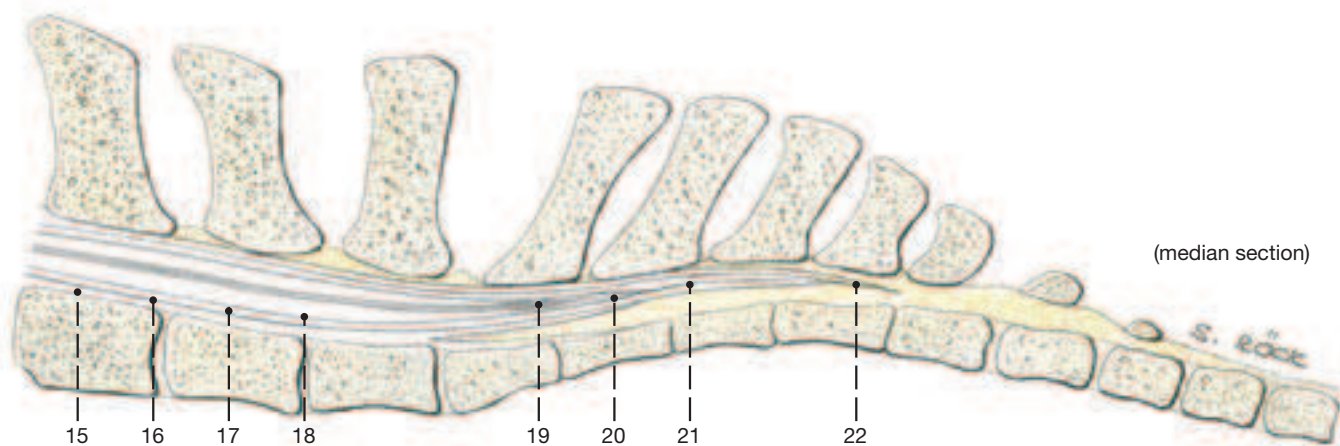
Transverse Section at C6



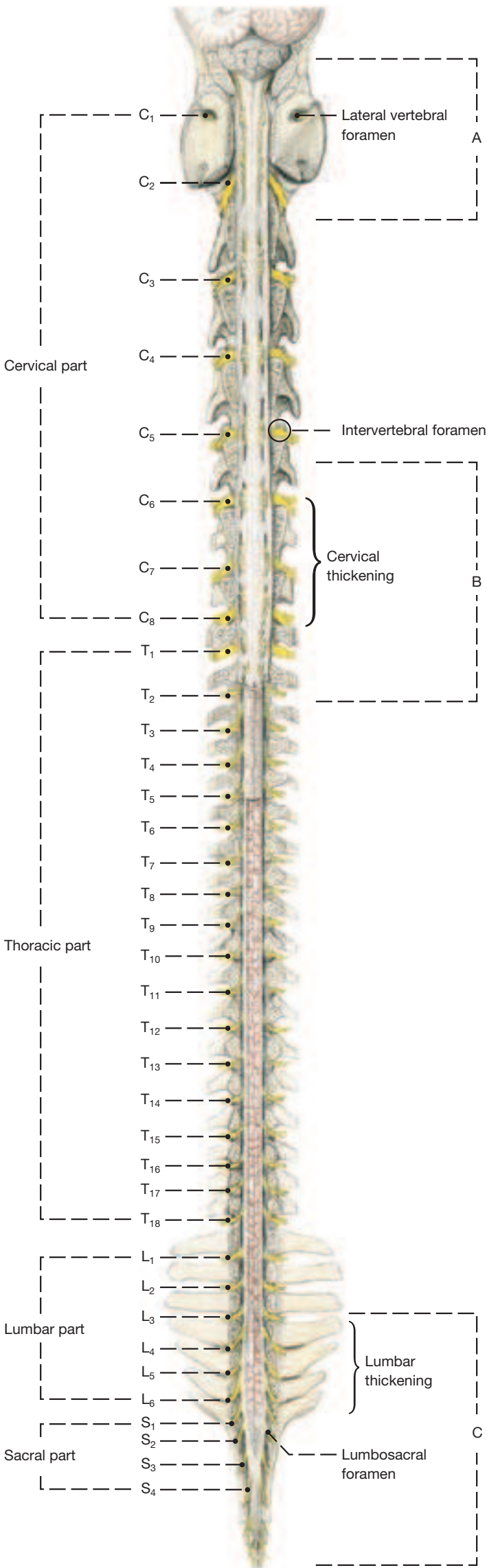
Transverse Section at T4



Lumbosacral Portion of Spinal Cord

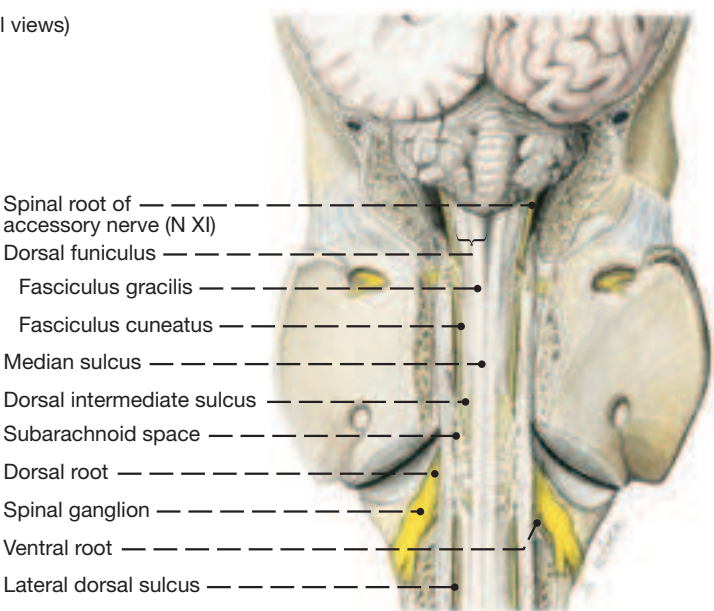


Spinal Cord of a Young Horse, in situ

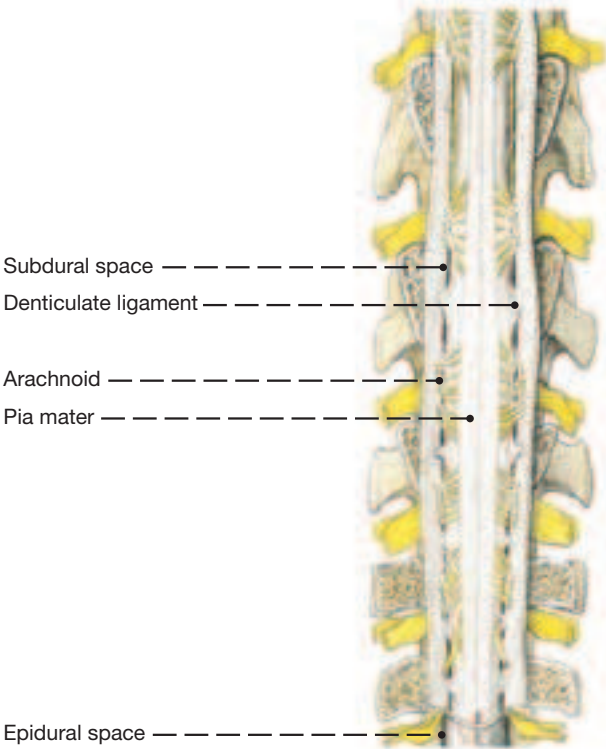


A. Medulla oblongata and cervical part

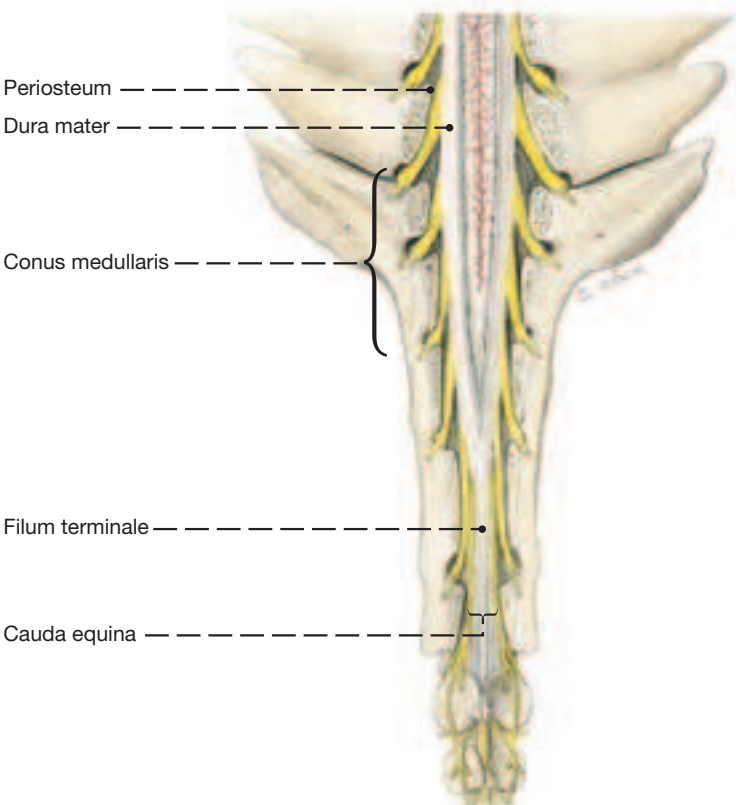
(Dorsal views)



B. Cervical thickening



C. Conus medullaris and cauda equina



1. Vertebral Column with Thorax and Nuchal Ligament

a) At the junction of neck and thorax the **VERTEBRAL COLUMN** by a deep concavity (as seen from the side) is farthest removed from the dorsal surface of the body. Caudal to this it gradually ascends to be close to the dorsal midline again in the lumbar and pelvic areas. The slanted **spinous processes** (12) of the thoracic vertebrae increase in length up to T4 (or T5) to form, with the scapulae, the basis of the withers.

Then the spinous processes get steadily shorter, until they have reach 10 cm, which is the length of the anticlinal vertebra (usually T16) in a medium size horse. This is also the length of the lumbar spinous processes which have a slight cranial inclination.

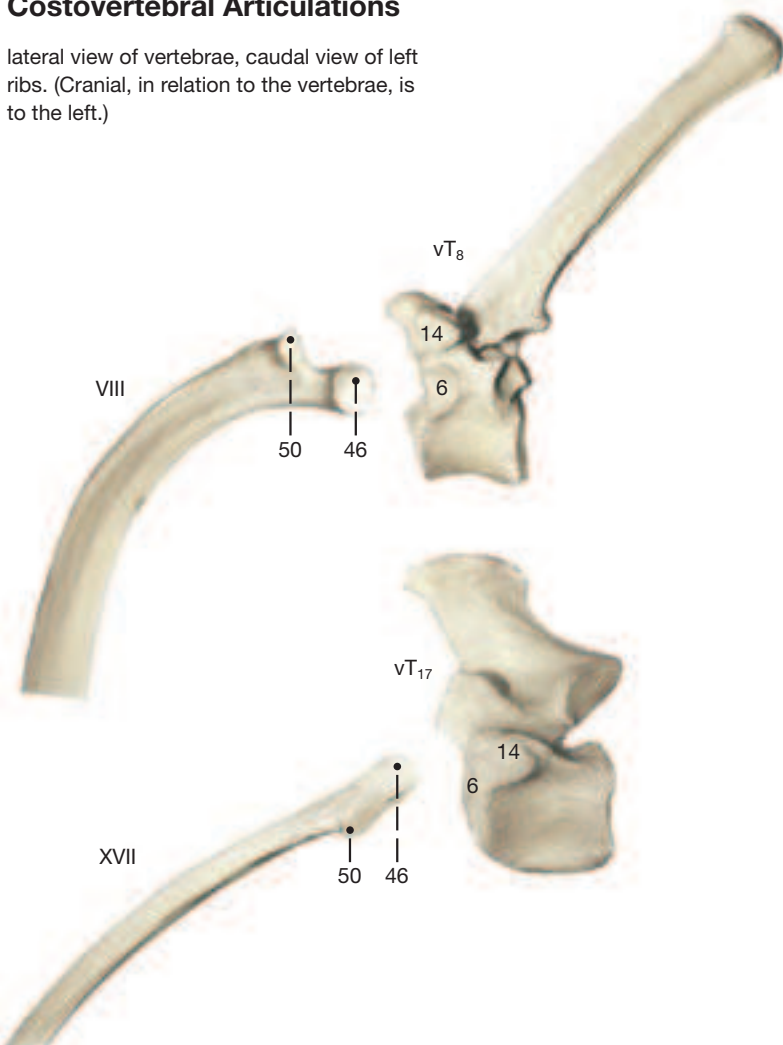
In young horses the ends of the long thoracic spinous processes of the withers are capped with cartilage, which gradually ossifies with age. The vertebral formula is as follows: C7 (as in all domestic mammals), T18 [17,19], L6 [5,7], S5, Cd (Cy) [15–21]. The square brackets indicate fairly common variations. (The lower case v preceding the segmental designation stands for vertebra.)

1 I. The spinous process of the **cervical vertebrae**, except for the second and the last, are poorly developed and absent on C1. The atlas has an **alar-** (27') and a **lateral** (28) **vertebral foramen** (for the first cervical nerve). The axis of older subjects also has a **lateral vertebral foramen** which transmits the second cervical nerve. Its crest-like spinous process shows evidence caudally that it developed from paired elements. The transverse processes of vertebrae C3–6 present **ventral** (13') and **dorsal** (13'') **tubercles**.

2 II. The articular surfaces of the articular processes on the **thoracic vertebrae** undergo a change in direction from a nearly dorsal (horizontal) plane orientation to one that is sagittal. In the more caudal thoracic vertebrae the **cranial costal facet** (6) on the body is approached and finally touched by the **costal facet** (14) on the transverse process to form a combined surface for both the head and the tubercle of the rib. In some of these vertebrae the caudal notch is transformed to a lateral vertebral foramen that transmits the spinal nerve.

Costovertebral Articulations

lateral view of vertebrae, caudal view of left ribs. (Cranial, in relation to the vertebrae, is to the left.)



III. The **transverse processes** (13) of the **lumbar vertebrae** project laterally, and the last two form a joint (or fuse) with each other. This causes the intervertebral foramina to be partitioned into dorsal and ventral openings for the respective primary branches of the spinal nerves. The last lumbar transverse process articulates at its base with the wing of the sacrum with a similar partition of the intervertebral foramen.

IV. The **sacral vertebrae** fuse when the horse is 4–5 years old. Its spinal processes remain separate at their summits, but merge at their bases with the occasional loss, or right/left division, of the interarcuate spaces. The **promontory** (38), ventrally on the cranial end, is not a salient feature upon rectal palpation because of the lack of angulation at the lumbosacral junction. The **lumbosacral (interarcual) space** (23) at the same level is wide.

V. The paired nature of the spinous processes on the **caudal vertebrae** is a feature of the first two elements. After that, and up to the sixth, the arches are open dorsally and farther distally disappear altogether. The last ten or so elements, therefore, are mere cylindrical rods representing the bodies of the vertebrae. The first caudal vertebra has the tendency to fuse with the sacrum.

b) The **THORAX** is formed by the ribs, the thoracic vertebrae, and the sternum. The relatively large number of ribs (18 mostly) cause it to extend to within a short distance of the pelvis. It is compressed from side to side cranially to accommodate shoulder and arm within the skin of the trunk, but caudal to the forelimb it is wider and more barrel-shaped.

The first 8 [9] **ribs** end directly on the sternum (**sternal ribs**; 41) while the remaining 10 [9] are **asternal ribs** (42). Supernumerary ribs are represented usually as floating ribs that do not reach the costal arch. The first rib is short and almost incapable of movement; it solidly connects the vertebral column to the sternum and provides a solid base for the respiratory movements of the more and more mobile, later ribs.

The cranial portion of the **sternum** consisting of **manubrium** (54) and the next three sternebrae, is laterally flattened. The caudal portion—the last two **sternebrae** (56) and the xiphoid process—is dorsoventrally flattened. The ventral border of the sternum forms a cartilaginous **crest** (55') that fails to show the segmentation of the bone. The crest ends cranially by an upturned **manubrial cartilage** (54').

c) The elastic **NUCHAL LIGAMENT** consists of two parts, each paired. Dorsally is the cord-like **funicular part** (**funiculus nuchae**; A) and ventral to it the flat **laminar part** (**lamina nuchae**; B).

The **funiculus** extends from the external occipital protuberance to the summits of the 3rd, 4th, or 5th thoracic vertebrae where it is continued by the less elastic **supraspinous ligament** (C) that ends at the sacrum. The cranial segment of the funiculus is an oval cord that passes dorsal to atlas and axis without attaching to these bones. In midneck the paired funiculus gradually flattens and takes on a paramedian position which it maintains at the withers by lying dorso-lateral to the summits of the thoracic spines so that its right and left parts almost make contact with the scapular cartilages. Caudal to the withers the supraspinuous ligament gradually narrows again to form a single median structure.

Passage of the funiculus over the thoracic spines at the withers is eased by the **supraspinous bursa** (C'). A similar function falls to the **cranial** (A') and **caudal** (A'') **nuchal bursae** which lie dorsal to atlas and axis, respectively, and of which the caudal is inconstant.

The fenestrated **lamina nuchae** fills the space between the cervical vertebrae and the funiculus. It extends cranioventrally from the latter and from the spinous processes of T2 and T3 and attaches on the spinous processes of all cervical vertebrae except the first.

d) **MUSCLES OF THE VERTEBRAL COLUMN** (see Table on p. 96).

The Vertebral Column, the Thorax, and the Nuchal Ligament

(Caudodorsal view)

Vertebral column and bones of the thorax

Cervical vertebrae (C1–7)
Thoracic vertebrae (T1–18 [17–19])
Lumbar vertebrae (L1–6 [5–7])
Sacral vertebrae (S1–5)
Caudal vertebrae (Cd1–x) (Cy1–x)

Body (1)
Ventral crest (2)
Cranial extremity (3)
Caudal extremity (4)
Caudal costal facet [C7, T] (5)
Cranial costal facet [T] (6)

- Vertebral canal (7)
- Arch (8)
- Intervertebral foramen (9)
 - Cranial notch (10)
 - Caudal notch (11)
- Spinous process (12)
- Transverse process (13)
 - Ventral tubercle [C3–6] (13')
 - Dorsal tubercle [C3–6] (13'')
 - Costal facet [T] (14)
 - Transverse foramen [C1–6] (15)

Cranial articular process (16)
Caudal articular process (17)
Costal process [C3–6, L] (18)

Mamillary process [T-S] (20)

Interarcular space
Lumbosacral interarcual space (23)
Sacrocaudal interarcual space (24)

Atlas [C1] (25)

Wing (26)
Alar foramen (17')
Lateral vertebral foramen (28)
Dorsal arch (29)
Ventral arch (30)

Axis [C2] (31)

Lateral vertebral foramen (31')
Dens (32)

Sacrum [S1–5]


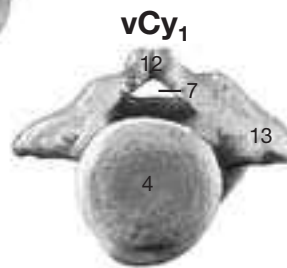
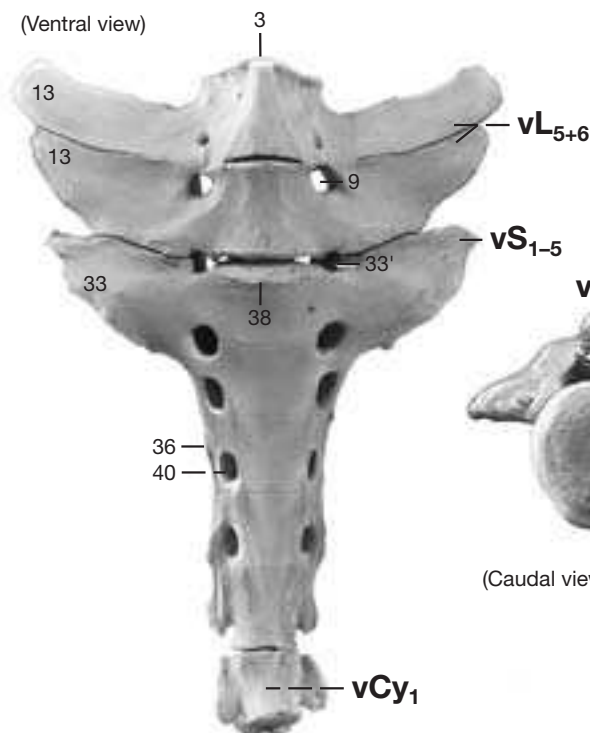
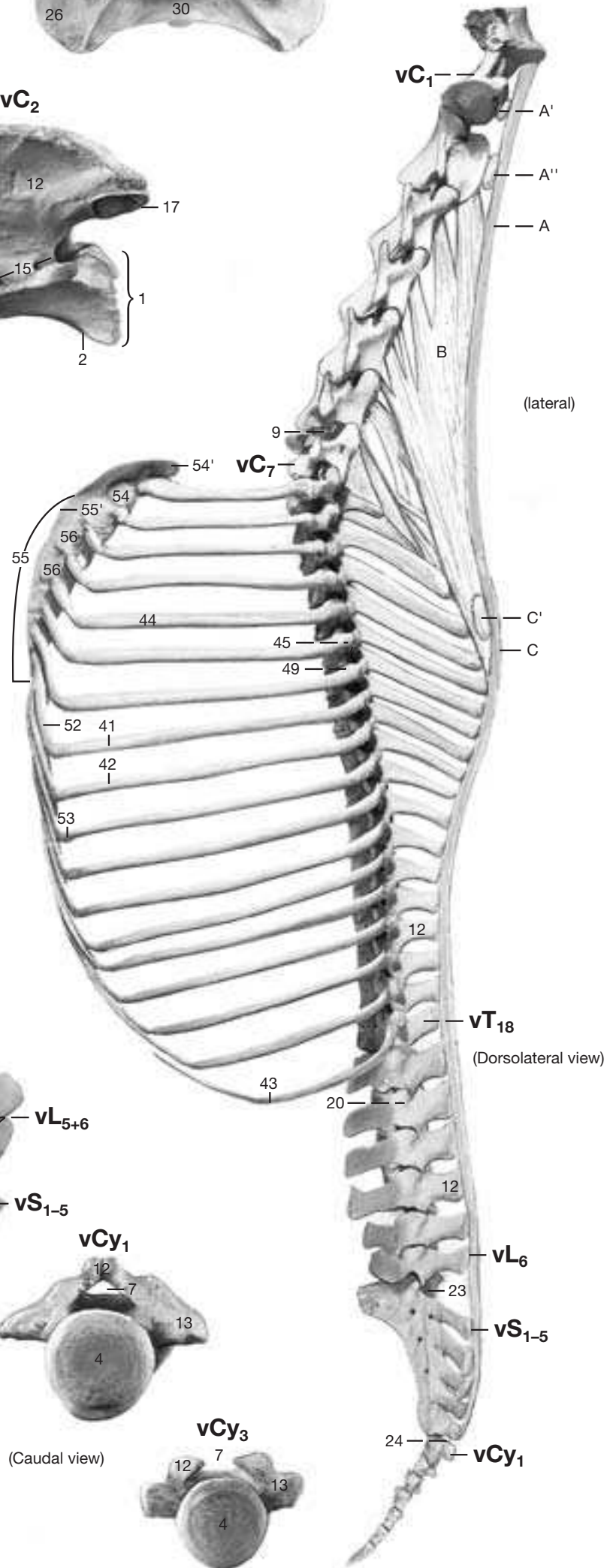
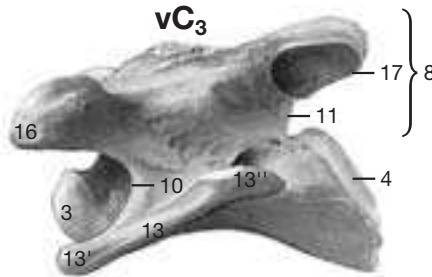
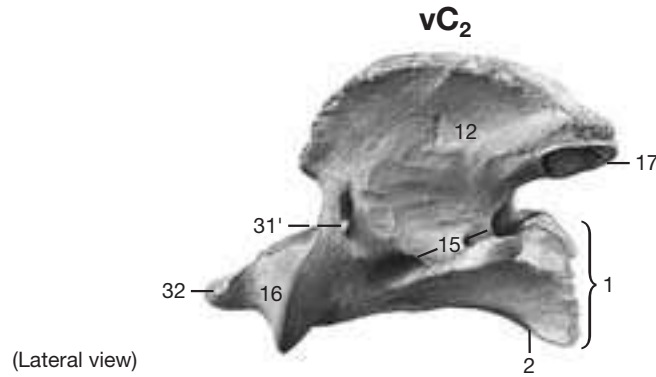
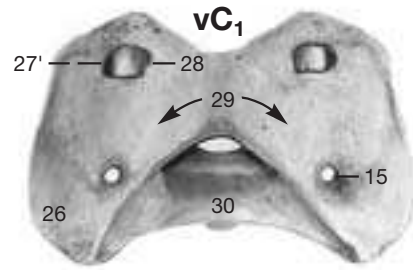
Wing of sacrum [S1] (33)
 Notch (foramen) of wing (33')
 Auricular surface (34)
 Lateral sacral crest (36)
 Promontory (38)
 Dorsal sacral foramen (39)
 Ventral sacral foramen (40)

Ribs

- Sternal ribs (41)
- Asternal ribs (42)
- Floating rib (43)
- Bony part of rib (44)
 - Head of rib (45)
 - Articular surface (46)
 - Tubercle of rib (49)
 - Articular surface (50)
- Costal cartilage (52)
 - Knee of rib, costochondral junction (53)

Sternum

- Manubrium (54)
- Manubrial cartilage (54')
- Body of sternum (55)
- Crest of sternum (55')
- Sternebrae (56)



- A Funiculus of nuchal lig.
- A' Cranial nuchal bursa
- A'' Caudal nuchal bursa
- B Lamina of nuchal lig.
- C Supraspinous ligament
- C' Supraspinous bursa

2. Neck and Thoracic Wall

Removal of the skin, and underlying fascia, and certain cutaneous muscles exposes the supf. structures shown in the upper dissection on the opposite page. In the lower dissection also the following structures were removed (lower Figure on facing page): forelimb, supf. shoulder-girdle muscles, sternocephalicus, omohyoideus, ext. jugular vein; and partly the rhomboideus, serratus ventralis, subclavius, and pectoral muscles.

a) There are three **CUTANEOUS MUSCLES** in the area (see also left Fig. on p. 64). The **cutaneus omobrachialis** covers shoulder and arm with nearly dorsoventrally oriented fibers; it is continued caudally by the much larger **cutaneus trunci** whose fibers run cranio-caudally. The **cutaneus colli** (5) covers the caudventral portion of the neck; it arises from the manubrium sterni and from the cervical fascia and ascends in the shape of a V obliquely across right and left jugular grooves to end, and partly attach, on the cleidomastoideus.

b) The **SUPF. SHOULDER-GIRDLE MUSCLES**: The **cervical** (10) and **thoracic** (10') parts of the **trapezius** arise from a long stretch of the dorsal midline and converge on the spine of the scapula.

The **omotransversarius** (6) passes cranially from the clavicular intersection (see further on) to the transverse processes of the 2nd to 4th cervical vertebrae. Its ventral border is fused with the dorsal border of the cleidomastoideus. The **cleidomastoideus** (4') is continuous caudally with the cleidobrachialis. The fibrous clavicular intersection that separates these two muscles is present only in the deeper strata of these muscles. Superficially, there is no visible boundary between cleidobrachialis and cleidomastoideus, and the single unit they appear to form constitutes the **brachiocephalicus**. The cleidomastoideus arises with its deep strata from the clavicular intersection; it forms the dorsal border of the jugular groove and ends on the mastoid process of the petrous temporal bone.

1 The **sternocephalicus** (—**mandibularis**) (4) furnishes the ventral border of the jugular groove whose floor to a large extent is formed

by the omohyoideus (see further on). The **sternocephalici** arise from the manubrium sterni and remain connected in the ventral midline to about halfway up the neck. More cranially, each muscle passes deep to the parotid gland and with a discrete tendon ends on the caudal border of the mandible.

The **latissimus dorsi** (11) has a broad origin from the thoracolumbar fascia. Its fibers course cranioventrally at first, but closer to the scapula they turn ventrally to end on a relatively thin tendon. This makes contact with the tensor fasciae antebrachii but unites fully with the teres major tendon with which it ends on the teres tuberosity on the medial surface of the humerus.

2 The **supf. pectoral muscles** (**pectoralis descendens**, 26; and **pectoralis transversus**, 26') cross the medial surface of the elbow joint to end on the fascia of arm and forearm, respectively. The **pectoralis descendens** bulges forward and with the cleidobrachialis forms the **lateral pectoral groove** (9). The median pectoral groove separates right and left descending pectorals in the midline.

c) VEINS OCCUPYING THE JUGULAR AND LATERAL PECTORAL GROOVES

3 The **jugular groove** is bounded dorsally by the cleidomastoideus, ventrally by the sternocephalicus (—**mandibularis**), while most of its floor is provided by the omohyoideus. The **ext. jugular vein** (3) that fills the groove results from the confluence of the **maxillary** (2) and the more ventral **linguofacial** (1) veins and carries blood toward the heart. The jugular groove and its vein are covered in the caudal two-thirds of the neck by the cutaneus colli muscle.

In the caudal end of the jugular groove, the ext. jugular vein releases the **supf. cervical vein** (22) craniodorsally, and the **cephalic vein** (24) caudoventrally. The latter descends to the forearm in the lateral pectoral groove.

3. Deep Shoulder-Girdle Muscles, the Muscles of the ventral Part of the Neck and the visceral Space they enclose

a) DEEP SHOULDER-GIRDLE MUSCLES:

The **rhomboideus** consists of two parts. The **cervical** (28) is cranial to the scapula, on which it attaches, while the **thoracic part** (28') is at the level of the scapula and lies deep to scapular cartilage.

The **pectoralis profundus** (25') ascends from its origin on the sternum (and vicinity) to the medial and lateral tubercles of the humerus. The **subclavius** (25), also one of the pectoral muscles, arises from the cranial part of the sternum and ascends craniomedial to the shoulder joint and supraspinatus muscle to end on the cranial border of the scapula.

The **serratus ventralis** (27, 27'), like the rhomboideus, consists of cervical and thoracic parts. Both parts converge on the upper part of the medial scapular surface; the cervical part with caudodorsal, mostly fleshy bundles, the thoracic with vertical and craniodorsal bundles and tendinous sheets.

b) VENTRAL NECK MUSCLES:

The **sternohyoideus** (19) and **sternothyroideus** (20) ascend ventral to the trachea from a common origin on the manubrium of the sternum. They divide in midneck to seek their separate insertions on the basihyoid, and the thyroid cartilage of the larynx, respectively. Right and left muscles in the caudal half of the neck are fused in the midline, and the sternohyoidei remain so to their attachment on the basihyoid. The **omohyoideus** (13) arises from the subscapular fascia just dorsal to the shoulder joint. On its way to the basihyoid it very obliquely crosses the deep surface of the ext. jugular vein, after which it fuses with the sternohyoideus.

c) The VISCERAL SPACE OF THE NECK:

The space occupied by trachea, esophagus, and the vessels and nerves accompanying them is formed ventrally by the strap muscles

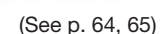
arising from the manubrium (**sternohyoideus**, —**thyroideus**, and —**cephalicus**); laterally by the omohyoideus and the sternocephalicus again; and dorsally by the longus colli and capitis, muscles of the vertebral column. The **trachea** (21), the largest occupant of the visceral space holds a median position and, depending on the level, is related to all muscles bounding the visceral space. Its cartilages overlap dorsally, and their ends are joined by the tracheal muscle that lies in the dorsal wall of the tube between the mucous membrane and the cartilages. The **common carotid artery** (16) lies dorsolateral to the trachea at the cranial end of the neck, while near the thorax it has descended into a ventrolateral position. (An internal jugular vein is very small or absent.) The **esophagus** (14) at the cranial end of the neck is dorsal to the trachea; in midneck it lies to the left of the trachea; shortly before the thoracic inlet it can even be ventral to the trachea, but as it passes into the thorax it regains its dorsal position in respect of the trachea. The **vagosympathetic trunk** (17) lies dorsomedial, and the **recurrent laryngeal nerve** (15) ventromedial to the common carotid artery.

d) LYMPHATIC STRUCTURES:

4 The **supf. cervical lymph nodes** (7), imbedded in fat, lie against the cranial surface of the subclavius and are covered laterally by the cleidomastoideus. They drain supf. structures of the neck, thorax, and forelimb. Their efferents pass directly to the veins at the thoracic inlet, or indirectly via the caudal deep cervical nodes.

The **cranial** (12), **middle** (18), and **caudal** (23) **deep cervical lymph nodes** are grouped along the tracheal (lymph) duct that conveys lymph from the head to the veins at the thoracic inlet. The cranial group is confluent with the medial retropharyngeal nodes. The especially large nodes of the caudal group are occasionally difficult to distinguish from the supf. cervical nodes and from the cranial mediastinal nodes.

(lateral view)



1. Thoracic Wall, Respiratory Muscles, Lungs, and Lymphatic Structures

For the dissections on this page the intercostal muscles and the ribs (except ribs 9 and 15–18) were removed without disturbing the insertion of the diaphragm. In the upper dissection on the opposite page the right lung was also removed. Except for size and the number of ribs, the thoracic cavity of the horse follows the general mammalian pattern. The few species-specific features are noted in the text.

a) The cranial portion of the **THORAX** is covered laterally by the skeleton and muscles of shoulder and arm, preventing clinical examination by auscultation and percussion of the organs within—unless the forelimb is pulled forward. The latissimus dorsi and the flat abdominal and cutaneous muscles cover the ribs and intercostal muscles caudal to the forelimb and are part of the thoracic wall.

b) **RESPIRATORY MUSCLES** (see Tables on Myology on p. 98).

- I. Expiratory muscles
- II. Inspiratory muscles, including the diaphragm, the principal inspiratory muscle.

The **diaphragm** forms the boundary between thoracic and abdominal cavities. Its insertion on the thoracic wall extends in a gentle curve from the 8th and 9th costal cartilages, across the costochondral junctions of the 9th–15th ribs, to the middle of the 18th rib where it turns craniomedially to end at the vertebral end of the last (17th) intercostal space. In the median plane the diaphragm bulges forward to the level of the 7th rib, and thus is almost opposite the olecranon in the standing animal. The three openings of the diaphragm, beginning dorsally, are the **aortic hiatus** between right and left crura, for the aorta; the **esophageal hiatus** in the (larger) right crus, for the esophagus; and the **caval foramen** (5) in the tendinous center, for the caudal vena cava. Surrounding the tendinous center is the muscular part divisible into **sternal** (7), **costal** (6), and **lumbar** (3) **segments** by which the diaphragm is attached at its periphery.

c) The two **PLEURAL SACS** line the thoracic cavity including the diaphragm and contact each other in the median plane to form the mediastinum. Where the pleura that covers the diaphragm reflects on itself to become the costal pleura that lines the ribs, is the **line of pleural reflection** that follows the attachment of the diaphragm. Craniodorsal to the line of pleural reflection, **diaphragmatic** (8) and **costal** (9) **pleurae** are in contact and are separated by a potential space known as the **costodiaphragmatic recess** (10).

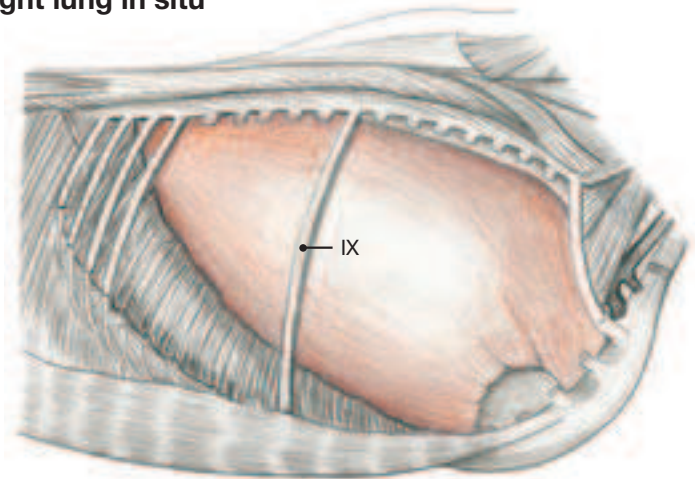
1 d) The **MEDIASTINUM** contains the heart and all other thoracic organs except the lungs (which reside within the pleural sacs) and the **caudal vena cava** (e) which indents the right pleural cavity supported by the **caval fold** (f).

In regions where the mediastinum contains no organs it is relatively thin and may be fenestrated as a result of an underdeveloped or degenerated lamina propria that separates the two pleural layers. Fenestrations are seen mainly caudal to the heart. This part of the mediastinum is pushed far over to the left because of the greater mass of the right lung.

e) The **ESOPHAGUS** (14) traverses the mediastinum from the thoracic inlet to the diaphragm. At the inlet it lies still a little to the left, but still in the cranial mediastinum it reaches the median plane dorsal to the trachea. In this region its muscular coat changes from striated to smooth muscle which may be seen in fresh specimens by a color change.

f) The **LUNGS** reflect the general shape of the thoracic cavity and are long and laterally compressed cranially. The **root of the lung**, fully visible when one lung is removed, lies opposite the 6th rib and includes the **principal bronchus** (A) and the **pulmonary artery and veins** (w, x). The “lung field” is the projection of the lung on the surface of the animal, caudal to the forelimb. It is roughly triangular, bounded dorsally by the back muscles and caudoventrally by the basal border of the lung. The latter curves from the costochondral junction of the 6th rib through the middle of the 11th rib to the edge of the back muscles at the 16th intercostal space. The lung can be percussed and auscultated within the lung field, though respiratory

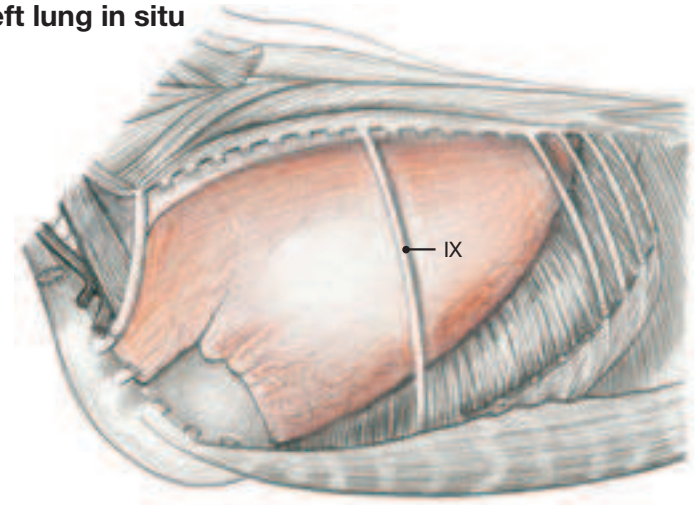
Right lung in situ



sounds cease a few cm proximal to the thin basal border so that the “audible” lung field is slightly smaller than the projection.

The right lung is larger than the left because it carries the centrally located **accessory lobe** (25). Inter- and intralobar fissures are absent so that **cranial** (18) and **caudal** (26) **lobes** are separated only by the wide **cardiac notch** (22). Part of the mediastinal surface of both lungs fuses in an elongated area caudal to the hilus. The lobulation of the equine lungs is indistinct.

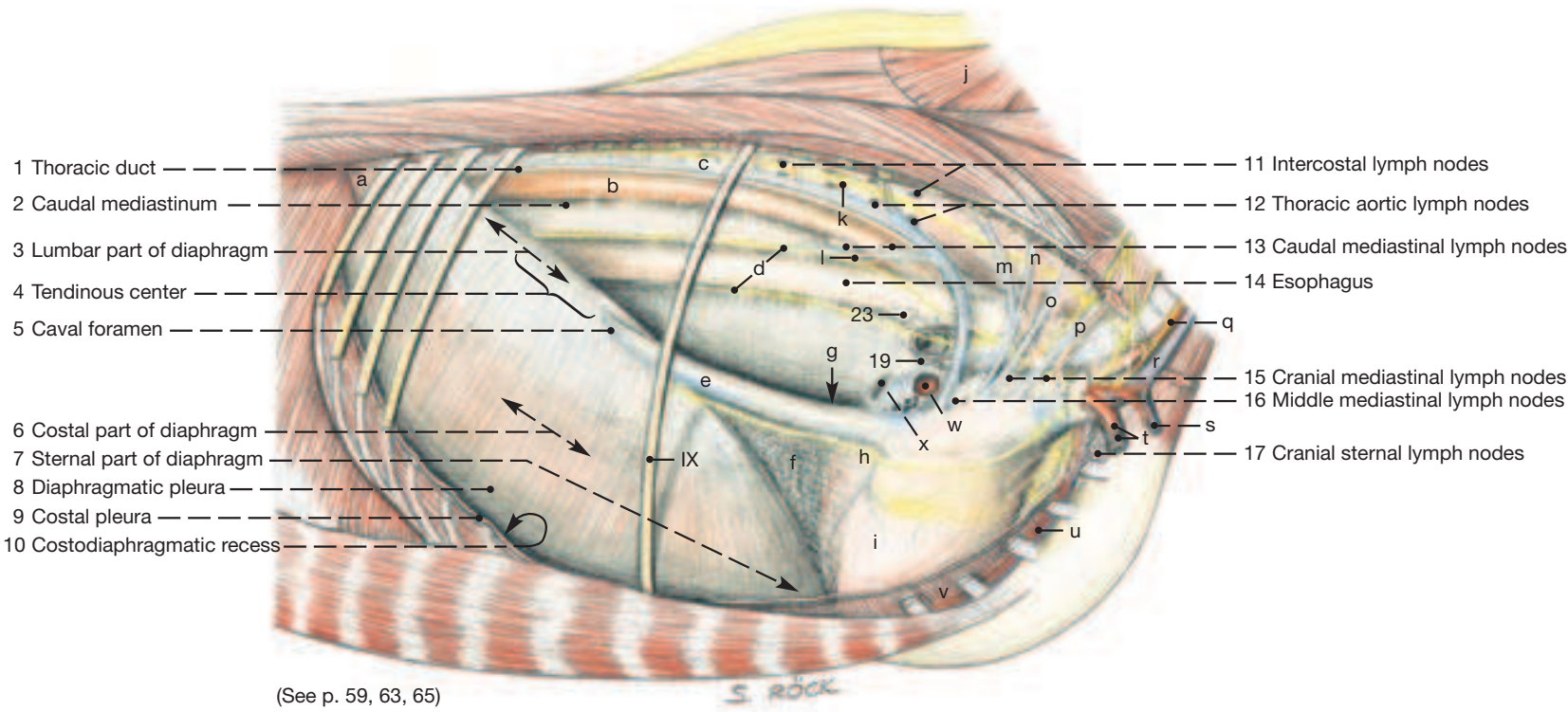
Left lung in situ



g) Most of the **LYMPH NODES** of the thorax, as in other areas, consist of aggregates of small nodes. The **right** (19), **left** (20), and **middle** (23) **tracheobronchial nodes** surround the tracheal bifurcation. Nearby **pulmonary nodes** (24) are inconstant and are covered by lung tissue. The **cranial mediastinal nodes** (15) continue the caudal deep cervical nodes within the thorax. **Middle mediastinal nodes** (16) lie dorsal to the heart, and the **caudal mediastinal nodes** (13) occupy the caudal mediastinum between aorta and esophagus. Inconstant **cranial sternal lymph nodes** (17) lie cranial to the internal thoracic vessels and are not easily distinguished from the cranial mediastinal nodes. There are also inconstant **caudal sternal lymph nodes** where the diaphragm attaches to the sternum. The **intercostal lymph nodes** (11) occupy the dorsal ends of the intercostal spaces 3–16, while the paired **thoracic aortic nodes** (12) lie dorsal to the aorta opposite the 3rd to the 17th thoracic vertebrae; they are more numerous on the left since the right ones are often absent at the level of the 9th–14th vertebrae.

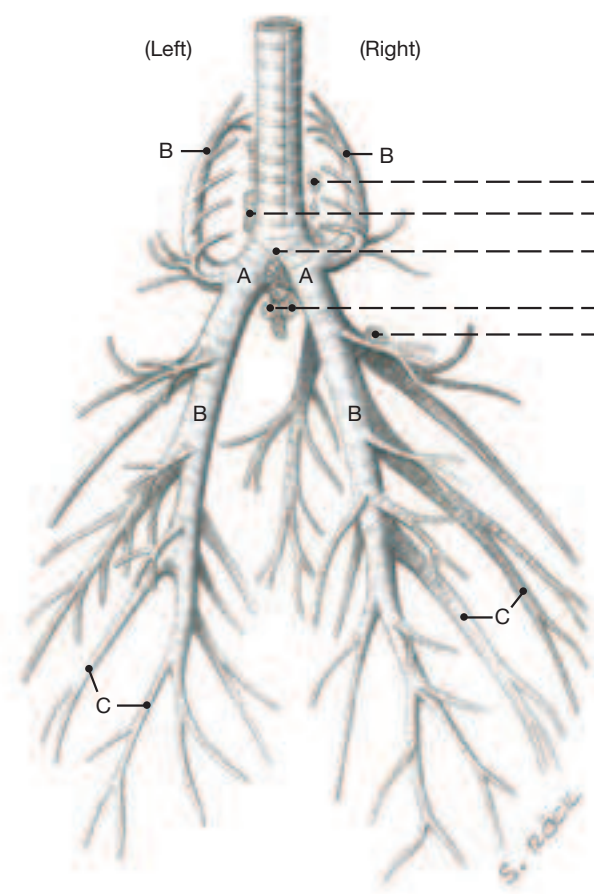
The efferent lymphatics arising from the nodes in the thoracic cavity communicate variously and either join the veins at the thoracic inlet or the cranial segment of the **thoracic duct** (1). The latter, having arisen from the cisterna chyli, accompanies the aorta forward and crosses the left face of the trachea before ending on one of the veins at the thoracic inlet, usually the cranial vena cava.

The Thoracic Cavity (right side) and the Lungs

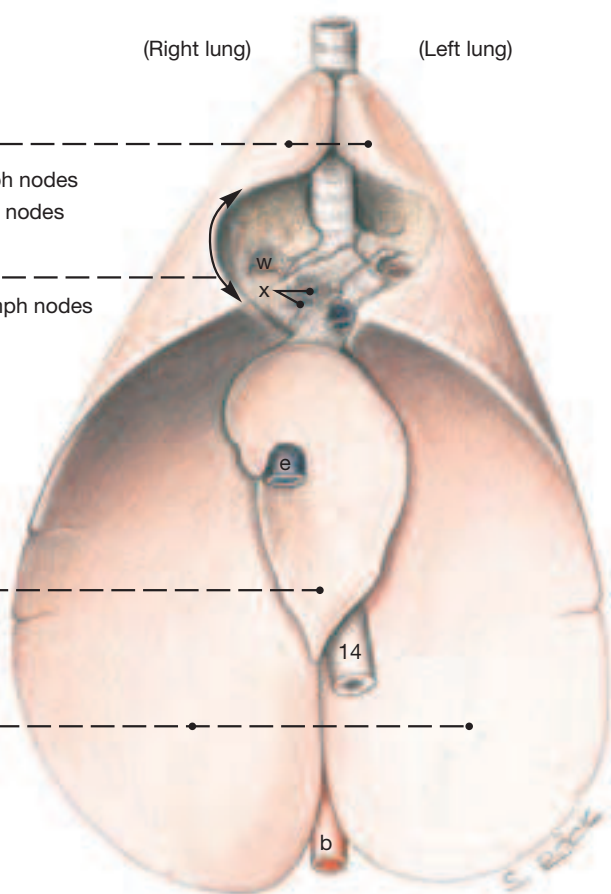


- | | | | |
|-----------------------------------|------------------------|---|-------------------------|
| A Principal bronchus | e Caudal vena cava | l Bronchoesophageal vessels | r Ext. jugular vein |
| B Lobar bronchus | f Caval fold | m Supreme intercostal vessels | s Cephalic vein |
| C Segmental bronchus | g Mediastinal recess | n Dorsal scapular vessels | t Axillary vessels |
| a Retractor costae | h Phrenic nerve | o Deep cervical vessels | u Int. thoracic vessels |
| b Aorta | i Pericardiac pleura | p Vertebral vessels and nerve | v Transversus thoracis |
| c Right azygous vein | j Semispinalis capitis | q Common carotid a. and vagosympathetic trunk | w Pulmonary artery |
| d Dorsal and ventral vagal trunks | k Intercostal vessels | | x Pulmonary veins |

Bronchial Tree, dorsal view



Lungs, ventral view



UQL|XbVxUmAVqC+HnIZ42uaraA==|1288008698

2. Heart and Thymus

a) HEART and its Projection on the Thoracic Wall

1

Depending on the breed and the amount of training, the weight of the **heart** relative to body weight ranges between 0.6 % for a draft horse and 1 % for a Thoroughbred. Species-specific features of the organ serve to distinguish it mainly from the bovine heart which attains comparable size. The horse's heart is cone shaped, but has a blunted apex when relaxed (diastole). The amount of fat in the coronary and interventricular grooves varies with the breed; the grooves contain relatively little fat in highly bred subjects. The fat associated with the heart is intensely yellow and soft. The free border of the left auricle is usually notched.

The **left coronary artery** (15) a few cm from its origin splits into **circumflex** (16) and (descending) **interventricular** (17) branches; while the **right coronary artery** (18; 19) itself pursues a circumflex course in the coronary groove before sending an **interventricular branch** (20) down the subsinuosal interventricular groove. When the heart is opened (as in a post mortem examination) a large cardiac cartilage may be palpated next to the origin of the aorta; a smaller accessory cartilage is sometimes present.

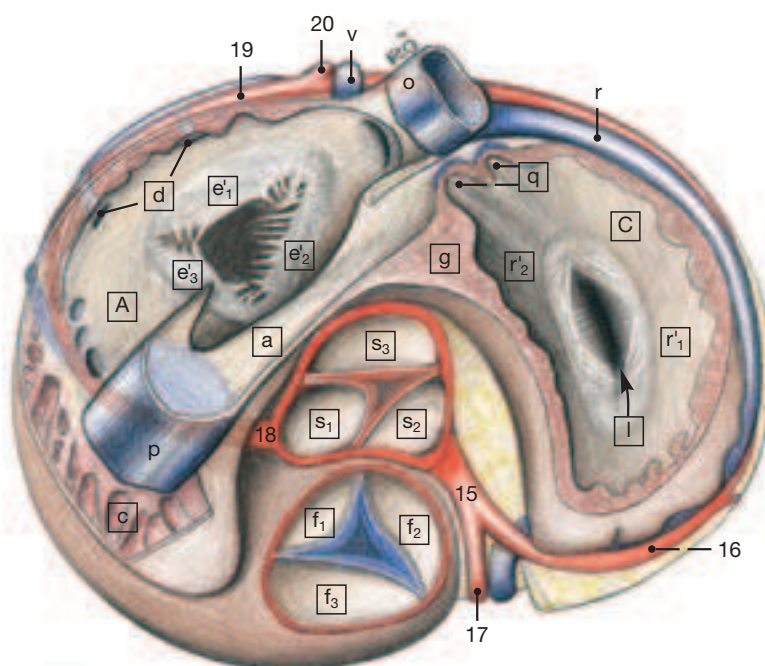
The heart makes direct contact with the ribs through the cardiac notches of the lungs from the 3rd to the 5th intercostal space on the left, and from the 3rd to the 4th space on the right (area of absolute dullness, caudal to triceps). More dorsally lung tissue intervenes between heart and chest wall (area of relative dullness). The four heart valves are best auscultated as follows: left AV, low in the left 5th intercostal space, aortic, high in the left 4th space, just below a horizontal line through the shoulder joint; pulmonary, low in the left 3rd space; and right AV-valve, low in the right 3rd or 4th spaces.

b) The distribution of the **BLOOD VESSELS** cranial to the heart is as follows: The parent artery is the **brachiocephalic trunk** (14), the only branch of the aortic arch near the base of the heart. It in turn gives rise to the **right subclavian artery**, a short bicarotid trunk for the **right** (see p. 61.q) and **left** (5) **common carotid arteries**, and (also) the **left subclavian artery** (7). The **costocervical trunk** (4), the first branch of the subclavian, gives off the **supreme intercostal** (1) and the **dorsal scapular** (2) **arteries**. The subsequent branches of the subclavian artery are the **deep cervical** (8) and the **vertebral** (3) **arteries**. The former passes into the dorsal part of the neck where it lies against the laminar part of the nuchal ligament, the latter passes toward the head through the transverse foramina of the cervical vertebrae and at the atlas anastomoses with the occipital artery; it then enters the vertebral canal where it contributes to the blood supply of the brain and spinal cord. The **supf. cervical artery** (6) is the last branch arising from the convexity of the subclavian; it passes forward to supply the ventral portion of the cervicothoracic junction. Finally, the **internal thoracic artery** (9), the last branch of the subclavian to arise within the thoracic cavity, passes ventrocaudally to course along the sternum. The corresponding veins by and large are satellite to the arteries.

c) The **NERVES** encountered within the thoracic cavity conform to the common pattern. Beginning ventrally, the **phrenic nerve** (see p. 61.h) crosses the base of the heart to gain the diaphragm. The **vagus** (e) at the aortic arch releases the left **recurrent laryngeal nerve** (h) and with its fellow from the other side furnishes the dorsal and ventral vagal trunks that accompany the esophagus through the diaphragm. The **sympathetic trunk** (12) lies on the bodies of the thoracic vertebrae. Its major branch, the greater **splanchnic nerve** (12), arises from the 6th to the 15th sympathetic ganglia.

d) The **THYMUS** (10), when at its largest (about 2 months after birth), fully fills the ventral part of the mediastinum cranial to the heart. Some of its tissue may extend into the neck to lie next to the trachea where, when broken up, it may be mistaken for caudal deep cervical lymph nodes. In rare cases thymus tissue may be encountered also near the thyroid gland.

Base of the Heart, sectioned in the dorsal (horizontal) plane



A* Right atrium

- a Sinus venosus
- b Coronary sinus
- c Pectinate muscles
- d Veins entering atrium

C Left atrium

- q Entrance of pulmonary veins

- g Interatrial septum
- h Fossa ovalis
- i Epicardium
- j Myocardium
- k Endocardium

B Right ventricle

- e Right atrioventricular (AV) valve
- e'₁ Parietal cusp
- e'₂ Septal cusp
- e'₃ Angular cusp
- e''₁ Great papillary muscle
- e''₂ Lesser papillary muscles
- e''₃ Subarterial papillary muscle
- f Pulmonary valve
- f₁ Right semilunar valve
- f₂ Left semilunar valve
- f₃ Intermediate semilunar valve

D Left ventricle

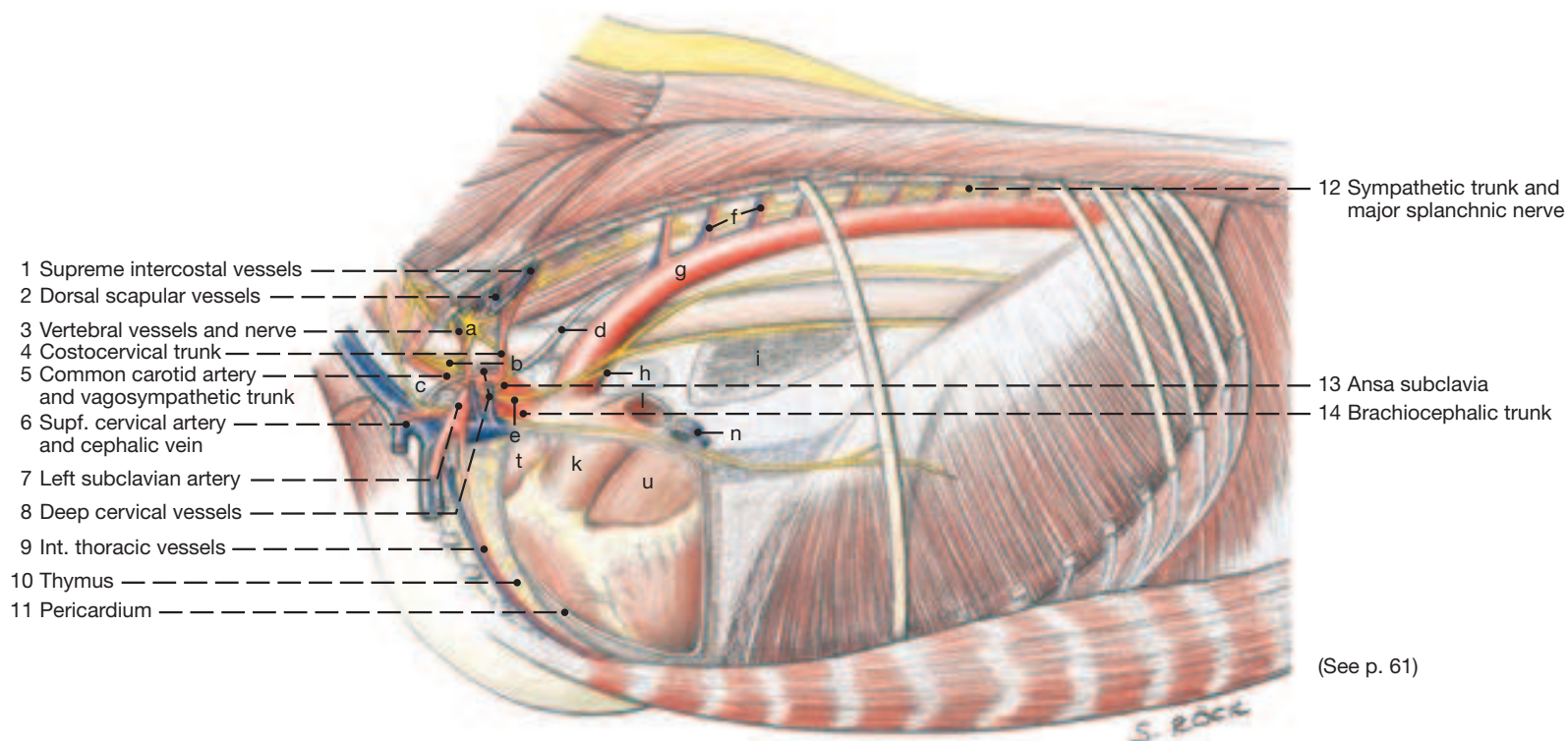
- r Left atrioventricular (AV) valve
- r'₁ Parietal cusp
- r'₂ Septal cusp
- r''₁ Subauricular papillary muscle
- r''₂ Subatrial papillary muscle
- s Aortic valve
- s₁ Right semilunar valve
- s₂ Left semilunar valve
- s₃ Septal semilunar valve

- l Atrioventricular orifice
- m Interventricular septum
- n Trabeculae septomarginales
- o Trabeculae carneae
- p Chordae tendineae

* The letters of the above legend are placed in squares on the drawings of the heart.

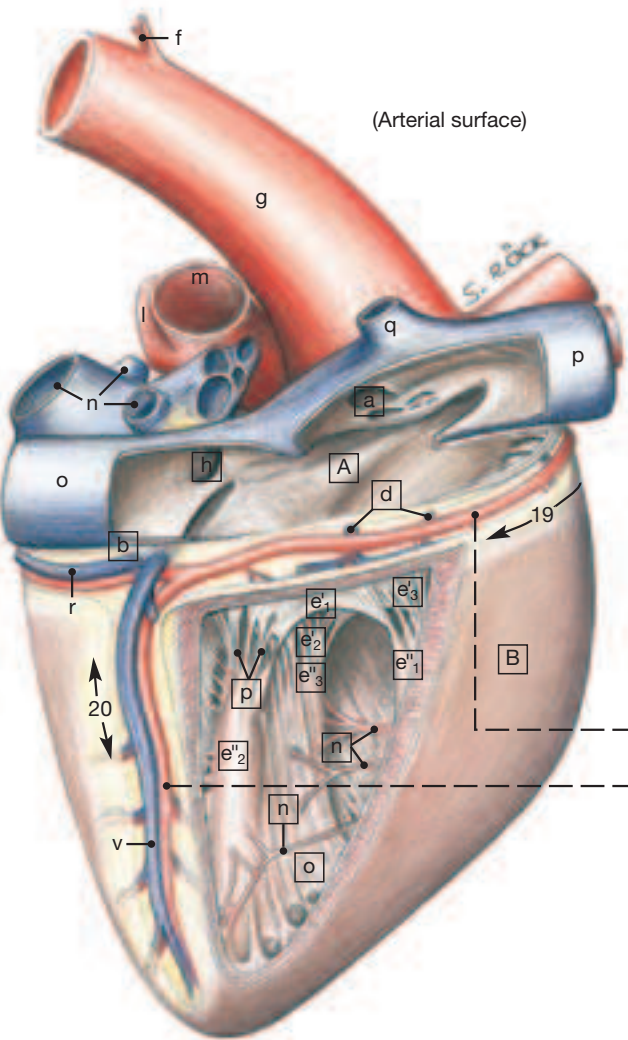
Thoracic Cavity and Heart

left lateral view

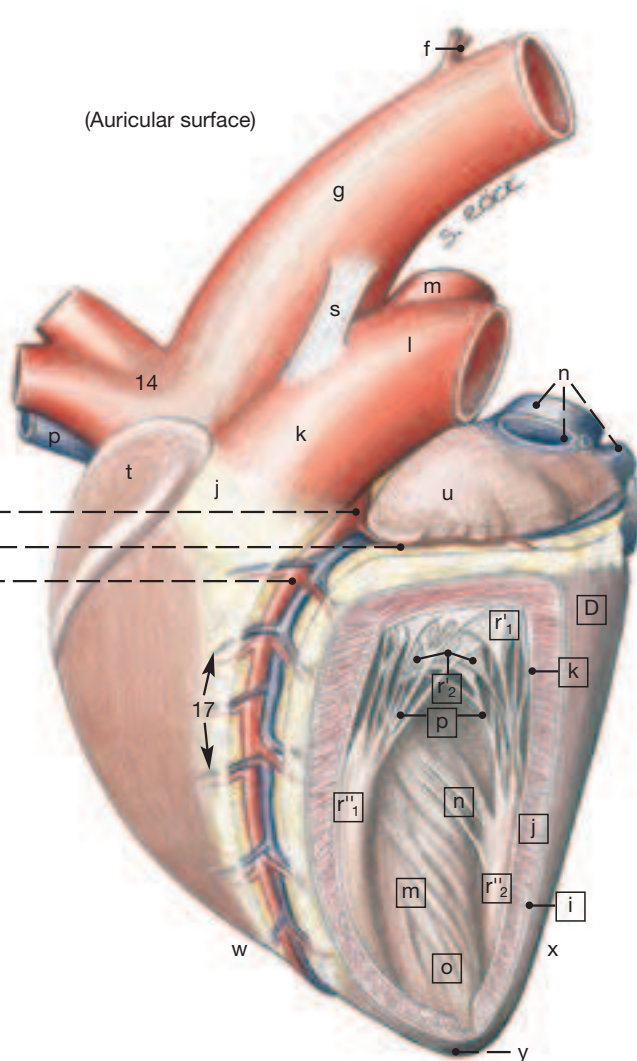


- | | | | | |
|----------------------------|---------------------------|--------------------------|----------------------|--------------------------------------|
| a Cervicothoracic ganglion | f Intercostal vessels | k Truncus arteriosus | p Cranial vena cava | u Left auricle |
| b Middle cervical ganglion | g Aorta | l Left pulmonary artery | q Right azygous vein | v Middle cardiac vein |
| c Trachea | h Recurrent laryngeal n. | m Right pulmonary artery | r Great cardiac vein | w Right ventricular (cranial) border |
| d Thoracic duct | i Interpulmonary adhesion | n Pulmonary veins | s Lig. arteriosum | x Left ventricular (caudal) border |
| e Vagus | j Conus arteriosus | o Caudal vena cava | t Right auricle | y Apex |

Right atrium and ventricle



Left atrium and ventricle



- | |
|---|
| 15 Left coronary artery |
| 16 Circumflex branch of 15 |
| 17 Paraconal interventricular groove and branch of 15 |
| 18 Right coronary artery |
| 19 Coronary groove |
| 20 Subsinoasal interventricular groove and branch of 18 |

Chapter 8: Abdominal Wall and Cavity

1. The Abdominal Wall

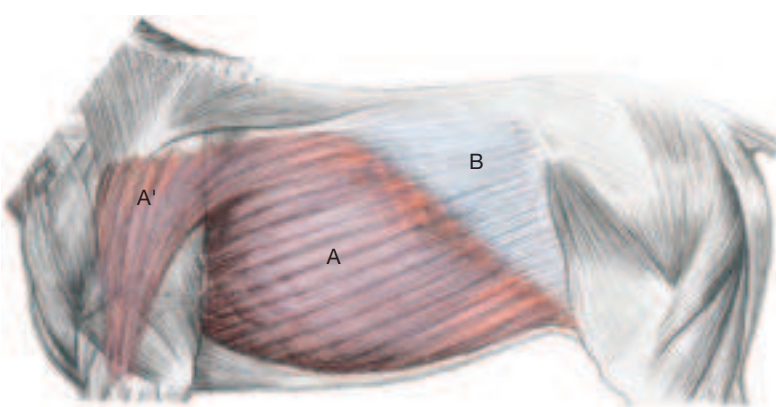
To show the supf. muscles and nerves (upper dissection on facing page) the skin and cutaneous muscles were removed. For the lower dissection the forelimb, latissimus dorsi, and external abdominal oblique were fully, and the internal abdominal oblique partly removed.

a) On the undissected, skin-covered trunk attention should be given of three palpable and sometimes visible features: the paralumbar fossa, the costal arch, and the so-called spur vein. The paralumbar fossa is a triangular depression cranioventral to the coxal tuber, bounded principally by the muscles of the back and the last rib. It is most obvious in emaciated subjects. The length of the thorax positions the end of the costal arch and the last rib close to the pelvis leaving a narrow flank between the last rib and the thigh. The **supf. thoracic (spur) vein** (2), becoming subcutaneous near the olecranon, passes caudally along the border of the deep pectoral muscle.

b) The subcutaneous **TRUNK FASCIA** (see also p. 74) consists of supf. and deep layers.

I. The **supf. trunk fascia** (B in the Fig. on this page) encloses the **cutaneous muscle of the trunk** (**M. cutaneus trunci**; A) which extends from the area of the olecranon to the withers and caudally to the level of the thigh. This large plate of muscle is thin dorsally, but up to 2 cm thick caudoventrally where it lies within the fold of the flank that connects the abdomen with the stifle. The muscle blends cranially with the **cutaneus omobranchialis** (A') that covers much of the triceps.

The palpable **subiliac lymph nodes** (10) lie on the cranial border of the tensor fasciae latae (cranial edge of thigh) dorsal to the stifle.



II. The part of the **deep fascia** that lies directly on the external abdominal oblique muscle contains much elastic tissue that colors it yellow and gives it the additional name, **tunica flava** (yellow) abdominis, or, less formally, **abdominal tunic** (4). It increases in thickness ventrally and blends with the linea alba. It functions in the support of the heavy abdominal viscera of this herbivorous animal.

1 The fibrous **linea alba** (see p. 75.18) connects the aponeuroses of the right and left abdominal muscles in the midventral line. It begins at the sternum, where it is about 2 cm wide, encloses the umbilicus widening slightly (3 cm), and caudal to this is very narrow. It ends on the prepubic tendon.

3 c) The **ABDOMINAL WALL** is formed by four abdominal muscles but it also includes portions of the ribs and the costal arch.

4 I. The **external abdominal oblique** (3) has a fleshy origin on the lateral surface of the ribs and, more caudally, on the thoracolumbar fascia. Its wide aponeurosis is divided into abdominal and pelvic tendons. The former inserts on the linea alba, the latter on the coxal tuber and the prepubic tendon between which points it is slightly thickened to form the inguinal ligament. A slit-like gap, the supf.

Clinical and Functional Anatomy p. 168

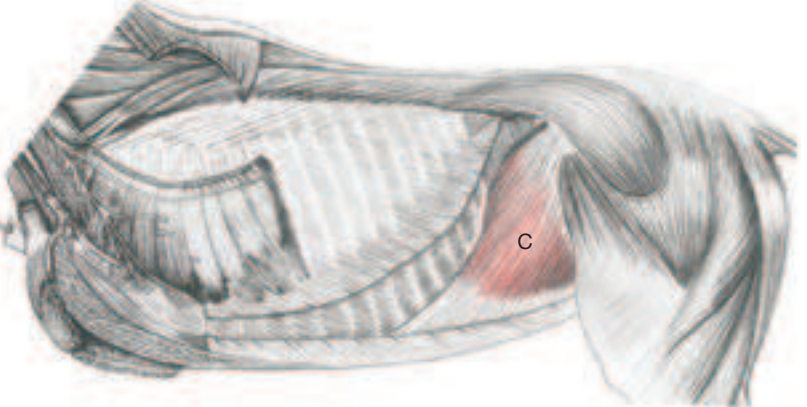
inguinal ring, partly separates the two tendons at the level of the prepubic tendon. The abdominal tendon combines with the aponeurosis of the internal abdominal oblique muscle to form the external rectus sheath (see further on).

Lateral cutaneous branches of spinal nerves T16–L4 pass through the external oblique muscle and the abdominal tunic that covers it. Those from L1 (5) and L2 (6) on their way to the skin of the thigh pass over the subiliac lymph nodes. The **lateral cutaneous femoral nerve** (11; from L3 and L4) accompanies the caudal branch of the **deep circumflex iliac vessels** (7), passes caudal to the lymph nodes, and innervates the medial skin of the thigh dorsal to the stifle.

II. The **internal abdominal oblique** (C on this page) takes origin from the coxal tuber and the inguinal ligament and ends on the costal arch and with its aponeurosis (which joins that of the external oblique) on the linea alba. Its musculoaponeurotic junction descends from the costal arch and bends caudally to follow the lateral border of the rectus abdominis. The free caudoventral border of the muscle forms the cranial margin of the deep inguinal ring.

III. The **transversus abdominis** (9) is the least extensive of the three flank muscles, its caudal border reaching only to the level of the coxal tuber. The muscle does not usually take part in the formation of the inguinal canal, but its aponeurosis, which also ends on the linea alba, forms the internal rectus sheath. The musculoaponeurotic junction passes caudodorsally, caudal and parallel to the costal arch, in the direction of the sacrum.

The **ventral branches of spinal nerves T16 to L3** pass ventrally imbedded in the lateral surface of the transversus muscle. They car-



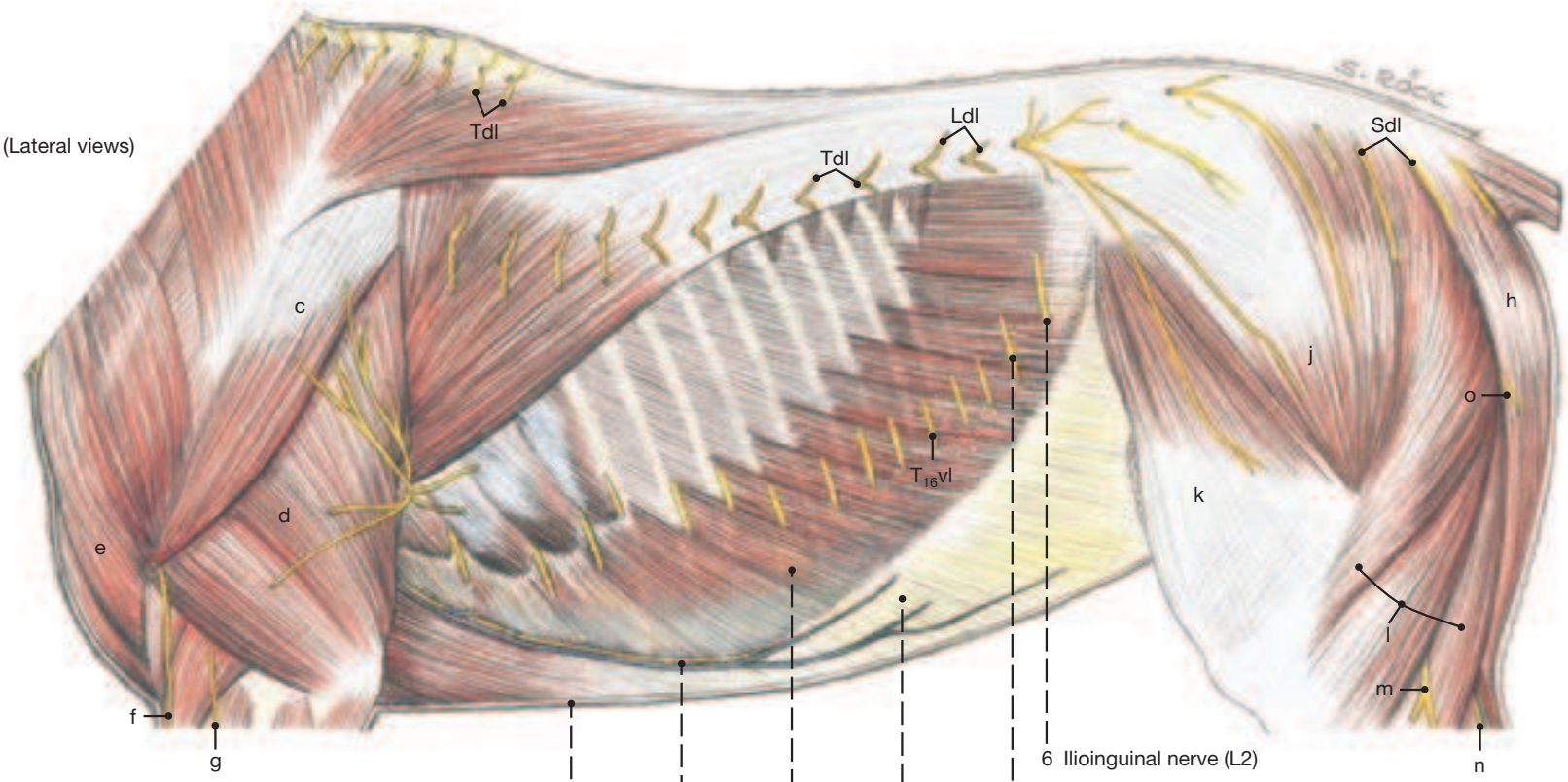
ry motor fibers for the rectus abdominis, sensory fibers for the parietal peritoneum, and close to the linea alba give rise to the short ventral cutaneous branches.

IV. The **rectus abdominis** (8) arises from the 4th to the 9th costal cartilages and adjacent parts of the sternum and ends principally—via the accessory ligament—on the head of the femur, but also on the prepubic tendon (see p. 76). It is marked by about ten **tendinous intersections** (8) which attach the muscle to the **external rectus sheath**. This enclosure (as already alluded to) consists of external and internal sheaths, the former a combination of the two oblique muscle aponeuroses, the latter furnished by the transversus abdominis.

d) The abdominal wall formed by these muscles is lined by **TRANSVERSE FASCIA**, and this in turn by parietal peritoneum. The transverse fascia blends caudally with the iliac fascia, which covers the iliopsoas, and that is continuous with the pelvic fascia.

e) The parietal **PERITONEUM** (see also p. 74) in the male animal sends an evagination (vaginal process) through the inguinal canal into the scrotum.

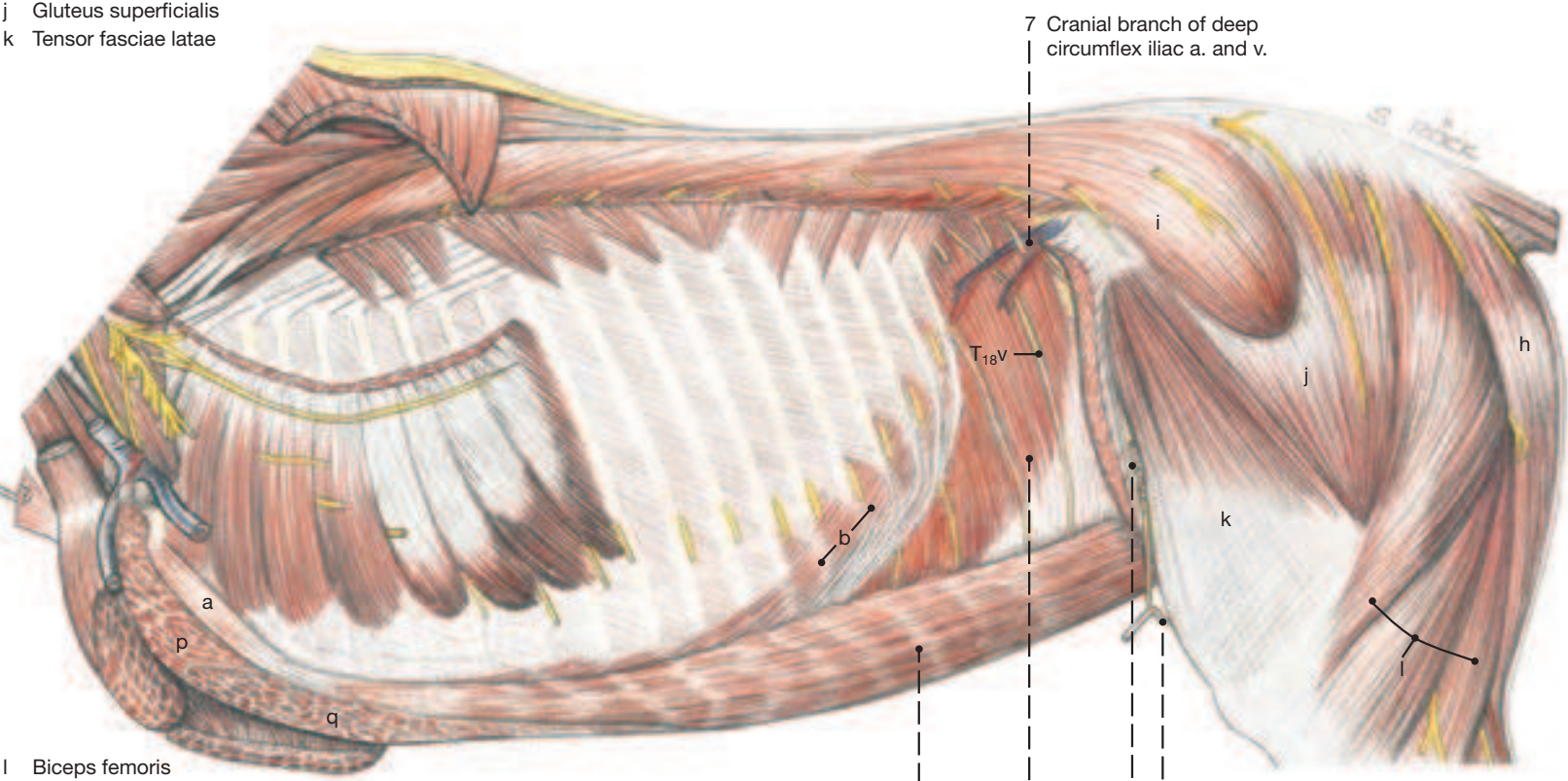
Superficial and Deep Dissections of the Trunk



- a Rectus thoracis
- b Internal intercostal muscles
- c Deltoideus, resected
- d Long head
- e Cleidobrachialis
- f Cran. cutaneous antebrachial n. (axillary)
- g Supf. branch of radial n.
- h Semitendinosus
- i Gluteus medius
- j Gluteus superficialis
- k Tensor fasciae latae

- 1 Skin
- 2 Supf. thoracic vein and lateral thoracic nerve
- 4 Abdominal tunic
- 5 Iliohypogastric nerve (L1)
- 6 Ilioinguinal nerve (L2)

(See p. 59)



- l Biceps femoris
- m Lateral cutaneous sural nerve
- n Caudal cutaneous sural nerve
- o Caudal cutaneous femoral nerve
- p Subclavius
- q Pectoralis profundus

- 7 Cranial branch of deep circumflex iliac a. and v.
- 8 Rectus abdominis with tendinous intersections
- 9 Transversus abdominis
- 10 Subiliac lymph nodes
- 11 Lateral cutaneous femoral nerve

Tdl Dorsal cutaneous br. of thoracic n.
Ldl Dorsal cutaneous br. of lumbar n.
Sdl Dorsal cutaneous br. of sacral n.
T16vl Lateral cutaneous br. of thoracic n. T16
T18v Ventral br. of thoracic n. T18

UQL|XbVxUmAVqC+HnIZ42uaraA==|1288008787

2. Topography of the Abdominal Organs and Their Relation to the Abdominal Wall

For the demonstration of the undisturbed organs of the abdominal cavity (dissections on facing page) the following structures were fully or partially removed: certain ribs and all intercostal tissues, diaphragm except for a narrow median strip, abdominal muscles except the rectus, parietal peritoneum, and the tensor fasciae latae.

Knowledge of the relationship of the abdominal organs to the abdominal wall is essential for the various methods by which these organs can be examined (rectal palpation, percussion, auscultation and abdominocentesis). It must be kept in mind, however, that the intestines in particular, because of their loose attachment, can shift markedly from the position most often depicted in anatomical illustrations. Least accessible are the organs covered by the ribs and costal arch, in the so-called intrathoracic part of the abdominal cavity. Most of them lie against the diaphragm and thus are overlain, in addition to the ribs, by portions of the lungs. The abdominal cavity, as a whole, is shaped like an egg whose pointed end occupies the cupola of the diaphragm, whose blunt end is at the pelvic inlet where the abdominal cavity opens into the pelvic cavity, and whose long axis is oriented from cranioventral to caudodorsal. Clinical examination is, of course, easiest through the soft abdominal wall caudal to the costal arch.

It is important for the diagnosis of positional changes and colic arising from these to understand the **ATTACHMENT** of the entire colon to the roof of the abdomen. The **ascending mesocolon** (see p. 71.33) splits off from the right side of the root of the mesentery. It does not form a sheet, but attaches the dorsal and ventral colon layers to each other, being visible only as narrow tissue bridges where the two pieces of gut come together. It extends, therefore, from the mesenteric root to the **pelvic flexure** (see p. 71.27) where it is sheet-like and spans the short distance between the two limbs of the flexure. Accordingly, the entire ascending colon except for its beginning and end (also adhered to the dorsal abdominal wall and base of the cecum) lies free on the abdominal floor and is subject to twisting or displacement. The descending mesocolon, however, is a regular sheet like the (jejunal) mesentery and allows also the descending colon considerable range in the caudal portion of the abdominal cavity.

a) LEFT SIDE

- 1** Left lobe of liver (1), stomach (2), and spleen (3) are intrathoracic and, with the exception of parts of the spleen covered also by lung. These organs are related ventrally to the **left dorsal colon** (9) and the beginning of the **dorsal diaphragmatic flexure** (7); though still under cover of the ribs, some parts of the left dorsal colon escape being blanketed by the lung. (See p. 71 for an understanding of the double flexures of the ascending colon.)

The upper part of the flank is occupied by a mixture of **descending colon** (5) and **jejunum** (4). The former has two bands (teniae) of which the free one as well as the sacculations (fecal balls) are prominent. The jejunum is without bands. Below these coils lie the caudal parts of the **left colon** (9; 10); the left dorsal has a smaller diameter than the left ventral; both become confluent in the **pelvic flexure** (6) which, shielded by the thigh, lies in front of the pelvic inlet often extending across the median to the right.

b) RIGHT SIDE

Quadrant (17) and **right lobes of the liver** (16), **right kidney** (15), and **descending** (13) and **transverse** (12) parts of the **duodenum** are intrathoracic on the right. Ventral to these organs lie the **base of the**

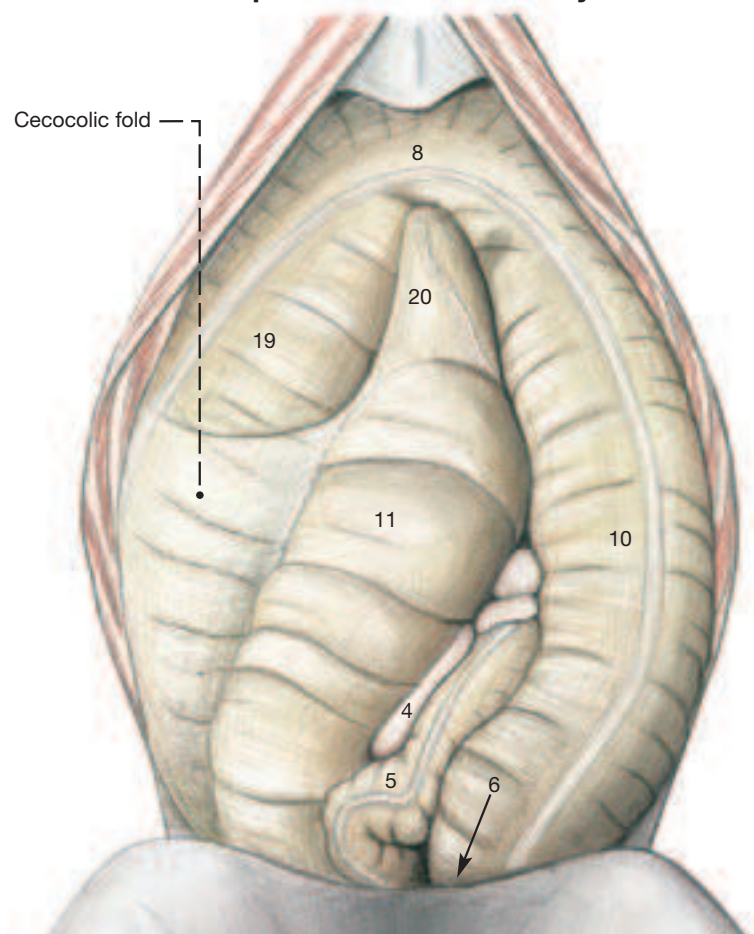
cecum (14) and the **capacious right dorsal colon** (18) turning cranially into the dorsal diaphragmatic flexure. The right lung covers the liver (except for its caudoventral angle), the kidney, and part of the duodenum.

The right flank is occupied by the **base of the cecum** (14) which is continued ventrally by the **body of the cecum** (11). This is directed craniomedially to allow the **right ventral colon** (19) to make contact with the costal arch.

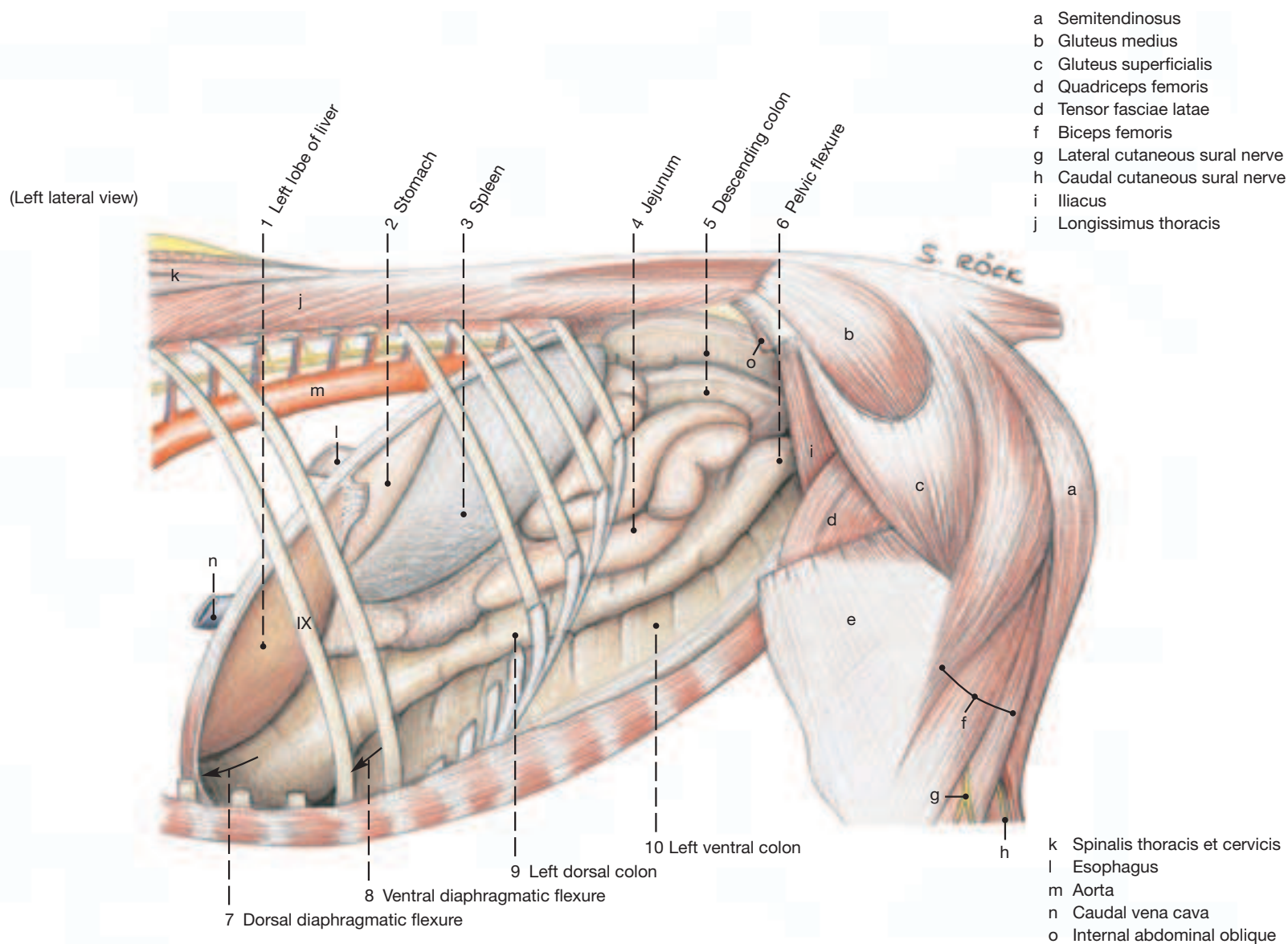
c) VENTRAL ABDOMINAL WALL

The dissection on this page depicts the abdominal organs that lie on the floor of the abdomen; the soft ventral abdominal wall was removed so that the organs are flanked by the right and left costal arches. The ventral loop of the ascending colon—**right ventral colon** (19), **ventral diaphragmatic flexure** (8), and **left ventral colon** (10)—dominates the field. Nestling between its parts are the **body** (11) and **apex** (20) of the **cecum**. The latter, among mammals, has the very unusual position, about 15 cm caudal to the xiphoid cartilage; the former is attached to the lateral free band of the right ventral colon by the **cecocolic fold**. This is an important landmark for blind orientation during abdominal surgery. Coils of **jejunum** (4) and **descending colon** (5; with prominent band) may insinuate themselves between the body of the cecum and the left ventral colon to make intermittent contact with the ventral abdominal wall which, close to the pelvis, rises steeply to the level of the pubic brim.

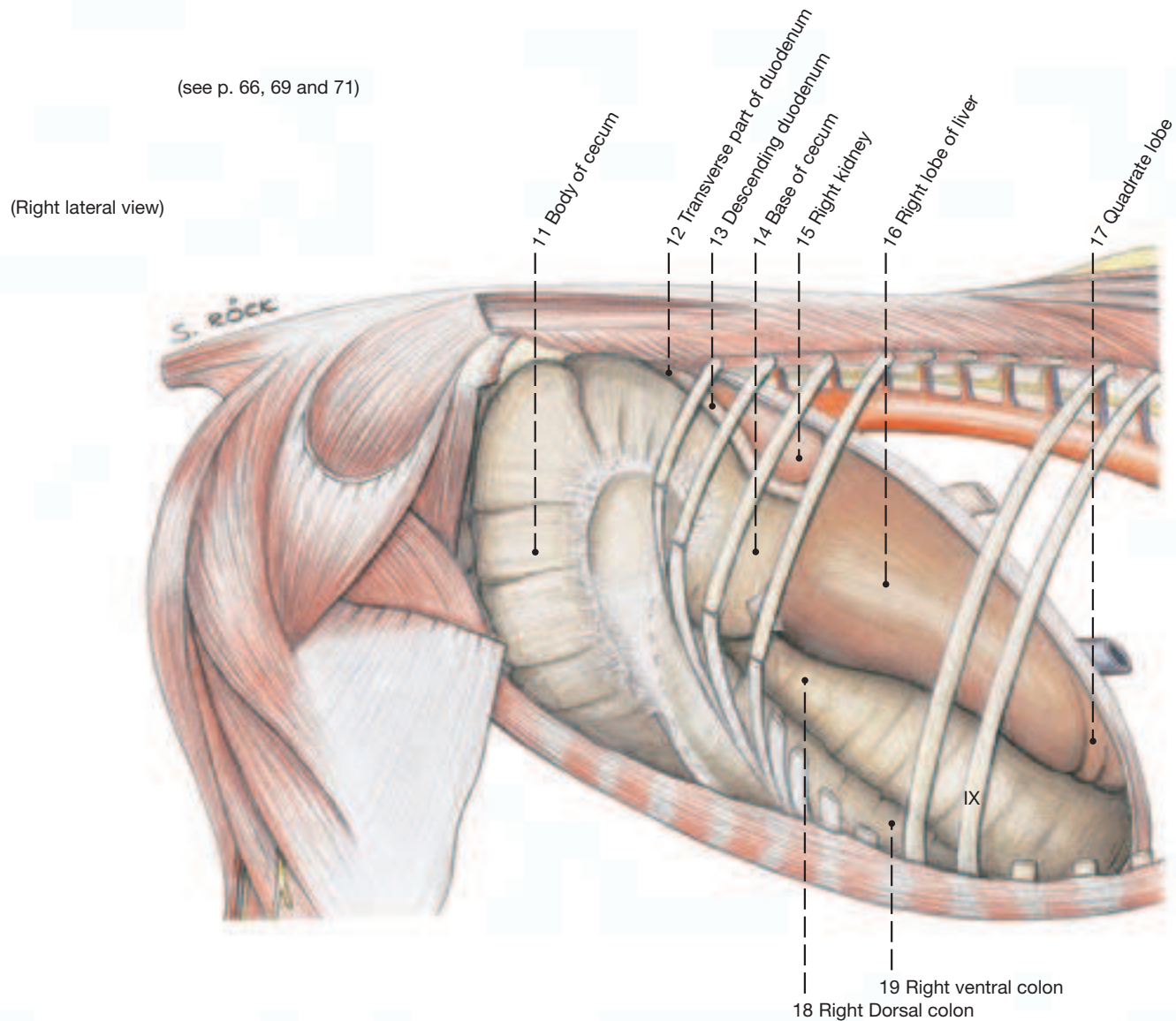
Ventral View of Opened Abdominal Cavity



Abdominal Cavity and Organs



(see p. 66, 69 and 71)



3. Spleen, Liver and Bile Duct, Pancreas, and Stomach with Omenta

a) The **SPLEEN** (11) in the fresh state is bluish; after death and exposure to air the red pulp becomes more obvious and colors the organ reddish-brown. Smooth muscle in capsule and supporting framework allows much variation in size and is important in the function of the spleen as a blood reservoir. The average weight of the spleen is about 1.5 kg. Thoroughbreds and other racers have relatively larger spleens and greater blood storage capacity than draft horses. The spleen is roughly triangular with a broad dorsal base and a ventral apex that is bent cranially. Its position varies slightly with respiration and with the distension of the stomach to which it is tied by the **gastrosplenic ligament** (9). The parietal surface of the spleen lies against the diaphragm under cover of the caudalmost ribs, dorsally opposite the last three intercostal spaces and ventrally reaching forward to the 9th to 11th interspaces. Its convex caudal border is roughly parallel and 10 cm cranial to the costal arch, but its caudodorsal end can protrude slightly into the flank (see p. 67). The visceral surface is divided by the long (ca. 50 cm) hilus into a small cranial gastric surface and a much larger intestinal surface and through these is related to stomach, pancreas, and intestines. The spleen is held in place by **gastrosplenic** (9), **phrenicosplenic**, and **renosplenic** (12) ligaments that connect it to stomach, diaphragm, and left kidney, respectively.

b) The **LIVER** accounts for about 1.5% of body weight and thus is relatively small when compared to that of the dog, a carnivore. Its large right lobe atrophies in many horses as a result of pressure from a chronically distended right ventral colon that lies under it (see p. 67).

The liver lies entirely within the intrathoracic part of the abdomen and extends from the 6th intercostal space cranioventrally on the left to the 15th interspace caudodorsally on the right. Much more of its mass lies to the right of the median plane (see p. 67). The **caudate lobe** (18) is notched at its ventral free border. A papillary process, is lacking. Its caudate process carries a distinct impression for the right kidney. The major characteristic of the equine liver is the absence of a gall bladder which in the other domestic mammals marks the border between the quadrate lobe and the large right lobe of the organ. The junction between the quadrate and the left medial lobe is well marked by the round ligament (obliterated umbilical vein) that passes caudally to the umbilicus in the free border of the **falciform ligament** (13). Before reaching its destination the round ligament courses subperitoneally for a short distance. A fissure separates **left lateral** (2) and **left medial** (19) lobes. The large **right lobe** (15) is undivided.

The liver is held in place by **right** (17) and **left** (21) **triangular ligaments**. They attach it to the fleshy periphery of the diaphragm. The **coronary ligament** (not shown) attaches the parietal surface of the liver to the diaphragm more centrally.

The hepatic ducts are relatively wide which may be related to the absence of a gall bladder. They merge within the organ to form the **common hepatic duct** (16). The latter is continued by the bile duct that opens into the duodenum at the **major duodenal papilla** (31 in Fig. on this page) situated in the second bend of the S-shaped cranial part.

c) The **PANCREAS** also opens with its **pancreatic duct** on the **major duodenal papilla**. Its **accessory pancreatic duct**, however, opens on the **minor duodenal papilla** (32) opposite the major papilla. The pancreas is roughly triangular; its **body** (2) is cranial and lies against the cranial part of the duodenum; it is perforated by the **portal vein** (d). The **left lobe of the pancreas** (10) extends across the median plane to the left where it makes contact with the stomach and the dorsal abdominal wall. The **right lobe** (4) follows the descending duodenum and is related to the right kidney and nearby base of the cecum.

d) The **STOMACH** of the horse is of the simple, unilocular kind and with a capacity of only 5–15 liters is small for such a large animal. It lies in the cranial part of the abdominal cavity entirely within the rib cage, mostly to the left of the median plane. It is strongly flexed with the result that entrance and exit, **cardia** (23) and **pylorus** (27' in Fig. on this page), lie close together. When moderately filled it lies opposite the 9th to the 14th intercostal spaces; but even when fully distended the stomach remains within the rib cage and fails to contact the abdominal floor. The cardia is fixed fairly solidly to the diaphragm at the esophageal hiatus, so that enlargements of the

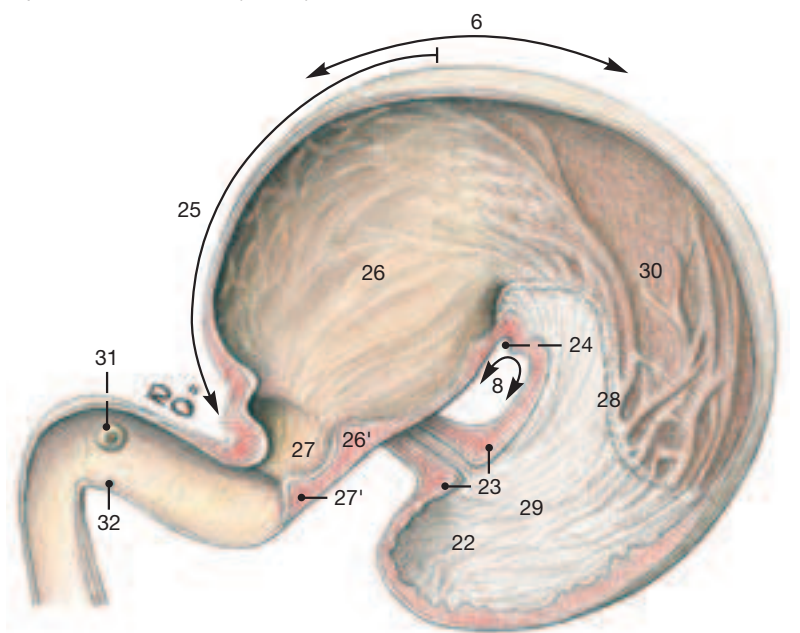
organ spread away from that point. Its **parietal (cranial) surface** is related to the diaphragm and the liver, while the **visceral (caudal) surface** faces the intestines.

The part of the stomach dorsal to the cardia, the **fundus**, is distinct in the horse and is known as the **blind sac (saccus cecus; 22)**. This is continued ventral to the cardia by the body which is joined to the **pyloric part** (25) at the deep **angular notch** (24). When the stomach is opened in the manner depicted on this page, the thickness of the **cardiac sphincter** (23) is revealed. This feature among others is thought to account for the horse's near inability to vomit. The two **sphincters** (26'; 27') at the pyloric end are also well developed, the more distal one especially, where the **pyloric canal** (27) is continued by the duodenum. The lining of the stomach is divided by the **margo plicatus** (28) into a proximal **nonglandular mucosa** (29) in the blind sac and body near the lesser curvature, and a **glandular mucosa** (26; 30) in the rest of the body and the pyloric part. In the fresh organ the former is light gray and harsh to the touch, while the latter is more reddish, softer, and smooth.

It is not possible to delimit grossly the three glandular zones. Histological sampling places the cardiac glands near the margo plicatus where they mix with the proper gastric glands of the distal body and beginning of the pyloric part; the pyloric glands are found in the rest of the pyloric part.

The stomach is attached to its surroundings by certain portions of the **greater**, and by the **lesser omentum**. The **greater omentum** (5) arises from the **greater curvature** (6), the lesser from the **lesser curvature** (8) of the organ. The two omenta and the visceral surface of the stomach enclose a subdivision of the peritoneal cavity known as the **omental bursa**. This sac-like potential space communicates with the general peritoneal cavity by a narrow (5 cm) canal named **epi-**

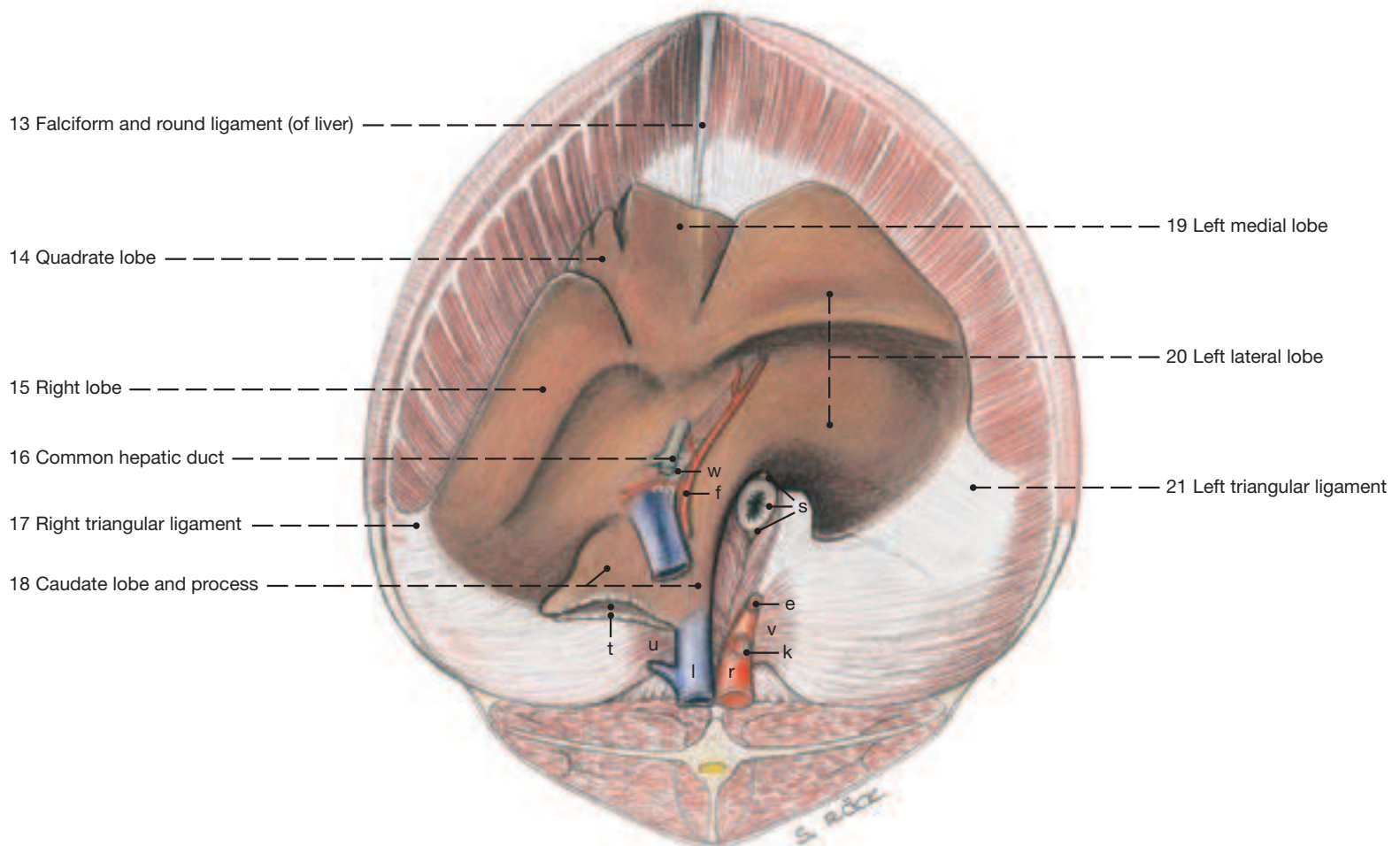
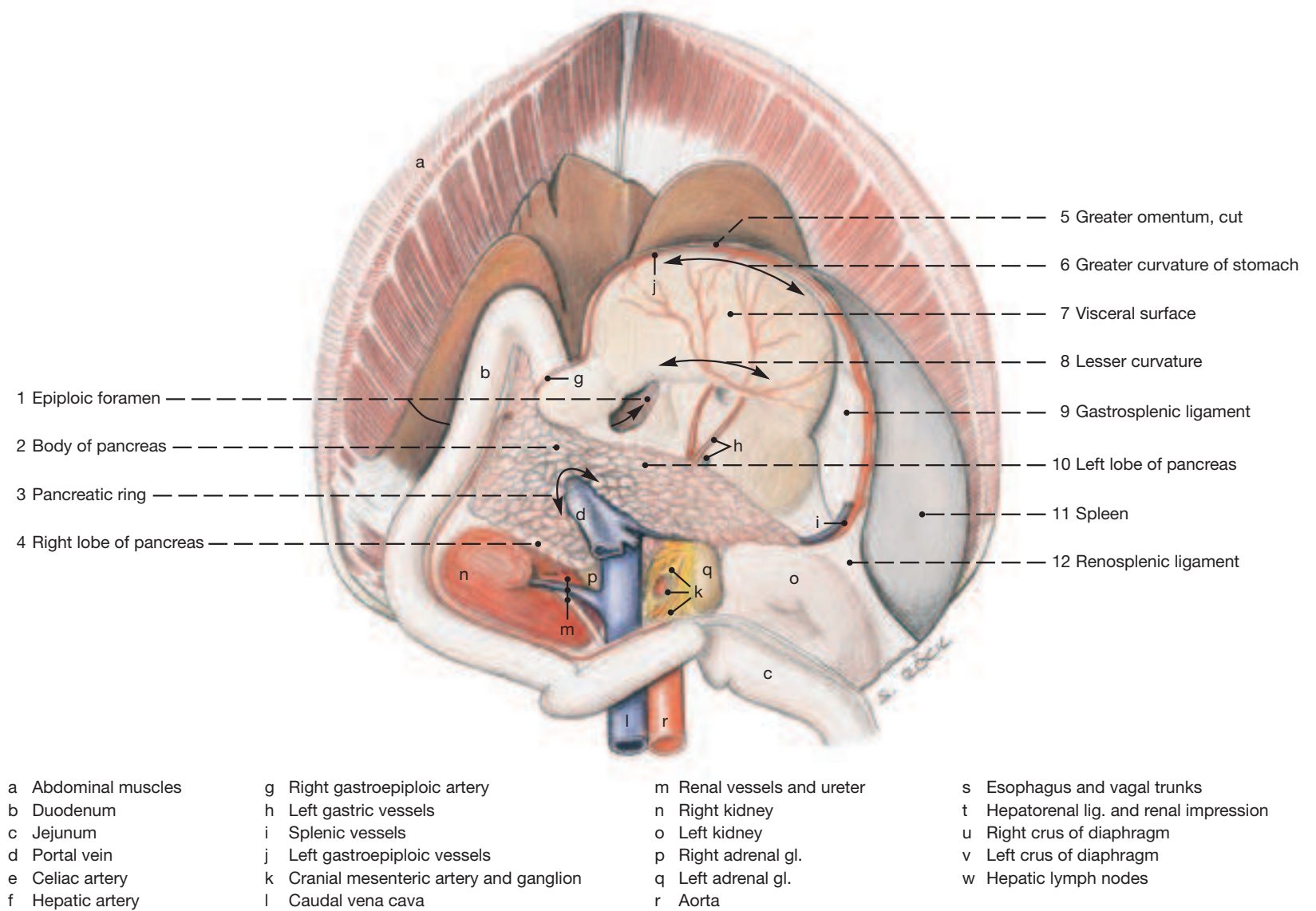
Stomach and Cranial Part of Duodenum,
opened on the visceral (caudal) surface



6 Greater curvature	25 Pyloric part	29 Nonglandular part
8 Lesser curvature	26 Pyloric antrum	30 Glandular part
22 Fundus, or blind sac	26' Sphincter of pyloric antrum	31 Major duodenal papilla
23 Cardiac sphincter at cardia	27 Pyloric canal	32 Minor duodenal papilla
24 Angular notch	27' Pyloric sphincter at pylorus	
	28 Margo plicatus	

ploric foramen (see p. 161, 68.2A). The foramen lies between the right lobe of the liver and the descending duodenum and extends medially between caudal vena cava and portal vein to allow access first into the vestibule, and then into the caudal recess of the omental bursa. The caudal recess is the part of the bursa that is enclosed almost entirely by the greater omentum; it is not extensive and is hidden from view between the stomach and the intestines; it has been removed in the upper dissection on the opposite page. The **gastrophrenic ligament**, a part of the greater omentum, attaches the greater curvature near the cardia to the crura of the diaphragm. The **gastrosplenic ligament** (9 on facing page) attaches the stomach to the spleen. The **lesser omentum** (not shown) spans the short distance between lesser curvature and the visceral surface of the liver which itself is well fixed to the diaphragm.

Spleen, Liver, Pancreas, and Stomach lying against the Diaphragm



(See p. 61, 67, 71 and 75)

4. Intestines

a) The **INTESTINAL TRACT** is divided into small and large intestines, although the terminal part of the latter, the descending or small colon, has a narrow lumen but it is easily distinguished by a prominent free band (tenia) and related sacculations (haustra).

1 The **small intestine** has three parts: duodenum, jejunum, and ileum; by and large it follows the general mammalian pattern.

2 The **duodenum** is about 1 m long. Its **cranial part** (1) begins at the pylorus with a slight enlargement and forms a sigmoid flexure that lies against the porta of the liver. The second bend of the flexure presents in its interior the **major and minor duodenal papillae** which lie opposite to each other and mediate the influx of bile and pancreatic juice (see p. 68). The **descending duodenum** (2) continues the sigmoid flexure and passes caudodorsally under cover of the liver to be followed at the right kidney by the **caudal flexure (transverse duodenum; 3)** that takes the duodenum from right to left around the caudal aspect of the root of the mesentery. As it enters the caudal flexure, high in the abdominal cavity, it is related and attached to the base of the cecum and to the transverse colon. The last segment, the **ascending duodenum** (4), is short, and medial to the left kidney it becomes the jejunum that has a markedly longer mesenteric attachment. The duodenojejunal junction is made plain by the cranial free border of the **duodenocolic fold** (5).

3 The **jejunum** (6), is about 25 m (70 feet) long; it is shorter in life. Owing to its long mesentery, jejunal coils can be found in many parts of the abdominal cavity; most of them, however, reside near the left flank, ventral to the pelvic inlet, and to the left of the cecum.

4 The **ileum** (7), about 50 cm long, continues the jejunum where the **ileocecal fold** (8) has its most proximal (oral) extent. It is characterized by a thick muscular coat that tends to narrow the lumen, although when relaxed in the fresh state after death the ileum may not appear or feel much different than the jejunum. The ileum ends on the **ileal papilla** (9) in the medial wall of the cecum at the junction of this organ's base and body.

The **large intestine** has three parts: cecum, colon, and rectum and is characterized in the horse by an expansive cecum and equally capacious parts of the colon which allow stasis of the ingesta for the purpose of their microbial destruction.

5 The **cecum** is about 1 m (4 feet) long and has a capacity of roughly 35 liters; it consists of **base, body, and apex**. The **base of the cecum** (10) occupies the right flank but extends forward as well to lie under cover of the last few ribs. (Since the latter part of the base is distal (aboral) to the ileocecal junction, it corresponds actually to the first part of the ascending colon as in most domestic mammals.) The base of the cecum is continued by a cylindrical **body** (12) that curves ventrally and cranially to follow the slope of the abdominal floor to the vicinity of the xiphoid cartilage where it is succeeded by the **apex** (13) that occupies the concavity of the ventral diaphragmatic flexure formed by the ascending colon. The cecal wall is gathered into sacculations by **four bands** of which the **medial** (16) and **lateral** (14) ones accommodate blood vessels and lymph nodes. The lateral band releases the **cecocolic fold** (18) that ties the right ventral colon to the cecum. The **dorsal band** (15) releases the ileocecal fold that ends on the ileum. The **ventral band** (17) is unremarkable except for joining the medial band shortly before reaching the apex of the organ.

The colon consists of ascending, transverse, and descending parts of which the first-named is the most capacious. For this reason it is also known as the **great colon** in contrast to small colon that designates the equine descending colon.

6 The **ascending colon** is about 4 m long, holds on average 80 liters, and is folded together to form a double loop consisting of **left** (26) and **right ventral** (20), and **left** (28) and **right dorsal** (30) parts. It begins at the **cecocolic orifice** (11) in the lesser curvature of the cecum that lies roughly opposite the costochondral junctions of the last two right ribs. Its first, slightly enlarged portion (**collum coli; 19**) deflects the digesta it contains from a caudal to a cranioventral direction which is the orientation of the first of the four parts, the

right ventral colon (IV*—20). This follows the right costal arch to the diaphragm which deflects the colon to the left side of the body in the form of the **ventral diaphragmatic flexure** (25). The latter is continued by the **left ventral colon** (IV—26) that passes toward the pelvic inlet on the left ventral abdominal wall. In the vicinity of the inlet the lumen decreases and the gut reflects upon itself to form the **pelvic flexure** (I—27); this many cross the median plane or lie within the pelvic cavity. The pelvic flexure is succeeded by the **left dorsal colon** (I—28). The two last-named segments because they carry only a single band (and that hidden in the mesocolic attachment; see further on) are without sacculations. The left dorsal colon passes cranioventrally to the diaphragm by which it is deflected to the right, **dorsal diaphragmatic flexure** (III—29), where the capacious **right dorsal colon** (III—30) begins. This has the largest diameter (ampulla coli) of the four parts of the ascending colon; but as it reaches the base of the cecum it is deflected to the left, decreases markedly in diameter, and crosses the median plan as the **transverse colon** (II—31). The latter lies cranial to the **cranial mesenteric artery** (45), and ventral to about the last thoracic vertebra, and adheres to the roof of the abdomen and the pancreas.

The **descending colon** (II—32), also known as small colon, is about 3 m (10 feet) long, is suspended by a broad mesocolon and mingles with the jejunum in the left flank.

The **rectum** (II—34), the last segment of the large intestine and about 30 cm in length, continues the small colon at the pelvic inlet. The **caudal mesenteric artery** (56) bifurcates into left colic and cranial rectal arteries that supply both the rectum and the caudal portions of the colon.

b) The **BLOOD SUPPLY** to the gastrointestinal tract follows the general mammalian plan despite the extraordinary shape of the large intestine. The **celiac artery** (35) splits into **splenic** (42), **left gastric** (37), and **hepatic** (36) arteries that pass to their respective organs. The **cranial mesenteric artery** (45) of many horses is subject to distortion by the activity of nematode larvae. Its principal branch, the ileocolic artery, gives rise to the **colic branch** (50) and the **right colic artery** (54) that supply the right and left ventral colons (first half) and the right and left dorsal colons (second half) of the ascending colon, respectively. These two vessels are of course very long; they anastomose at the pelvic flexure. Several (transverse) anastomoses connect the two vessels also in their initial course where they lie close together between the right dorsal and ventral colons. The **lateral** (52) and **medial** (51) cecal arteries also anastomose near the apex of the cecum.

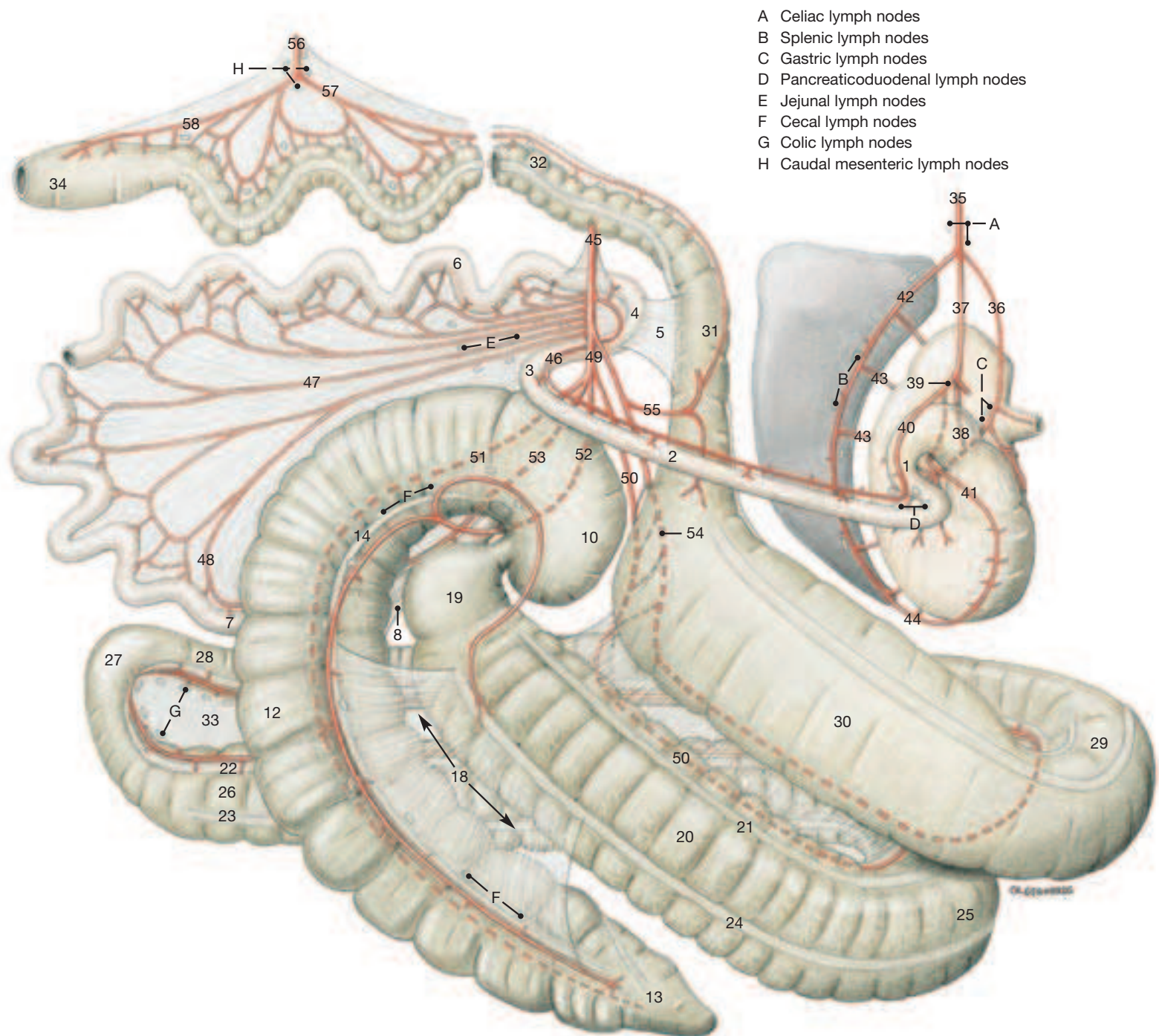
c) The **NERVE SUPPLY** of the intestines follows the general mammalian plan. The parasympathetic innervation is by the end-branches of the vagal trunks that follow the branches of the cranial mesenteric artery. The sympathetic innervation takes the same route but is brought to the region by the splanchnic nerves and passes through the ganglia in the root of the mesentery.

d) The position of the **LYMPH NODES** associated with the gastrointestinal tract can be determined by reference to the main drawing on the facing page: **celiac lymph nodes** (A), at the origin of the celiac artery; **splenic lymph nodes** (B), along the hilus of the spleen; **gastric lymph nodes** (C), in the lesser curvature of the stomach along the left gastric artery; **hepatic lymph nodes** (see p. 69), at the porta of the liver surrounding the portal vein; **pancreaticoduodenal lymph nodes** (D), between pancreas and descending duodenum; **jejunal lymph nodes** (E), in the dorsal, gathered part of the mesentery where the jejunal arteries originate; **colic lymph nodes** (G), between the dorsal and ventral layers of the ascending colon; **cecal lymph nodes** (F), along the medial and lateral bands of the cecum; and **caudal mesenteric lymph nodes** (H), grouped around the break-up of the caudal mesenteric artery.

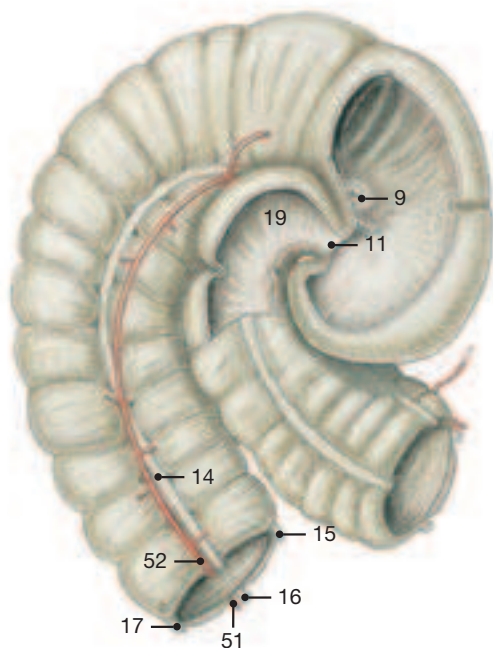
Lymph from the intestinal nodes is gathered by the intestinal lymph trunk that empties into the cisterna chyli. This is continued cranially by the thoracic duct which transports the lymph to the veins at the thoracic inlet.

* The Roman numbers following certain terms indicate the number of bands—and rows of sacculations—present on the corresponding segments and inform also on their relative capacity.

The Intestines, right lateral view



Part of Cecum and Right Ventral Colon, right lateral view



Duodenum
 Cranial part (1)
 Descending part (2)
 Transverse part (3)
 Ascending part (4)
 Duodenocolic fold (5)
 Jejunum (6)
 Ileum (7)
 Ileocecal fold (8)
 Ileal papilla and orifice (9)
 Cecum
 Base (10)
 Cecocolic orifice (11)
 Body (12)
 Apex (13)
 Lateral band (14)
 Dorsal band (15)
 Medial band (16)
 Ventral band (17)
 Cecocolic fold (18)

Colon
 Ascending colon
 Neck of colon (19)
 Right ventral colon (20)
 Lateral mesocolic band (21)
 Medial mesocolic band (22)
 Medial free band (23)
 Lateral free band (24)
 Ventral diaphragmatic flexure (25)
 Left ventral colon (26)
 Pelvic flexure (27)
 Left dorsal colon (28)
 Dorsal diaphragmatic flexure (29)
 Right dorsal colon (30)
 Transverse colon (31)
 Descending colon (32)
 Mesocolon (33)
 Rectum (34)
 Celiac artery (35)
 Left gastric artery (36)
 Hepatic artery (37)

Right gastric artery (38)
 Gastroduodenal artery (39)
 Cran. pancreaticoduodenal artery (40)
 Right gastroepiploic artery (41)
 Splenic artery (42)
 Short gastric arteries (43)
 Left gastroepiploic artery (44)
 Cranial mesenteric artery (45)
 Caud. pancreaticoduodenal artery (46)
 Jejunal arteries (47)
 Ileal artery (48)
 Ileocolic artery (49)
 Colic branch (50)
 Medial cecal artery (51)
 Lateral cecal artery (52)
 Mesenteric ileal branch (53)
 Right colic artery (54)
 Middle colic artery (55)
 Caudal mesenteric artery (56)
 Left colic artery (57)
 Cranial rectal artery (58)

Chapter 9: Pelvis, Inguinal Region, and Urogenital Organs

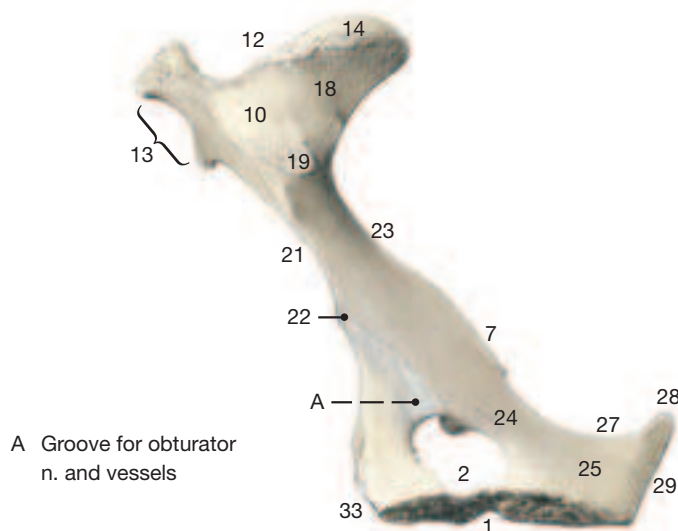
Clinical and Functional Anatomy p. 172

1. Bony Pelvis with Sacrosciatic Ligament, Supf. Inguinal Structures

- 1 a) **BONY PELVIS** (see upper Fig. on facing page): The bony pelvis comprises right and left hip bones (ossa coxarum) which are joined in the pelvic symphysis and united dorsally by the sacrum (see p. 164, Fig. 72.4, 72.5). The hip bones consist, from cranial to caudal, of ilium, pubis, and ischium. The pelvic symphysis ossifies in a cranio-caudal direction.

The **coxal tuber** (13) of the ilium lies under the skin as a nearly vertical palpable rectangle, whereas the **ischial tuber** (28), at the caudal end and belonging to the ischium, is covered by muscle. The ventral surface of the pubis presents a **groove for the accessory ligament** (33') and a wide **acetabular notch** (5). These features channel the accessory ligament to the head of the femur. The ligament represents the major insertion tendon of the rectus abdominis in the horse; it is absent in the other domestic mammals. The **obturator groove** (A on this page) guides the obturator nerve and accompanying vessels from the prominent **psoas minor tubercle** (22) to the **obturator foramen** (2). The floor of the pelvis is flat.

Right Os Coxae (Hip Bone), medial view

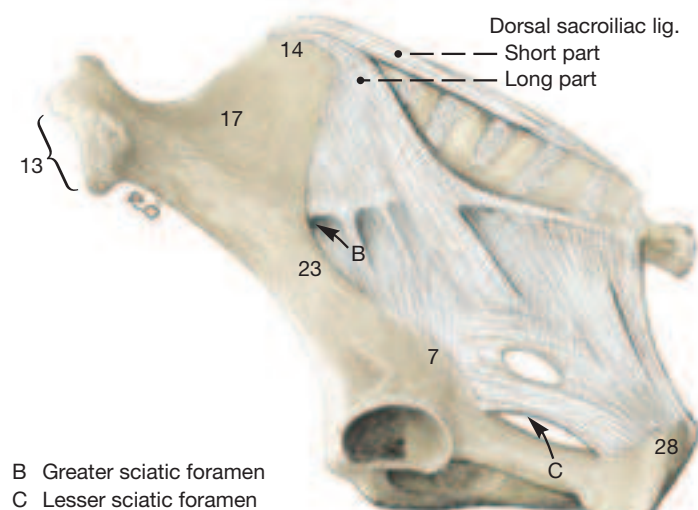


- 4 The pelvic inlet (framed by the terminal line) is round in the mare, while in the stallion it is pear-shaped with a lateral contraction toward the pelvic floor. Both vertical and transverse diameters of the pelvis are larger in the mare. The inlet of the male is marked in addition by an inconstant (age-related) **dorsal pubic tubercle** that lies opposite the **ventral pubic tubercle** (35) on the dorsal face of the bone.

- 6 b) The **SACROSCIATIC LIGAMENT** (upper Fig. on this page), characteristic of the large domestic ungulates, closes the pelvic cavity laterally. It extends from the lateral crest of the sacrum and the transverse processes of the first few caudal vertebrae to the **ischial spine** (7), and to the **ischial tuber** (28) leaving two openings, the **greater** (B) and **lesser** (C) **ischial foramina**, for certain structures to leave the pelvic cavity. The caudal border of the sacrosciatic ligament is covered, as is the ischial tuber at its ventral end, by the vertebral heads of the semitendinosus and semimembranosus muscles. It furnishes the lateral border of the triangular pelvic outlet whose dorsal apex is provided by a caudal (tail) vertebra, and whose ventral border is the **ischial arch** (29) that connects right and left ischial tubers. Because of the presence and fullness of the afore-mentioned vertebral muscular heads, the perineal (surface) region surrounding the anus (and vulva in the mare) is narrow with the result that an ischiorectal fossa is absent.

c) **SUPF. PUBIC AND INGUINAL STRUCTURES** (see lower Fig. on facing page): The stallion especially presents a median **symphyseal tendon fossa** (4) at the cranial extremity of the pelvic symphysis. It results from the failure of the right and left **gracilis** (8) tendons to unite; caudal to the fossa the tendons do unite to form the midsagittal

Left Sacrosciatic Ligament, lateral view



symphyseal tendon that attaches to the ventral surface of the pelvic symphysis and facilitates attachment of other thigh muscles in the crowded condition high between the thighs. The dissection of the unsplit hindquarters on the facing page shows that the **accessory external pudendal veins** (3) emerge from the symphyseal tendon fossa; they carry blood from the penis (or udder) to the deep femoral veins whose stumps are also depicted. The (proper) **external pudendal vessels** (11) pass through the inguinal canal and emerge as shown with the **genitofemoral nerve** (11) from the medial angle of the **supf. inguinal ring** (12) which lateral to these structures is covered on its deep surface by the **internal oblique muscle** (2).

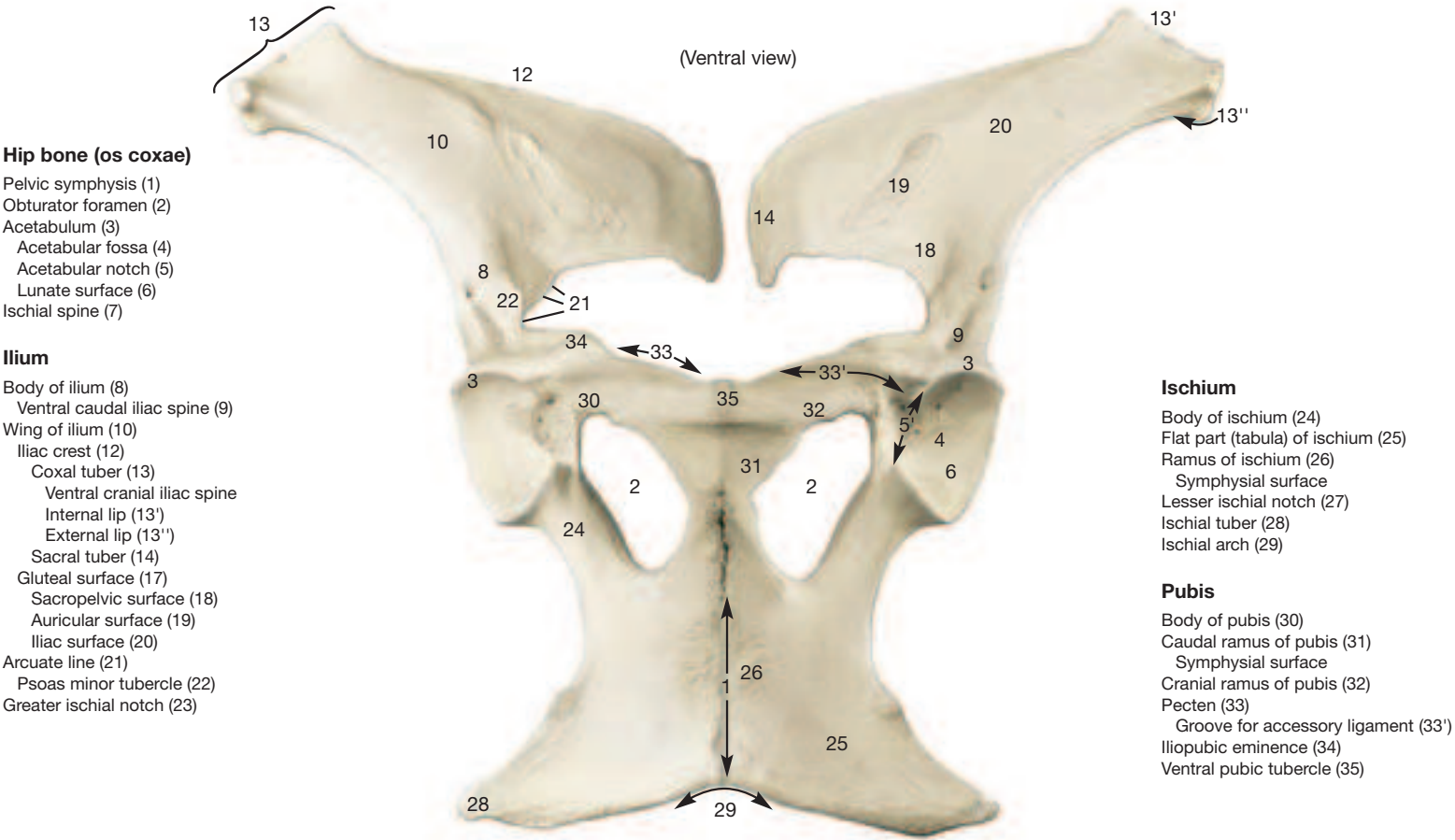
To appreciate how the large blood vessels supplying the hindlimb leave the abdominal cavity, the structures known as femoral triangle, vascular lacuna, and femoral canal need to be understood. The **femoral triangle** (7) is a nearly pyramidal space high in the medial surface of the thigh. The base of the pyramid is dorsal and is formed by the medial half of the vascular lacuna; the apex is ventral. The medial wall of the pyramid is formed by fascia and, more ventrally, by overlying skin. The cranial border of the femoral triangle is furnished by the **sartorius** (18), the caudal border by the **pectineus** (6).

The **vascular lacuna** (13) is an elliptical space between the inguinal ligament and the shaft of the ilium; its lateral half is occupied by the **sartorius** (18) that arises from the iliac fascia in the abdominal cavity and passes through the vascular lacuna to the vicinity of the stifle. The medial half of the vascular lacuna permits the external iliac vessels to leave the abdominal cavity in order to enter the thigh. As soon as they have passed through the vascular lacuna they occupy the femoral triangle and become the **femoral vessels** (15). They share the triangle with the deep inguinal lymph nodes (see p. 19.B). To complicate matters further, the medial extremity of the vascular lacuna is known as the **femoral ring** (5) that, in the intact state, is closed on the abdominal side by peritoneum and transverse fascia. The femoral ring lies medial to the external iliac vessels that pass through the vascular lacuna into the femoral triangle. In rare cases a loop of jejunum pushes through the femoral ring (femoral hernia) and comes to lie in the dorsomedial part (femoral canal) of the pyramidal femoral triangle.

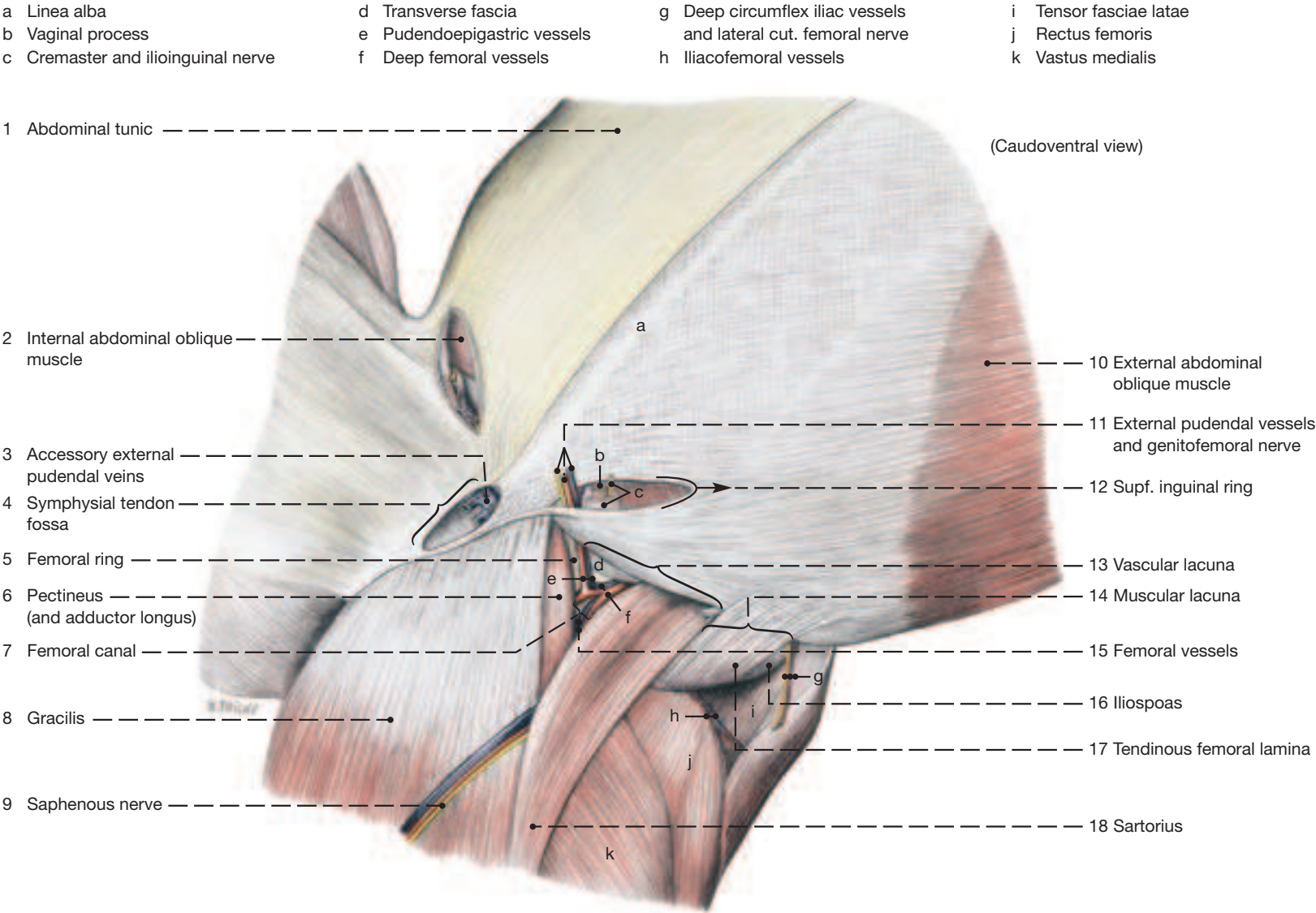
The **muscular lacuna** (14), in the standing horse, lies dorsolateral to the vascular lacuna. It conveys the **iliopsoas** (16), the femoral nerve and its branch, the **saphenous nerve*** (9), into the thigh. The contents of the muscular lacuna are overlain ventromedially by the **sartorius** (18), and ventrolaterally by the **abdominal tunic** (1) of the abdominal wall and by the **tendinous femoral lamina** (17) which is split off by the pelvic tendon of the **external abdominal oblique** (10) aponeurosis.

* Differing with certain textbooks, the saphenous nerve passes through the muscular lacuna (not the vascular), and the sartorius passes through the vascular lacuna (not the muscular).

Hip Bones



Supf. Pubic and Inguinal Structures



2. Inguinal Area

The complex inguinal area comprises the attachment of the soft ventral abdominal wall to the bony pelvis and, below this, scrotum and penis. It needs to be exposed both from the outside, and from inside the abdominal cavity, as shown in the lower Fig. on the facing page.

a) The **INGUINAL CANAL** is a flat, potential space between the internal and external abdominal muscles through which certain structures pass from the abdominal cavity into the subcutaneous tissues of the groin. The canal extends from the **deep inguinal ring** (6) at the free caudal border of the **internal abdominal oblique** (5) to the **supf. inguinal ring** (16) which is a slit in the aponeurosis of the external abdominal oblique muscle. The principal structure to use this route of exit in the stallion is the vaginal process and its contents. These are the **deferent duct** (7), the **testicular vessels** (17) accompanied by the testicular (nerve) plexus, and lymphatics; and, lying against the outside of the vaginal process, the **cremaster muscle** (4). The aggregate of these structures is known by the clinician as the **spermatic cord**. The mare lacks, of course, a vaginal process, but in some a tiny peritoneal and fascial evagination can be detected; the round ligament of the uterus and a weak cremaster muscle can be followed through the canal to the base of the udder (see p. 77). In both sexes the **genitofemoral nerve** (3), branches of the **second lumbar nerve** (L2; 2), and the **external pudendal vessels** (14) pass through the inguinal canal.

I. The **skin** (9) is reflected over the testes to form the **scrotum** (s) which has few hairs, is pigmented, and glistens from the secretion of sweat and sebaceous glands. Smooth muscle (tunica dartos) as a deep component of the scrotal skin, but also in the **scrotal septum** (20), wrinkles the skin in cold weather and helps to draw the testes closer to the body.

II. The elastic **abdominal tunic** (8; see also p. 73) that covers the external abdominal oblique muscle, in the stallion gives rise at the supf. inguinal ring to the **external spermatic fascia** (8') which encloses the spermatic cord and the testes. (A homologous but much less developed fascia can be dissected also in the mare; see p. 77.) The abdominal tunic also blends with the **fascia lata** (19) where thigh and abdominal wall lie against each other. In the ventral midline the abdominal tunic is anchored to the **linea alba** (18), from which, in the mare, the medial lamina of the suspensory apparatus of the udder arises; the lateral laminae originate from near the supf. inguinal ring and cover the sides of the udder (see p. 77). Similar laminae can be demonstrated in the stallion as the **suspensory ligament of the penis** (8'') that reaches also the prepuce. An additional sheet (lamina femoralis fascialis*; 8''), unrelated to penis and spermatic cord, extends from the fascia covering the lateral crus of the supf. inguinal ring to the thigh and opens the ring when the stallion spreads its hind limbs apart as occurs during service.

III. The **external abdominal oblique** (10) presents a slit-like defect between its **pelvic** (10') and **abdominal** (10'') tendons which was already described as the **supf. inguinal ring** (16). The ring is easily seen on the deep (internal) surface of the muscle (right side on lower Fig. on facing page). On the supf. (external) surface of the muscle, the ring is covered by the tube-like **external spermatic fascia** (8') which has been fenestrated on the left side of the same Fig..

The **internal abdominal oblique** (5) has a free border where it deviates from its attachment on the inguinal ligament. The free border and the inguinal ligament caudal to it form the **deep inguinal ring**

(6) which is a fusiform opening with **lateral** (6') and **medial angles** (6''). The **vaginal process** (13'') passes through the lateral angle of the ring, while the **external pudendal artery** (14) passes through the medial angle which lies close to the lateral border of the **rectus abdominis** (15). The cremaster passes through the ring together with the vaginal process. It is a phylogenetic detachment from transversus abdominis and internal abdominal oblique muscles but has acquired an origin of its own from the inguinal ligament.

The caudal border of the **transversus abdominis** (11) is at the level of the coxal tuber and thus does not reach the area of the inguinal canal or its rings.

IV. The **transverse fascia** (12) that lines the internal surface of the abdominal muscles evaginates the **internal spermatic fascia** (12') at the deep inguinal ring that encloses the vaginal process and with it passes through the inguinal canal. The fascia on its way to the testis changes to loose connective tissue that facilitates the sliding movements between the coverings of spermatic cord and testis. (In a closed castration the testis, still covered by vaginal tunic and spermatic fasciae, can be peeled out of the scrotum and detached after ligation.) In stallions with inguinal hernia, the area where the internal spermatic fascia becomes loose connective tissue forms a typically contracted ring. Cutting the ring is necessary for returning the herniated intestine to the abdominal cavity.

V. At the **vaginal ring** (13') the **parietal peritoneum** (13) forms the tubular but blind **vaginal process** (13'') which also passes through the inguinal canal. Spermatic cord and testis “sink into” the vaginal process and thus gain their immediate coverings known as the visceral and parietal vaginal tunics. The potential space between the two tunics (vaginal cavity) is continuous with the peritoneal cavity at the vaginal ring.

The **wall of the inguinal canal** consists of different tissues: the fleshy part of the internal abdominal oblique cranially and the pelvic tendon of the external oblique caudally—not the criteria of a canal. The inguinal canal is actually a potential space between these two muscles that are spread apart by the structures that pass through it and by loose connective tissue. The medial and lateral boundaries of the space are ill defined. The length of canal in a medium-sized horse, when measured along the spermatic cord, is about 15 cm, whereby it is necessary to remember that the cord enters the canal close to the lateral angle of the deep inguinal ring, and leaves it near the medial angle of the supf. inguinal ring.

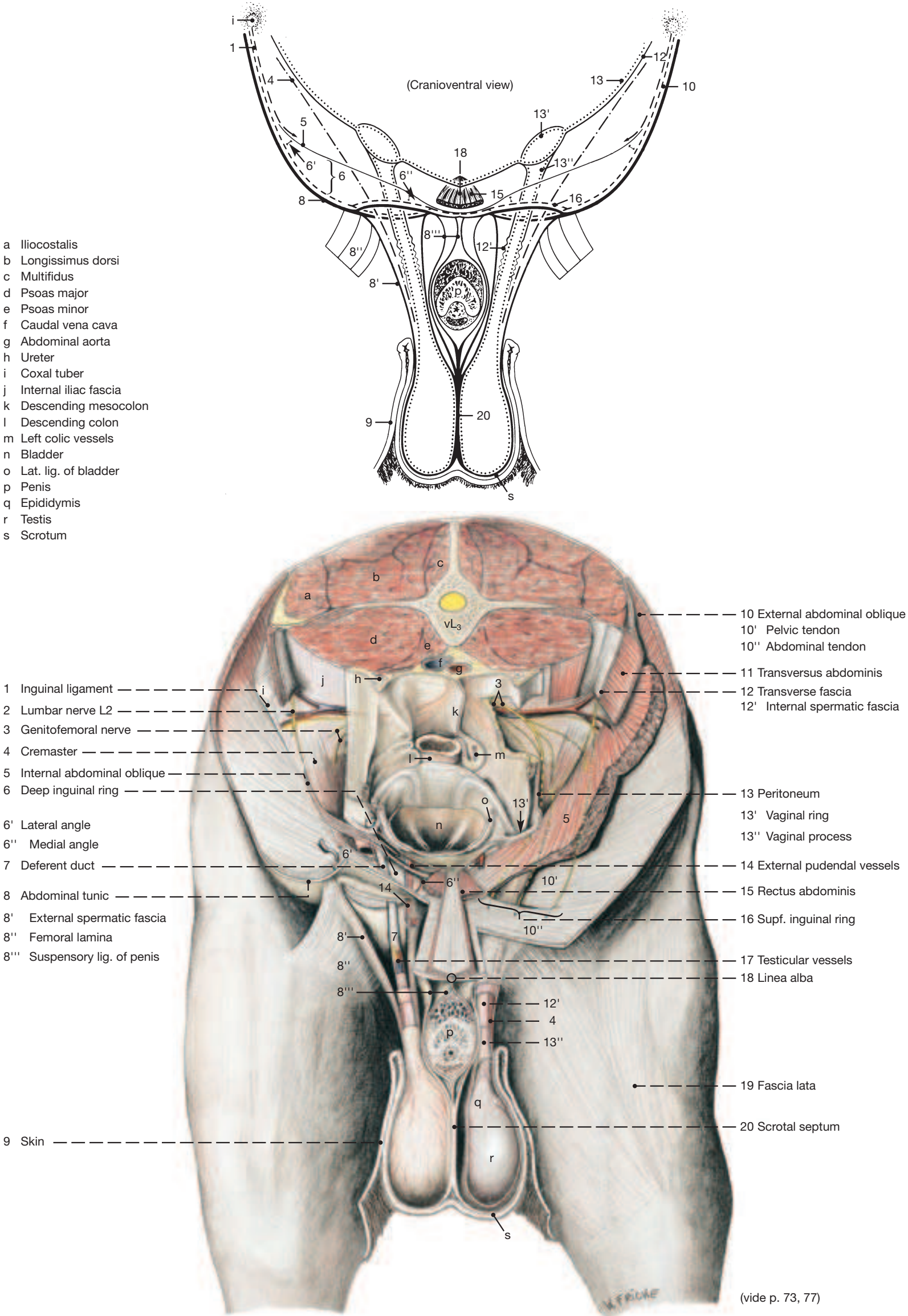
Upon approaching the pubic brim the **rectus abdominis** (15) tendons curve toward a median decussation of their fibers to penetrate the prepubic tendon. At the caudal angle of the supf. inguinal ring the abdominal tendon of the external abdominal oblique and the overlying abdominal tunic join the rectus fibers to form the accessory ligament of the femur.

b) The **INGUINAL LIGAMENT** (1) arises from the coxal tuber and ends within the prepubic tendon. After leaving the tuber it blends with the iliac fascia that covers the iliopsoas muscle. About its middle, the ligament loses contact with the fascia and unites with the pelvic tendon of the external abdominal oblique muscle** with which it concludes its course to the prepubic tendon. The lateral part of the inguinal ligament gives origin to a portion of the internal abdominal oblique by which it is hidden from view. In the lower Fig. on the facing page, the muscle origin has been removed to fully expose the ligament.

* Differing with certain texts, the lateral crus of the supf. ring does not split off an aponeurosis but a fascial sheet.

** The two united parts (inguinal ligament and the pelvic tendon of the external abdominal oblique) are known as the inguinal arch.

Inguinal Rings and Vicinity in the Stallion (♂)



3. Prepubic Tendon, Inguinal Canal of the Mare, Nerves of the Lumbar Plexus, Hypaxial Lumbar Muscles, and Udder

Clinical and Functional Anatomy p. 173

a) PREPUBIC TENDON

- 1** The **prepubic tendon** (2) is a strong, transversely oriented, fibrous mass set against the pecten of the pubis and extending from one iliopubic eminence to the other. The prepubic tendon is formed principally by the right and left **pectineus (and adductor longus) muscles** (5) whose tendons of origin, after arising from the pecten on both sides of the median as far laterally as the iliopubic eminences, decussate ventromedial to the pelvic symphysis. (The tendinous cranial parts of the gracilis and external obturator muscles also take part in its formation.)

The **inguinal ligament** (1) together with the pelvic tendon of the external abdominal oblique join the lateral parts of the prepubic tendon. The **accessory ligament** (4), the insertion tendon of the rectus abdominis, perforates, but also attaches itself to, the prepubic tendon and eventually passes via the acetabular notch to the fovea on the femoral head, accompanied the last few cm by the **ligament of the femoral head** (3).

- 2** The **linea alba** (14) is formed by the convergence of the aponeuroses of the flat abdominal muscles in the ventral midline. It is several cm wide near the umbilicus, but narrows to a few mm as it joins the prepubic tendon between the bellies of the rectus muscles.

b) STRUCTURES ASSOCIATED WITH THE INGUINAL CANAL OF THE MARE

The evaginations of the **peritoneum** (19, not shown on this side but at 12), the **transverse fascia** (12), and the **abdominal tunic** (13) are much less prominent than in the male, not always present, and difficult to demonstrate. The **round ligament of the uterus** (11) contains small amounts of smooth and striated muscle and presents a small, pendulous appendage near its origin from the uterine horn. It and a rudimentary cremaster muscle can be traced through the inguinal canal to where they end at the base of the udder. (In the specimen from which the lower Fig. on the facing page was drawn, the cremaster [see p. 75.4] was relatively well developed.)

c) THE NERVES OF THE LUMBAR PLEXUS (VENTRAL BRANCHES OF L2 TO L6)

Nerve L1 continues solely the ventral branch of the first lumbar nerve and thus cannot be regarded as belonging to the lumbar plexus, though it is often described under that heading. It takes a subperitoneal course to the vicinity of the deep inguinal ring and takes part in the innervation of the caudal parts of the internal abdominal oblique and the transversus abdominis muscles. Its sometimes double lateral cutaneous branch perforates (and also supplies) the abdominal muscles to innervate the skin and the fold of the flank.

Nerve L2 (18; with contribution from L3) also supplies the skin and the fold of the flank with its lateral cutaneous branch. It crosses the ventral surface of the **deep circumflex iliac vessels** (9), shortly before the latter penetrate the flank, to pass with one or two branches through the lateral part of the supf. inguinal ring.

The **lateral cutaneous femoral nerve** (10; from L3 and 4) obliquely crosses the dorsal surface of the deep circumflex iliac vessels and then accompanies their caudal branch through the body wall to the flank fold.

The **genitofemoral nerve** (20; from L2 to 4) crosses the deep circumflex iliac vessels more medially with one or two branches and passes through the medial part of the supf. inguinal ring.

The **femoral** and, its branch, the **saphenous nerves** (see p. 19.12; 19.25; from L4 to 6) were described on p. 18.

Also the **obturator nerve** (see p. 19.5; from L4 to 6) was already described on p. 18.

d) HYPAXIAL LUMBAR MUSCLES

For **psoas major** (7), **psoas minor** (8), and **quadratus lumborum** (not shown) consult the Tables on the musculature on p. 99.

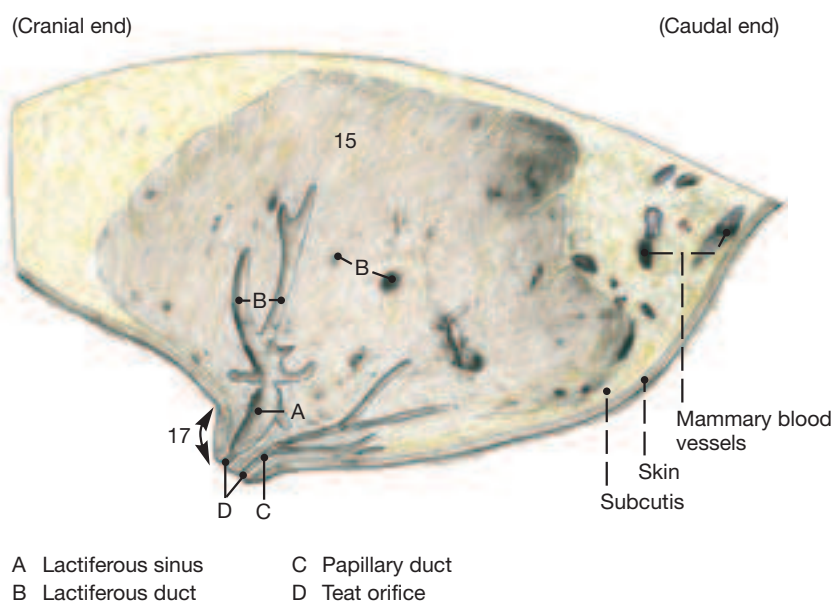
e) UDDER

The **udder** of the mare lies ventral to the area where the ventral abdominal wall joins the bony pelvis. Its shape and size are related to the functional state of the ovaries. It is a relatively small gland, hardly noticeable in the virgin mare but rounded and semispherical during the latter part of pregnancy and subsequent lactation. One hair (or more) protruding from the teat orifice, as well as other less obvious features remind us that the mammary gland is an enormously enlarged apocrine sweat gland. The hair disappears at the beginning of lactation or is worn off by the foal during suckling. Secretions of both sebaceous and sweat glands in the tip of the teat (or perhaps precocious colostrum) fill the two teat orifices and cover the tip of the teat with a waxy material whose presence indicates that foaling is imminent.

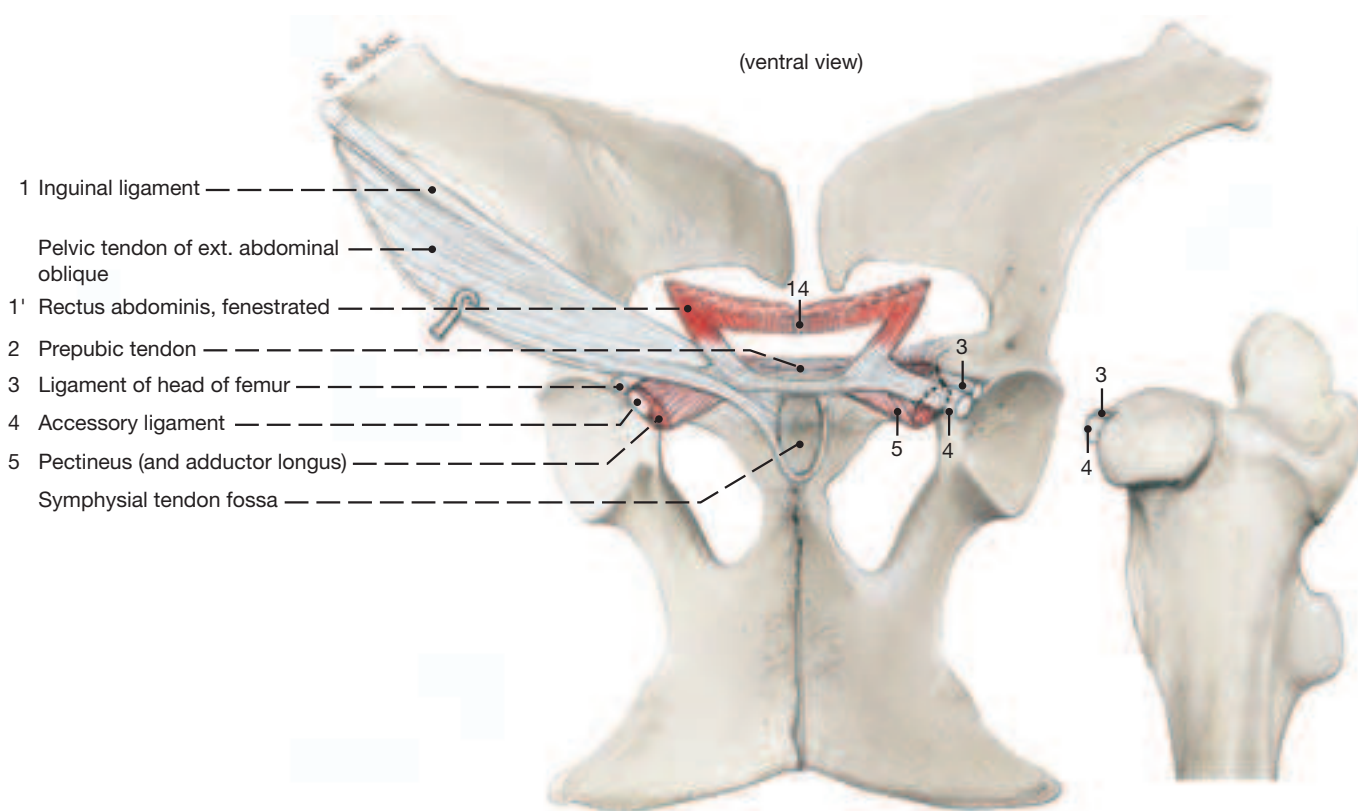
The udder (see Fig. on this page) comprises right and left **mammary glands** (15) each surmounted by a **teat** (17). Each gland accommodates two (sometimes three) duct systems which channel the milk through increasingly larger **lactiferous ducts** (B) into a **lactiferous sinus** (A) in the base of the teat and in the teat itself (teat sinus). Two **papillary ducts** (C) ending at the **teat orifices** (D) convey the milk to the outside. Though the two duct systems in each half of the udder are separate, the glandular tissue belonging to each can only be demonstrated by injections of different color suspensions into the two orifices. (For blood and nerve supply of the udder see p. 80.)

The udder is supported by a **suspensory apparatus** (21) that comprises medial and lateral laminae. The paired **medial lamina** (21') is elastic and arises from the abdominal tunic near the linea alba and separates the two halves of the udder along the prominent **intermammary groove** (16). The **lateral laminae** (21'') are less elastic though they arise also from abdominal tunic but in the vicinity of the supf. inguinal rings from where they pass lateral to the glandular tissue and separate it from a layer of adjacent fat.

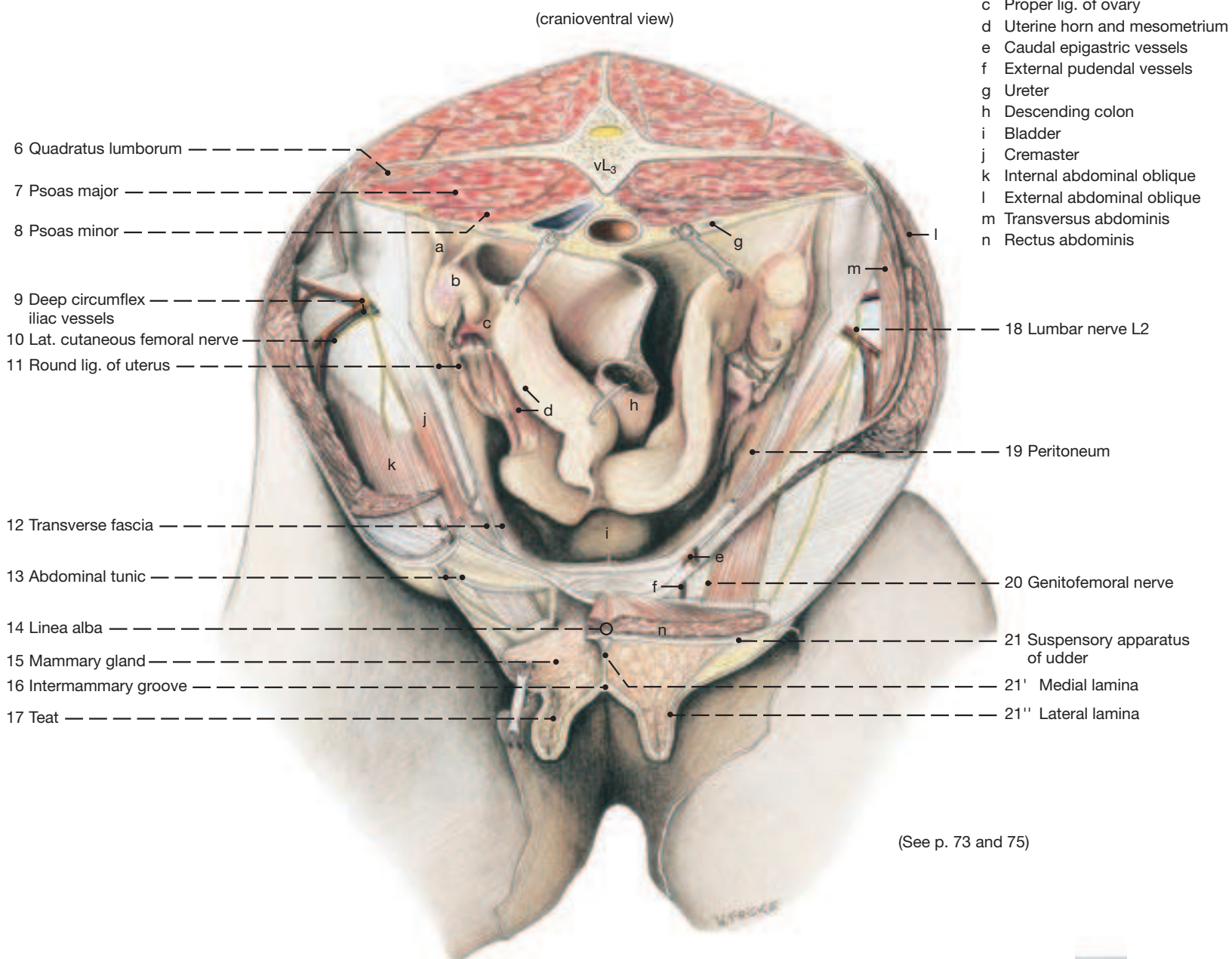
Udder, sagittal section through a teat



Prepubic Tendon, Inguinal Ligament, and Accessory Ligament



Inguinal Rings and Vicinity of the Mare (♀)



(See p. 73 and 75)

a) THE LYMPHATICS OF THE PELVIC AND LUMBAR AREAS

I. Lymph nodes outside the abdominal and pelvic cavities.

The **supf. inguinal lymph nodes** (see p. 85.s) in the male lie on each side of the penis and extend to the scrotum (scrotal lymph nodes); in the female they extend to the base of the udder (mammary lymph nodes).

The **subiliac lymph nodes**, which lie in the flank fold halfway between the coxal tuber and the patella, were described with the hindlimb (see p. 19.D) and with the abdominal wall (see p. 65.10).

The **deep inguinal lymph nodes** were mentioned in connection with the femoral triangle (see p. 19.B).

II. The retroperitoneal lymph nodes at the junction of abdomen and pelvis.

The **sacral lymph nodes** (6) lie caudal to the aortic bifurcation between the origins of right and left internal iliac arteries.

The **medial iliac lymph nodes** (4) surround the break-up of the abdominal aorta a little more cranial than the preceding nodes; some lie at the origin of the **deep circumflex iliac vessels** (10).

The **lateral iliac lymph nodes** (5) are located at the break-up of the **deep circumflex iliac vessels** into **cranial** (10') and **caudal** (10'') branches.

The **lumbar aortic lymph nodes** (3) continue the medial iliac nodes cranially along the abdominal aorta.

The **renal lymph nodes** (2) lie near the renal hilus between the branches of the renal vessels; they are not easily distinguished from neighboring lumbar aortic nodes.

Lymph passing through the afore-mentioned nodes enters the cisterna chyli which at the level of the kidneys accompanies the aorta on its right dorsal aspect. The cisterna is continued cranially by the thoracic duct which conveys the lymph to one of the veins at the thoracic inlet.

b) The paired **ADRENAL GLANDS** (7) are about 8 cm long, have an irregular surface, and are bilaterally compressed. Their yellowish-brown color distinguishes them from the more grayish-brown lymph nodes. The left gland lies against the left kidney cranial to its hilus. The right one lies between the hilus of the right kidney and the caudal vena cava.

c) THE URINARY ORGANS

The **right kidney** (1), shaped like the heart on a playing card, lies with its cranial pole in the renal impression of the liver, and makes contact dorsally the diaphragm. The base of the cecum is attached to its ventral surface. The bean-shaped **left kidney** (8) lies medial to the spleen to which it is bound by the renosplenic ligament (see p. 69.12). It is ventral to the last rib and the first two lumbar transverse processes and thus half a kidney's length caudal to the right kidney which lies ventral to the last two ribs and the first lumbar transverse process.

1 The kidneys are smooth on the surface. The **renal lobes** (15) have completely fused so that their original limits are revealed only by the course of the **interlobar arteries and veins** (19). When sectioned, the kidney discloses a granular reddish-brown **cortex** (16) which is easily distinguished from the dark-red **external** (20') and the paler **internal** (20'') part of the smooth **medulla** (20). The papillary ducts of the central parenchyma open on the small **renal crest** (20''') which juts into the equally small **renal pelvis** (13) located in the center of the organ. The papillary ducts near the poles of the kidney open into the two so-called **terminal recesses** (14). These are about 10 cm long, have a diameter of about 0.5 cm, and are cranial and caudal extensions of the renal pelvis, though they can also be regarded as overgrown collecting ducts without walls.

2 The **renal sinus** (18), the indentation on the medial border of the organ that gives passage to the ureter and the lymph- and blood vessels, contains the renal pelvis at its depth and forms the **hilus** (17) where ureter and blood vessels emerge. Some branches of the renal arteries do not utilize the hilus but penetrate the renal parenchyma from the ventral surface.

I. The wall of the **renal pelvis**—and that of the initial segment of the ureter—contain mucous glands that can be detected with the naked eye; they give the horse's urine its cloudy and slimy quality.

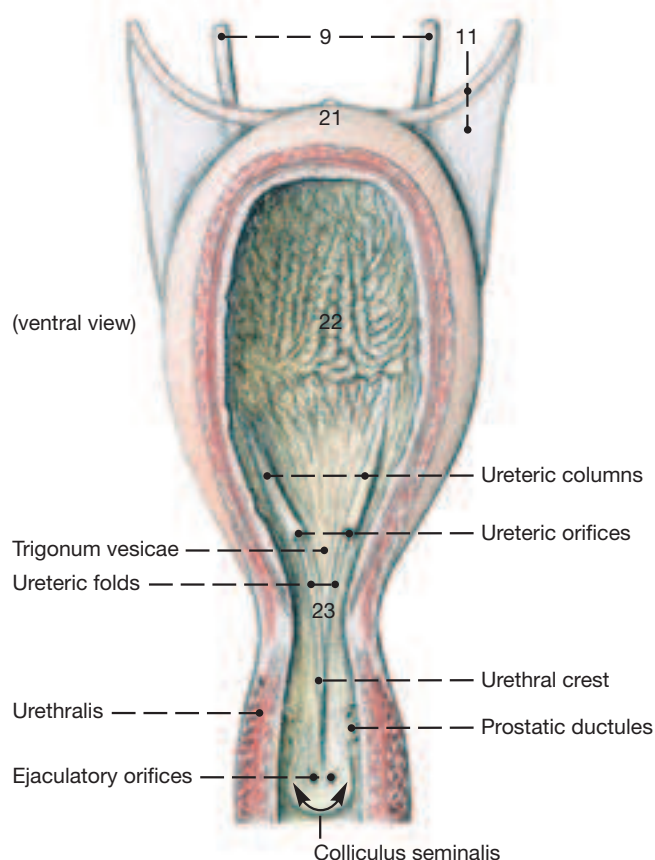
II. The **ureters** (9), after emerging from the hilus, lie retroperitoneally on each side of the two great abdominal blood vessels (aorta and caudal vena cava). Their pelvic part descends towards the dorsal surface of the bladder whose wall it penetrates obliquely; the pelvic part in the male briefly lies in the mesoductus deferens and crosses the dorsal surface of the deferent duct.

III. The **bladder** (see text Fig. below), when empty, has the size of a small fist and resides entirely within the pelvic cavity in a largely retroperitoneal position. When moderately filled, its **apex** (21) and **body** (22) hardly protrude into the abdominal cavity; but when filled to capacity, the apex may advance to the level of the umbilicus. The **neck of the bladder** (23), however, always remains within the pelvic cavity. The **lateral ligaments of the bladder** (11) carry the nearly obliterated umbilical artery (round ligament) in their free border (the artery arises from the cranial or caudal gluteal arteries). The **median ligament of the bladder** (12) connects the bladder to the pelvic floor and to the linea alba, and contains smooth muscle tissue.

IV. The **male urethra** (see p. 85.p) within the pelvic cavity (pelvic part) is 12 cm long; its lumen is narrow at the level of the prostate and at the ischial arch where it is continuous with the spongy penile part.

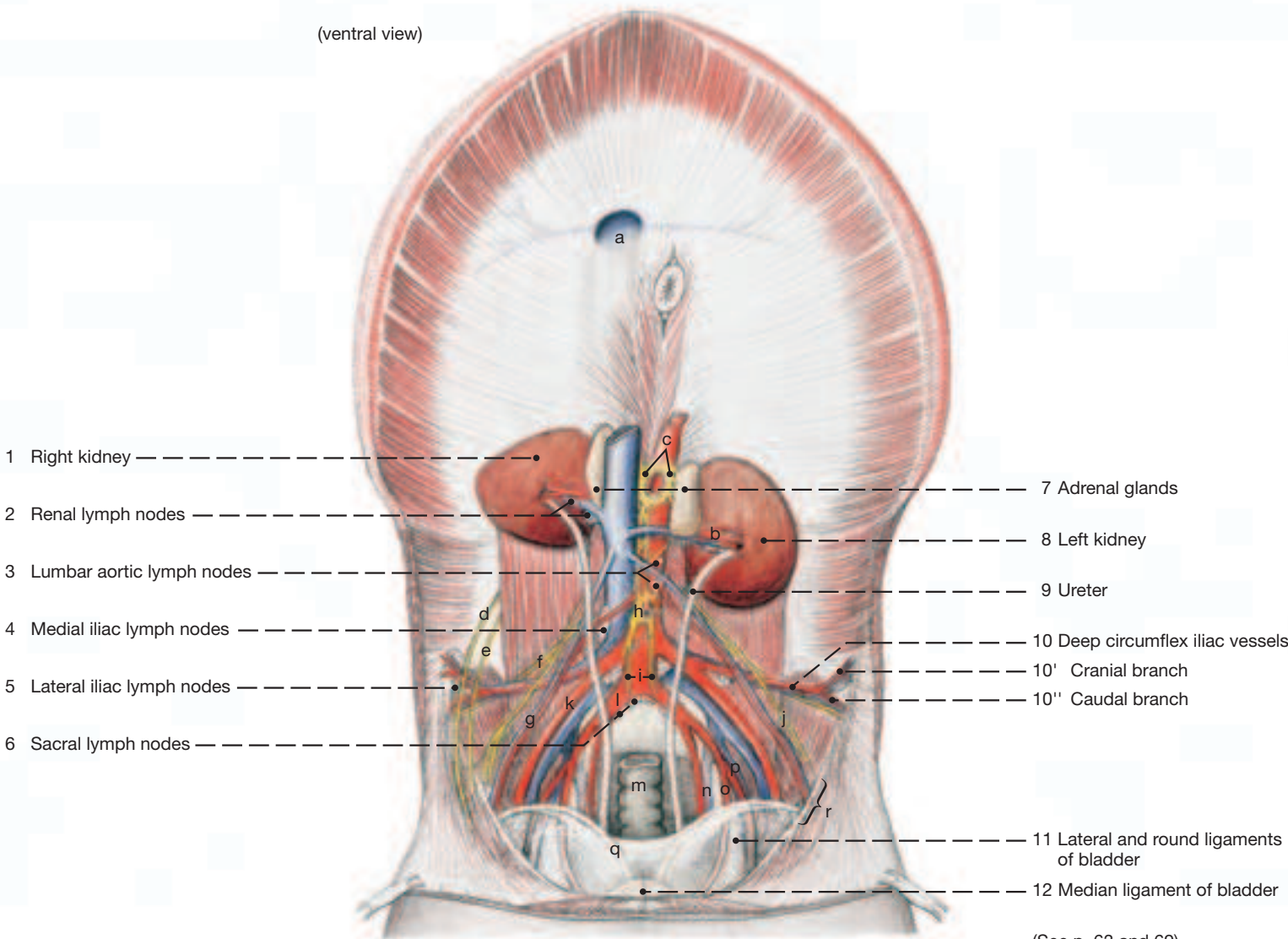
V. The **female urethra** (see p. 83), only 6 cm long, is short but compensates with a wide lumen throughout. This, plus its ability to dilate, occasionally permits a prolapse of the bladder through the urethra when bladder mucosa becomes visible in the vestibule of the vagina.

Urinary Bladder, with Pelvic Part of Male Urethra



Abdominal Cavity and Urinary Organs

(ventral view)

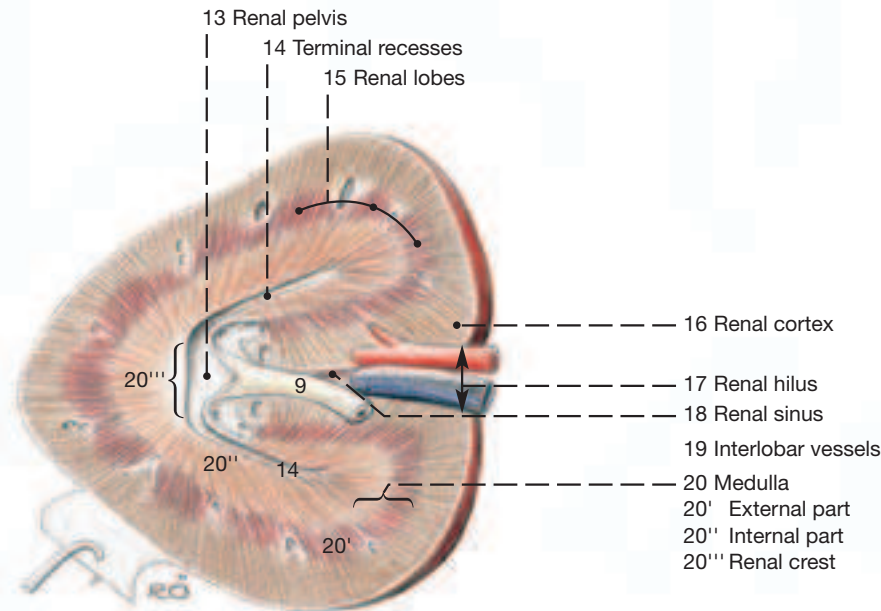


(See p. 63 and 69)

- | | | | |
|---------------------------------------|--|---------------------|-------------------------|
| a Caval foramen | f Lat. cutaneous femoral nerve | k Ext. iliac artery | p Int. pudendal vessels |
| b Renal vessels | g Testicular vessels | l Int. iliac artery | q Deferent duct |
| c Celiac and cran. mesenteric ganglia | h Caud. mesenteric artery and ganglion | m Rectum | r Deep inguinal ring |
| d Iliohypogastric nerve (L1) | i Hypogastric nerves | n Obturator vessels | s Interlobular vessels |
| e Ilioinguinal nerve (L2) | j Genitofemoral nerve | o Umbilical artery | |

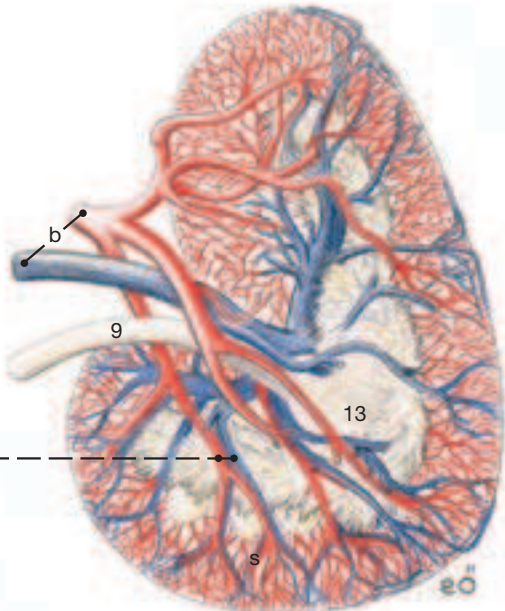
Right Kidney

sectioned through hilus and poles



Left Kidney

cast of renal vessels and renal pelvis



- 1 a) The **ABDOMINAL AORTA** (2) begins its break-up already at the level of the 5th lumbar vertebra. It gives rise to the paired external and internal iliac arteries, and to the unpaired **median sacral artery** which is occasionally absent.

The **external iliac artery** (10), seldom the internal iliac, in the mare releases the **uterine artery** (11), the principal artery of the uterus, and in the stallion it releases the **cremasteric artery** (11) which accompanies the testicular artery (from the aorta) through the vaginal ring. Before entering the vascular lacuna to gain the thigh, the external iliac gives rise to the **deep femoral artery** (12) which in turn gives off the **pudendoepigastric trunk** (13). This immediately gives off the **external pudendal artery** (15) which passes through the inguinal canal. The external pudendal, among other branches, supplies vessels for the udder and the **cranial artery of the penis** (19) which anastomoses on the dorsal surface of the penis with the **middle artery of the penis** (46; from the obturator) and the **dorsal artery of the penis** (38; from the internal pudendal).

The **internal iliac artery** (22), as does the abdominal aorta and sometimes also the caudal gluteal, sends **lumbar arteries** (3) to the vertebral column and associated structures, and immediately (opposite the 6th lumbar vertebra) divides into the **caudal gluteal** (47) and **internal pudendal arteries** (23). Of these the former is destined predominantly for the pelvic wall, while the latter goes to the pelvic viscera.

The **internal pudendal artery** (23), close to its origin, gives off the **umbilical artery** (24) which, in the stallion, releases the small **artery of the deferent duct** (25), and in both sexes the **cranial vesical artery** (26) and ends as the **round ligament of the bladder** (27) in the free border of the lateral ligament of the bladder. The internal pudendal then courses along the medial surface of the sacrosclatic ligament in the vicinity of the pudendal nerve and with its next branch, the **vaginal artery** (prostatic in the male) (28), supplies most of the pelvic viscera: **branch to deferent duct or uterine branch** (29), **caudal vesical artery** (30), **urethral branch** (31), **urethral branch** (32), **middle rectal artery** (33), **ventral perineal artery** (40), and the **caudal rectal artery** (41). The internal pudendal itself is continued by the **artery of the penis** (36); the clitoris receives its supply from the middle clitoral artery, a branch of the obturator artery.

The **caudal gluteal artery** (47) and its branches, especially the **cranial gluteal artery** (49) that exits by the greater sciatic foramen, supply the dorsolateral wall of the pelvis and the croup. The **obturator artery** (44), arising either from the caudal or cranial gluteal, is the exception: it passes caudoventrally on the medial aspect of the shaft of the ilium and leaves the pelvic cavity together with its satellite vein and nerve by the obturator foramen. Below the floor of the pelvis it detaches the **middle artery of the penis** (clitoris) (46).

- b) The **VEINS** of the pelvic cavity by and large are satellite to the arteries; deviations are shown in the Figures on the opposite page.

The **external pudendal vein** (15) that accompanies its satellite artery through the inguinal canal is very thin. Its blood-return function is assumed by the **accessory external pudendal vein** (16) which collects most of the veins from penis or udder and delivers the blood to the ipsilateral deep femoral vein (branch of external iliac) at the cranial end of the pelvic symphysis. Right and left accessory external pudendal veins anastomose here (in the symphyseal fossa; see p. 73.3) across the median plane; it is the transected anastomosis that attracts attention after the hind quarters of the cadaver are split (see p. 83). The large **obturator vein** (44) assists the accessory external pudendal vein in draining penis and udder.

The blood supply of penis and udder follows in greater detail.

- c) The **BLOOD SUPPLY OF THE PENIS** derives from three sets of vessels: internal pudendal artery and vein, obturator artery and vein, and external pudendal artery and the accessory external pudendal vein. The **internal pudendal artery** (23) becomes the **artery of the**

penis (36) which gives rise to the **artery of the bulb** (37) for the bulb and corpus spongiosum, and to the **dorsal artery of the penis** (38) which anastomoses with the **middle** (46) and **cranial** (19) **arteries of the penis** on the dorsal surface of the organ. The **deep artery of the penis** (39) for the corpus cavernosum carries blood from the obturator artery. The **veins** form an extensive plexus dorsal and lateral to the penis whose blood enters the **accessory external pudendal vein** (16) but also the **obturator** (44) and **internal** (23) **pudendal veins**.

- d) The **BLOOD SUPPLY OF THE UDDER** comes from the external pudendal artery via the caudal supf. epigastric (**cranial mammary artery**; 20) and from the internal pudendal artery via the dorsal labial branch that anastomoses with the ventral labial branch (**caudal mammary artery**; 18) of the external pudendal.

The **venous drainage** is mainly by the accessory external pudendal vein (**middle mammary vein**; 16) into the deep femoral, but also by the caudal supf. epigastric vein (**cranial mammary vein**; 20) and by the ventral labial vein of the external pudendal (**caudal mammary vein**; 18) which anastomoses with the dorsal labial vein of the internal pudendal.

- e) The **BLOOD SUPPLY OF THE UTERUS** comes principally from the **uterine artery** (11), a branch of the external (rarely internal) iliac. The uterine artery anastomoses cranially with the **uterine branch of the ovarian artery** (5) and caudally with the **uterine branch of the vaginal artery** (29).

- f) The **SACRAL PLEXUS OF NERVES** is the continuation of the lumbar plexus; together they form the lumbosacral plexus (see p. 76).

The **cranial gluteal nerve** (L6–S2; f) accompanies the like-named artery through the greater sciatic foramen to supply the gluteus medius, accessorius, and profundus, and also the tensor fasciae latae (see p. 19.8).

The **sciatic nerve** (L5–S2; g) also emerges from the greater sciatic foramen. Lying on the sacrosclatic ligament, it passes the hip joint dorsally and caudally, and as the largest nerve of the plexus enters the pelvic limb.

The **caudal gluteal nerve** (L6–S2; h) passes also through the greater sciatic foramen and accompanies like-named blood vessels into the gluteus supf. and into the vertebral heads of biceps and semitendinosus.

The **caudal cutaneous femoral nerve** (S1–S2; i) at first follows the dorsal border of the sciatic nerve but as the latter turns ventrally into the limb, it passes over the ischial tuber to end subcutaneously on the caudal surface of the thigh.

The **pudendal nerve** (S2–S4; j) at first lies on the medial surface of the sacrosclatic ligament, and then within the ligament, in which position it reaches the lesser sciatic foramen. Here it communicates with the caudal cutaneous femoral nerve. Before accompanying the internal pudendal vessels to the penis (clitoris), it gives rise to the **deep perineal nerve** (l) for the striated muscles of the perineum and the **supf. perineal nerve** (m) which is sensory to the vulva and perineal body.

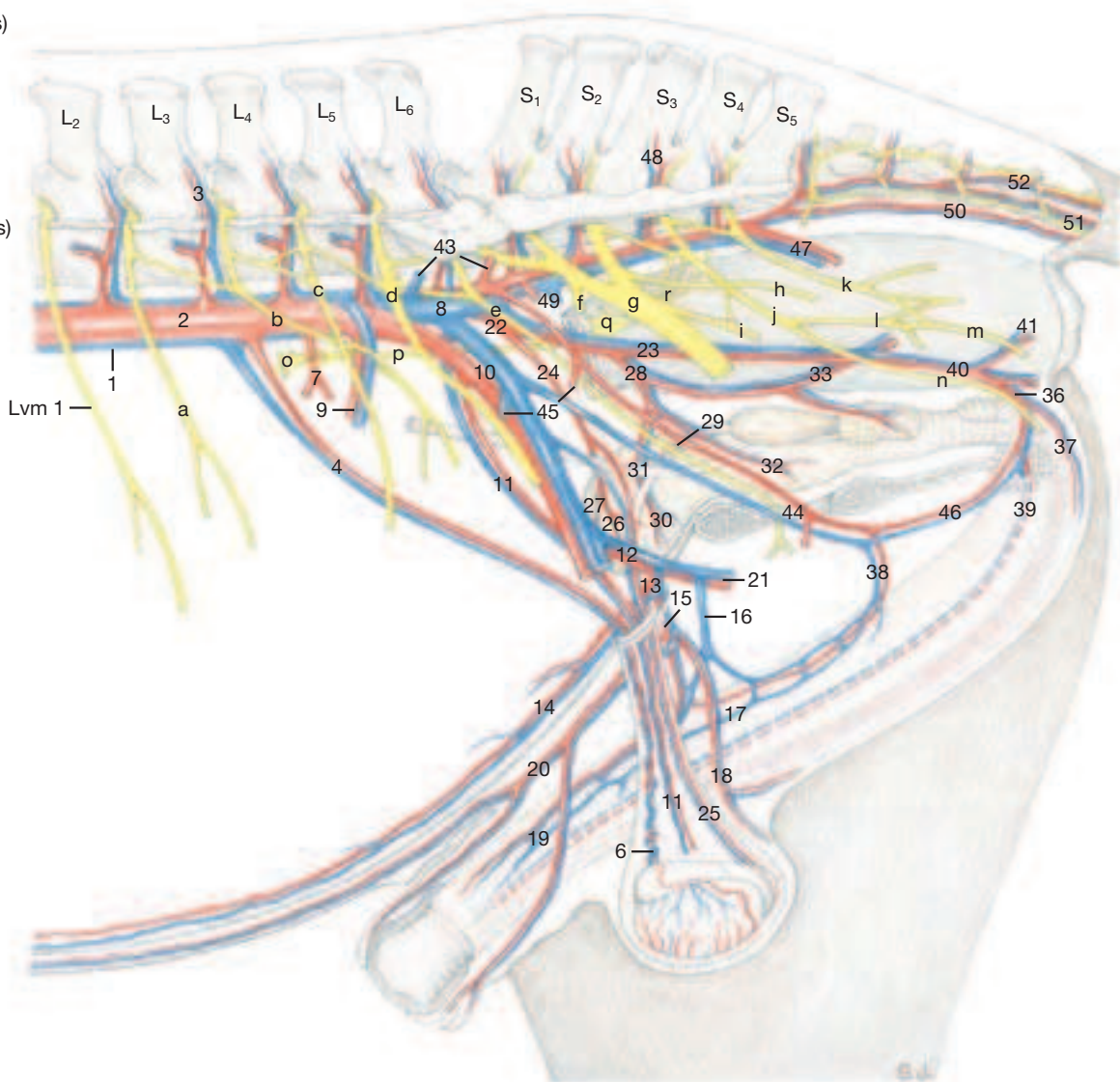
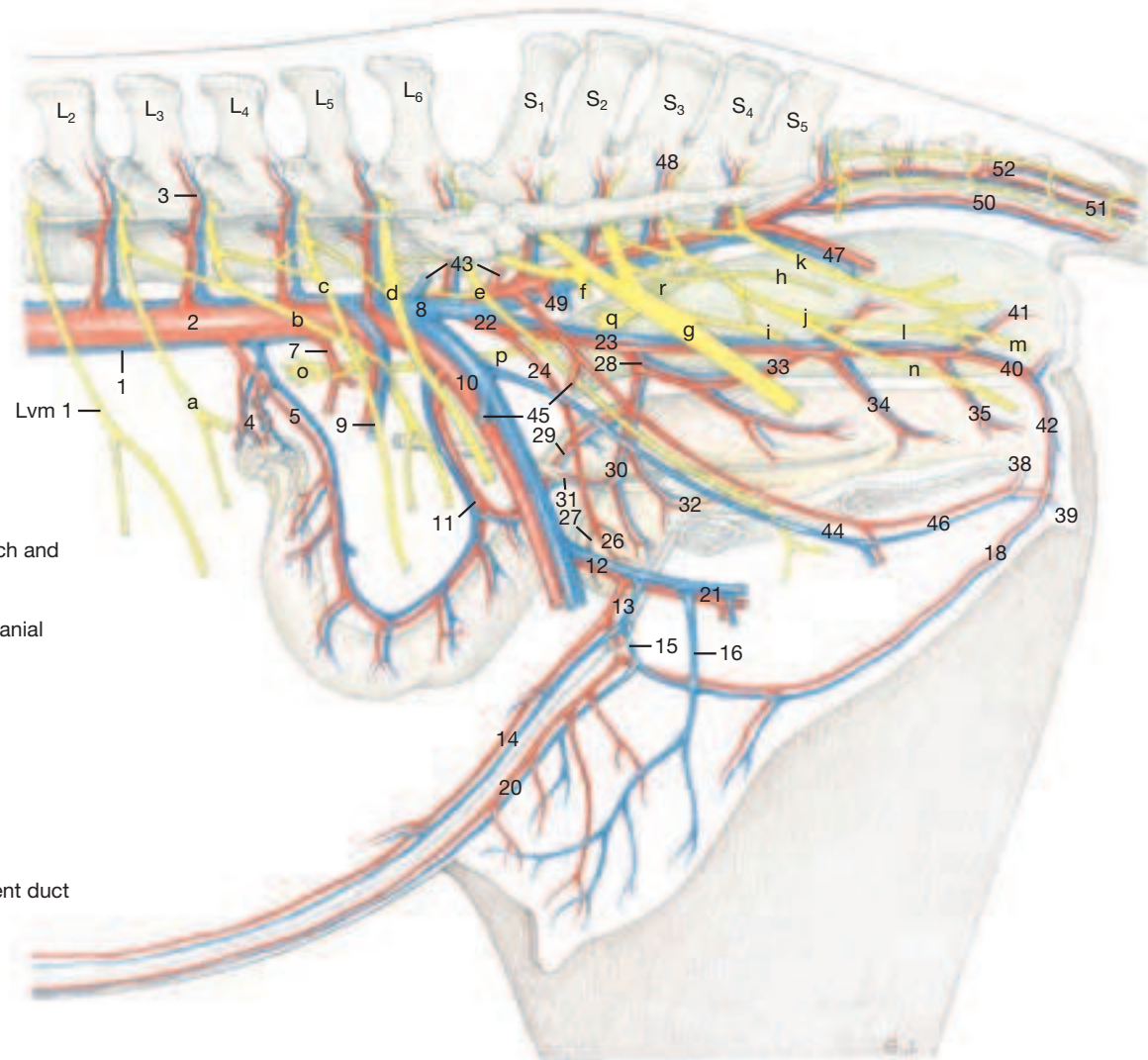
The **caudal rectal nerve** (S4, S5; k) passes caudoventrally and supplies sensation to rectum, anal canal, and perineum; it also contributes to the motor innervation of the perineal musculature.

- g) For the **AUTONOMIC NERVOUS SYSTEM** at the entrance to the pelvic cavity we need merely mention that the **caudal mesenteric ganglion** (o) lies cranioproximal to the origin of the **caudal mesenteric artery** (7), and that the **hypogastric nerve** (p), which begins here, at first follows the roof of the cavity and then descends to the **pelvic plexus** (q) on the viscera. The parasympathetic **pelvic nerves** (r) arise from the roots of the pudendal and caudal rectal nerves, pass ventrally, and join the pelvic plexus.

Arteries, Veins, and Nerves of the Pelvic Cavity

- 1 Caudal vena cava
- 2 Abdominal aorta
- 3 Lumbar vessels
- 4 Ovarian or testicular vessels
- 5 Uterine branch
- 6 Pampiniform plexus
- 7 Caudal mesenteric artery
- 8 Common iliac vein
- 9 Deep circumflex iliac vessels
- 10 External iliac vessels
- 11 Uterine or cremasteric vessels
- 12 Deep femoral vessels
- 13 Pudendoepigastric arterial trunk and pudendoepigastric vein
- 14 Caudal epigastric vessels
- 15 External pudendal vessels
- 16 Accessory ext. pudendal vein [middle mammary vein]
- 17 Venous plexus of penis
- 18 Ventral labial (scrotal) arterial branch and v. [caudal mammary vessels]
- 19 Cranial vessels of penis
- 20 Caudal supf. epigastric vessels [cranial mammary vessels]
- 21 Medial circumflex femoral vessels
- 22 Internal iliac vessels
- 23 Internal pudendal vessels
- 24 Umbilical artery
- 25 Vessels of deferent duct
- 26 Cranial vesical artery
- 27 Round ligament of bladder
- 28 Vaginal or prostatic artery
- 29 Uterine branch or branch to deferent duct
- 30 Caudal vesical vessels
- 31 Ureteric branches
- 32 Urethral branches
- 33 Middle rectal vessels
- 34 Vestibular branch
- 35 Vessels of the vestibular bulb
- 36 Vessels of the penis
- 37 Vessels of the bulb of the penis
- 38 Dorsal vessels of the penis (clitoris)
- 39 Deep vessels of the penis (clitoris)
- 40 Ventral perineal vessels
- 41 Caudal rectal vessels
- 42 Dorsal labial branches
- 43 Iliolumbar vessels
- 44 Obturator vessels
- 45 Iliacofemoral vessels
- 46 Middle vessels of the penis (clitoris)
- 47 Caudal gluteal vessels
- 48 Sacral branches
- 49 Cranial gluteal vessels
- 50 Median caudal vessels
- 51 Ventrolateral caudal vessels
- 52 Dorsolateral caudal vessels

- a Ilioinguinal nerve (L2)
- b Genitofemoral nerve
- c Lateral cutaneous femoral nerve
- d Femoral nerve
- e Obturator nerve
- f Cranial gluteal nerve
- g Sciatic nerve
- h Caudal gluteal nerve
- i Caudal cutaneous femoral nerve
- j Pudendal nerve
- k Caudal rectal nerves
- l Deep perineal nerve
- m Supf. perineal nerve
- n Dorsal nerve of penis (clitoris)
- o Caudal mesenteric ganglion
- p Hypogastric nerve
- q Pelvic plexus
- r Pelvic nerves



6. Female Reproductive Organs

Clinical and Functional Anatomy p. 174–176; 180–183

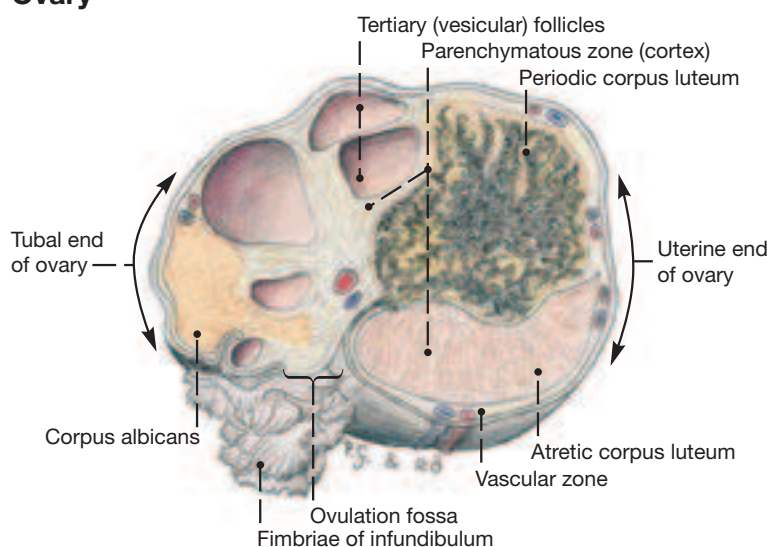
1 a) The **OVARY** (10) is relatively very large (about 8 by 5 cm) lies about 10 cm caudal to the kidneys and, when projected onto the skin, the same distance cranioventral to the coxal tuber, i.e., at the level of the 5th lumbar vertebra. The ovary is suspended by the 15 cm long **mesovarium** (2) whose cranial border (**suspensory ligament of the ovary**; 1) extends on the sublumbar area towards the diaphragm. The mesovarium splits off the **mesosalpinx** (3) from its lateral surface and is continued caudally by the **mesometrium** (4). The three sheets taken together constitute the **broad ligament**.

The oval ovary of the filly gradually takes on the shape of a bean. This is brought about by regression of the cell masses in the stroma (cessation of the hormonal influence), more rapid growth at the poles, and progressive indentation at the free border to form the **ovulation fossa**. The germinal epithelium is concentrated in the area of the fossa which thus is the only region on the surface of the organ where ovulation can occur. The remainder of the ovary is covered by peritoneum (flat mesothelial cells) which has a slightly different color than the germinal epithelium. The **parenchymatous zone** containing the follicles lies deep to the germinal epithelium and thus surrounds the depth of the ovulation fossa. (In the filly, before the fossa developed, the parenchymatous zone covered (cap-like) the free border of the ovary.) The **vascular zone** of the adult ovary is relegated to the poles and attached border. The concept of the parenchymatous zone forming a cortex and the vascular zone forming a medulla, as is the case in other domestic mammals, does not apply in the mare.

The surface of the ovary is relatively flat, and corpora lutea, even at their largest, do not become conspicuous. Likewise, mature follicles, which can attain a diameter of 6 cm, bulge only slightly from the surface; they are not as easily recognized on rectal exploration as in the cow where the ovaries are considerably smaller.

b) The **UTERINE TUBE** (14) meanders—parallel to the body axis—from the ovulation fossa to the horn of the uterus. It is suspended in the **mesosalpinx** (3) that arises from the lateral surface of the mesovarium and ends with a free border a few mm ventral to the uterine tube. The mesosalpinx forms the lateral, and the **proper ligament of the ovary** (6) the medial wall of the shallow **ovarian bursa** (5) which has a wide entrance, open ventrally, for easy access to the ovary.

Ovary



2 The **infundibulum** (16), the funnel shaped ovarian end of the uterine tube, partly covers the ovary with its **fimbriae** (16) and is firmly attached to it in the vicinity of the ovulation fossa. The abdominal orifice of the tube, situated in the center of the infundibulum, faces the ovary and leads into the shorter wide part (**ampulla**) of the tube. Depending on the phase of the cycle, the ampulla may attain a diameter of 6 mm. The longer remainder (**isthmus**) of the tube is only half as wide and ends with its **uterine orifice** (15) on the tip of the uterine horn where it raises a small **papilla** that contains a sphincter.

3 c) **UTERUS. Horns** (11) and **body** (12) are of about equal length (25 cm each). Both are in the abdominal cavity; only the **cervix**, which is about 6 cm long, lies in the pelvic cavity where it rests on bladder

and urethra. The mesometrium that suspends these parts extends from the tip of the uterine horn to the cervix and attaches to the mesometrial border where its two lamellae enclose the triangular (in transverse section) **parametrium** consisting of many blood vessels embedded in connective tissue. The lateral surface of the mesometrium splits off the **round ligament of the uterus** (7) that can be traced from the tip of the uterine horn to the vicinity of the inguinal canal.

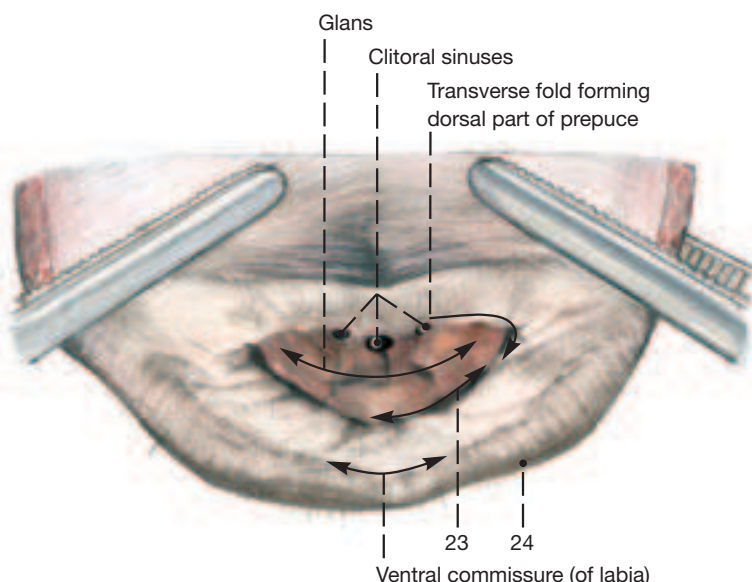
The **cervix** (27) intervenes without external landmarks between the body of the uterus and the vagina. It is possible, however, on rectal palpation to determine its extent by its firm consistency. Radially arranged longitudinal folds close the **cervical canal** (27) except during estrus. The lumen of the uterus gradually narrows to the diameter of the cervical canal where the **internal uterine ostium** (13) is located. The **external uterine ostium** (26) lies in the center of the intravaginal part (portio vaginalis) of the cervix that occupies the cranial end of the vagina. The longitudinal folds of the cervical canal extend through the external uterine ostium and give the portio vaginalis its lobed appearance.

5 d) The **VAGINA** (19) is as long as the uterine body (about 25 cm). It lies in the center of the pelvic cavity ventral to the rectum and dorsal to bladder and urethra. Only its cranial portion is covered by peritoneum which dorsally forms the floor of the deep **rectogenital pouch** (8) and ventrally the roof of the less extensive **vesicogenital pouch** (9). The vaginal lumen is dorsoventrally compressed. Longitudinal folds are present and provide a reserve for dilation. The lumen surrounds the intravaginal part of the cervix, forming a complete ring-like space known as **vaginal fornix** (18). Caudally, the vagina is continued by the **vestibule** (22) at a relatively distinct transverse fold (**hymen**; 20) on the floor and sides of the junction that is located immediately cranial to the **external urethral orifice** (21) and is supported ventrally by the constrictor vestibuli.

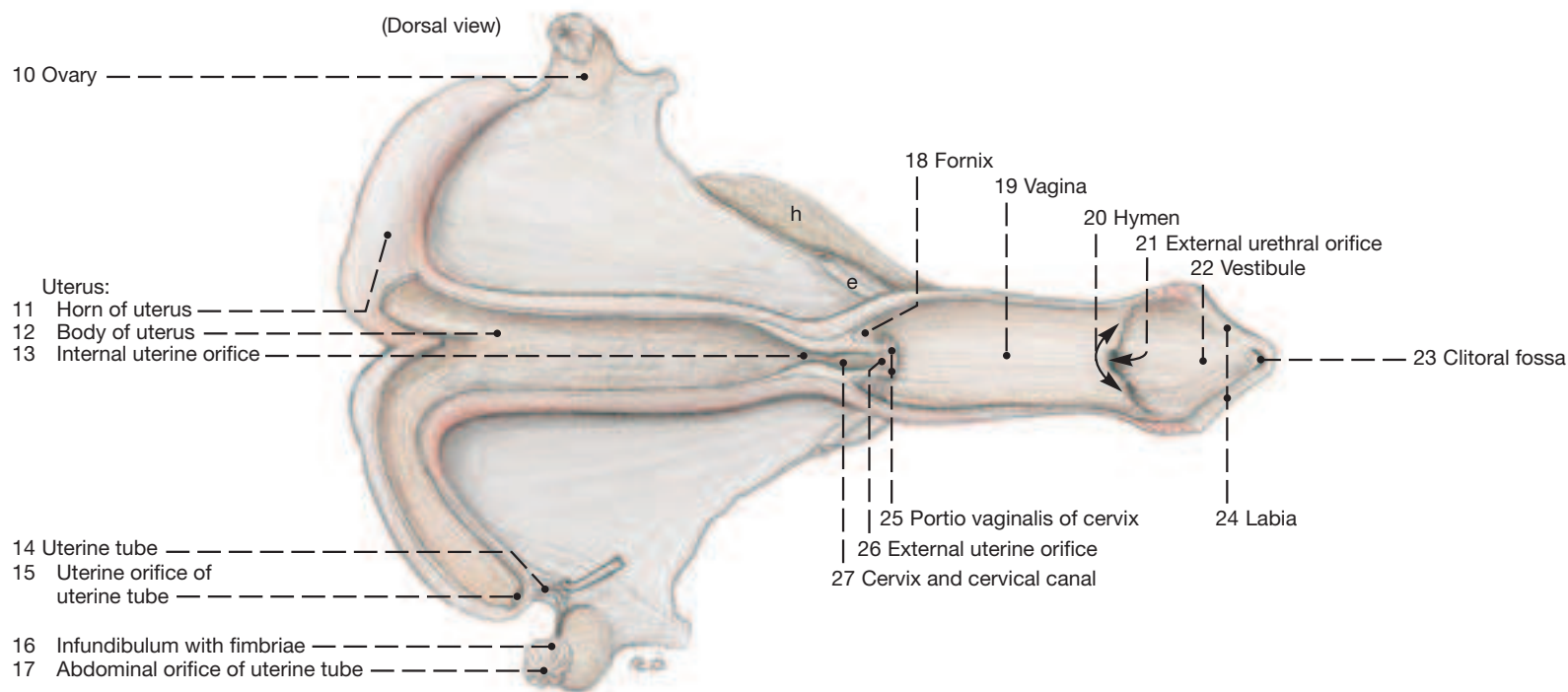
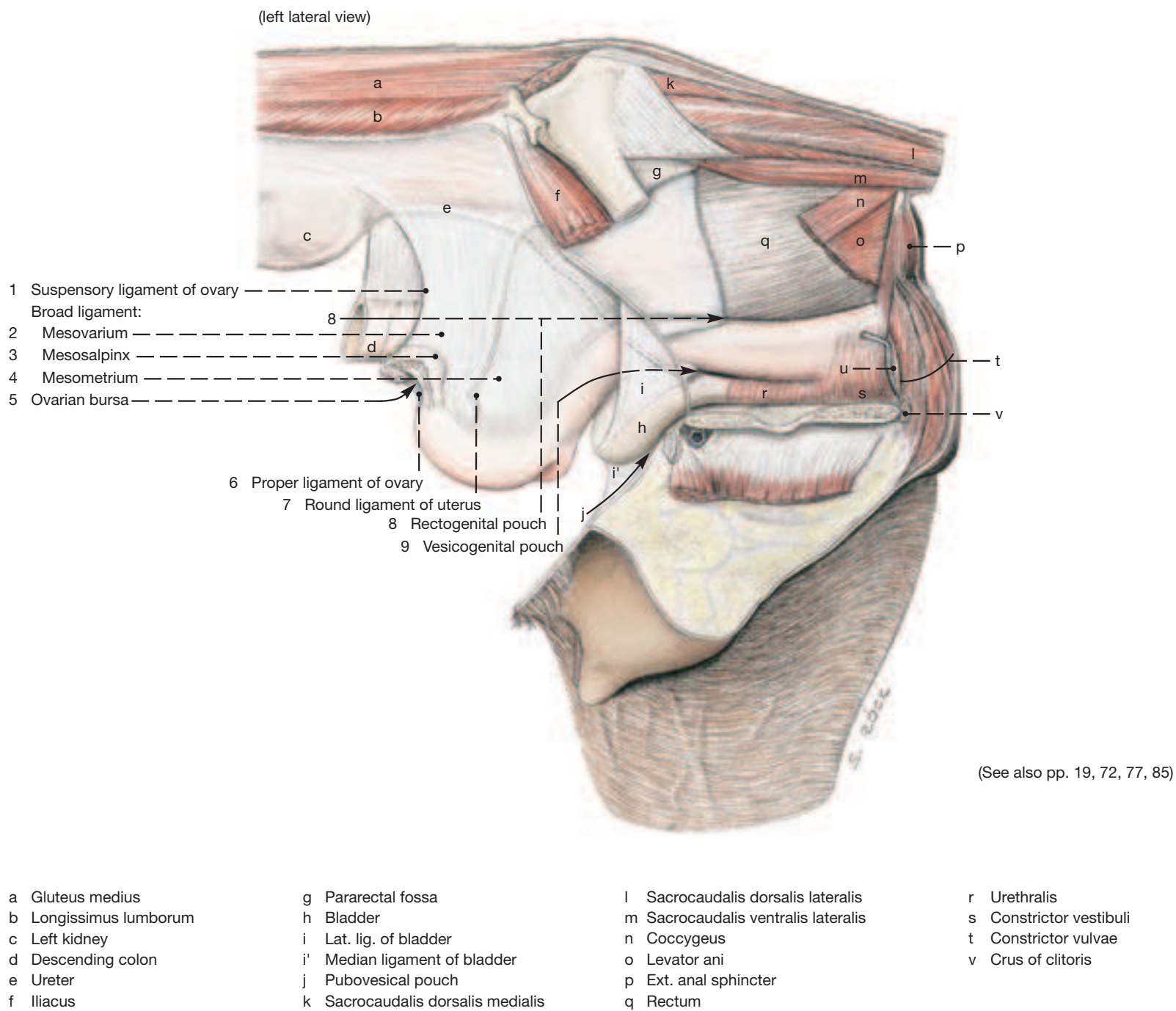
7 e) The **VULVA** comprises the two **labia** (24) which surround the vulvar cleft forming a pointed **dorsal commissure** and a rounded **ventral commissure** which encloses and hides the large glands of the clitoris.

8 The mare's **clitoris** (see Fig. in this column) is well developed. It consists of crura, body, and glans of which the last named lies in the **clitoral fossa** (23) in the ventral end of the vulva. The **prepuce of the clitoral glans** is formed by a transverse fold of vestibular mucosa and the ventral ends of the labia. **Sinuses** in the periphery of the glans can harbor infectious agents such as the organism responsible for contagious equine metritis (CEM). The deeper ones on the dorsal aspect are often removed (sinusectomy) to eliminate carriers of the disease in mares imported into the U.S.A. The others are shallow and can be cleansed by washing.

Clitoris, caudal view of glans



Female Reproductive Organs



7. Male Reproductive Organs

Clinical and Functional Anatomy p. 176–177

1 a) The **TESTES** (19; t) lie in the pubic region between the cranial parts of the thighs. Their long axes almost match that of the trunk, but change to a nearly dorsoventral direction when the testes are drawn up by the cremaster muscles. The testes are anchored to the parietal layer of the vaginal process by the **mesorchium** (v') and by the **ligament of the tail of the epididymis** (w). The latter forms the caudal end of the mesorchium and is attached to the dartos that lines the scrotum by a condensation of connective tissue forming the scrotal ligament. The **proper ligament of the testis** (x) connects the caudal pole of the testis to the tail of the epididymis.

2 The testis has the shape of a bilaterally compressed, shortened egg. The arterial pattern visible on the surface is characteristic for the species. A major branch of the **testicular artery** (20) appears close to the tail of the epididymis and meanders along the free border of the testis toward the cranial pole where it breaks up. Tortuous branches given off during its course supply both sides of the organ. The testicular parenchyma, on section, appears yellowish gray; the **mediastinum testis** and the rete testis it contains are indistinct and concentrated at the cranial pole close to the head of the epididymis.

3 **4** b) The **head** (14) of the **EPIDIDYMIS** does not extend beyond the cranial pole of the testis, but the **tail** (16) is larger and projects well beyond the caudal extremity of the testis so that it can be palpated without difficulty. Between the head and the tail is the **body of the epididymis** (15) which forms the **testicular bursa** (17) with the dorsal part of the lateral surface of the testis.

5 c) There is a full complement of **ACCESSORY REPRODUCTIVE GLANDS** consisting of **seminal vesicle**, **ampulla of the deferent duct**, **prostate**, and **bulbourethral gland**. These are fully developed in the stallion and retain their juvenile status following castration in the gelding. The **seminal vesicle** (11) and the **ampulla of the deferent duct** (10, whose wall is thickened by glands) lie on the dorsal surface of the bladder with the ureter between them. The seminal vesicle is homologous to the vesicular gland of ruminant and pig but because of its central collecting space carries a different name. Its duct joins the deferent duct forming a short ejaculatory duct that opens on the colliculus seminalis where it is flanked by several openings of the ducts of the prostate (see p. 78). The knobby **right** (12) and **left** (13) **lobes of the prostate** are connected by an isthmus dorsal to the urethra. There is no disseminate part. The paired **bulbourethral glands** (18) lie at the level of the pelvic outlet. Their medial surfaces especially are covered by the **bulboglandularis** (18, part of m. ischiourethralis). The ducts open in two rows on the dorsal surface of the urethra as the latter proceeds to pass ventrally around the ischial arch.

6 d) **PENIS** and **PREPUCE** (sheath) present several features characteristic of the horse (see also the Fig. on this page). The **prepuce proper**, comparable to that of the other domestic mammals, is a sleeve with internal and external surfaces (**laminae**; 5; 6) of which the latter is the skin. Where the two surfaces become confluent cranially, the

sleeve forms the **preputial orifice** (4). The internal lamina gives rise to an additional, circular **preputial fold** which is similarly constructed (1; 2) and which, with its cranial border, forms the **preputial ring** (3). The preputial fold disappears as it is applied to the erected penis; only the preputial ring remains identifiable by its smooth surface forming a ring-like elevation (3) that is a useful landmark for the surgeon.

The equine **penis** is of the musclocavernous type. When quiescent it is about 50 cm long and reaches only to the level of the umbilicus. During maximal erection it becomes three times as long. The corpus cavernosum is nearly uniform as a median septum penis is formed only caudally where the corpus cavernosum gives rise to the two crura by which the organ is attached to the ischial arch of the pelvis. The groove on the ventral surface contains urethra and surrounding corpus spongiosum held in place by the **bulbospongiosus** (7). The cranial end of the corpus cavernosum presents a prominent dorsal process and two lesser ventrolateral processes all of which are capped by the glans.

The **glans** (D) is formed by the corpus spongiosum. Its less robust tunica albuginea renders it softer in the erected state than the corpus cavernosum; this is thought to protect the female organs during coitus. The cranial surface of the glans is recessed ventrally to form the **fossa glandis** (E) from which the free end of the urethra (urethral process) with its external urethral orifice protrudes slightly. The greatest circumference of the glans is the **corona glandis** (F) which often carries short papillae. The abrupt narrowing of the glans proximal to the corona is known as the neck of the glans (collum glandis). Dorsally, the glans is continued proximally by a dorsal process, about 10 cm long, that lies on the corpus cavernosum without external demarkation and is visible only upon sectioning.


The muscles of the horse's penis are well developed. The **ischiocavernosus** (8) typically lies in a depression of the semimembranosus. It arises from the ischial arch close to the ischial tuber and caudal border of the sacrospinous ligament and surrounds the crus of the penis of the same side. During erection the ischiocavernosus contract rhythmically to pump arterial blood that has entered the corpus cavernosum forward, and at the end of sexual excitement allow the blood to leave the penis again. The **bulbospongiosus** (7) begins near the bulbourethral glands, covers the **bulb of the penis** (7) and reaches apically to the free part of the penis. Its transverse fibers connect the edges of the urethral groove to contain urethra and corpus spongiosum. The smooth **retractor penis** (9) takes origin from the caudal vertebrae and with right and left parts descends on each side of the rectum. The two parts unite and decussate below the rectum where two narrow bands of muscle arise to lie on the caudal, and later ventral, surface of the bulbospongiosus. As the two retractor bands approach the free part of the penis, they work their way through the transverse fibers of the bulbospongiosus so that the latter muscle then lies ventral to the retractor.

Penis

(Transverse section)

(Left lateral view*)

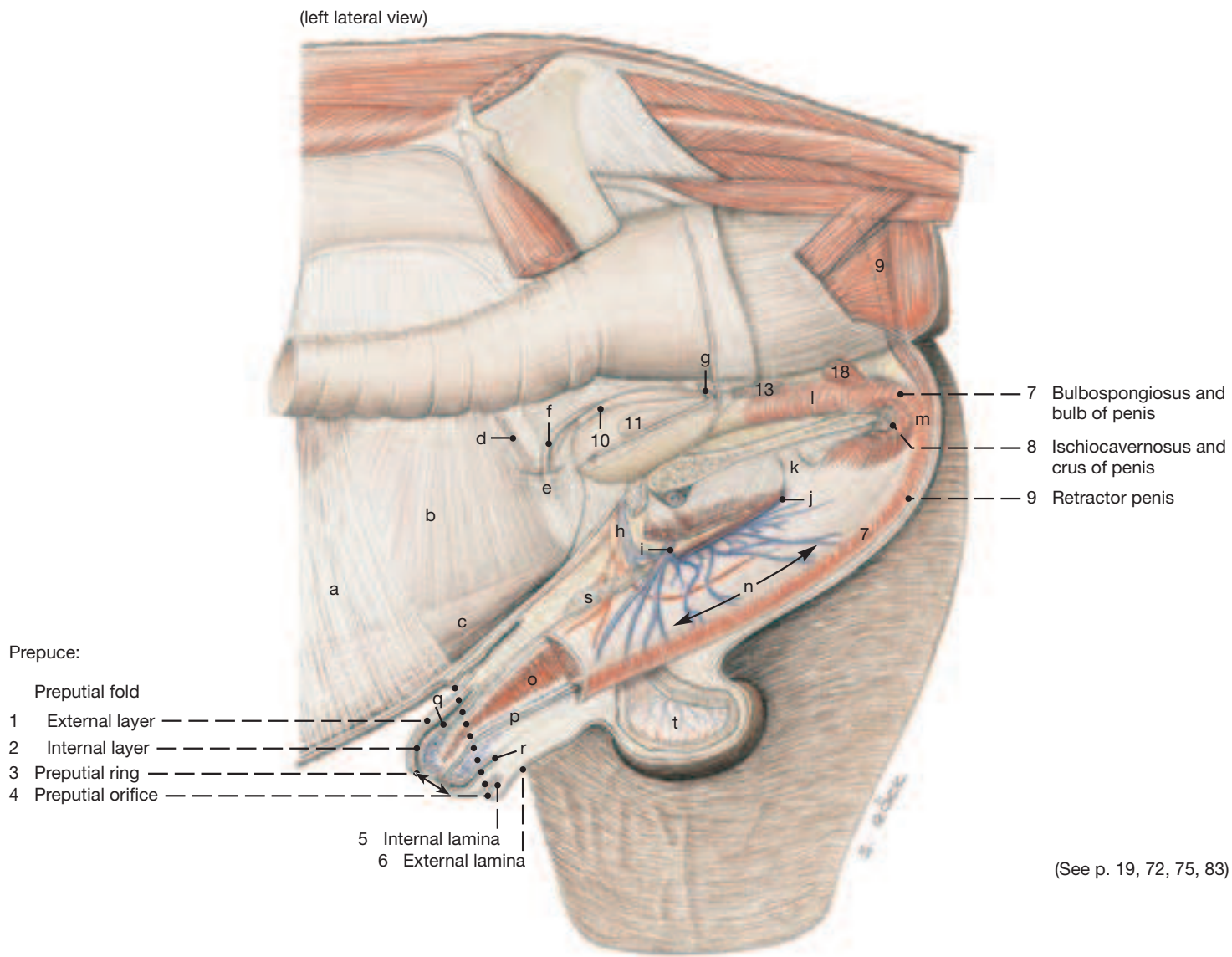
(Transverse section)



A Tunica albuginea
B Septum of penis
C Trabeculae
D Glans
E Fossa glandis
F Corona glandis
G Collum glandis
H Urethral process and external urethral orifice

Red line: Outline of corpus cavernosum penis
Blue line: Outline of corpus spongiosum glandis and dorsal process of glans

Male Reproductive Organs

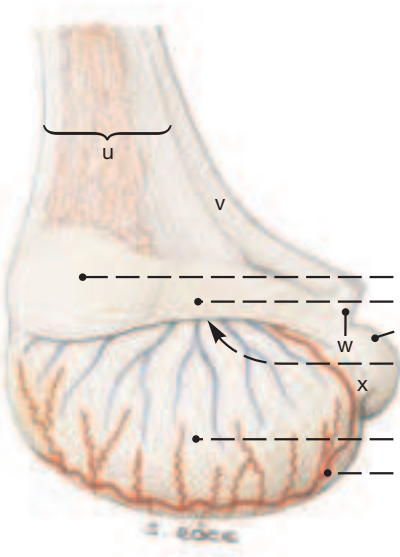


(See p. 19, 72, 75, 83)

- | | | | |
|---------------------------------------|-------------------------------|---------------------------------|-----------------------------------|
| a Right transversus abdominis | g Ureter | m Root of penis | s Supf. inguinal lymph nodes |
| b Right internal abd. oblique | h Ext. pudendal vessels | n Body of penis | t Medial surface of right testis |
| c Right rectus abdominis | i Accssory ext. pudendal vein | o Corpus cavernosum | u Spermatic cord (mesorchium) |
| d Proximal mesorchium (Vascular fold) | j Middle artery of penis | p Urethra and corpus spongiosum | v Mesofuniculus, mesorchium at v' |
| e Vaginal ring | k Suspensory lig. of penis | q Free part of penis | w Lig. of tail of epididymis |
| f Deferent duct | l Urethralis | r Depth of preputial cavity | x Proper lig. of testis |

Left Testis and Epididymis

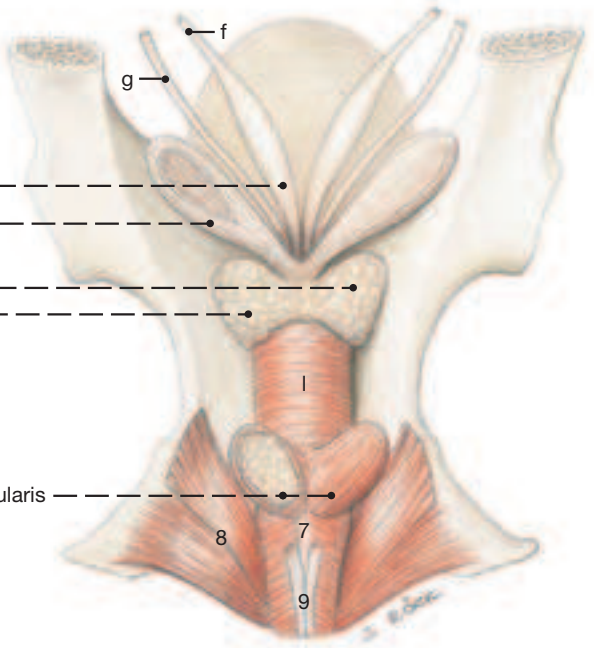
(lateral view)



- 10 Ampulla of deferent duct
11 Seminal vesicle
Prostate:
12 Right lobe
13 Left lobe
Epididymis:
14 Head
15 Body
16 Tail
17 Testicular bursa
18 Bulbourethral gland and bulboglandularis
19 Left testis
20 Testicular artery

Accessory Reproductive Glands

(dorsal view)



UQL|XbVxUmAVqC+HnIZ42uaraA==|1288009198

8. Perineum, Pelvic Diaphragm, and Tail

a) **PERINEUM** and **PERINEAL REGION** are terms that refer to the area surrounding anus and vulva in the female, and anus and the root of the penis in the male. Specifically, the perineal region is on the surface of the body, and therefore has no depth.

The **perineum** lies deep to the perineal region; it is the body wall that closes the pelvic cavity caudally. Since this particular part of the body wall by necessity includes the anal canal and urogenital tract, it is considerably more complicated than ordinary body wall, like that of the flank, for example. The boundaries of the perineum are the floor of the bony pelvis ventrally, the sacrosciatic ligaments laterally, and the sacrum and first few caudal vertebrae dorsally. In caudal view, therefore, the perineum is triangular.

The **perineal region** is only skin deep. It comprises the narrow median strip between the rounded semimembranosi, the anus and vulva, and extends from the root of the tail to the ventral commissure of the vulva, which in older mares falls below the level of the pelvic floor. (The region may be divided into anal and urogenital parts by a line connecting the ischial tubers which can only be discerned by deep palpation.) In the male the perineal region extends to the base of the scrotum. The prominence of the two semimembranosi and their proximity to the midline precludes formation of an ischioanal fossa. For the same reason the caudal border of the sacrosciatic ligament cannot be palpated as is the case in dog and cattle.

b) The **PELVIC DIAPHRAGM** is the muscular basis of the perineum. It is formed by the **levator ani** and **coccygeus** (see pp. 19.i; e, and 83.o; n) of which the latter slightly overlaps the lateral surface of the former. The levator ani arises from the ischial spine and adjacent medial surface of the sacrosciatic ligament. Most of its fibers end on the anus where they mingle with those of the external anal sphincter. The coccygeus has a similar origin but passes more dorsally to insert on the first few caudal vertebrae. The two muscles are sandwiched between layers of fascia that are an integral part of the pelvic diaphragm. The space between the two coccygeus muscles dorsal to the anus is closed by the **external anal sphincter** (see p. 83.p) and the smooth **internal anal sphincter** and **rectococcygeus muscles**. The latter is a dorsal gathering of the outer longitudinal muscle layer of the rectum that passes caudally beyond the level of the anus to the undersurface of the tail vertebrae (see Fig. on this page).

The hiatus between the pelvic diaphragm and the caudal margin of the pelvic floor is closed by the **urogenital diaphragm** that is penetrated by the urogenital canal accompanied in the male by the **bulbospongiosus** (see p. 83.9) and in the mare by the corresponding **constrictor vestibuli** and **constrictor vulvae muscles** (see p. 83.s; t). Another muscle in the area is the paired **retractor penis (clitoridis)** (see p. 85.9) which arises from the second caudal vertebra and descends, deep to the levator ani, on each side of the rectum. It decussates ventral to the rectum and from here descends to the ventral surface of the penis, but does not reach the clitoris in the mare.

The **perineal body** is a musculo-fibrous node of tissue between anus and vestibule and consequently is a median structure. It comprises the muscular connection between external anal sphincter and constrictor vestibuli, the internal anal sphincter, the subanal decussation of the retractor clitoridis, and a fibrous plate (perineal septum) that passes craniodorsally from the vestibule to the rectum.

The birth process in the mare is occasionally accompanied by perineal lacerations; in severe cases a foot of the foal can push through the dorsal wall of the vestibule and the ventral wall of the rectum, tearing apart the tissues of the perineal body.

In the male the urethra can be palpated as it turns around the ischial arch. It is accessible to the surgeon at this point when urinary calculi have to be removed.

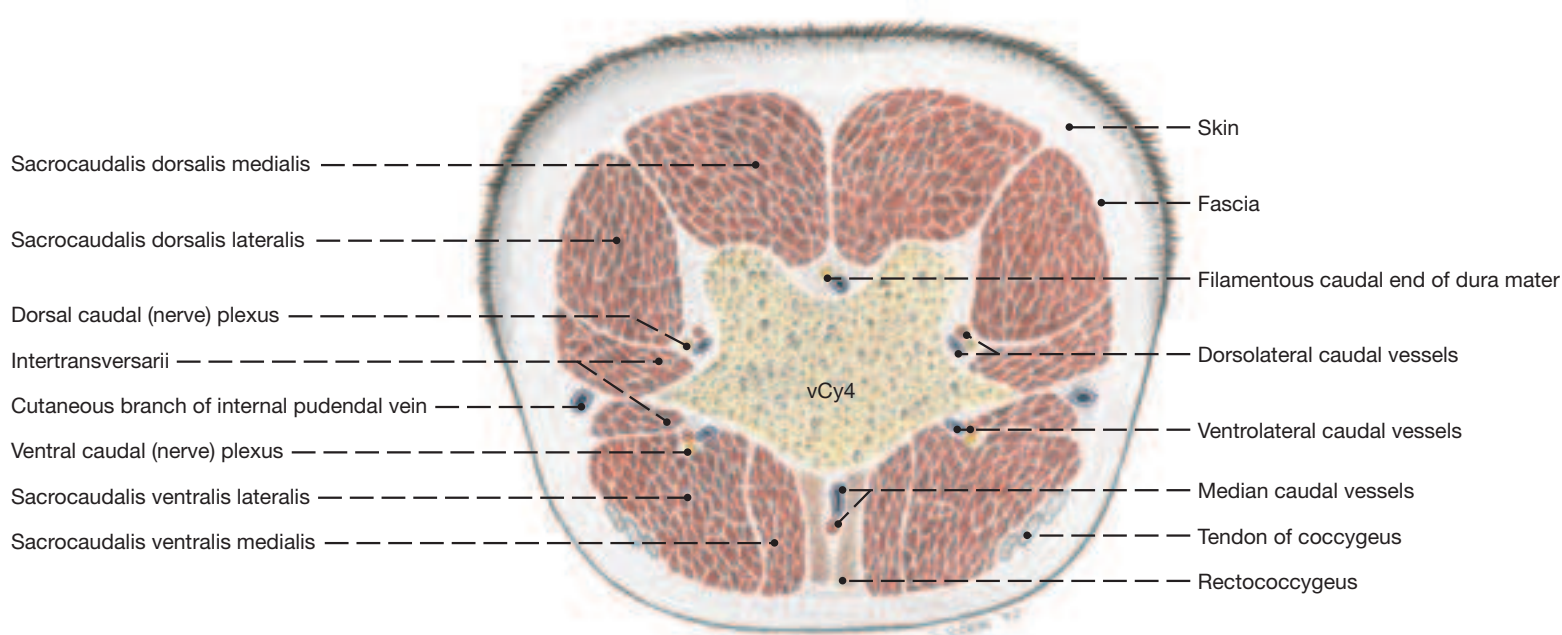
The **pudendal** and **caudal rectal nerves** (see p. 81.j; k) supply the perineum with motor and sensory innervation. They arise from spinal nerves S2–S4 where their roots communicate. The nerves furnish supf. perineal nerves to the skin of the perineal region as far as the base of udder and scrotum.

The pudendal nerve at first lies on the deep surface of the sacrosciatic ligament but soon buries into it. At the lesser sciatic foramen it communicates with the **caudal cutaneous femoral nerve** and releases the **deep perineal nerve** (see p. 81.i; l). The latter reinforces the supf. perineal nerves and then passes deeply to the muscles of the perineum. The continuation of the pudendal nerve crosses the internal pudendal artery and, near the median plane, turns around the ischial arch to innervate penis and clitoris.

The caudal rectal nerve runs parallel to the pudendal nerve and at first supplies the coccygeus and levator ani. Further branches go to the anal sphincter and via the supf. perineal nerve to the skin.

c) The **TAIL** of the horse contains about 20 vertebrae of which the last few are thin rods without discernable processes. The vertebrae are surrounded by several muscles most of which arise from the sacrum (Mm. sacrocaudales); the muscles are enclosed by fascia on the outside of which is the skin. There are four **sacrocaudales muscles**: **dorsalis medialis** (see p. 83.k), **dorsalis lateralis** (see p. 83.l), **ventralis lateralis** (see p. 83.m), and **ventralis medialis** (see also the Fig. on this page). The much smaller **intertransverse muscles** connect neighboring transverse processes. The smooth **rectococcygeus**, as already mentioned, continues the longitudinal muscle layer of the rectal wall to the first few caudal vertebrae. The retractor penis (clitoridis) passes ventrally from the second caudal vertebra. Blood vessels and nerves closely accompany the caudal vertebrae. The largest are the **median caudal vessels** (from the caudal gluteal) which lie ventral to the vertebrae associated, at the root of the tail, with the rectococcygeus (see Fig. on this page). Taking the pulse from the artery is not as convenient as in cattle in which the sacrocaudal muscles are not as well developed.

Transverse Section of the Root of the Tail

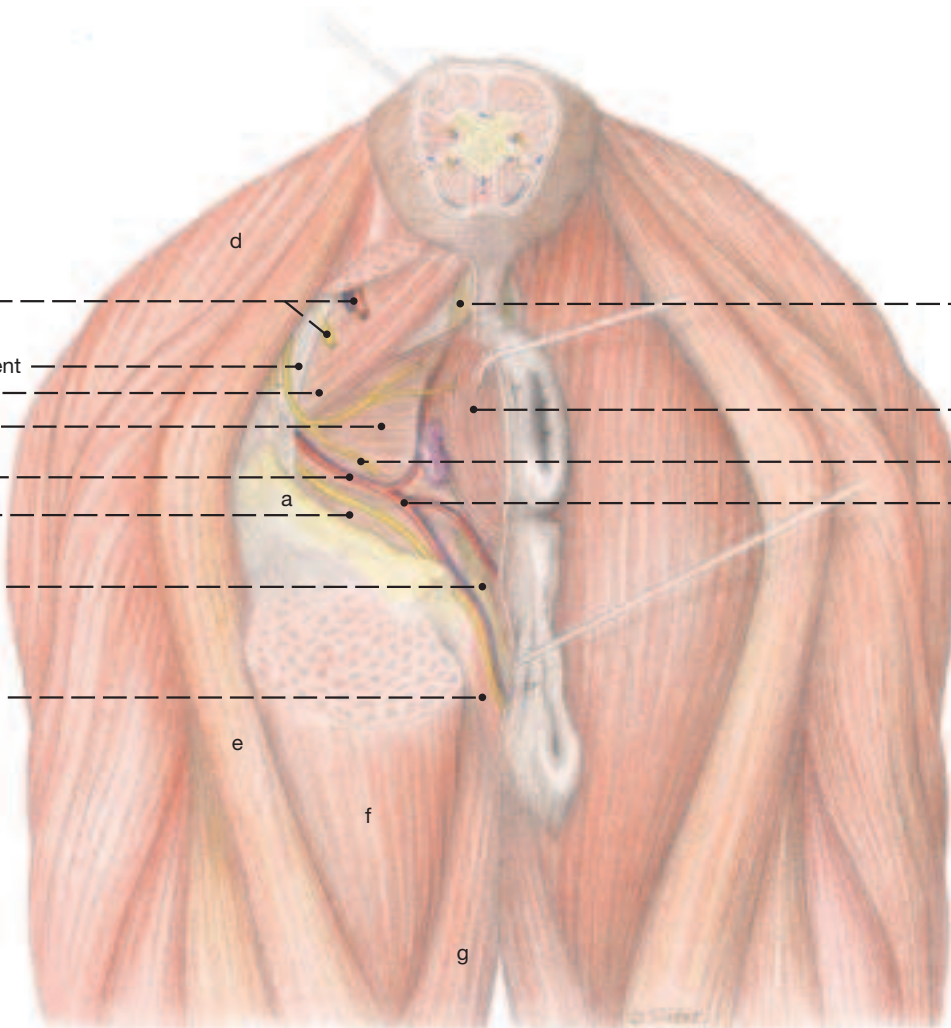


Regio perinealis



(caudal view)

- | | |
|---|---------------------------|
| 1 Caudal rectal n.,
Caudal gluteal a./v. | 7 Rectococcygeus m. |
| Broad sacrotuberous ligament | 8 External anal sphincter |
| 2 Coccygeus m. | 9 Deep perineal nerve |
| 3 Levator ani m. | Ventral perineal a./v. |
| Internal pudendal a./v. | |
| 4 Obturator internus | |
| 5 Retractor clitoridis m. | |
| 6 Constrictor vulvae m. | |



- a Ischiadic tuber
b Greater trochanter
c Third trochanter

- d Biceps femoris m.
e Semitendinosus m.
f Semimembranosus m.
g Gracilis m.

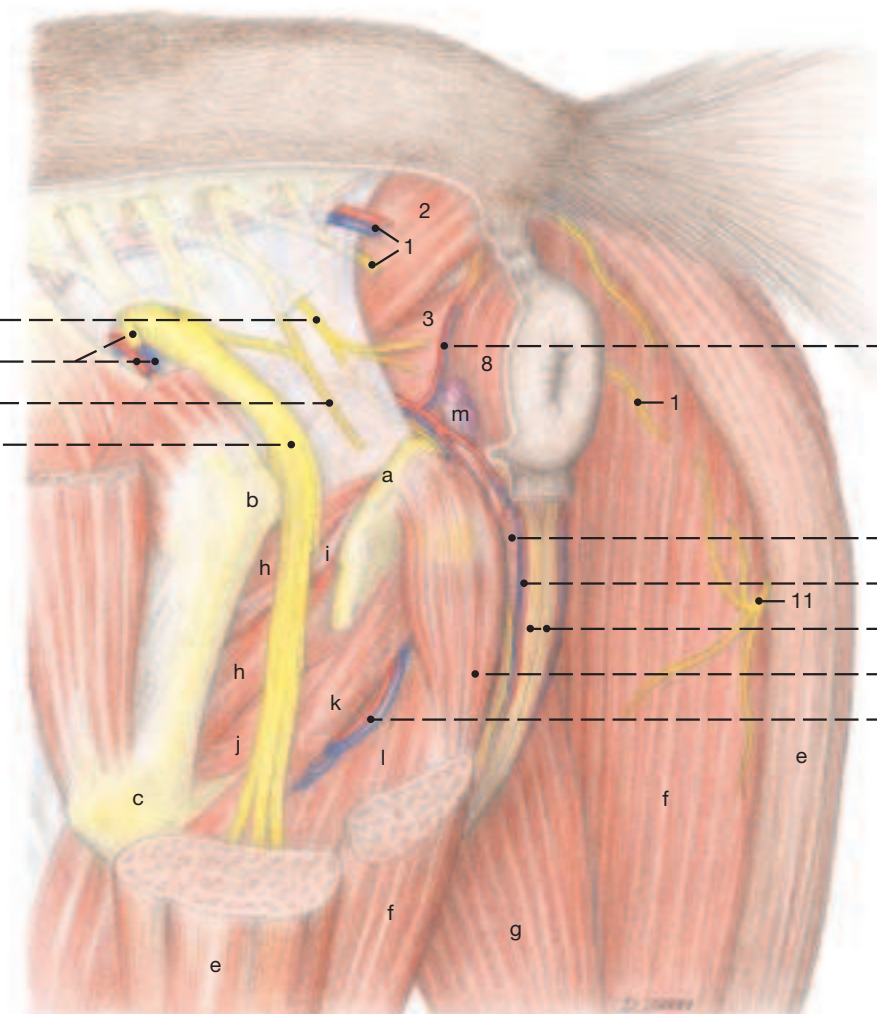
- h Gemellus mm.
i Internal obturator m.
j External obturator m.
k Quadratus femoris m.

- l Adductor magnus m.
m Anorectal ln.



(lateral view)

- | | |
|--------------------------------|--------------------------------|
| 10 Pudendal n. | 12 Bulbospongiosus m. |
| Cranial gluteal a./v. | a./v. of the bulb of the penis |
| 11 Caudal cutaneous femoral n. | 13 Retractor penis m. |
| Ischiadic (sciatic) n. | Ischiocavernosus m. |
| | Dorsal a./v. of the penis |



Chapter 10: Selected Body Systems in Tabular Form

1. Muscles

Muscle	Origin	Insertion	Innervation	Function	Comments
Medial shoulder and arm muscles (p. 7)					
Teres major (7.1)	Caudal border of scapula and subscapularis	Teres tuberosity of humerus	Axillary n.	Flexes shoulder joint	Wide, flat muscle
Subscapularis (7.3)	Subscapular fossa of scapula	Lesser tuberosity of humerus	Subscapular and axillary nn.	Predominantly an extensor of shoulder joint	Multipennate; functions as (contractile) medial collateral ligament of shoulder joint
Coracobrachialis (7.19)	Coracoid process of scapula	Proximomedial surface of humerus	Musculocutaneous n.	Extensor of shoulder joint; adductor of limb	Has a synovial bursa or a tendon sheath associated with tendon of origin
Articularis humeri	Proximal to medial rim of glenoid cavity	Neck of humerus	Axillary n.	Tenses shoulder joint capsule	Lies on medial surface of shoulder joint capsule
Biceps brachii (7.25)	Supraglenoid tubercle	Radial tuberosity; medial collateral lig.; via lacertus fibr. on tendon of extensor carpi rad.	Musculocutaneous n.	Extensor of shoulder joint; flexor of elbow joint; via lacertus fibr. stabilizer of carpus (in stay-apparatus)	Intertubercular bursa under tendon of origin; has int. tendon; consists of two parts assumed to be principally postural and locomotor
Brachialis (7.20)	Proximocaudal surface of humerus	Proximomedial surface of radius	Musculocutaneous n.; lateral parts of muscle by radial n. in half the horses	Flexor of elbow joint	Long fibers for considerable shortening during contraction; in half the horses additional innervation by radial n.
Tensor fasciae antebrachii (7.21)	Caudal border of scapula; insertion tendon of latissimus dorsi	Deep fascia of forearm; olecranon	Radial n.	Tenses forearm fascia; extends elbow joint	
Lateral shoulder and arm muscles (p. 7)					
Deltoideus • Clavicular part (M. cleidobrachialis) (7.22) • Scapular part (7.6)	Clavicular inscription Aponeurotically from scapular spine; fleshy from caudal border of scapula	Crest of humerus Deltoid tuberosity of humerus	Axillary n.	Advances limb Flexes shoulder joint	
Teres minor (7.13)	Distal half of caudal border of scapula	Proximal to deltoid tuberosity of humerus	Axillary n.	Flexes shoulder joint	Covered by deltoideus
Supraspinatus (7.5)	Supraspinous fossa, scapular cartilage and spine	Greater and lesser tubercles of humerus	Suprascapular n.	Extends and stabilizes shoulder joint	Biceps tendon of origin passes between the two insertion tendons of supraspinatus
Infraspinatus (7.10)	Infraspinous fossa, scapular cartilage and spine	Fleshy on greater tubercle of humerus; strong tendon to lat. surface of greater tubercle distal to lat. insertion of supraspinatus	Suprascapular n.	Extends (and flexes) shoulder joint; functions as (contractile) lat. collateral ligament	Multipennate; its strong tendon underlain by (infraspinatus) bursa
Triceps brachii		Olecranon tuber (underlain by small bursa)	Radial n.	Extends elbow joint, its long head also flexes shoulder joint	Medial head is relatively the weakest
• Long head (7.15) • Lateral head (7.16) • Medial head (7.17)	Caudal border of scapula Deltoid tuberosity and vicinity Medial surface of humerus, middle third				
Anconeus (7.24)	Border of olecranon fossa	Lat. surface of olecranon	Radial n.	Extends elbow joint; raises joint capsule to prevent its being pinched during extension of joint	Not easily separated from lat. head of triceps

Muscle	Origin	Insertion	Innervation	Function	Comments
Caudomedial forearm muscles (p. 7)					
Supf. digital flexor (7.32)	Medial epicondyle of humerus	Distal collat. tubercles of prox. phalanx; prox. collat. tubercles of middle phalanx	Ulnar n.	Flexes digit and carpus; extends elbow joint	Receives access. lig. from radius; forms sleeve around deep flexor tendon at fetlock joint
Deep digital flexor (7.35)		Flexor surface of distal phalanx		Flexes digit and carpus; extends elbow joint	Receives access. lig. from carpus; passes through supf. flexor sleeve; bursa betw. tendon and navicular bone
• Humeral head	Medial epicondyle of humerus		Median and ulnar nn.		
• Ulnar head	Medial on olecranon		Ulnar n.		
• Radial head	Middle of caudal surface of radius		Median n.		
Flexor carpi ulnaris (7.41)		Access. carpal bone	Ulnar n.	Flexes carpus	Its humeral head underlain by a bursa
• Humeral head	Medial epicondyle of humerus				
• Ulnar head	Medial on olecranon				
Flexor carpi radialis (7.28)	Medial epicondyle of humerus	Prox. end of Mc2	Median n.	Flexes carpus	At its origin underlain by a bursa that communicates with that of flexor carpi ulnaris
Metacarpus					
Interosseus (medius)	Proximocaudal on Mc3, and palmar carpal lig	Prox. sesamoid bones	Deep branch of ulnar n.	Counteracts overextension of fetlock joint	Contains little muscular tissue; sends extensor branches around prox. phalanx to common digital extensor
Craniolateral forearm muscles: Most of which arise from the lateral epicondyle of the humerus (p. 7)					
Common digital extensor (7.33)	Radial head (Phillip's muscle) (7.34)	Proximodorsal on prox. phalanx (together with tendon of lat. dig. extensor)	Radial n.	Carpal and digital extensor	In the digit the tendon receives the extensor branches of the interosseus
	Humeral head (7.33) Lat. epicondyle of humerus Ulnar head (Thierness' muscle)	Extensor process of distal phalanx (and of middle phalanx)			
Lateral digital extensor (7.36)	Prox. end of radius and ulna	Proximodorsal on prox. phalanx	Radial n.	Extensor of fetlock joint (not of digit)	Insertion tendon combines with Phillip's muscle and is underlain by a bursa
Extensor carpi radialis (7.31)	Lat. supracondylar crest and radial fossa	Proximodorsal on Mc3	Radial n.	Extends carpus	Tendon receives the lacertus fibr. and passes under the insertion tendon of the extensor obliquus
Ulnaris lateralis (M.extensor carpi ulnaris) (7.38)	Lat. epicondyle of humerus	Its short tendon on access. carpal bone; its long tendon prox. on Mc4	Radial n.	Flexes (!) carpus	Only the long tendon has a tendon sheath
Extensor carpi obliquus (M.abductor pollicis longus) (7.42)	Craniolateral, middle of radius	Prox. on Mc2	Radial n.	Extends carpus	Covered by the digital extensors; its tendon has a tendon sheath and is underlain by a bursa
Muscles of the hip joint (p. 19)					
Tensor fasciae latae (19.20; 73.i)	Coxal tuber	Together with the fascia lata on patella, lat. patellar lig., and cran. border of tibia; with supf. gluteal muscle on third trochanter	Cran. gluteal n.	Flexes hip joint; protracts hindlimb; extends stifle; tenses fascia lata	Forms cran. border of thigh; its caudal portion blends with supf. gluteal muscle

Muscle	Origin	Insertion	Innervation	Function	Comments
Muscles of the group					
Supf. gluteal muscle (19.11)	Coxal tuber (gluteal fascia)	Third trochanter and fascia lata	Cranial and caudal gluteal nn.	Flexes hip joint; protracts and abducts hindlimb	Blends with tensor fasciae latae
Middle gluteal muscle (19.3)	Longissimus lumborum; gluteal surface of ilium; sacrum; sacroiliac and sacrosciatic lig.	Greater trochanter	Cranial gluteal n.	Extends hip joint; abducts hindlimb	
Accessory gluteal muscle (19.9)	Gluteal surface of ilium	Just distal to greater trochanter	Cranial gluteal n.		Considered deep portion of middle gluteal muscle; tendon underlain by trochanteric bursa
Deep gluteal muscle (19.6)	Ischial spine	Greater trochanter	Cranial gluteal n.	Abducts hindlimb	Deep to caudal portion of middle gluteal muscle
Caudal thigh muscles: Double innervation by caudal gluteal and tibial nerves (p. 19)					
Biceps femoris (19.22)	Vertebral head: Spinous and transv. processes of last three sacral vertebrae; Sacrosiatic lig. and tail fascia; Pelvic head: ischial tuber	Patella; lat. and middle patellar ligg.; cran. border of tibia; crural fascia; and via its tarsal tendon on calcaneus	Caudal gluteal and sciatic nn.	Extends hip and stifle joints; with its caudal division flexes stifle; abducts hindlimb; extends hock joint	
Semitendinosus (19.1)	Vertebral head: last sacral and first two caudal vertebrae; tail fascia and sacrosiatic ligament; Pelvic head: ventral aspect of ischial tuber	Cranial border of tibia; crural fascia; via tarsal tendon on calcaneus	Caudal gluteal and sciatic nn.	Limb supporting weight: extends hip, stifle, and hock joints; Limb not supporting weight: flexes stifle, retracts and adducts limb	Bursa between ischial tuber and vertebral head of muscle
Semimembranosus (19.23)	Vertebral head: first caudal vertebra; sacrosiatic ligament; Pelvic head: ventromedial aspect of ischial tuber	Medial condyles of femur and tibia	Caudal gluteal and sciatic nn.	Limb supporting weight: extends hip and stifle joints; Limb not supporting weight: retracts, adducts, and rotates limb inward	Blends with adductor
Deep muscles of the hip joint (pp. 19 and 87)					
Gemelli (87.h)	Dorsal border of ischium	Trochanteric fossa of femur	Muscular br. of sciatic n.	Rotate thigh outward	
Internal obturator (19.7; 87.i)	Internal surface of ischium and pubis from border of obturator foramen to pelvic symphysis	Trochanteric fossa of femur	Muscular br. of sciatic n.	Rotates thigh outward	As tendon crosses lesser sciatic notch it is surrounded by a tendon sheath
Quadratus femoris (87. k)	Ventral surface of ischium	Caudal surface of femur near third trochanter	Muscular br. of sciatic n.	Assists in extending hip joint	Covered medially by adductor
External obturator (87.j)	Ventral surface of pelvis from border of obturator foramen	Trochanteric fossa of femur	Obturator n.	Rotates thigh outward; adducts limb	Obturator n. passes through a gap in this muscle
Medial muscles of the thigh: adductors (p. 19)					
Gracilis (19.21; 73.8; 87.g)	Pelvic symphysis via symphyseal tendon	Crural fascia, medial patellar ligament, and cranial border of tibia	Obturator n.	Adducts limb (also extends stifle)	The tendons of origin of right and left muscles form the symphyseal tendon; the muscle forms the caudal border of the femoral triangle
Adductor (19.19)	Ventral surface of pelvis; symphyseal tendon	Caudal surface and medial epicondyle of femur	Obturator n.	Adducts and retracts limb	
Pectineus (19.14; 73.6; 77.5)	Pubis and iliopubic eminence of the other side	Medial surface of femur	Obturator and femoral nn.	Adducts limb; flexes hip joint	The tendons of origin of right and left muscles form the prepubic tendon

Muscle	Origin	Insertion	Innervation	Function	Comments
Extensors of the stifle (p. 19)					
Sartorius (19.10; 73.18)	Int. iliac fascia and insertion tendon of psoas minor	Medial aspect of stifle	Femoral n.	Flexes hip joint; pro- tracts and adducts limb	Forms cranial border of femoral triangle
Quadriceps femoris (19.15; 73.j)		Via the intermediate patellar ligament on the tibial tuberosity	Femoral n.	Flexes hip joint (rectus fem.); extends and sta- bilizes stifle	Tonus stabilizes patella; prox. and distal infra- patellar bursae lie deep to insertion tendon (intermediate patellar lig.)
• Rectus femoris (19.o)	Shaft of ilium cranial to acetabulum				
• Vastus lateralis (19.p)	Proximolateral on femur				
• Vastus medialis (19.n)	Proximomedial on femur				
• Vastus intermedius	Proximodorsal on femur				
Special flexor of the stifle: caudal to the stifle (p. 19)					
Popliteus (19.27)	Lat. condyle of femur	Caudomedial border of tibia	Tibial n.	Flexes stifle	Tendon of origin is sur- rounded by a pouch of the stifle joint
Extensors of the hock, flexors of the digit: on caudal surface of leg (p. 19)					
Gastrocnemius (19.26)	With medial and lateral heads from cor- responding supracondy- lar tuberosities of the femur	As part of common calcanean tendon on calcanean tuber	Tibial n.	Extends hock; flexes stifle	
Soleus (19.28)	Prox. end of fibula	Joins common calcanean tendon	Tibial n.	Rudimentary muscle; could extend the hock	Forms m. triceps surae with both heads of gas- trocnemius
Supf. digital flexor (19.31)	Supracondylar fossa of femur	Plantar on distal end of proximal phalanx and prox. collateral tuber- cles of middle phalanx	Tibial n.	Being mainly tendinous, the prox. part acts in the reciprocal mecha- nism, the distal part supports fetlock and pastern joints	Large subtendinous bur- sa over calcanean tuber; forms sleeve for deep dig. flexor at fetlock joint
Deep digital flexor		Plantar on distal phalanx	Tibial n.	Extends hock; flexes digit	
• Lat. digital flexor (19.34)	Caudal surface of tibia with tibialis caudalis				Their tendons combine to pass over the susten- taculum tali Joins common deep flex- or tendon in metatarsus
• Tibialis caudalis (19.33)	Caudal surface of tibia with lat. dig. Flexor				
• Med. digital flexor (19.29)	Lat. tibial condyle				
Fexors of hock and extensors of digit: Craniolateral on leg (p. 19)					
Tibialis cranialis (19.36)	Lat. condyle and tuberosity of tibia	Dors. br.: on T3 and prox. end of Mt3; Med. br.: on T1+2	Peroneal n.	Flexes hock joint	The medial branch of its insertion tendon is known also as the “cunean tendon”
Peroneus tertius (19.37)	Lat. condyle of femur	By four branches on all tarsal bones (except T1+2) and on Mt3	Peroneal n.	Entirely tendinous; constituent of reci- procal mechanism	Originates together with long dig. extensor from the lat. condyle of the femur
Long digital extensor (19.40)	Lat. condyle of femur	Extensor process of dis- tal phalanx; secondarily on proximal and mid- dle phalanges	Peroneal n.	Extends digit; flexes hock	Held to dorsal surface of hock by three retinacula; in digit receives extensor brr. from interosseus
Lateral digital extensor (19.41)	Lat. collat. lig of stifle and nearby tibia and fibula	Joins long extensor tendon	Peroneal n.	Extends digit; flexes hock	
Extensor digitalis brevis	From the lat. brr. Of peroneus tertius inser- tion tendon	Joins tendon of long extensor	Peroneal n.	Rudimentary: could extend digit	
Metatarsus					
Interosseus muscle (suspensory ligament)	Mt3, calcaneus, and T4	Prox. sesamoid bones	Tibial n.	Counteracts overexten- sion of fetlock joint	In the foal, the inter- osseous is fairly muscu- lar. In the adult the interosseous is entirely tendinous. Its extensor branches pass onto the dorsal aspect of the proximal phalanx and join the long digital ex- tensor tendon.

Muscle	Origin	Insertion	Innervation	Function	Comments
Facial Musculature (p. 37)					
Cutaneous muscle of the face (37.a)	Thin bundles between larynx and mouth		Facial n.	Moves the skin; retracts angle of the mouth	
M. sphincter colli profundus: Muscles of the external ear (p. 37)					
Supf. cervicoauricularis (37.29)	Ext. occipital protuberance and nuchal lig.	Ext. surface of auricle	Caudal auricular n. (from facial), and great auricular n.	Raises auricle	Has double innervation
Cervicoscutularis	Nuchal crest	Caudomedial on scutiform cartilage	Facial and caudal auricular nn.	Elevates auricle	Well developed
Cervicoauricularis profundus and medius (37.l)	Nuchal lig. and caudal surface of occipital bone	Lateral border of auricle	Facial and caudal auricular nn.	Moves auricle laterally	Partially covered by supf. cervicoauricularis
Interscutularis (37.o)	Connects right and left scutiform cartilages	Also attaches on ext. sagittal crest and temporal line	From facial n.: auriculopalpebral n. and rostral auricular brr.	Stabilizes scutiform cartilage	
Frontoscutularis (37.m) • Frontal part • Temporal part	Temporal line Zygomatic arch	Rostal and lateral on scutiform cartilage	From facial n.: auriculopalpebral n. and rostral auricular brr.	Stabilizes scutiform cartilage	Both parts well isolated
Supf. scutuloauricularis	Scutiform cartilage	Rostromedial on auricle	From facial n.: auriculopalpebral n. and rostral auricular brr.	Straightens and moves auricle medially	May be divided into three parts
Zygomaticoauricularis (37.n)	Zygomatic arch	Ventromedial on auricle	From facial n.: auriculopalpebral n. and rostral auricular brr.	Moves auricle medially	
Parotidoauricularis (37.28)	Fascia covering parotid gland	Ventrolateral on the base of the auricle	Cervical br. of facial n.	Depressor of auricle	Lies on parotid gland
Styloauricularis	Ext. acoustic meatus	Ventromedial on the base of the auricle	Caudal auricular n. (from facial)	Not known	Lies on ext. acoustic meatus
Muscles of the lips and cheek (p. 37)					
Orbicularis oris (37.1)	Forms a closed circle around the mouth		Dorsal and ventral buccolabial brr. of facial n.	Closes the mouth opening	No attachment on bone
Buccinator (37.7)	Border of upper jaw and coronoid process of mandible	Border of lower jaw	Dorsal and ventral buccolabial brr. of facial n.	Forms muscular basis of cheek; returns food to the central cavity of the mouth	May be divided into buccal and molar parts
Zygomaticus (37.5)	Facial crest	Angle of mouth	Auriculopalpebral br. of facial n.	Retracts angle of mouth	
Caninus (37.3)	Rostral end of facial crest	Lateral border of nostril	Dorsal and ventral buccolabial brr. of facial n.	Elevates upper lip and widens nostril	Passes between the two parts of the levator nasolabialis
Levator labii superioris (37.6)	Lacrimal bone	By common tendon with its fellow between the nostrils in the upper lip	Dorsal and ventral buccolabial brr. of facial n.	Elevates upper lip; “flehmen” reaction	Covers infraorbital foramen; passes deep to levator nasolabialis
Depressor labii inferioris (37.2)	Mandibular ramus	Blends with orbicularis oris in lower lip	Dorsal and ventral buccolabial brr. of facial n.	Depresses and retracts lower lip	Its tendon covers the mental foramen

Muscle	Origin	Insertion	Innervation	Function	Comments
Muscles of the eye lids and nose (p. 37)					
Orbicularis oculi (37.23 and 43.c)	Forms a closed circle around palpebral fissure		Auriculopalpebral n. (from facial n.)	Closes palpebral fissure	Better developed in upper lid
Levator anguli oculi (37.22)	Base of zygomatic process of frontal bone	Medial end of upper lid	Auriculopalpebral n. (from facial n.)	Elevates medial part of upper lid	A small muscle
Levator nasolabialis (37.4)	Frontal and nasal bones	Supf. part: blends with orbicularis oris; deep part: into upper lid	Auriculopalpebral n. (from facial n.)	Elevates upper lip; enlarges nostril	Caninus passes between the two parts of the muscle
Malaris (37.9)	Dorsal to facial crest	Lower lid	Auriculopalpebral n. (from facial n.)	Pulls lower lid ventrally	A small muscle
Muscles of mastication (pp. 37, 39 and 45)					
Supf. Muscles of the intermandibular space					
Digastricus (39.17)	Paracondylar process	Ventral border of mandible; its occipito-mandibular part to angle of mandible	Caudal belly: digastric br. of facial n.; Rostral belly: mylohyoid n. of mandibular n.	Opens mouth; elevates hyoid apparatus	The two bellies are separated by an intermediate tendon which penetrates the tendon of the stylohyoideus
Mylohyoideus (39.15; 45.k)	Lingual surface of mandible (mylohyoid line)	Basihyoid and lingual process; and median raphe	Mylohyoid n. (from mandibular n.)	Elevates floor of mouth; presses tongue against hard palate	Consists of rostral and caudal parts
Lateral Muscles of Mastication					
Temporalis (39.11)	Temporal fossa and medial surface of zygomatic arch	Coronoid process of mandible	Masticatory n. (from mandibular n.)	Mastication (elevates mandible and presses it against maxilla)	
Masseter (39.9) • Supf. part • Deep part	Facial crest Zygomatic arch	Large area caudolateral on mandible	Masticatory n. (from mandibular n.)	Mastication (elevates mandible and presses it against maxilla)	Pennate muscle
Medial Muscles of Mastication					
Ptergoideus (39.12) • —medialis • —lateralis	Pterygoid process of basisphenoid and vicinity	Convave medial surface of mandible; condyle of mandible and vicinity	Pterygoid nn. (from mandibular n.)	Synergist to masseter; in unilateral contraction: moves lower jaw laterally	The mandibular n. lies between the two muscles; the lateral muscle is fleshy
Muscles of the eye (p. 41 and Anatomy of the Dog)					
Muscles of the pharynx (p. 47)					
Stylopharyngeus (47.10)	Medial on dorsal third of stylohyoid	Dorsolateral pharyngeal wall	Glossopharyngeal n. (IX)	Dilates pharynx	The only muscle that dilates the pharynx
Muscles of the Soft Palate					
Tensor veli palatini (47.7)	Muscular process of petrous temporal bone, pterygoid bone, lateral surface of auditory tube	Around hamulus of pterygoid bone into the aponeurosis of the soft palate	Mandibular n. (V3)	Tenses soft palate	
Levator veli palatini (47.8)	Muscular process of petrous temporal bone, lateral surface of auditory tube	In the soft palate	Pharyngeal plexus (IX and X)	Elevates soft palate	

Muscle	Origin	Insertion	Innervation	Function	Comments
Rostral Pharyngeal Constrictors					
Pterygopharyngeus (47.9)	Pterygoid bone	Pharyngeal raphe	Pharyngeal plexus (IX and X)	Constricts and protracts pharynx	Difficult to separate from palatopharyngeus; crosses lat. surface of levator veli palatini
Palatopharyngeus (47.11)	Via aponeurosis of soft palate from palatine and pterygoid bones	Pharyngeal raphe and dorsal border of thyroid cartilage	Pharyngeal plexus (IX and X)	Constricts and protracts pharynx	Lies medial to levator veli palatini
Middle Pharyngeal Constrictor					
Hypopharyngeus (47.12)	Medial surface of ventral end of stylohyoid; thyrohyoid and thyroid lamina	Pharyngeal raphe	Pharyngeal plexus (IX and X)	Constricts pharynx	May be divided into cerato- and chondropharyngei
Caudal Pharyngeal Constrictors					
Thyropharyngeus (47.13)	Thyroid cartilage	Pharyngeal raphe	Pharyngeal plexus (IX and X)	Constricts pharynx	Blends with cricopharyngeus
Cricopharyngeus (47.14)	Arch of cricoid cartilage	Pharyngeal raphe	Pharyngeal plexus (IX and X)	Constricts pharynx	Blends caudally with the longitudinal musculature of the esophagus

Intrinsic muscles of the larynx (p. 49)

Cricothyroideus (49.12)	Ventrolateral on cricoid cartilage	Caudal border of thyroid lamina	Cranial laryngeal n. (from vagus)	Narrows glottic cleft; tenses vocal folds	
Cricoarytenoideus dorsalis (49.7)	Ipsilateral half of cricoid lamina	Muscular process of arytenoid cartilage	Recurrent laryngeal n. (from vagus)	Enlarges glottic cleft	
Cricoarytenoideus lateralis (49.6)	Rostrolateral on cricoid cartilage	Muscular process of arytenoid cartilage	Recurrent laryngeal n. (from vagus)	Narrows glottic cleft	
Arytenoideus transversus (49.5)	Muscular processes of right and left arytenoid cartilages	Median raphe dorsal to arytenoid cartilages	Recurrent laryngeal n. (from vagus)	Narrows glottic cleft	Unpaired muscle
Thyroarytenoideus			Recurrent laryngeal n. (from vagus)	Narrows glottic cleft	
• Ventricularis (49.9)	Ventromedial on thyroid cartilage, and on cricothyroid ligament	Muscular process of arytenoid cartilage; some fibers blend with arytenoideus transv.			
• Vocalis (49.11)	Ventromedial on thyroid cartilage	Muscular and vocal processes of arytenoid cartilage			
Thyroarytenoideus accessorius	Muscular process of arytenoid cartilage	Dorsal border of thyroid lamina	Recurrent laryngeal n. (from vagus)	Constricts glottic cleft	Inconstant and present only in the horse; may be represented by a ligament
Tensor ventriculi laryngis	Cuneiform process of epiglottic cartilage	Fans to lateral surface of laryngeal ventricle	Recurrent laryngeal n. (from vagus)	Tenses lateral laryngeal ventricle	Thin muscle, present only in the horse

Muscles of the tongue and hyoid apparatus (fan into the tongue or attach on the basihyoid) (p. 45 and 51)

M. lingualis proprius	Intrinsic tongue muscle		Hypoglossal n. (XII)	Simultaneous contraction of transv. and perpendicular bundles stiffens the tongue	Consists of longitudinal, transverse, and perpendicular bundles
Extrinsic Tongue Muscles					
Styloglossus (51.10)	Lateral surface of stylohyoid	Ends near the tip of the tongue	Hypoglossal n. (XII)	Pulls tongue caudodorsally; in unilateral contraction, to the side	Right and left muscles fuse near the tip of the tongue

Muscle	Origin	Insertion	Innervation	Function	Comments
Hyoglossus (45.e; 51.11)	Lingual process of basihyoid; stylo- and thyrohyoids	Ends in tongue, most fibers near dorsum and near median plane	Hypoglossal n. (XII)	Pulls tongue caudoven- trally	Antagonist to genio- glossus
Genioglossus (45.d)	Incisive part of mandible	Fans sagittally into the tongue, into tip and toward root	Hypoglossal n. (XII)	Pulls tongue rostrally and ventrally	The median septum of the tongue separates right and left muscles
Muscles of the Hyoid Apparatus					
Geniohyoideus (45.j)	Incisive part of mandible	Lingual process of basihyoid	Hypoglossal n. (XII)	Draws hyoid apparatus (and tongue) rostrally	Forms muscular basis of the floor of the mouth
Thyrohyoideus (51.12)	Thyroid cartilage	Thyrohyoid bone	Hypoglossal n. (XII)	Draws larynx and thyrohyoid toward each other	Rostral continuation of the sternothyroideus
Mylohyoideus (45.k)	See Supf. Muscles of the Intermandibular Space (p. 38)				
Stylohyoideus	Caudodorsal end of stylohyoid bone	Thyrohyoid bone	Facial n. (VII)	Draws thyrohyoid bone and larynx dorsocaudally	Tendon of insertion is split for passage of intermediate tendon of digastricus
Occipitohyoideus	Paracondylar process	Caudodorsal end of stylohyoid bone	Facial n. (VII)	Depresses root of tongue and larynx	Blends with caudal belly of digastricus
Hyoideus transversus (49.j)	Ceratohyoid bone	On median raphe to connect with its fellow from the other side	Glossopharyngeal n. (IX)	Elevates root of tongue	
Ceratohyoideus	Rostral border of thyrohyoid bone	Caudal border of ceratohyoid and prox. end of stylohyoid bones	Glossopharyngeal n. (IX)	Draws larynx rostro- dorsally	Thin plate of muscle, fills triangle between cerato- and thyrohyoids
Hyoepiglotticus	Basihyoid bone	Base of rostral surface of epiglottic cartilage	Hypoglossal n. (XII)	Draws epiglottis rostroventrally	Associated with hyo-epiglottic ligament

Infrahyoid muscles (p. 45/51, and 59)

Sternothyroideus (51.k; 59.20)	} Manubrium sterni	} Thyroid cartilage of larynx	Spinal nerve C1	Retracts larynx; synergist to sternohyoideus	In midneck divided by a transverse tendinous intersection into cranial and caudal parts
Sternohyoideus (59.19)			Spinal nerve C1	Retracts basihyoid and tongue	
Omohyoideus (37.j; 59.13)	Subscapular fascia near shoulder joint	} Lingual process of basihyoid bone	Spinal nerve C1	Synergist to sternohyoideus	Connected to overlying cleidomastoideus in caudal half of the neck; forms floor of jugular groove

Cutaneous muscles (p. 37/59, and 64)

Platysma:					
• Cutaneous muscle of the face (37.a)	From the supf. fascia in the vicinity of the larynx	Fades away in the vicinity of the angle of the mouth	Ramus colli of the facial n.	Tightens and moves the skin of the head	
• Cutaneus colli (59.5)	Manubrium sterni	On the supf. fascia covering the region of the jugular groove	Ramus colli of the facial n.	Tightens and moves the skin on the ventral surface of the neck	By its contraction may interfere with the raising of the jugular vein
Cutaneus trunci (64.A)	From the supf. trunk fascia roughly along a line from the withers to the fold of the flank	Opposite the dorsal two thirds of the scapula: blends with the supf. shoulder fascia; Opposite the ventral third of the scapula: ends with deep pectoral muscle on medial surface of humerus	Lateral thoracic and intercostobrachial nn.	Tightens and moves the skin of the trunk	Its fibers run from cranial to caudal

Muscle	Origin	Insertion	Innervation	Function	Comments
• Cutaneus omobrachialis (64.A')	From the supf. shoulder fascia opposite the scapula	Over the elbow joint	Intercostobrachial n.	Tightens and moves the skin over the shoulder	Is a cranial continuation of the cutaneus trunci
Epaxial muscles of the vertebral column (p. 59)					
Splenius (59.d) • —capitis • —cervicis	Spinous processes of T3–5 by means of thoracolumbar fascia; nuchal ligament	Nuchal crest and mastoid process of temporal bone; transv. processes of C2–5	Dorsal br. of local spinal nn., and dorsal br. of accessory n. (XI)	Extends, elevates, or bends neck and head laterally	Well developed; contours visible through skin; both parts distinguished easily
Iliocostalis • —cervicis	Between transv. processes of C4 and T1 and first rib		Dorsal br. of local spinal nn.	Stabilizes lumbar vertebrae and ribs; extends vertebral column and bends it laterally; may function in expiration	Its lumbar portion is fused with the longissimus muscle
• —thoracis (59.n, 75.a)	Lumbar transverse processes and fleshy from cran. border of ribs	Angles of ribs 1–15 and transv. process of C7			
Longissimus • —lumborum • —thoracis (59.m') • —cervicis (59.m) • —capitis et atlantis (51.o)	Spinous processes of sacrum, lumbar, and thoracic vertebrae; wing of ilium; transv. processes of thoracic and cervical vertebrae	Transv. processes of vertebrae; tubercles of ribs; wing of atlas; and mastoid process of temporal bone	Dorsal br. of local spinal nn.	Stabilizes and extends vertebral column; elevates or bends head and neck laterally	Longissimus capitis and atlantis are well separated
Spinalis (59.u) • —thoracis • —cervicis	Spinous processes of lumbar and last 6 thoracic vertebrae	Spinous processes of the first 6–7 thoracic and the last 5 cervical vertebrae	Dorsal br. of local spinal nn.	Stabilizes back and neck; elevates neck or bends it laterally	
Semispinalis capitis (51.m; 61.j)	Transv. processes of the first 6–7 thoracic vertebrae; articular processes of the last 5–6 cervical vertebrae	Occipital bone	Dorsal br. of local spinal nn.	Elevates head and neck or bends it laterally	Uniform powerful muscle
Multifidus (75.c) • —cervicis • —thoracis • —lumborum	Articular and mamillary processes of all vertebrae from C2 to sacrum	Spinous processes of preceding vertebrae	Dorsal br. of local spinal nn.	Stabilizes and twists the vertebral column; elevates neck	In the neck the muscles connect neighboring vertebrae; caudally the muscles are longer and bridge up to six vertebrae
Intertransversarii (59.l)	Between transverse and articular processes of cervical and tail vertebrae		Dorsal br. of local spinal nn.	Stabilizes vertebral column and bends it laterally	Present only in neck and tail; dorsal, middle, and ventral muscles can be distinguished
Sacrocaudalis dorsalis medialis (83.k)	Between spinous and mamillary processes of the last 2–3 sacral and the first several caudal vertebrae		Dorsal br. of local spinal nn.	Elevates tail and bends it laterally	Caudal continuation of multifidus muscles
Sacrocaudalis dorsalis lateralis (83.l)	Laterally on sacrum; transv. processes of the cranial and mamillary processes of the more caudal tail vertebrae	By tendon on the preceding vertebra	Dorsal br. of local spinal nn.	Elevates tail and bends it laterally	Caudal continuation of longissimus muscle; in distal part of tail only thin tendons

Hypaxial of the vertebral column (p. 53)

Hypaxial Muscles

Scalenus • medius (59.p) • ventralis (59.p')	First rib	Transv. process of C7; transv. process of C4–6	Ventral br. of local spinal nn.	Flexes neck, or bends it laterally; may assist inspiration by elevating first rib	The roots of the brachial plexus pass between the two muscles
--	-----------	--	---------------------------------	---	---

Muscle	Origin	Insertion	Innervation	Function	Comments
Longus capitis (51.s; 59.j)	Transv. processes of C3–5	Muscular tubercle on base of skull	Ventral br. of local spinal nn.	Flexes head or bends it laterally	Continues longus colli muscle to the head
Longus colli (59.k)	Thoracic part: bodies of T1–6; Cervical part: transv. processes of C3–7	Thoracic part: transv. processes of C6 and 7; Cervical part: bodies of cervical vertebrae and ventral tubercle of atlas	Ventral br. of local spinal nn.	Flexes neck	
Sacrocaudalis ventralis (19.b)	Lateral part: ventral surface of sacrum, transv. processes of first few tail vertebrae; Medial part: ventral surface of tail vertebrae	With combined tendons on ventrolateral surface of tail vertebrae	Ventral br. of local spinal nn.	Flexes tail or bends it laterally	The median caudal vessels course in the groove between right and left muscles
Rectus capitis ventralis (51.b)	Ventral arch of atlas	On the base of the skull caudal to longus colli muscle	Ventral br. of local spinal nn.	Flexes atlanto-occipital joint	

Dorsal muscles to the head (p. 51)

Rectus capitis dorsalis major	Spinous process of axis	Nuchal crest	Dorsal br. of C1	Elevates head	Relatively weak muscle
Rectus capitis dorsalis minor	Dorsal arch of atlas	Occipital bone	Dorsal br. of C1	Elevates head	Weak muscle; occasionally atrophied
Obliquus capitis caudalis (51.n)	Spinous process of axis	Wing of atlas	Dorsal br. of C2	Rotates atlas (and head) to the side of the muscle	Cranial continuation of multifidus, much enlarged
Obliquus capitis cranialis (51.l)	Ventral surface of wing of atlas	Nuchal crest and mastoid process of temporal bone	Dorsal br. of C1	Extends head, or flexes it laterally	Occupies the space between atlas and occipital bone

Dorsal muscles of the shoulder girdle:

Suspend the limb from neck and trunk (p. 58 and 59)

Trapezius (59.10; 59.10')	Nuchal and supra-spinous ligaments from C2 to T10	Thoracic part: dorsal third of scapular spine; Cervical part: entire scapular spine	Dorsal br. of accessory n. (XI)	Elevates shoulder: draws scapula craniodorsally and caudodorsally	
Omotransversarius (59.6)	Shoulder fascia	Transv. processes of C2–4	Medioventral br. of local cervical nn.	Protracts limb; bends neck laterally	Fused ventrally with the cleidomastoideus
Rhomboideus • —cervicis (59.28) • —thoracis (59.28')'	Nuchal and dorso-scapular ligaments from C2 to T8	Scapular cartilage	Medioventral br. of local thoracic and cervical nn.	Draws scapula dorsally and cranially; elevates neck	
Latissimus dorsi (7.2; 59.11)	Supraspinous ligament from T3 caudally via thoracolumbar fascia	Teres major tuberosity of humerus together with teres major muscle	Thoracodorsal n.	Retracts limb; flexes shoulder joint; when limb is fixed, draws trunk cranially	Wide muscle; converges toward axillary fossa

Ventral muscles of the shoulder girdle:

Suspend the trunk between the forelimbs (p. 58 and 59)

Supf. pectoral muscles • Pectoralis transversus (59.26') • Pectoralis descendens (59.26)	Costal cartilages 1–6 and adjacent sternum Manubrium sterni	Forearm fascia Deltoid tuberosity and crest of humerus	Cranial and caudal pectoral nn.	Connect forelimb with trunk; adduct, pro- and retract forelimb	Pectoralis descendens forms lateral pectoral groove with cleido-brachialis; right and left pectoralis desc. muscles form median pectoral groove
--	--	---	---------------------------------	--	---

Muscle	Origin	Insertion	Innervation	Function	Comments
Deep pectoral muscle (7.h; 59.25')	Sternum; distally on ribs 4–9; tunica flava abdominis	Major and minor tubercles of humerus; tendon of origin of coracobrachialis	Cranial and caudal pectoral nn.	Suspends trunk between forelimbs; retracts limb; stabilizes shoulder joint	
• Subclavius (5.g; 59.25)	Sternum and costal cartilages 1–4	Blends with supraspinatus and shoulder fascia	Cranial pectoral nn.	Suspends trunk; stabilizes shoulder joint	Lies deep to the supf. pectoral muscles
Serratus ventralis • —cervicis (59.27) • —thoracis (57.27')	Transverse processes of C4–7 First 8 or 9 ribs	Scapular cartilage and two adjacent triangular areas on medial surface of scapula	Ventral br. of local cervical nn. Long thoracic n.	Suspends trunk; raises neck when forelimb is fixed; may support inspiration	Major part of synsarcotic connection between trunk and forelimb; Cervical part is fleshy, thoracic part is intershot with tendinous sheets
• Sternoccephalicus (mandibularis) (57.4; 37.K)	Manubrium sterni	Caudal border of mandible	Ventral br. of accessory n. (XI)	Opens mouth; flexes or inclines head and neck to the side of the muscle	Forms ventral border of jugular groove; does not belong to shoulder girdle muscles
• Cleidomastoideus (57.4')	From clavicular intersection at cranial end of cleidobrachialis	Mastoid process of temporal bone	Ventral br. of accessory n. (XI)	Protracts forelimb; flexes and turns head	Forms dorsal border of jugular groove

Expiratory muscles:

Compress thorax by drawing ribs mediocaudally (pp. 59/61, and 65)

Serratus dorsalis caudalis (59.v')	Thoracolumbar fascia	Caudal borders of ribs 11–18	Intercostal nn.	Expiratory muscle	
Internal intercostal muscles (65.b)	In intercostal spaces; fibers run cranioventrally		Intercostal nn.	Expiratory muscle	
Retractor costae (61.a)	Thoracolumbar fascia	Caudal border of last rib	Lumbar nn.	Expiratory muscle	Belongs to the group of internal intercostal muscles
Transversus thoracis (61.v)	Deep surface of sternum	Medial surface of ventral ends of ribs 2–8	Intercostal nn.	Expiratory muscle	Cranial continuation of transversus abdominis

Inspiratory muscles:

Expand thorax by drawing ribs craniolaterally (p. 59/65 and 69)

Serratus dorsalis cranialis (59.v)	Supraspinous ligament via thoracolumbar fascia	Cranial borders of ribs 5–11	Intercostal nn.	Inspiratory muscle	
Rectus thoracis (65.a)	First rib	Costal cartilages 2–4	Intercostal nn.	Inspiratory muscle	Cranial continuation of rectus abdominis
External intercostal muscles (59.h)	In intercostal spaces; fibers run caudoventrally		Intercostal nn.	Inspiratory muscle	Fibers are at almost right angles to those of int. intercostal muscles
Levatores costarum	Transverse processes of thoracic vertebrae	Cranially on angles of ribs 2–17	Intercostal nn. (dors. br.)	Inspiratory muscle	Represent vertebral parts of ext. intercostal muscles
Diaphragm (69.u; 69.v) • sternal part • costal part • lumbar part	Tendinous center	From sternum across lower parts of ribs 9–15 and middle of rib 18, to last thoracic vertebra and lumbar vertebrae 1–4	Phrenic n.	Principal inspiratory muscle	Costal part interdigitates with transversus abdominis; there are three foramina: aortic hiatus, esophageal hiatus, and caval foramen

Muscle	Origin	Insertion	Innervation	Function	Comments
Abdominal muscles (p. 66)					
External abdominal oblique (59.i; 65.3; 73.10; 75.10)	Lateral surface of ribs 4–18; thoracolumbar fascia	Abdominal tendon: linea alba and prepubic tendon; Pelvic tendon: coxal tuber, inguinal lig., prepubic tendon	Local intercostal and ventral br. of lumbar nn.	Compresses abdominal viscera as in defecation, micturition, parturition, and expiration.; flexes the trunk	The supf. inguinal ring is a gap between abdominal and pelvic tendons; aponeurosis forms external rectus sheath with aponeurosis of int. abd. oblique; fibers run caudoventrally
Internal abdominal oblique (19.l; 64.C; 73.2; 75.5)	Coxal tuber and adjacent inguinal lig.	Last rib; cartilages of last five ribs; linea alba and prepubic tendon	Local intercostal and ventral br. of lumbar nn.	Similar to preceding muscle	Forms cranial border of deep inguinal ring; aponeurosis forms external rectus sheath with aponeurosis of ext. abd. oblique; fibers run cranioventrally; detaches cremaster muscle
Transversus abdominis (65.9; 75.11)	Medial surface of costal cartilages 7–18; lumbar transverse processes	Linea alba	Local intercostal and ventral br. of lumbar nn.	Similar to preceding muscle	Aponeurosis forms internal rectus sheath; its deep surface it usually covered by a layer of subperitoneal fat
Rectus abdominis (65.8; 75.15)	Lateral surface of costal cartilages 4–9	Prepubic tendon and, via accessory lig., on head of femur	Local intercostal and ventral br. of lumbar nn.	Assists in the actions of preceding muscle; well positioned to flex lumbar spine and lumbosacral joint	Its attachment on the femoral head stabilizes the hip joint; the muscle contains about ten transverse tendinous inscriptions
Sublumbar muscles (p. 73/75 and 77)					
Quadratus lumborum (77.6)	Ventral surface of prox. ends of last two ribs; lumbar transverse processes	Ventral surface of wing of sacrum and nearby sacroiliac ligaments	Local intercostal and ventral br. of lumbar nn.	Weak muscle; possibly stabilizes last two ribs and lumbar vertebrae	Contains much tendinous tissue
Psoas major (19.g; 73.16; 75.d; 77.7)	Similar to preceding muscle	As iliopsoas (by fusing with iliacus) on lesser trochanter of femur	Local intercostal and ventral br. of lumbar nn.; lumbar plexus	Protracts hindlimb and rotates it outward; flexes hip joint; stabilizes vertebral column when hindlimb is fixed	
Iliacus (19.h; 73.16)	Sacroiliac surface of ilium; adjacent wing of sacrum and psoas minor tendon	As iliopsoas (by fusing with psoas major) on lesser trochanter of femur	Same as preceding muscle	Same as preceding muscle	May be divided into lateral and medial parts
Psoas minor (75.e; 77.8)	Bodies of last three thoracic and first few lumbar vertebrae	Psoas minor tubercle of ilium	Same as preceding muscle	Flexes pelvis on the loins; inclines pelvis to the side	
Pelvic diaphragm (p. 87)					
Levator ani (19.i; 83.o; 87.3)	Medial surface of ischial spine and adjacent part of sacrosciatic lig.	Blends with ext. anal sphincter; also on perineal septum	Caudal rectal n.	Fixes anus during defecation; synergist to coccygeus	Its subanal loop forms part of perineal body

Muscle	Origin	Insertion	Innervation	Function	Comments
Coccygeus (19.e; 83.n; 87.2)	Similar to preceding muscle	Transverse processes of first three to five tail vertebrae; also on tail fascia	Caudal rectal n.	Flexes tail and moves it laterally	Related dorsolaterally to levator ani

Further muscles of the perineum

External anal sphincter (83.p; 87.8)	Muscle fibers related to the tail vertebrae surround the anus		Caudal rectal and deep perineal nn.	Constricts anus	Striated muscle; fibers ventral to anus contribute to perineal body
Internal anal sphincter	Thickened circular muscle coat of rectum surrounds anus		Caudal rectal and deep perineal nn.	Constricts anus	Smooth muscle
Rectococcygeus (87.7)	Caudal continuation dorsal to anus of longitudinal smooth muscle coat of rectum	Fourth or fifth tail vertebra	Caudal rectal n.	Stabilizes anus during defecation	Smooth muscle

Urogenital diaphragm (p. 87)

Bulbospongiosus (87.12)	Continues the urethralis muscle and extends to the glans	Individual fibers extend between corpus cavernosum and a median raphe	Deep perineal n.	Empties spongy part of urethra	
Constrictor vestibuli (87.4)	Ventral border of levator ani	Meets muscle from other side ventral to vestibule	Deep perineal n.	Constricts vestibule	Muscle is deficient dorsally
Constrictor vulvae (87.6)	Striated fiber bundles under skin of vulva	Fiber bundles fuse dorsally with external anal sphincter	Deep perineal and caudal rectal nn.	Constricts vulvar cleft	Thought to be involved in the exposure of the clitoral glans (winking) during heat
Retractor penis (clitoridis) (87.13 resp. 87.5)	Ventral surface of second tail vertebra	Decussates below anal canal; ends in the male on corpus spongiosum, near the glans, in the female to the side of the clitoris	Deep perineal n.	Retracts penis; may elevate clitoris or be involved in the exposure of the clitoral glans (winking) during heat	Smooth muscle; has anal and penile (clitoral) parts; contributes to perineal body
Ischiocavernosus (87)	Ischial tuber and adjacent part of sacrosciatic lig.	Crus and adjacent part of body of penis	Deep perineal n.	Rhythmically compresses crus of penis during erection	In the female, rudimentary but with similar attachments

2. Lymphatic Structures

Lymph nodes	Position	Afferents from	Efferents to	Comments
Parotid lymphocenter				
Parotid l.nn. (39.5)	Deep to parotid gl.; ventral to temporomandibular joint	Skin and muscles of dorsal part of head; eye muscles, lids, lacrimal gl., ext. ear	Lateral and medial retropharyngeal nodes	6–10 nodes; some embedded in parotid gl.
Mandibular lymphocenter				
Mandibular l.nn. (39.16)	Intermandibular space where facial artery crosses ventral border of mandible	Skin of face; masticatory, pharyngeal, hyoid, and tongue muscles; salivary gl.	Cranial deep cervical nodes	Large elongated mass of up to 150 nodes; forms forwardlooking V with the nodes of the other side
Retropharyngeal lymphocenter				
Lateral retropharyngeal l.nn. (39.19)	Ventral to wing of atlas on lateral wall of guttural pouch	Similar to medial retropharyngeal l.nn.	Medial retropharyngeal nodes	8–15 up to 15 mm diameter nodes
Medial retropharyngeal l.nn. (39.20)	Dorsolateral on pharynx	Muscles and deep structures of head; large salivary gl.; pharynx, larynx, and thyroid gl.	Cranial deep cervical nodes	20–30 nodes up to 40 mm diameter
Supf. cervical lymphocenter				
Supf. cervical l.nn. (7.A, 59.7)	Cranial to shoulder joint; deep to cleidomastoideus and omotransversarius	Parts of neck and thoracic wall; forelimb	Caudal deep cervical nodes	Long chain of many small nodes along cranial border of subclavius
Deep cervical lymphocenter				
Cranial deep cervical l.nn. (59.12)	On trachea near thyroid gland	Larynx, esophagus, trachea, mandible, and ventral neck	Tracheal duct; middle deep cervical nodes	30–40 nodes; not easily distinguished from med. retropharyngeal nodes
Middle deep cervical l.nn. (59.18)	On trachea in mid neck	Trachea and esophagus; muscles ventral to trachea	Tracheal duct; caudal deep cervical nodes	Number and size of nodes vary greatly; may form a long chain or be absent
Caudal deep cervical l.nn. (59.23)	Cranial to first rib ventrolateral to trachea	Forelimb, neck, esophagus, and thymus	Cranial mediastinal nodes, or directly into adjacent veins	Near scalenus; not easily distinguished from cranial mediastinal nodes
Axillary lymphocenter				
Proper axillary l.nn. (7.B)	Caudomedial to shoulder joint; deep to teres major	Part of thoracic wall; muscles of shoulder and arm	Caudal deep cervical nodes	Caudal to where the axillary artery gives off the subscapular
Cubital l.nn. (7.C)	Proximomedial to elbow joint	Elbow joint; and muscles, tendons, and joints distal to that	Proper axillary nodes	5–20 nodes between biceps and medial head of triceps
Dorsal thoracic lymphocenter				
Thoracic aortic l.nn. (61.12)	Between aorta and the bodies of thoracic vertebrae 6–17	Shoulder girdle muscles and thoracic wall deep to them; mediastinum, pleura, and aorta	Cranial mediastinal nodes and thoracic duct	1–4 paired nodes at each vertebra
Intercostal l.nn. (61.11)	In intercostal spaces 3–16 near the heads of the ribs	Local epaxial muscles, vertebrae and muscles of the thoracic wall; pleura; diaphragm	Thoracic aortic nodes and thoracic duct	The sympathetic trunk lies between the intercostal and thoracic aortic nodes
Ventral thoracic lymphocenter				
Cranial sternal l.nn. (61.17)	On internal thoracic artery and manubrium sterni	Ribs, sternum, mediastinum, and pericardium	Cranial mediastinal nodes	
Caudal sternal l.n.	Inconstant; on sternum near diaphragm	Diaphragm, liver, pericardium	Cranial sternal or cranial mediastinal nodes	May lie in the caval fold (plica venae cavae)

Lymph nodes	Position	Afferents from	Efferents to	Comments
Mediastinal lymphocenter				
Cranial mediastinal l. nn. (61.15)	Precardial mediastinum; among the great vessels	Muscles of neck; trachea and esophagus; heart and mediastinum	Into veins at thoracic inlet via right lymphatic and thoracic ducts	Number and size vary greatly
Nuchal l.n.	In first intercostal space and along deep cervical vessels	Deep muscles of neck near thoracic inlet	Cranial mediastinal nodes	Inconstant node; on deep surface of longissimus cervicis
Middle mediastinal l. nn. (61.16)	Dorsal to heart, on right side of esophagus and trachea	Heart, aorta, esophagus, trachea	Cranial mediastinal and middle tracheobronchial nodes	Not easily distinguished from cranial and caudal mediastinal nodes
Caudal mediastinal l. nn. (61.13)	Caudal to aortic arch, along esophagus	Mediastinum, esophagus, and lungs	Middle and cranial mediastinal nodes	Up to 7 nodes; not easily distinguished from middle mediastinal nodes
Bronchial lymphocenter				
Tracheobronchial l. nn. —right (61.19) —middle (61.23) —left (61.20)	Surrounding tracheal bifurcation	Lung, trachea, mediastinum, esophagus, heart	Cranial mediastinal nodes	Three groups of up to 20 nodes each
Pulmonary l. nn.				
Lumbar lymphocenter				
Lumbar aortic l. nn. (79.3)	On aorta and caudal vena cava	Lumbar muscles; urogenital organs and kidneys	Lumbar trunks	30 to 160 nodes from kidneys to deep circumflex iliac vessels
Renal l.nn. (79.2)	Associated with the renal vessels	Kidney, ureter, and adrenal gland; also liver and duodenum	Lumbar aortic nodes	Not easily distinguished from lumbar aortic nodes
Ovarian l. n.	In prox. part of mesovarium	Ovary	Lumbar aortic nodes	Inconstant small node
Celiac lymphocenter				
Celiac l. nn. (71.A)	Surround celiac artery	Stomach, spleen, pancreas, liver; also lung and mediastinum	Cisterna chyli via celiac trunk	Some nodes lie on left gastric and splenic arteries
Splenic l. nn. (71.B)	On splenic vessels and in gastrosplenic ligament	Spleen and stomach	Celiac nodes	Number and size vary greatly
Gastric l. nn. (71.C)	On left gastric artery; also on cardia and lesser curvature of stomach	Esophagus, stomach, liver, omentum; also lung	Celiac nodes	Number and size vary greatly
Hepatic l. nn. (69.w)	Near the porta	Liver, pancreas, duodenum	Celiac nodes	Number and size vary greatly
Pancreaticoduodenal l. nn. (71.D)	Associated with right gastric and right gastroepiploic arteries	Duodenum, pancreas, stomach	Hepatic and celiac nodes	Number and size vary greatly
Omental l. nn.	In gr. omentum and gastrosplenic lig. near gr. curvature of stomach	Stomach and omentum; also spleen	Splenic and hepatic nodes	Number and size vary greatly
Cranial mesenteric lymphocenter				
Cranial mesenteric l. nn.	At the origin of the cranial mesenteric artery	Duodenum, pancreas, colon; also from jejunal, cecal, and colic nodes	Cisterna chyli via intestinal trunk	70–80 small nodes surrounding the cranial mesenteric artery
Jejunal l. nn. (71.E)	Associated with prox. ends of jejunal arteries	Jejunum and ileum	Cranial mesenteric nodes	Number and size vary greatly
Cecal l. nn (71.F)	Along dorsal, lateral, and medial bands of cecum	Cecum, ileum, and duodenum	Cranial mesenteric nodes	Long strands of hundreds of small nodes
Colic l. nn. (71.G)	In ascending mesocolon	Ascending and transverse colon; also ileum	Cranial mesenteric nodes	3000 to 6000 small nodes in thick strands between dorsal and ventral layers of ascending colon
Caudal mesenteric l. nn. (71. H)	Associated with the caudal mesenteric artery	Descending colon, rectum, peritoneum	Lumbar trunks	The nodes are grouped around bifurcation of caudal mesenteric artery
Vesical l. nn	In lateral ligaments of bladder	Bladder, prostate	Medial iliac nodes	1 or 2 inconstant nodes

UQL|XbVxUmAVqC+HnIZ42uaraA==|1288009554

Lymph nodes	Position	Afferents from	Efferents to	Comments
Iliosacral lymphocenter				
Medial iliac l. nn. (79.4)	At origin of deep circumflex iliac vessels	Muscles of pelvis and thigh; urogenital organs, peritoneum	Efferents form lumbar trunks	Up to 25 nodes; the largest can be 5.5 cm long; at breakup of aorta
Lateral iliac l. nn.	At bifurcation of deep circumflex iliac vessels	Abdominal muscles, diaphragm, peritoneum	Medial iliac and lumbar aortic nodes	Up to 20 small nodes
Sacral l. nn. (79.5)	Near angle formed by internal iliac arteries	Muscles of croup; accessory reproductive glands	Medial iliac nodes	On average 5–10 nodes; some may lie along internal pudendal artery
Anorectal l. nn.	Retroperitoneally dorsal to rectum; a caudal group lies dorsolateral to anus	Rectum, anus; tail muscles, vagina and vulva	Caudal mesenteric, sacral, ischial, and medial iliac nodes	A total of 15–35 nodes
Uterine l. n.	In broad ligament of uterus	Uterus	Medial iliac nodes	Inconstant small node
Obturator l. n.	Cranial border of obturator vessels	Hip joint; iliopsoas, quadriceps, and gluteal muscles	Sacral and medial iliac nodes	Inconstant
Deep inguinal lymphocenter				
Deep inguinal l. nn. (19.B)	On femoral vessels in femoral triangle	Entire hindlimb; some abdominal muscles	Medial iliac nodes	Elongated group consisting of up to 35 nodes
Supf. inguinal lymphocenter				
Supf. inguinal l. nn.	Between ventral abdominal wall and penis, or base of udder	Nearby abdominal wall; penis, and scrotum; udder and vulva	Deep inguinal nodes	Embedded in fatty connective tissue; usually palpable
Subiliac l. nn. (19.D; 65.10)	Cranial border of thigh halfway between coxal tuber and patella	Skin and subcutis of dorsal and lateral thoracic and abdominal walls and of thigh	Lateral and medial iliac nodes	Elongated package of small nodes; palpable
Coxal l. n.	On rectus femoris cranial to hip joint	Hip joint, quadriceps, tensor fasciae latae	Medial iliac nodes	Inconstant; only present in 25% of horses
Ischial lymphocenter				
Ischial l. nn.	Lateral surface of sacrosciatic ligament, on caudal gluteal vessels	Tail; muscles of thigh	Medial iliac nodes	Up to 5 nodes
Popliteal lymphocenter				
Popliteal l. nn. (19.A)	On caudal border of gastrocnemius, between biceps and semitendinosus	Bones, joints, and muscles distal to position of these nodes	Deep inguinal nodes	Small group of up to 12 nodes

Lymph trunks	Position	Start	End	Comments
Thoracic duct (61.1)	Dextrodorsal to thoracic aorta; farther cranially on left surface of trachea	Continues cisterna chyli	Veins at thoracic inlet	Enters thoracic cavity via aortic hiatus
Celiac trunk	On right side of celiac artery	Formed by efferents of celiac nodes	Empties into cisterna chyli	
Intestinal trunk	On right side of cranial mesenteric artery	Formed by efferents of cranial mesenteric nodes	Empties into cisterna chyli	
Right and left tracheal ducts	On each side of trachea	Formed by efferents of cranial deep cervical nodes	Caudal deep cervical nodes	
Right lymphatic duct	Cranial to right first rib	Formed by efferents of cranial mediastinal and sternal nodes	Veins at thoracic inlet	

3. Peripheral Nervous System

Nerve	Innervation	Comments
Spinal nerve (pp. 58/59 and 64/65) <ul style="list-style-type: none"> • Dorsal branch •• Lateral branch •• Medial branch • Ventral branch •• Lateral branch •• Medial branch 	<p>Generally skin dorsolateral to epaxial musculature</p> <p>Generally epaxial musculature</p> <p>Generally skin of lateral and ventral parts of trunk, and of limbs</p> <p>Generally hypaxial musculature and limb muscles</p>	<p>Leaves vertebral canal via intervertebral foramen, except C1, C2, sometimes mid-T, and S1–5</p> <p>Generally sensory except in cervical nn. where these br. are motor</p> <p>Generally motor except in cervical nn. where these br. are sensory</p> <p>Except nn. of brachial and sacral plexuses</p> <p>Except nn. of brachial and sacral plexuses</p>
I. Cervical nerves (C1–C8)		C1 and C2 leave vertebral canal through lateral vertebral foramina
Dorsal branches <ul style="list-style-type: none"> • Lateral branches • Medial branches 	<p>Dorsolateral neck muscles</p> <p>Skin on dorsal part of neck</p>	<p>(See Muscle Table beginning p. 98)</p> <p>That of C2 is known as major occipital n. for the skin of the poll</p>
Ventral branches <ul style="list-style-type: none"> • Lateral branches • Medial branches 	<p>Lateral and ventral skin of neck; cutaneous mm. of head and neck; omotransversarius, rhomboideus, and cervical part of serratus ventralis</p> <p>Sternothyroideus, sternohyoideus, hypaxial mm. associated with cervical vertebrae</p>	<p>That of C2, known as transverse n. of neck, goes to cutaneous mm. of head and neck; and another br. of C2, known as great auricular n., goes to the ear; br. of C6, known as supraclavicular nn., supply the skin over the shoulder joint and descending pectoral m.</p> <p>Brr. of C2–5 form cervical plexus; C5, 6, and 7 form phrenic n. that passes through thoracic inlet to diaphragm; C6, 7, and 8 contribute to brachial plexus (see further on)</p>
II. Thoracic nerves (T1–T18)		
Dorsal branches <ul style="list-style-type: none"> • Lateral branches • Medial branches 	<p>Skin over dorsolateral part of back and thorax</p> <p>Local epaxial mm.</p>	<p>Known as dorsal cutaneous nn.</p> <p>(See Muscle Table beginning p. 99)</p>
Ventral branches <ul style="list-style-type: none"> • Lateral branches •• Lateral cutaneous branches 	<p>Intercostal mm.</p> <p>Muscles and skin on lateral thoracic wall</p>	<p>Known as intercostal nn.</p> <p>Those of T3 and 4 combine with lateral thoracic n. to form intercostobrachial n. (7.1) which innervates the cutaneus omobrachialis muscle and associated skin</p>
Medial branches	Muscles and skin on ventral thoracic wall	In region of sternal ribs, innervate intercostal mm. and transversus thoracis; in region of asternal ribs, innervate ext. and int. abdominal obliques, and rectus and transversus abdominis mm.; that of T18 is known as costoabdominal n. for psoas and quadratus lumborum mm.
• Ventral cutaneous branches	Skin on ventral and lateral thoracic and abdominal wall to udder and prepuce	
III. Lumbar nerves (L1–L6)		
Dorsal branches <ul style="list-style-type: none"> • Lateral branches •• Medial and lateral cutaneous branches 	<p>Skin of lumbar region and cranial part of croup</p>	Known as cranial clunial nn., over the gluteal region
• Medial branches	Epaxial lumbar mm.	
Ventral branches		Form roots of lumbar plexus (see further on)
• Lateral branches	Skin and muscles of lateral and ventral abdominal wall, and of hindlimb	
• Medial branches	Skin and muscles of lateral and ventral abdominal wall, and of hindlimb	
IV. Sacral nerves (S1–S5)		
Dorsal branches <ul style="list-style-type: none"> • Lateral branches • Medial branches 	<p>Skin of croup and thigh</p> <p>Caudal segments of multifidus and dorsal tail muscle</p>	Known as middle clunial nn.

Nerve	Innervation	Comments
Ventral branches • Lateral branches • Medial branches	Muscles of hindlimb	Leave vertebral canal through ventral sacral foramina Form roots of sacral plexus (see further on)
V. Caudal (coccygeal) nerves (Cd1–Cd5)		Form cauda equina
Dorsal branches	Dorsal sacrocaudal mm. and intertransversarii; skin on dorsal surface of tail	Form dorsal sacral plexus
Ventral branches	Ventral sacrocaudal mm. and intertransversarii; skin on ventral surface of tail	Form ventral sacral plexus

Brachial plexus (pp. 6/7; 8/9; 10/11)

Network of ventral branches of spinal nerves C6, 7, and 8, and T1 and 2, which form the roots of the plexus that perforate the scalenus muscle to approach the forelimb craniomedial to the shoulder joint.

Suprascapular nerve (7.9)	Supra- and infraspinatus	From C6 and 7; crosses cranial border pf scapula
Subscapular nerve (7.3)	Subscapularis	Chiefly from C6 and 7
Axillary nerve (7.14)		Chiefly from C7 and 8; most of the nerve passes between subscapularis and teres major to lateral surface of limb
• Muscular branches	Caudal part of subscapularis, teres major and minor, deltoideus, and articularis humeri	
• Craniolateral cutaneous branch of arm	Skin lateral to prox. part of humerus	
• Cranial cutaneous antebrachial nerve (7.26; 9.24)	Skin on cranial surface of forearm	
Musculocutaneous nerve (7.7)		Chiefly from C7, but also from C6 and C8; forms ansa axillaris with median n.
• Proximal muscular branch (7.a)	Coracobrachialis and biceps	Crosses lateral surface of coracobrachialis to reach biceps
• Distal muscular branch (7.b)	Brachialis	
• Medial cutaneous antebrachial nerve (7.30; 9.29)	Skin on medial surface of forearm, carpus, and into metacarpus	
Radial nerve (7.11)		From C7, 8, and T1; passes between teres major and long head of triceps to lateral surface of limb, then crosses lateral supracondylar crest (see also Radial Paralysis)
• Muscular branches	Triceps, tensor fasciae antebrachii, anconeus	
• Caudolateral cutaneous branch of arm	Skin lateral to distal part of humerus	
• Deep branch (7.18)		
•• Muscular branches	Extensor(s) carpi radialis, carpi ulnaris, digitalis communis, digitalis lateralis, carpi obliquus	
• Superficial branch (7.27)		
•• Lateral cutaneous antebrachial nerve (7.29; 9.27)	Skin on lateral surface of forearm	Does not proceed to metacarpus and digit as in other domestic mammals
Median nerve (7.8; 9.11)		Chiefly from C8 and T1, contributions also from C7 and T2; accompanies brachial a.; in forearm accompanies median a. between deep digital flexor and flexor carpi radialis
• Muscular branches	Flexor carpi radialis, humeral and radial heads of deep digital flexor	
• Medial palmar nerve (7.37)		Passes carpus in carpal canal accompanying supf. and deep flexor tendons, continues to fetlock joint on medial aspect of these tendons
N. digitalis palmaris communis II (9.16)		
••• Communicating branch	In metacarpus connects to lateral palmar n. which descends on lateral aspect of flexor tendons	
••• Medial (palmar) digital nerve	Hoof dermis, hoof cartilage, coffin joint, navicular bone and bursa	Continues medial palmar n. into digit; runs palmar to medial digital a.; crosses deep surface of ligament of ergot
•••• Dorsal branch (11.9)	Skin on dorsomedial surface of fetlock and digit, dorsal part of pastern joint, coronary dermis	May be double
•••• Branch to digital cushion (11.10)	Digital cushion	
• Lateral palmar nerve (7.39; 9.15)		Above carpus receives palmar br. of ulnar n., passes carpus in substance of flexor retinaculum, then lies on lateral aspect of flexor tendons where it receives communicating br. from medial palmar n.
N. digitalis palmaris communis III (9.15)		
•••• Deep branch	Interosseus	
•••• Lateral and medial palmar metacarpal nerves (7.n, m)	Fetlock joint; skin on dorsolateral and dorso-medial aspect of digit	Deeply embedded on axial surface of splint bones, then subcutaneous across fetlock joint

UQLXbVxUmAVqC+HnIZ42uaraA==|288009611

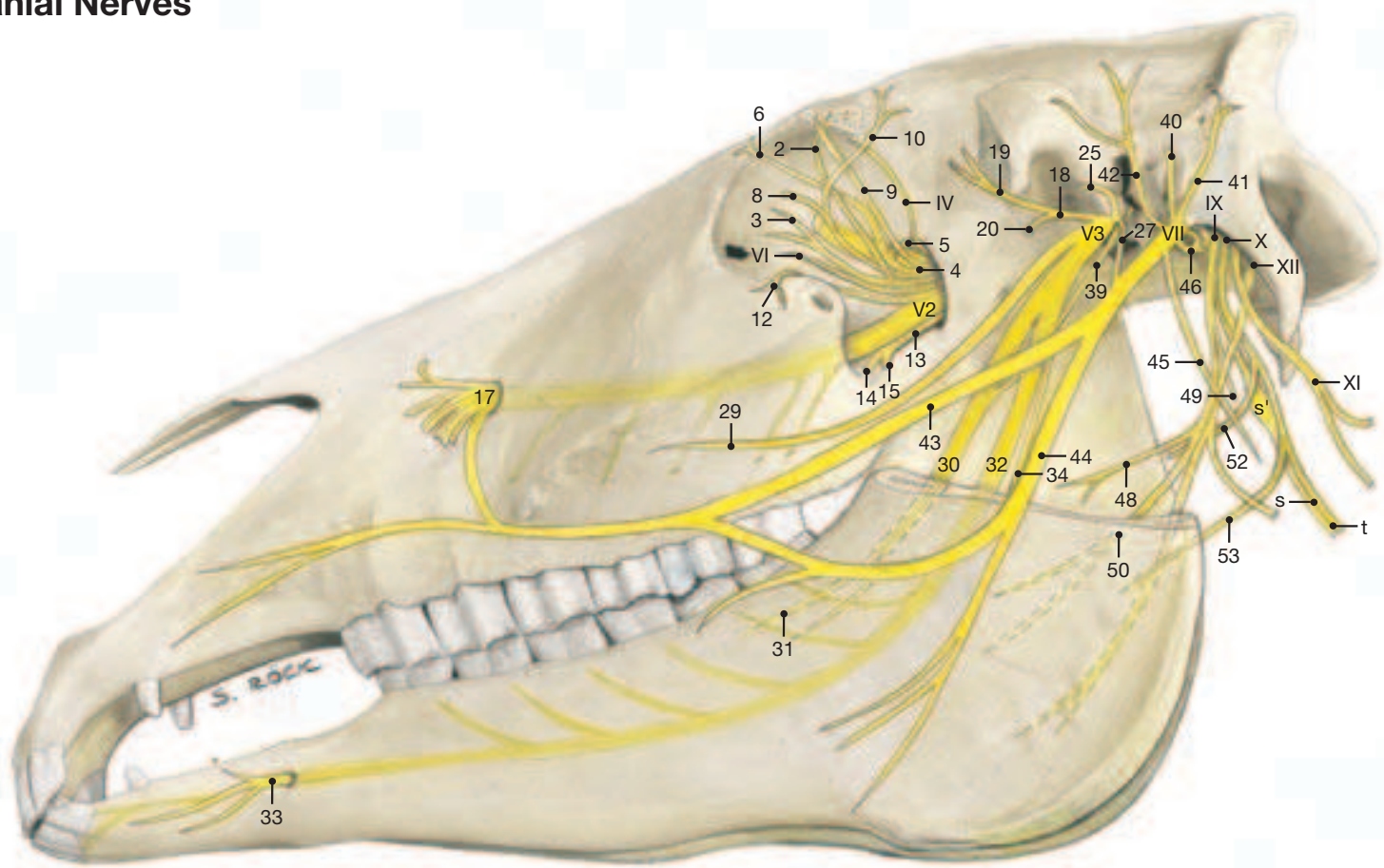
Nerve	Innervation	Comments
••• Lateral (palmar) digital nerve (9.17) •••• Dorsal branch •••• Branch to digital cushion	Same as medial digital n. (see above)	Continues lateral palmar n. into digit May be double
Ulnar nerve (7.12)		Chiefly from C8 and T1, occasionally T2; lies caudal to brachial vessels and crosses the caudal (extensor) aspect of elbow joint
• Caudal cutaneous antebrachial nerve (7.23) • Muscular branches • Dorsal branch (7.43; 9.14) • Palmar branch (7.40; 11.d)	Skin on caudal aspect of forearm Flexor(s) carpi ulnaris, digitalis supf., digitalis profundus (ulnar head) Dorsolateral skin of carpus and metacarpus	Emerges just prox. to accessory carpal bone and turns dorsodistally Joins lateral palmar n. at the carpus (see above)
Cranial and caudal pectoral nerves (9.e; 9.c) Long thoracic nerve (59.r) Lateral thoracic nerve (59.s)	Pectoral muscles and subclavius Thoracic part of serratus ventralis Cutaneus trunci and ventral skin on thorax and abdomen	Chiefly from C7 and C8 Chiefly from C8 and T1 (see also intercostobrachial n., 59.g)
Thoracodorsal nerve (7.2)	Latissimus dorsi	Chiefly from C8
Lumbosacral plexus		
LUMBAR PLEXUS (pp. 18/19; 20/21; 76/77; 80/81)		Ventral branches of L2–6 form the roots of the lumbar plexus
Ventral branch of L1 (iliohypogastric n.) (21.2)		No communication with neighboring ventral brr., therefore not part of lumbar plexus
• Lateral branch • Medial branch	Abdominal mm. except rectus; skin of flank Caudal parts of abd. mm.; skin on ventral abd. wall; udder and prepuce	Penetrates oblique abd. mm. and continues as lateral cutaneous br. Passes subperitoneally to vicinity of deep inguinal ring From L2 and L3
Ventral branch of L2 (ilioinguinal n.) (21.3; 75.2; 77.18) • Lateral branch • Medial branch	Abdominal mm. except rectus; skin of flank Caudal parts of abd. mm.; peritoneum in vicinity of inguinal canal	Penetrates oblique abd. mm. and continues as lateral cutaneous br. Crosses bifurcation of deep circumflex iliac vessels, passes through inguinal canal
Genitofemoral nerve (21.5; 73.11; 75.3; 77.20) • Genital branch • Femoral branch	Internal abdominal oblique m. and cremaster; vaginal tunic; skin of prepuce, scrotum, and udder Medial skin of thigh	From L2–L4; crosses deep circumflex iliac vessels; passes through inguinal canal Passes through vascular lacuna
Lateral cutaneous femoral nerve (21.6; 77.10; 65.11)	Psoas major; skin on cranial part of thigh and stifle	From L3 and L4
Femoral nerve (19.12) • Muscular branches • Saphenous nerve (19.25; 73.9)	Sartorius, quadriceps, pectineus, and part of adductor Sensory brr. to stifle joint; skin on medial surface of thigh, leg, and metatarsus	From L3 to L6; passes between psoas minor and iliopsoas to muscular lacuna where it detaches saphenous n. Accompanies femoral vessels until it becomes subcutaneous
Obturator nerve (19.5)	Ext. obturator, pectineus, gracilis, and adductor	From L4 to L6, also S1; passes through obturator foramen

Nerve	Innervation	Comments
Sacral plexus (pp 18/19; 20/21; 80/81)		Roots from S1 to S5
Cranial gluteal nerve (19.8)	Gluteal mm. and tensor fasciae latae	From L6 to S2; emerges from greater sciatic foramen
Caudal gluteal nerve (19.2)	Vertebral heads of biceps, semitendinosus, and semimembranosus; also supf. gluteal m.	From L6 to S2; emerges from greater sciatic foramen
Caudal cutaneous femoral nerve (21.17)	Skin on caudal part of thigh	From S1 and S2; lies on lateral surface of sacrosciatic ligament
Caudal clunial nerves	Skin on caudal part of thigh	
Ischiatic nerve (19.4)		From L5 to S2; through greater sciatic foramen to lie on lateral surface of sacrosciatic lig., then turns ventrally caudal to hip joint
• Muscular branches	Small muscles in vicinity of hip joint; semimembranosus and pelvic heads of biceps and semitendinosus	(see Table p. 90)
• Common peroneal nerve (19.17)		
• Lateral cutaneous sural nerve (19.24)	Skin lateral and distal to stifle joint Perforates distal part of biceps	Crosses lateral surface of gastrocnemius and is under the skin at the stifle joint where it divides into supf. and deep peroneal nn.
• Superficial peroneal nerve (19.39)		Arises opposite stifle joint space and passes distally between lateral and long digital extensor muscles
•• Muscular branches	Lateral digital extensor	
•• Dorsal and lateral cutaneous branches	Skin dorsolateral to hock joint, metatarsus, and digit	
• Deep peroneal nerve (19.32)		Passes deeply between lateral and long dig. extensors, then distally on tibialis cranialis to dorsal surface of hock joint and under extensor retinacula to dorsal surface of metatarsus and digit
•• Muscular branches	Tibialis cranialis, lateral and long dig. extensors, extensor brevis, peroneus tertius	
•• Medial dorsal metatarsal nerve (23.8)	Skin on dorsomedial aspect of digit	Descends on medial surface of large metatarsal bone
•• Lateral dorsal metatarsal nerve (23.9)	Skin on dorsolateral aspect of digit	Descends dorsal to lateral splint bone
• Tibial nerve (19.13)		Descends between the two heads of gastrocnemius and divides prox. to hock joint into med. and lat. plantar nn.
•• Caudal cutaneous sural nerve (19.30; 23.6)	Skin on caudal aspect of leg	Accompanies lateral saphenous v.; passes distally on common calcanean tendon across lateral surface of hock to fetlock joint
•• Muscular branches	Popliteus, extensors of hock and flexors of digit	
•• Medial plantar nerve (19.38; 21.26)		Crosses plantar aspect of hock and in metatarsus lies on medial aspect of flexor tendons
••• N. digitalis plantaris communis II (21.27; 23.10)		
•••• Communicating branch (23.12)	In metatarsus connects to lateral plantar n. on lateral aspect of flexor tendons	
•••• Medial (plantar) digital nerve (23.15)	The plantar digital nerves have a similar distribution as the palmar digital nerves (see above)	
• Lateral plantar nerve (19.35; 21.26)		
Deep branch	Interosseus	
••• Lateral and medial plantar metatarsal nerves (23.13; 23.14)		Deeply embedded on axial surface of splint bones; then subcutaneous, but only the medial nerve reaches the hoof dermis
•• Lateral (plantar) digital nerve (23.16)		The plantar digital nerves have a similar distribution as the palmar digital nerves (see above)
Pudendal nerve (19.f)	Rectum, reproductive organs	From S2 to S4; crosses ischial arch with int. pudendal a.
• Superficial perineal nerves	Skin of perineal region, cranially to scrotum and udder	
• Deep perineal nerve	Ischiocavernosus, bulbocavernosus, urethralis, retractor penis (clitoridis)	
• Dorsal nerve of penis (clitoris)	Penis (clitoris)	
Caudal rectal nerve (19.c)		From S4 and S5
• Muscular branches	Anal sphincters, coccygeus, levator ani	
• Cutaneous branches	Skin around anus	

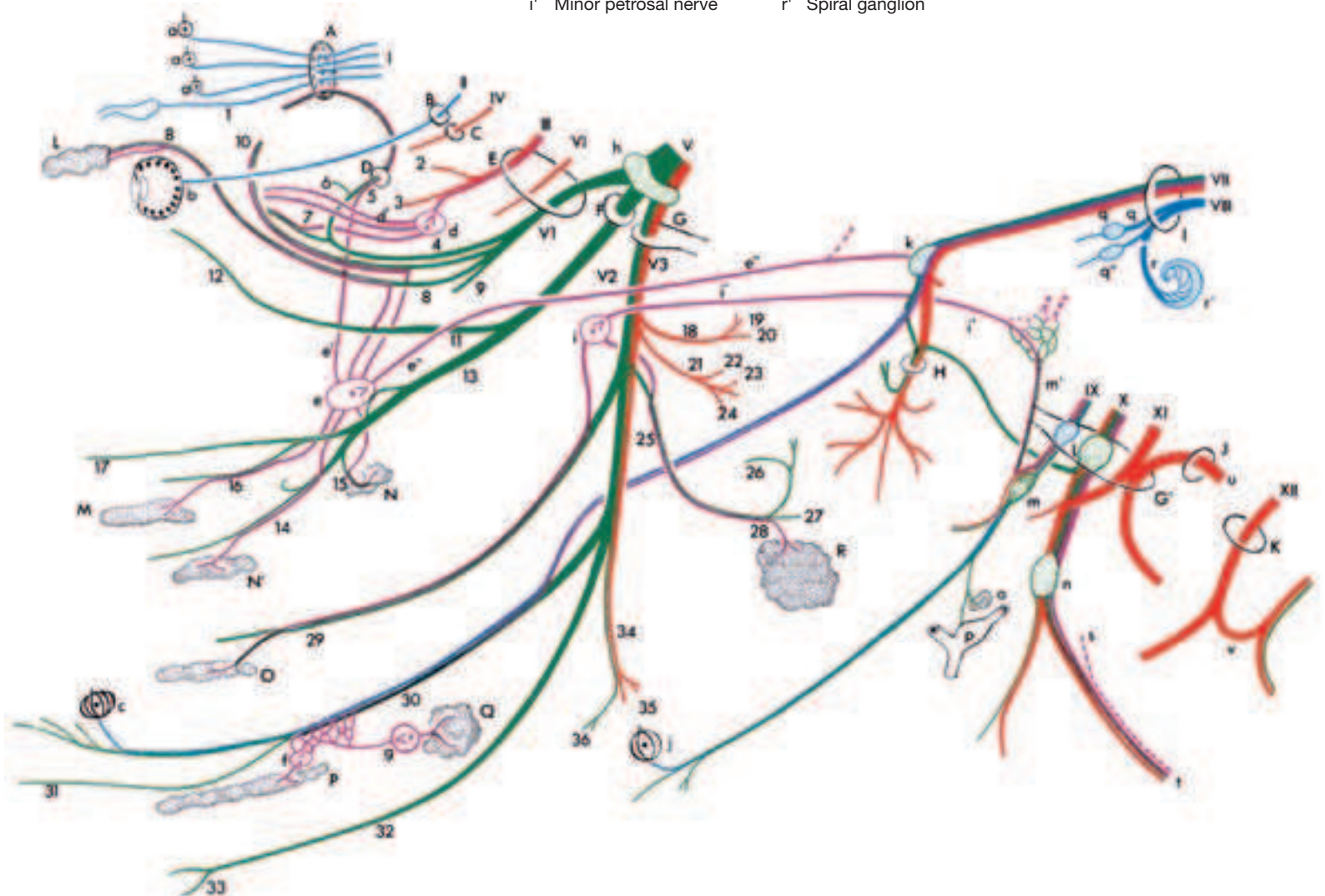
4. Cranial Nerves

Nerv	Fig.	Name (fiber type)	Innervation	Comments
I		Olfactory n. (special sense: olfaction)	Olfactory region in nasal cavity	Origin: olfactory bulb; leaves skull by cribriform plate
	(1)	Vomeranasal n. (special sense: olfaction)	Vomeranasal organ	
II		Optic n. (special sense: sight)	Optic part of retina	Developmentally an evagination of the diencephalon; leaves skull by optic foramen
III	41.17	Oculomotor n. (s, m, psy)		Origin: mesencephalon; leaves skull by orbital fissure
	(2)	Dorsal branch (m)	Dorsal rectus, levator palp. sup., retractor bulbi muscles	
	(3)	Ventral branch (m, psy)	Medial and ventral recti, ventral oblique muscles	
IV	41.11	Trochlear n. (m)	Dorsal oblique muscle	Origin: mesencephalon; leaves skull by trochlear foramen
V		Trigeminal n.		Origin: rhombencephalon; nerve of 1st pharyngeal arch
VI		Ophthalmic n. (s)	Skin surrounding eyes, ethmoid bone, lacrimal gl., upper eyelid	Leaves skull by orbital fissure
	(4) 41.21	Nasociliary n. (s)		Detaches a br. to frontal sinus
	(5) 41.20	Ethmoidal n. (s)	Olfactory area of nasal cavity	Leaves orbit by trochlear notch; brr. to frontal sinus
	(6) 41.19	Infratrochlear n. (s)	Conjunctiva, 3rd eyelid, lacrimal caruncle and skin near medial angle of eye	Receive psy.* fibers from ciliary gangl.
	(7) 41.22	Long ciliary nn. (s, psy)	Iris, cornea, ciliary m.	Usually double; receives psy. fibers from pterygopalatine gangl. and sy. fibers from int. carotid plexus
	(8) 41.12	Lacrimal n. (s, psy, sy)	Lacrimal gl., skin and conjunctiva near lat. angle of eye	Perforates periorbita and leaves orbit through supraorb. for. where it becomes supraorbital n. (41.8)
	(9) 41.9	Frontal n. (s)	Skin of forehead and upper eyelid; br. to frontal sinus	Receives psy. fibers from pterygopalatine gangl.
	(10) 41.10	Zygomaticotemporal br. (s, psy)	Skin of temporal region, lacrimal gl.	Leaves skull by round foramen
V2	39.27	Maxillary n. (s)		
	(11) 41.27	Zygomatic n.		Leave orbit near lat. angle of eye
	(12) 41.16	Zygomaticofacial br. (s)	Lower eyelid, tarsal gl.	Receives psy. fibers from pterygopalatine gangl.
	(13)	Pterygopalatine n. (s, psy)		Passes through gr. palatine canal
	(14) 41.d	Greater palatine n. (s, psy)	Mucosa and gll. of hard palate	
	(15) 41.e	Lesser palatine n. (s, psy)	Mucosa and gll. of soft palate	
	(16) 41.c	Caudal nasal n. (s)	Mucosa of nasal cavity and gums	Passes through sphenopalatine for.
	(17) 39.27' 41.b	Infraorbital n. (s)	Skin of nose, nostrils and upper lip; also via alveolar brr. upper teeth and maxillary sinuses	Leaves skull by infraorbital for.
V3	39.23	Mandibular n. (s, m)		Leaves skull by oval notch of for. lacerum
	(18)	Masticatory n. (m)		
	(19)	Deep temporal nn. (m)	Temporalis muscle	
	(20) 39.7	Masseteric n. (m)	Masseter muscle	Passes laterally through mandibular notch
	(21)	Medial pterygoid n. (m)	Med. pterygoid muscle	At its origin lies the small otic gangl.
	(22)	Tensor tympani n. (m)	Tensor tympani muscle	
	(23)	Tensor veli palatini n. (m)	Tensor veli palatini	
	(24)	Lateral pterygoid n. (m)	Lat. pterygoid muscle	
	(25) 39.21	Auriculotemporal n. (s, sy, psy)		Receives psy. fibers from otic gangl
	(26) 37.26	Transverse facial br. (s)	Skin of masseteric region and over temporomandibular joint	Detaches brr. to temporomandibular joint
	(27)	Communicating br. (s)	Carries sensory fibers to dorsal and ventral buccal brr. of facial n (VII)	The sensory fibers are thus distributed to the side of the face
	(28)	Parotid brr. (s, psy)	Parotid gl.	Bring psy. fibers to the parotid gl.
	(29)	Buccal n. (s, psy)	Buccal gll. and mucosa of buccal part of oral cavity	Receives psy. fibers from otic gangl.
	(30) 39.13	Lingual n. (s, psy, and gustatory)	Mucosa of apex and body of tongue	Receives psy. and gustatory fibers via chorda tympani (VII)
	(31)	Sublingual n. (s)	Mucosa of prefrenular part of oral cavity	
	(32) 39.25	Inferior alveolar n. (s)	Lower teeth and gums	Enters mandible by mandibular for.
	(33) 37.i	Mental n. (s)	Skin of lower lip and chin	Leaves mandible by mental for.
	(34) 39.15	Mylohyoid n. (m)	Mylohyoides muscle	
	(35)	Rostral digastric br. (m)	Rostral belly of digastricus	
	(36)	Submental brr. (s)	Skin of rostral part of intermandibular space	

Cranial Nerves



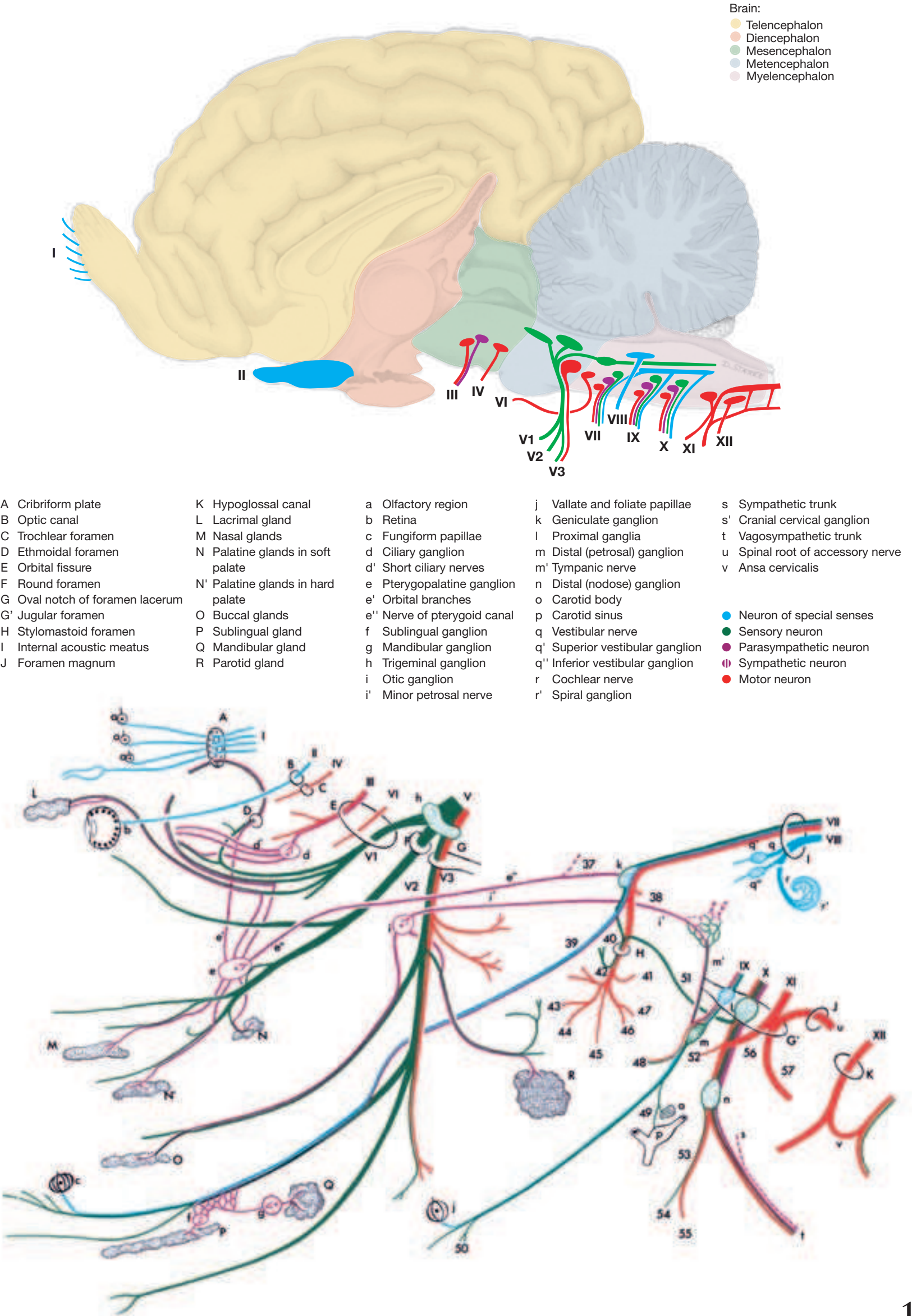
- | | | | | |
|---------------------------------|-----------------------------------|------------------------------|----------------------------------|----------------------------------|
| A Cribriform plate | K Hypoglossal canal | a Olfactory region | j Vallate and foliate papillae | s Sympathetic trunk |
| B Optic canal | L Lacrimal gland | b Retina | k Geniculate ganglion | s' Cranial cervical ganglion |
| C Trochlear foramen | M Nasal glands | c Fungiform papillae | l Proximal ganglia | t Vagosympathetic trunk |
| D Ethmoidal foramen | N Palatine glands in soft palate | d Ciliary ganglion | m Distal (petrosal) ganglion | u Spinal root of accessory nerve |
| E Orbital fissure | N' Palatine glands in hard palate | d' Short ciliary nerves | m' Tympanic nerve | v Ansa cervicalis |
| F Round foramen | O Buccal glands | e Pterygopalatine ganglion | n Distal (nodose) ganglion | |
| G Oval notch of foramen lacerum | P Sublingual gland | e' Orbital branches | o Carotid body | |
| G' Jugular foramen | Q Mandibular gland | e'' Nerve of pterygoid canal | p Carotid sinus | |
| H Stylomastoid foramen | R Parotid gland | f Sublingual ganglion | q Vestibular nerve | |
| I Internal acoustic meatus | | g Mandibular ganglion | q' Superior vestibular ganglion | |
| J Foramen magnum | | h Trigeminal ganglion | q'' Inferior vestibular ganglion | |
| | | i Otic ganglion | r Cochlear nerve | |
| | | i' Minor petrosal nerve | r' Spiral ganglion | |



Cranial Nerves

Nerv	Fig.	Name (fiber type)	Innervation	Comments
VI	41.28	Abducent n. (m)	Lateral rectus, lateral portion of retractor bulbi	Origin: rhombencephalon; leaves skull by orbital fissure
VII	37.18	Facial n. (m, s, psy, gustatory)		Origin: medulla oblongata; has facial and intermediate components; enters int. acoustic meatus, bears geniculate gangl. in facial canal; leaves skull by stylomastoid for.; n. of 2nd pharyngeal arch
	(37)	Greater petrosal n. (psy)	Gll. of nasal cavity and palate	Runs in petrosal canal; joins deep petrosal n. (sy.) to form n. of petrosal canal which goes to pterygopalatine gangl.
	(38)	Stapedial n. (m)	Stapedius muscle	
	(39)	Chorda tympani (gustatory, psy)	Salivary gll.	Leaves petrous temporal bone by petrotympanic fissure and joins lingual n. (V3)
	(40) 37.27	Internal auricular br. (s)	Skin on int. surface of external ear	Is joined by auricular br. of vagus
	(41) 37.30	Caudal auricular n. (m)	Muscles of external ear	Is joined by dorsal br. of first two cervical nn.
	(42)	Auriculopalpebral n. (m)	Orbicularis oculi, interscutularis, zygomaticus, levator nasolabialis, mm. of external ear	Joins br. of auriculotemporal n. (V3)
	(43) 37.12	Dorsal buccal br. (m)	Muscles of upper lip and nose	Receives communic. br. from auriculotemporal n. (V3); n. injured in facial paralysis
	(44) 37.13	Ventral buccal br. (m)	Muscles of cheek and lower lip	
	(45)	Cervical br. (m)	Parotidoauricularis, cut. mm. of head and neck	Unites with ventral br. of cervical nn.
	(46)	Digastric br. (m)	Caudal belly of digastricus	
	(47)	Stylohyoideus br. (m)	Stylohyoideus	
VIII		Vestibulocochlear n. (special sense: balance and hearing)	Macula of utricle and saccule, ampullary crests, spiral gangl. of cochlea	Origin: rhombencephalon; into petrous temporal bone through int. acoustic meatus
IX	47.28 51.3	Glossopharyngeal n. (m, s, psy, gustatory)		Origin: medulla oblongata; leaves skull by jugular for.; n. of 3rd pharyngeal arch; lies in a fold of guttural pouch
	(48) 51.4	Pharyngeal br. (s, m)	Pharyngeal mucosa, stylopharyngeus	Takes part in forming pharyngeal plexus
	(49) 51.c	Carotid sinus br. (s)	Baroreceptors in wall of carotid sinus, chemoreceptors in carotid body	
	(50) 51.5	Lingual br. (s, gustatory)	Mucosa of root of tongue and pharynx	Communicates with lingual n. (V3)
X	47.26	Vagus (s, m, psy)		Origin: medulla oblongata; leaves skull by jugular for.; n. of 4th pharyngeal arch; in a fold of guttural pouch
	(51)	Auricular br. (s)	Skin of external acoustic meatus	Communicates with int. auricular br. (VII)
	(52) 51.d	Pharyngeal br. (s, m)	Pharyngeal mm. except stylopharyngeus; mucosa of pharynx and larynx	Takes part in forming pharyngeal plexus
	(53)	Cranial laryngeal n. (s, m)		Arises from distal gangl.
	(54) 49.a	• Internal br. (s)	Laryngeal mucosa rostral to glottis	Passes into larynx through thyroid for.
	(55) 49.b	• External br. (m)	Cricothyroideus	
		Cardiac br. (psy)	Heart	
		Recurrent (caudal) laryngeal n. (m, s, psy)	Br. to trachea and esophagus; laryngeal mm. except cricothyroideus; laryngeal mucosa caudal to glottis	Leaves vagus in thorax; passes up the neck; thought to be involved in "roaring"
XI	47.23 51.15	Accessory n. (m)		Origin of cranial root: medulla oblongata, spinal root: cervical spinal cord; leaves skull by jugular for.; lies against guttural pouch
		• Cranial root		
		• Spinal root		
	(56)	Internal br. (m)	Connects with vagus	
	(57)	External br. (m)		
	51.r	• Dorsal br. (m)	Trapezius	
	51.q	• Ventral br. (m)	Sternocephalicus	
XII	47.29 51.14	Hypoglossal n. (m)	Intrinsic tongue musculature; genio-, stylo-, and hyoglossi	Origin: medulla oblongata; leaves skull by hypoglossal canal; forms ansa cervicalis with ventral br. of C

Cranial Nerves



Contributions to Clinical-Functional Anatomy

Arthroscopy and Endoscopy in Veterinary

Medicine

ASTRID B. M. RIJKENHUIZEN

General Remarks. Veterinary medicine today without arthroscopy (Gr. *arthros* = joint; *scopein* = to examine) in the treatment of joint diseases is something that cannot be imagined. This so-called key-hole surgery, or also minimally invasive surgery, is realized by application of the arthroscope, an optical system of lenses. It is one of the greatest advances of the last decade in the recognition and treatment of joint diseases and has almost completely replaced the conventional surgery of joints. In contrast to conventional surgery with a wide access, this minimally invasive procedure has several advantages. These are less stress for the horse, better demonstration of the anatomical structures of the joint, the minimizing of soft tissue trauma, shorter operation times for many manipulations, less post-operative pain, extension of therapeutic possibilities, shorter healing time, a better cosmetic result, and a quicker recovery of efficiency. A substantial advantage of this technically high quality method is improved diagnostics should the clinical and radiographic as well as the sonographic examination fail to clarify the problem. **Endoscopy** also serves for diagnostic examination and minimally invasive manipulations at the internal surfaces of the body cavities and hollow organs, for example the gastrointestinal tract. The procedure is similar to arthroscopy with application of similar methods and instruments.

Instruments and Objectives of Arthroscopy. Arthroscopy is utilized predominantly for endoscopic examination of joints but also for other synovial structures such as synovial sheaths (tendovaginoscopy) and synovial bursae (bursoscopy). In doing this, the arthroscope is introduced through a small incision of the skin and soft tissues into joint cavities or synovial sheaths or bursae. The visual impression is transmitted by a camera to a monitor to facilitate orientation to the surgeon. In this way the internal structures of the joint, synovial sheath or bursa can be directly observed. The surgeon sees these internal structures only by way of the monitor. Installation of the monitor is at shoulder-level of the surgeon and faces the surgeon. Additional mechanical or surgical instruments can be introduced to permit minimally invasive treatments; for example, the removal of bone or bone-fragments.

What Possibilities of Evaluation are Provided by Arthroscopy? Cartilage, bone, the joint capsule with synovial and fibrous layers, menisci, collateral ligaments, cruciate ligaments, and tendons associated with the joints as, for example, the long digital extensor, will be assessed.

- Degenerative changes (among other things, frayed ligaments, formation of fissures, traces of where the bones have rubbed against and damaged one another, partial losses of bone, rarefaction or thickening or detachment of cartilage, arthrotic alterations such as marginal swellings, cysts of articular cartilage).
- Inflammatory changes of the joint capsule (among other things, number, size and shape of synovial villi), hyperemic changes, adhesions as well as partial or complete rupture).
- Traumatic changes (fragments, etc.).



Fig. 1. Arthroscopy of the tarsal tendon sheath. (Courtesy of Prof. Dr. Rijkenhuizen)

Possible Applications of Arthroscopy

a. Diagnosis: When clinical or diagnostic imaging examination does not result in a certain diagnosis, direct arthroscopic visualization of the intraarticular structures may deliver additional information. Also a possibility exists to obtain biopsy material of altered structures directly viewed.

b. Instituting therapy at the same time that the diagnosis is made.

- Removal of osseous or cartilaginous free bodies (*corpora libera*) that are occurring freely in synovia;
- In joint inflammation, synovectomy for bacterial examination and culture (partial removal of the altered *stratum synoviale*);
- Tapping of synovia for bacterial examination;
- Arthroscopic procedures of osteosynthesis; for example, fractures of the third carpal bone (*os carpale III*);
- Synovectomy (partial removal of the ulcerated synovial membrane) in cases of arthritis;
- Removal of osteochondromas (tumors of osseous and cartilaginous tissue);
- Smoothing and suturing of fissures in tendons or menisci;
- Flushing of the joint cavity to remove articular detritus and infectious material, for example, during treatment of articular hemorrhage and septic arthritis; this can be done with visual monitoring of the procedure:
- Removal of cysts and necrotic tissue;
- Smoothing of marginal excrescences of joints;
- Reconstruction of cruciate ligament in case of rupture.

Arthroscopy is most suited for treatment of osteochondrosis dissecans.

Which joints and synovial structures are treated arthroscopically?

Almost every joint is suitable for arthroscopy. Nowadays, it is applied in the examination and treatment of the hock joint, fetlock joint, femoropatellar joint, femorotibial joint, radiocarpal and intercarpal joints. But also the coffin joint, pastern joint, hip joint, shoulder, elbow, and temporomandibular joints have possible application. For tendovaginoscopy in the horse, the flexor aspect of the fetlock region, carpal region, and the tendon sheaths of the flexor aspect of the hock joint are suitable. For bursoscopy, the navicular bursa, intertubercular bursa and the subtendinous and calcaneal bursae and also acquired (subcutaneous) bursae can be examined. Virtually any structure that is filled with synovial fluid can be examined endoscopically.

What instruments will be used?

The main instrument that is used is a rigid arthroscope (4 mm diameter) with a viewing angle of 0° to 30° or 45° or 70°. It contains optical device that is connected by a light-conducting cable to a cold light source (150–300 watt). Smaller optical instruments with a diameter of 2.7 mm can be used for smaller joints, for example, the coffin joint. Usually longer optical instruments are employed for the femoropatellar joint in order to assess the articular surfaces distal to the patella. The angle of view can be altered simply by turning the optical device without moving the entire instrument. In this way, the operator is able to hold the optical device away from other instruments and is thus able to protect it from damage during manipulation. The optical device is connected to a video camera that is connected to a monitor and digital image processor for recording.



Fig. 2. Tendon and tendon sheath, opened wedge-like. The inner lining of the tendon sheath (*peritendineum*) is formed as a double-layered *mesotendineum* that surrounds the tendon as an *epitendineum*. The connective tissue that conducts the vessels can, as a *vinculum tendineum*, pass from the tendon to the underlying bone. (Courtesy of Institut f. Veterinär-Anatomie, Berlin)

A pump is used to expand the joint cavity with fluid or gas. This maintains a constant pressure in the joint during manipulations. This expansion is necessary to provide space within the joint for a far reaching inspection and surgical manipulations. Trocars are used to introduce the instrument, which is pushed through the trocar. The passage within the trocar is sealed by valves. In this way, neither gas nor fluid escapes from the joint during the changing of instruments. The passage of the optical instrument through the different compartments of the joint space is essential for examination of the joint. The operator is able to evaluate the individual structures one after the other. As mentioned, arthroscopy is used not only for diagnosis but at the same time for minimally invasive manipulations. Special instruments have been developed for this purpose. They are also introduced by special access to the joint. Among these are hand instruments such as punch, pliers, scissors, knives, curettes and rasps and, in addition, motor driven instruments for smoothing articular cartilage and menisci. Laser and thermocautery instruments are also used.

How is the arthroscope used?

The positioning of the patient in lateral or dorsal recumbency depends on the manipulation to be performed. This should be done in such a way that movement, manipulation, of the joint to be examined is possible. As in conventional operations the surgery is realized under aseptic conditions. First, a cannula is introduced into the joint and by this means the joint is filled with physiological saline or gas (carbon dioxide or air) and the joint cavity expanded. After that, a small incision is made in the skin and, using a blunt or sharp trocar, the arthroscope is introduced into the joint space after which the trocar is replaced by the optical instrument. One or two additional joint openings are made for the introduction of special surgical instruments. Certain manipulations such as the extirpation of an osteochondroma, are carried out after the ligation of blood vessels. For minimally invasive procedures, the principle of the so-called triangular technique is employed. This means that the surgical instruments and the optical instrument are introduced at the points of a triangle. The triangle technique provides optimal viewing with the necessary freedom of movement and, besides that, additional protection for the sensitive optical instrument. Later, sutures close the small openings in the joint needed for the operation. If possible, a sterile dressing is applied.

Follow-up treatment in arthroscopic manipulations

Depending on the indication and seriousness of the operation, the limbs and joints are fully weight-bearing following the procedure. If fragments of bone and cartilage were removed, a follow-up control radiograph is appropriate.

Complications of arthroscopy

During the procedure, technical problems may occur that impair visibility. Damage to blood vessels may lead to hemorrhage and reduce visibility. This impairment of visibility can be removed by

increasing fluid-flow or by irrigation. Iatrogenic complications as, for example, injuries to cartilage, blood vessels, and nerves that are caused by the treating veterinarian must be considered. Synovial fluid may leak out at the injection site. There may be herniation at the site of incision. Occasionally, there may be observed an increase in secondary periosteal bone or ossifications within the joint. Infections are dreaded complications that, in the extreme, may result in ankylosis.

Special preconditions for successful endoscopy

To carry out a procedure like this in which direct observation of the field of operation is lacking, orientation is exclusively by monitor, and there is a loss of the three dimensional sense that requires a systematic training. Solid anatomical knowledge and a rich experience are essential preconditions for successful minimally invasive manipulations. A well-adjusted team of surgeons, a trained staff and a well equipped operating room are additional requirements for successful surgery.

Endoscopy of the hock joint (talocrural joint, Fig. 3)

Arthroscopy of the talocrural joint is most common because therapeutic options are favorable here and a good overview can be obtained by expanding the joint space. The dorsal and plantar parts of this compound joint are most valuable. Positioning: dorsal or lateral recumbency. Access: Standard access is dorsomedial, as far distal as possible. Indications: *osteochondrosis dissecans* (OCD) and traumata of the articular ridges of the trochlea of the talus, of the tibial cochlea as well as the lateral and medial malleoli.

Arthroscopy of the stifle joint (Fig. 4)

Arthroscopy of the stifle joint is often done. The stifle or genu joint is subdivided into a femoropatellar joint with its own joint capsule and the femorotibial joint with medial and lateral joint capsules. Orientation within the femoropatellar joint is excellent. In the femorotibial joint only the cranial and caudal parts are visible. Positioning: dorsal recumbency or, in rare cases, lateral recumbency. Access: Standard access for the femoropatellar joint is craniomedial, between the medial and intermediate patellar ligaments. But access can also be achieved by splitting the intermediate patellar ligament or entering between the lateral and intermediate patellar ligaments. Starting from the femoropatellar joint access can be gained to the femorotibial joint. The medial joint can be separately examined by positioning the arthroscope between the medial and intermediate patellar ligaments, directing the instrument caudoproximally and somewhat axially. The lateral joint cavity can also be reached from this access.

- Indications ([1], [2]):
- Osteochondrosis dissecans (OCD) of the medial ridge of the trochlea
- Cysts of the medial condyle
- Cruciate ligament repair following rupture of the ligament
- Repair of the meniscus following meniscal tears

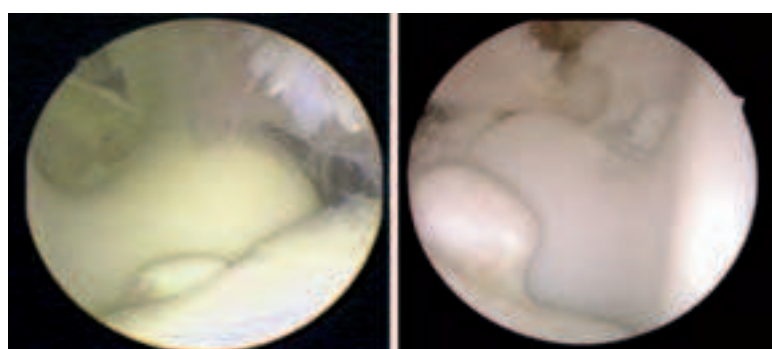


Fig. 3. Arthroscopy of the tarsocrural joint. Photographs of an OCD of the sagittal ridge of the tibia. (Courtesy of Prof. Dr. Rijkenhuizen)

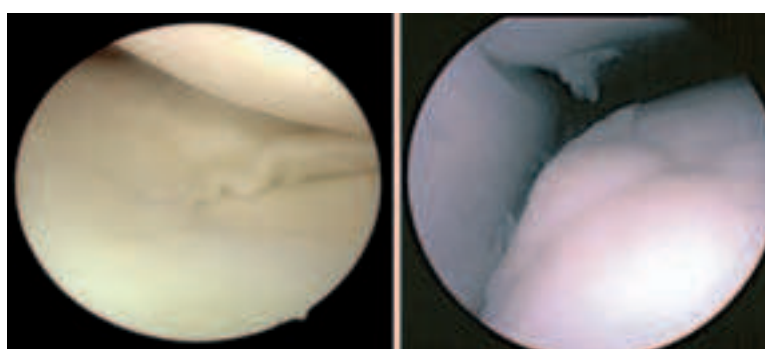


Fig. 4. Arthroscopy of the stifle joint. Left: Meniscus of the lateral femorotibial joint. Right: OCD of the lateral ridge of the femur (femoropatellar joint). (Courtesy of Prof. Dr. Rijkenhuizen)

4.1. Ossification of the individual thoracic limb bones takes place predominantly from several ossification centers, which are separated from each other by cartilaginous growth zones (growth plates or physes). Some of these apophyses and epiphyseal growth plates close only after birth and for this reason, for a certain time, are still demonstrable by radiograph (Figs. 4.1.1, 4.1.2). [3] Knowledge of their localization and of the time of closure is of paramount clinical importance as the growth plates may feign fracture lines in young animals. Moreover, they represent a certain *locus minoris resistentiae* (weak point) and fractures of the growth plates (so-called Salter-Harris fractures) are not rare. Depending on the configuration of the fracture line or the involvement of the epiphysis and/or metaphysis, 6 types can be differentiated. [5] On the thoracic limb, the proximal growth plates of the ulna and radius as well as the distal plates of the humerus, scapula, radius and Mc III (cannon bone) are most frequently encountered. [4] Treatment and prognosis depend on the kind of fracture. In most cases, a surgical approach (internal fixation of the fracture fragments by osteosynthesis) is indicated. [6] [5] If the fracture is stable and there is no dislocation of the bone fragments and no joint involvement, a conservative treatment is possible. [6]

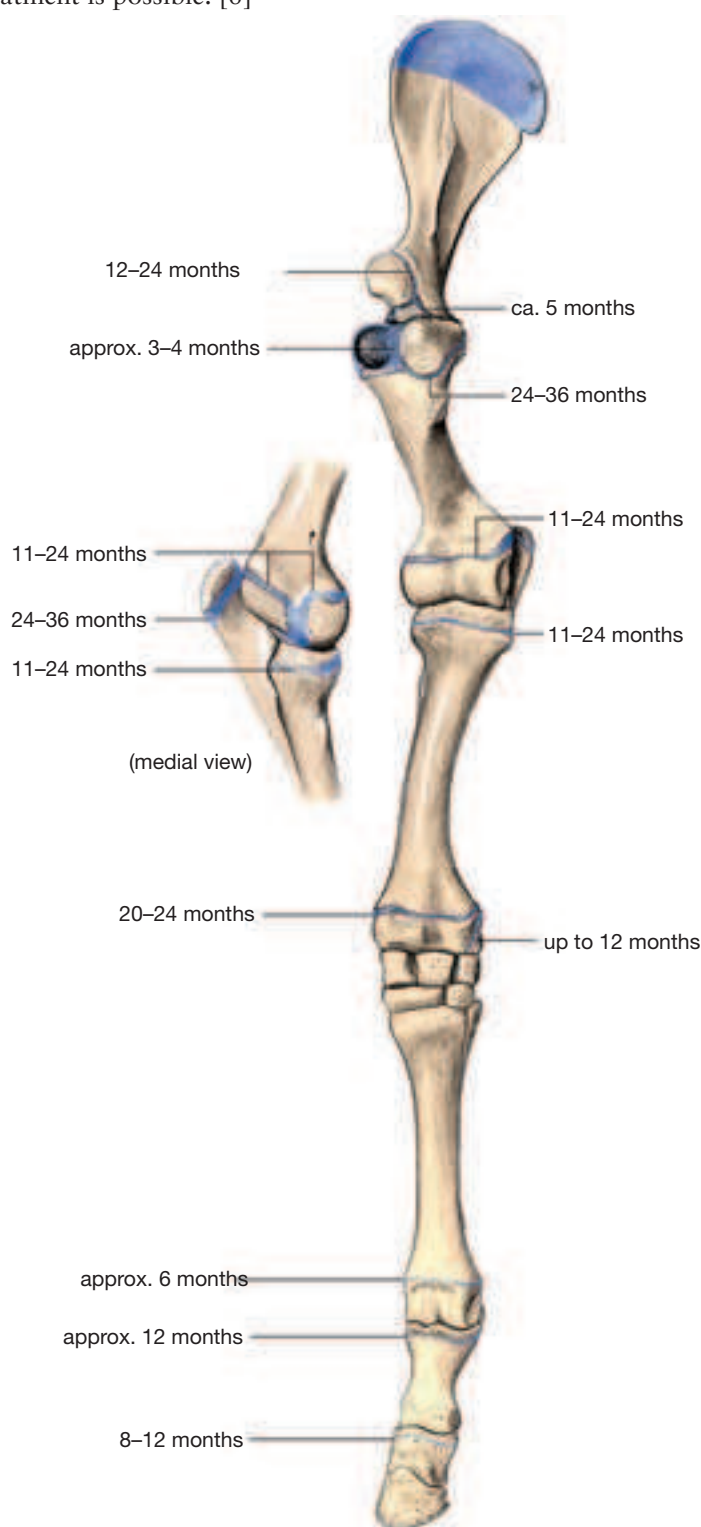


Fig. 4.1.1. Apophyseal and epiphyseal lines of fusion of the thoracic limb of the horse. (Closure of the growth plates after Butler *et al.*, 2000). (Courtesy of Institut f. Veterinär-Anatomie, Berlin)

Unequal growth in the area of the growth plate can result in angular limb deformities. In such cases, an axial deviation of the distal limb in a lateral direction is called a valgus position; an axial deviation in the medial direction, a varus position. [7] [8] The distal epiphysis of the radius is most often affected, in which, because of a greater growth potential on the medial aspect, a carpus valgus results. [7] In addition to the asymmetrical growth of the growth plate cartilage, an incomplete ossification and deformation of the carpal bones may be the cause of the axial deviation. [8] [9] Moreover, very often a low-grade carpus valgus may develop in newborn foals as a result of slack periarticular ligaments. This usually corrects itself during the first postnatal weeks. [8] [9] On the basis of radiographs in which lines through the longitudinal axis of the radius and metacarpal bone III are drawn, the origin and degree of severity of the axial deviation (intersection or angular deviation of the lines) can be determined (Fig. 4.4). [10] A special form of axial deviation in the carpal region (offset knee or bench knee) consists of a valgus deviation at the distal end of the radius and a varus deviation at the proximal metacarpal bone III. [7] For the correction of axial deviations in the area of the growth plate, also surgical manipulations, which have an impact on bone growth in the growth plate, are in use besides conservative methods of treatment. In this way, the growth of the bone can be inhibited on the convex aspect, actually the growth plate can be overbridged temporarily by suitable osteosynthetic procedures. [8] [9] Alternatively or in combination with this, bone growth on the concave aspect can be stimulated by an incision and lifting of the periosteum. [7] [8] [9] The usefulness of the foregoing is, to be sure, controverted. [11] In both surgical procedures, the time of growth plate closure must be taken into account. [7] [8]

4.2. Scapula. Fractures are relatively rare. Most often, the supraglenoid tubercle is affected in which case the fracture-line usually reaches the shoulder joint. Owing to the pull of the attaching muscles (biceps brachii and coracobrachialis muscles), the fragments are as a rule displaced cranially and distally. [12] [13]

4.3. Fractures of the humerus occur often as oblique or spiral fractures of the metaphysis or of the diaphysis. [14] Avulsions in the area of the deltoid tuberosity or of the tubercles can also occasionally be observed. [13] In addition, incomplete fractures due to fatigue or stress fractures (fissures) in young thoroughbreds in training are not rare. In the proximal part of the bone, the caudolateral cortex is predominantly affected; distally, the fractures are often located craniomedially or caudally. For diagnosis, scintigraphy^a is the method of choice as the fracture lines are sometimes not recognizable radiographically. [15] [16].

^a Image-producing method with the use of a radioactive substance (as a rule, technetium 99m) that, following intravenous injection, is selectively concentrated in a specific tissue. For scintigraphy of bone, the radioactive isotope is coupled to a bone marker (polyphosphonate) that, with active bone formation, is accumulated in hydroxyapatite crystals. The radiation given off with radioactive breakdown can be recorded with the help of a so-called gamma-camera in which case there is a locally elevated radiation intensity, which points to an increased metabolic activity in a particular bone.

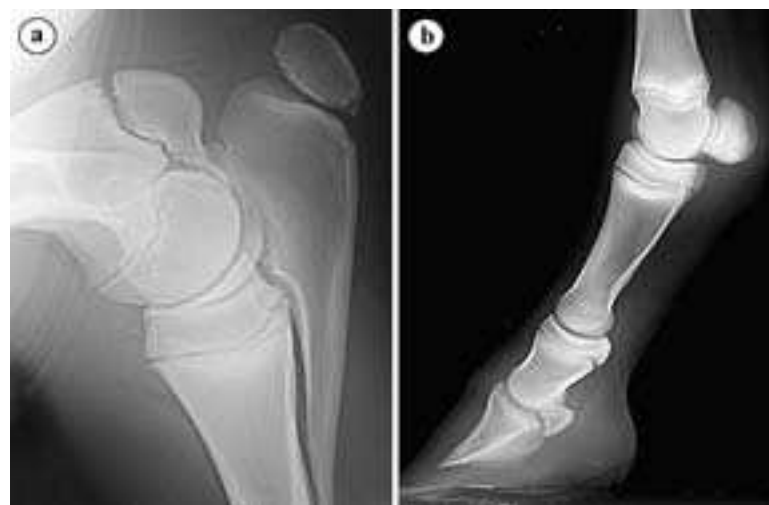

Fig. 4.1.2. Growth plates in the region of the elbow (a) and on the distal limb (b) of a 2.5 months old warmblood filly-foal. (Courtesy of Klinik für Orthopädie bei Huf-u. Klautentieren, Veterinärmed. Univ. Wien)

4.4. In most horses, the distal part of the **ulna** is reduced. The lateral styloid process of the radius, which in foals has an isolated ossification center, can be considered as a remnant of the distal end of the ulna. (Fig. 4.4) In some pony breeds (especially, the Shetland pony), a completely developed ulna (*ulna completa*, *ulna persistens*) is sometimes found, which can be understood as a form of atavism. Such ponies usually have misconformation of the limb in the form of a *carpus valgus*. [17]

4.5. Fractures of the **olecranon** are usually the result of direct trauma to the elbow region. [18] Depending on its configuration, five different types are distinguished. Articular fractures in the region of the semilunar notch are seen most often. [18] [19] Conservative treatment is possible. Especially in the case of displaced fracture fragments or involvement of the elbow joint a surgical approach in the form of internal fixation of the bone fragments by way of a suitable osteosynthetic procedure is recommended. [18] [20] [19]

4.6. Fractures of the **radius** may take many forms, but most often oblique or spiral fractures are observed. [21] [22] Particularly in 2–3 year old thoroughbreds in training stress fractures in the region of the radial diaphysis may occur. [15]

4.7. In premature or immature foals as well as in twins, **incomplete ossification** of the carpal bones is sometimes observed in which cases the lateral carpal bones (**carpal bones III, IV, as well as the ulnar and intermediate carpal bones**) are most often affected. [23] [24] For diagnosis, radiographic examination is the preferred means, but sonographic imaging of the joint can give valuable information. [25] Slight delays in the ossification process can be recognized radiographically in the rounded-off form of the corresponding carpal bone and, in severe cases, ossification of the cartilaginous precursor of the carpal bone can be lacking completely. [26] Thus, carpal

bones that are insufficiently ossified can by the foal's bodyweight alone be compressed and deformed wedgelike. [27] The result is that misconformations of the limb (angular limb deformities) occur frequently in which case, as a rule, a *carpus valgus* develops. [23] The main objective of conservative treatment is to prevent bone or, respectively, cartilage damage of the carpal bone concerned and to maintain the axis of the limb until ossification is complete. [27]

4.8. Especially in racehorses osteochondral fragmentation occurs relatively often (in the form of **chip** or **slab fractures**) at the dorsal^b or dorsomedial border of certain carpal bones [28] [29]. This has its origin in bone restructuring after repeated mechanical overload. [30] In chip fractures, the osteochondral fragment extends only into one joint (most often the middle carpal or radiocarpal joint) in which case the fracture is located most frequently proximally on **carpal bone III** or distally on the **radial carpal**. [31] [32] [33] Chip fractures are also observed, not rarely, proximally on the radial carpal bone or intermediate carpal bone as well as distally on the radius. [31] [34] The slab fracture is characterized by a complete separation of the (usually) dorsal surface of a carpal bone in which the fracture line extends through the entire bone into two neighboring joints. [31] [33] Carpal bone III is especially affected [30][29], more rarely the radial carpal bone or intermediate carpal bone as well as carpal bone IV. [35] Sometimes there occur fractures at the palmar borders of the proximal row of carpal bones as well as caudodistally on the radius. These are predominantly the result of a single trauma. [36] Treatment depends on the configuration of the fracture and also on the size of the fragments. Usually a surgical approach (arthroscopic removal or internal fixation of fragments) is indicated. [35] [30] [29] For combined slab fractures, which are accompanied by instability of the carpal joint, partial or complete arthrodesis (surgical immobility) of the carpal joint is described. [37]

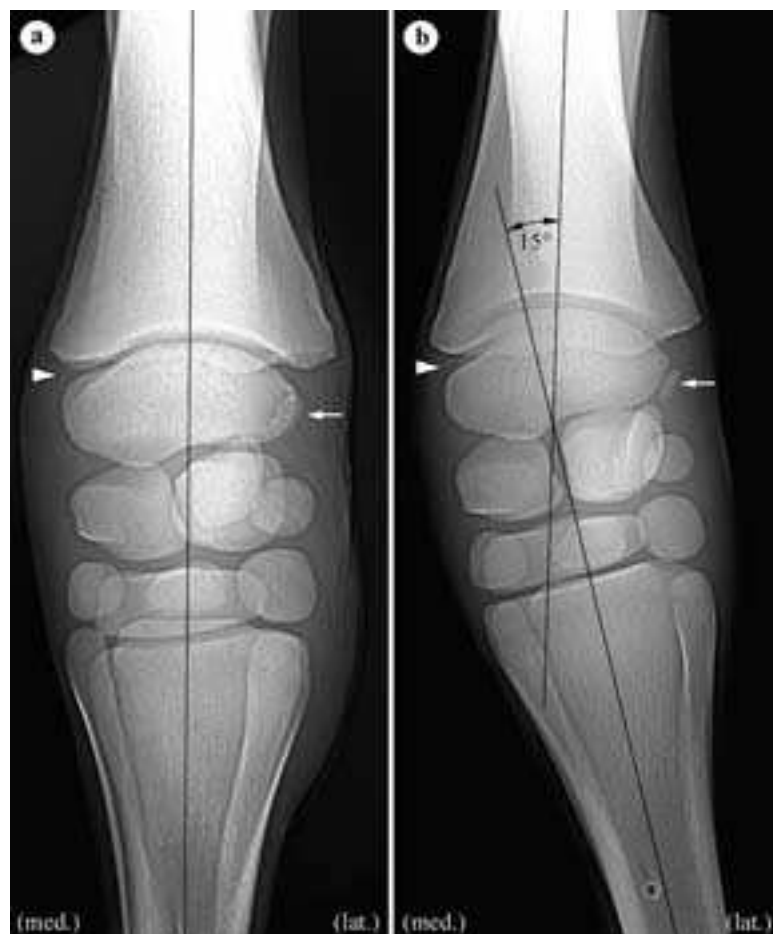


Fig. 4.4. Carpus of a 17 days old warmblood colt-foal, dorsopalmar radiograph a) regular limb position, b) carpus valgus with an axial deviation of about 15° in the region of the antebrachio-carpal joint. **Arrowhead:** distal epiphyseal fusion-line of the radius; **Arrow:** Isolated ossification center of the lateral styloid process (corresponds to the distal end of the ulna). (Radiograph: Klinik für Orthopädie bei Huf- u. Klautieren, Veterinärmed. Univ. Wien)

^b With respect to the designation of direction on the thoracic limb: In the region of the distal limb (up to and including the carpus) the term “dorsal” is used in the place of “cranial” and in place of “caudal” the designation “palmar” is employed.

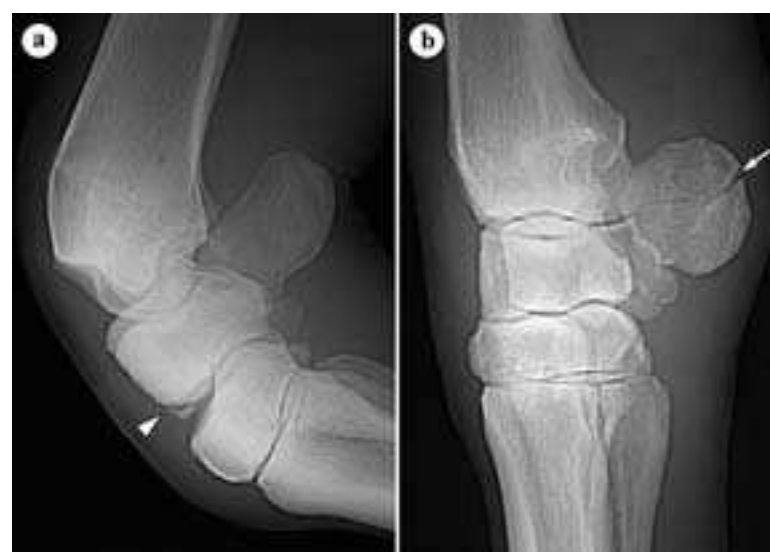

Fig. 4.8. a) Carpal joint in flexion with a dorsodistal chip-fracture of the radial carpal bone (**arrow head**), 3 years thoroughbred stallion, b) 3 months old horizontal-fracture of the accessory carpal bone (**arrow**), 13 years old Channel Island horse. (Radiograph: Klinik für Orthopädie bei Huf- u. Klautieren, Veterinärmed. Univ. Wien)

4.9. The **accessory carpal bone** is located palmarolaterally and is a readily palpable bony landmark. It may also fracture, especially in racehorses. Vertical fractures are most often observed; whereas, horizontal fractures are seen only rarely (Fig. 4.8, b). [31]

4.10. Occasionally a **carpal bone I** [38] [39] is developed and, sporadically, even a **carpal bone V**. [38] On radiographs of the carpal joint, these should not be confused with osteochondral fracture-fragments.

4.11. Dorsally or dorsomedially on the **cannon bone** (Mc III) of young racehorses (especially 2 year old thoroughbreds in their first year of training) there may occur an increase in bone substance, which is brought about by a stress-dependent restructuring of the immature bone (**bucked shins**). Radiographically, predominantly periosteal, but also endosteal, increases in bone can be observed. Such a “pre-damaged” bone is less resistant to stress as the horses concerned, at the age of 3 years, relatively often exhibit fatigue fractures of the dorsolateral corticalis in the region of the middle or distal diaphysis. Both conditions are classified together as “dorsal metacarpal disease.” [40] The training regime of the horses plays an important role in the pathogenesis of this disease. The duration of the stress as well as the kind of gait and speed are particular risk factors. [41]

Also, stress-fractures occasionally occur on the distal end of metacarpal bone III of young thoroughbreds. [42] [43] In the majority of cases they are simple, complete or incomplete oblique fractures in the region of the lateral condyle. [43] Fractures of the medial condyle are rare and have a more spiral configuration. [44]

Likewise, longitudinal fatigue-fractures of the palmar cortical substance occur fairly often at the proximal end of metacarpal bone III. [45] [46] Articular chip-fractures of proximal metacarpal bone III are also not rare. These fractures are predominantly located dorsomedially. [47]

The area of origin of the suspensory ligament (interosseous muscle) on the proximopalmar aspect of metacarpal bone III is also of great importance. Owing to overload of the suspensory apparatus in athletic horses, there may be observed here changes in bone density or, respectively, increases in bone substance or avulsion fractures. [48] [49] [50] Especially in trotters, the dorsal sagittal ridge of metacarpal/metatarsal bone III is a frequent site of disturbance of endochondral ossification in the region of the articular cartilage (*osteochondrosis dissecans*; Fig. 4.11.a). [51] [52] In most cases, the pelvic limb is affected, but osteochondritic lesions can often also be seen at the distal end of metacarpal bone III of the thoracic limb. [51]

4.12. The **splint bones** can be easily distinguished on radiographs as the medial bone (metacarpal bone II) has three, the lateral splint bone (metacarpal bone IV) only two articular facets for the carpal bones. The medial splint bone is also frequently longer than the lateral. [53]

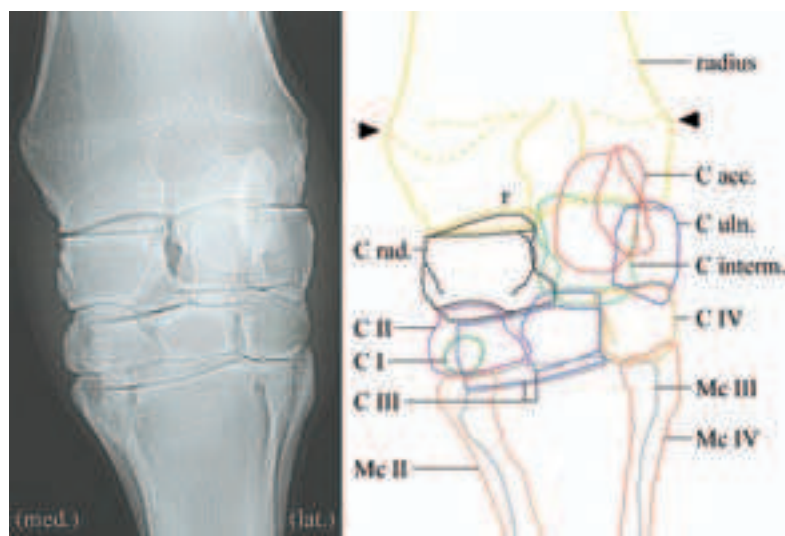


Fig. 4.10. Carpal joint of an adult horse (dorsopalmar radiograph) with schematic representation of the individual bones.

Mc II-IV: metacarpal bones II-IV, **C I-IV:** carpal bones I-IV, **C acc.:** accessory carpal bone, **C interm.:** intermediate carpal bone, **C rad.:** radial carpal bone, **C uln.:** ulnar carpal bone. **Arrowhead:** vestige of the distal epiphyseal fusion of the radius. (Radiograph: Klinik für Orthopädie bei Huf- u. Klautentieren, Veterinärmed. Univ. Wien)

Fractures of the splint bones of the horse are often diagnosed but they are not in every case linked to lameness. [54] [55] Proximal fractures have usually a traumatic cause (frequently injury as a result of being kicked by another horse); whereas, distal fractures are usually the result of fatigue. [55] The latter are mostly associated with inflammation of the suspensory ligament (interosseous muscle) and are mainly caused by forces that act on the freely moveable end of the splint bone. [54] [55] The rudimentary lateral and medial interosseous muscles [the author refers here to the small ligament that extends from the distal end of each splint bone and ends in the ligamentous tissue proximal to the fetlock joint], which originate each at the distal end of the splint bone, extend in the direction of the sesamoid bone and end in the fascia of the fetlock joint, play a special role in this connection. [55] These bands are especially under tension in hyperextension of the fetlock joint and exert a pull on the end of the splint bone. [54] [55] Because the proximal part of the splint bone is relatively firmly connected to metacarpal bone III by interosseous metacarpal ligaments, the transition to the freely moveable end of the splint bone is a site that is predisposed to fracture. [55] Many fatigue-fractures heal spontaneously and only a weakly developed callus (increase of bone in the region of the fracture) is observed. [55] If there is a greater callus formation, mechanical irritation may lead to inflammation of the suspensory ligament (interosseous muscle). In such a case, surgical removal of the distal splint bone, including the increased bone formation, is indicated. But the proximal third of the splint bone should be preserved for reasons of maintenance of carpal stability. If more than two-thirds must be removed, it is sometimes essential to fix the remaining proximal part of the splint bone to metacarpal bone III. [56]

“**Splints**” are locally circumscribed periosteal increases of bone in the region of the metacarpus in which in the majority of cases the proximal part of the splint bone (especially the medial splint bone, Mc II) is affected. [57] [38] Basically, splints can appear at any age but are most often observed in young horses. [57] They usually form following traumatic inflammation of the periosteum. [57] [38] A further reason is excess stress of the interosseous metacarpal ligaments with secondary bone formation at their attachment. [57] Usually, they are as a rule not important clinically [38], but in case of greater bone formation may also result in inflammation of the suspensory ligament. [56] [58] If lameness is observed, the splint and eventually the end of the splint bone located distal to the splint may be removed. Moreover, neurectomy (section and partial removal) of the medial or, respectively, lateral palmar metacarpal nerve is described. [58]

4.13. Fractures of the **proximal phalanx** (long pastern bone, P1, first phalanx) occur relatively often, especially in racehorses. They develop suddenly during a race or in training and result in lameness. Different types are distinguished according to the configuration of the fracture, concerning which a midsagittal fracture, which begins at the fetlock joint, is most frequently observed. In the majority, we

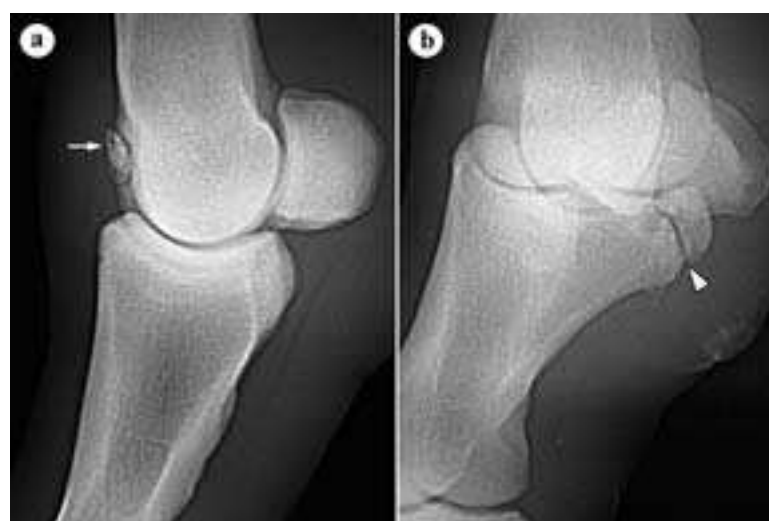

Fig. 4.11. a) Fetlock joint chip (arrow): Osteochondrosis dissecans in the region of the dorsal sagittal crest of Mc III, 8 years warmblood mare, b) Fracture in the region of the lateral palmar eminence of the proximal phalanx (Birkeland fracture, arrowhead), 10 years trotter-mare. (Radiograph: Klinik für Orthopädie bei Huf- u. Klautentieren, Veterinärmed. Univ. Wien)

are dealing with incomplete fractures (fissures), but also, not rarely, complete fractures sometimes occur, extending to the pastern joint. Treatment and prognosis depend on the configuration of the fracture. Often a surgical approach (internal fixation of the fracture-fragments by osteosynthesis) is indicated. [59] [60]

Beyond that, occasionally small osteochondral fragments (so-called **Birkeland fractures**; Fig. 4.11.b) occur proximopalmarly on the long pastern bone. To be sure, these are not linked with a lameness in every case. Basically, they can be found also on the thoracic limb; but, for the most part, they are observed on the pelvic limb (sometimes even bilaterally). [61] [62] Such bone fragments are found above all in trotters very frequently but are observed also in warmbloods. [63] They are predominantly located medially and originate as a rule in the first postnatal months from avulsion fractures in the region of attachment of the short sesamoidean ligaments. [63] [64] Sometimes the severed tissue fragments also ossify secondarily. [63] Intra-articular and extra-articular fractures in the region of the proximal tuberosities of the proximal phalanx are considerably more rare. These occur exclusively laterally. [65] Treatment depends on the position and size of the bone fragment. Usually a surgical approach (arthroscopic removal) or internal fixation is indicated. [66] [61]

Osteochondral fragments (chip fractures) are also observed relatively often proximodorsally on the proximal phalanx. They are predominantly located in the fetlock joint of the thoracic limb, but they are also not rare in the pelvic limb. [51] Such fragments are not always associated with a lameness, but can also be an incidental finding on x-ray examination. The arthroscopic removal of the chip is usually performed under general anesthesia [67] [68], but is also possible in standing horses. [69] Each increase in bone substance on the lateral and palmar aspect of the proximal phalanx in the region of ligamentous attachment (so-called osteophytes) are designated “**osteophytic growth**” in the figure (Fig. 4.13.b). The cause is a chronic ossifying periostitis resulting from repeated stress at the attachment of ligaments. Especially in athletic horses and racehorses, the attachments of the oblique sesamoidean ligaments are affected. However, such insertional desmopathies may occur also at the attachment of other ligaments. Usually they are incidental findings on the radiograph and without clinical importance. [70]

4.14. Fractures of the middle phalanx (short pastern bone, P2) may develop if pressure from the proximal phalanx and from the distal phalanx (coffin bone) act on the middle phalanx, which at the same time is subjected to torsion of the proximal interphalangeal (pastern) joint. In this case, the forces concentrate at the center of the proximal articular surface of the middle phalanx, where multiple radiating fractures usually take origin (Fig. 4.13.a). Often, some fracture lines reach the distal interphalangeal (coffin) joint. Prognosis depends on the number of fragments that develop and the extent to which the joint participates. The steps in treatment are also geared mainly to the number and size of the fracture-fragments. [71] [72] Internal fixation is often not possible because of

the intense crushing of the bone. [72] In addition to conservative therapy (classical cast bandage), a so-called “trans-fixation cast” can be used for weight relief of the distal limb. At the same time, several parallel-arranged Steinman-nails are screwed through the cannon bone and their projecting ends fixed in a cast. In this way, the body weight is transferred from the cannon bone to the cast and from there to the ground without the digital bones having to take over the load. [72] A similar principle is followed in the so-called “walking cast” in which the Steinman-pins are connected not only to the cast but also to the U-shaped metal frame. In this framework, the limb is properly suspended so that transfer of the force to the ground is possible without loading the distal limb. [73]

4.15. Fractures of the coffin bone (distal phalanx, third phalanx) are especially not rare in racehorses, in which in the majority of cases the thoracic limb is involved. [74] Depending on the configuration of the fracture one differentiates six different types. [75] Oblique fractures of the body of the coffin bone with involvement of the coffin joint are most often seen. [74] Also sagittal fractures as well as fractures in the region of the margo solearis (solear border), the palmar or plantar process of the coffin bone or the extensor process are relatively often observed; whereas, crushing fractures are rather rare. [75] Treatment and prognosis depend on the location and configuration of the fracture. Conservative treatment (external fixation by appropriate orthopedic shoeing and applying a foot bandage) have the objective to eliminate the hoof mechanism and, by this means, to obtain immobilization of the fracture. [76] Compression of the fracture crack, which is especially desirable in sagittal fractures with joint involvement is only possible surgically. [77] Because the surgical approach goes through the lateral hoof wall, surgical treatment of the fracture is associated with a high risk of infection. [77] [76]

Differential diagnosis must be considered in that palmar at the palmar process of the hoof or in the region of the extensor process separate ossification centers may occur, which are not to be confused with fractures. [78] [79] Moreover, isolated fragments of dense bone proximally at the **extensor process** may be caused by a metaplasia (dystrophic mineralization) of the extensor tendon or of the joint capsule or by a developmental defect in the region of the articular cartilage (*osteochondrosis dissecans*; Fig. 4.15, a). [78] The clinical significance of such fragments in the region of the extensor process is different. In case of lameness, the treatment depends on the location and size of the fragment. If the fragment is intra-articular, then usually a surgical approach in the form of an arthroscopic or arthrotomic removal is indicated. [80] For larger fragments an internal fixation is also described. [81]

In many horses, at the dorsal part of the solear border of the coffin bone, a concave indentation (*crena marginis solearis*) is observed as an anatomical variant and an equivalent of a solear spur. [82] [83] Similar changes in contour of the coffin bone may also develop on the basis of a pressure-related atrophy of bone in the case of the existence of a horn column (Fig. 26.8). [82]

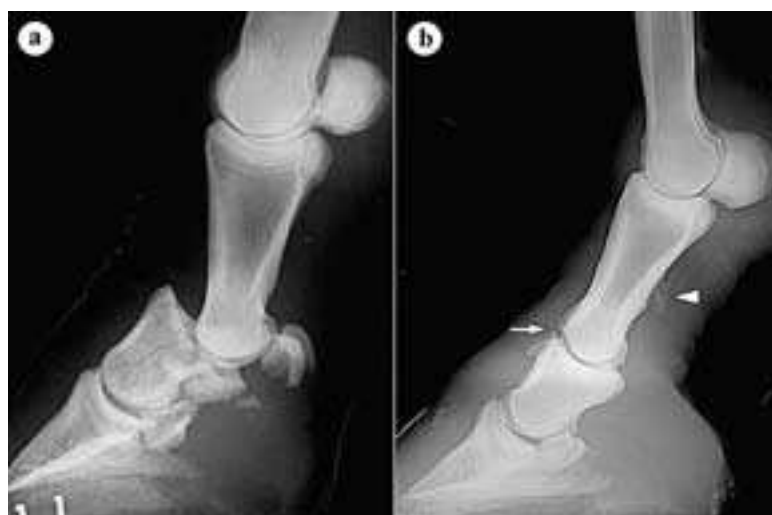

Fig. 4.13. a) Multiple fractures of the middle phalanx (short pastern bone), 10 years warmblood mare, b) arthrosis of the pastern joint (arrow) and chronic ossifying periostitis (arrowhead), 23 years warmblood mare. (Radiograph: Klinik für Orthopädie bei Huf- u. Klauentieren, Veterinärmed. Univ. Wien)

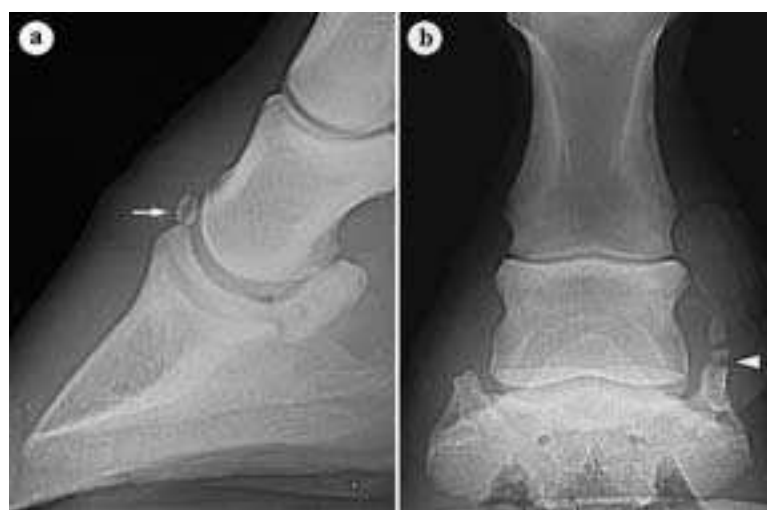

Fig. 4.15. a) Coffin joint-chip (arrow), 16 years warmblood gelding, b) Fracture of the ossified ungular cartilage (arrowhead), 18 years warmblood gelding. (Radiograph: Klinik für Orthopädie bei Huf- u. Klauentieren, Veterinärmed. Univ. Wien)

4.16. The proximal border of the **ungular cartilage** can be readily palpated as an elastic structure under the skin. Sometimes the elasticity is lost due to a gradual ossification of the cartilaginous tissue, which in advanced stages can also be palpated. [84] **Ossifications of the unguar cartilage** occur especially in heavy draft horses both on the medial as well as the lateral unguar cartilages of the thoracic limbs. [85] Also in warmbloods (especially in horses working on hard ground) such alterations are not rare, but, to be sure, here the lateral unguar cartilage is more likely to be affected. [85] Ossification of the unguar cartilage starts usually at the base and, with greater ossification, reaches almost to the level of the pastern joint. [84] Often separate ossification centers have developed, which may simulate fracture lines (Fig. 4.15.b). [25] As a rule, we are dealing with incidental radiographic findings without clinical relevance. [84] [85]

Wounds in the region of the unguar cartilage may lead to necrosis of the cartilaginous tissue and formation of an **ungular fistula**. Typically, directly proximal to the lateral or palmar coronary border, there is a chronic outflow of pus from a wound that is not healing. Lameness is usually present. Treatment as a rule consists of surgical removal of the altered cartilage-tissue. [86]

4.17. The proximal **sesamoid bones** together with the suspensory ligament (interosseous muscle) and the distal sesamoidean ligaments are important elements of the suspensory apparatus. If the suspensory ligament loses its distal fixation owing to fracture of these sesamoid bones, an excessive hyperextension of the fetlock joint occurs (breakdown, see also 12.2). [87] [88] Fractures of the proximal sesamoid bones are primarily observed in young racehorses (trotter and thoroughbred), but are also possible in all other horses. [89] For the most part, the proximal sesamoid bones of the thoracic limb are affected. In trotters, fractures of the proximal sesamoid bones are also often seen on the pelvic limb. [91] According to the location and configuration of the fracture line, six different types are distinguished. [92] Apical fractures are most common, but fractures of the basis, midbody and crushing fractures are also not rarely observed. [92] [93] [90] Abaxial fractures usually involve the attachment of the suspensory ligament (m. interosseus) on the abaxial border of the sesamoid and are usually not articular. [92] [93] Sagittal fractures are considerably more rare and are mostly located on the axial border of the sesamoid and are associated often with a fracture of the lateral condyle of Mc III. [94] [92] Also in foals less than 2 months of age sesamoid fractures may occur. Often they are fractures of the base of the medial sesamoid bone of the thoracic limb. The fractures mostly develop on pasture when the foal tries to follow the mother at high speed. [95] Treatment and prognosis depend on the configuration of the fracture and on the size of the fracture-fragment as well as on the age of the horse. Often a surgical approach (arthroscopic or arthrotomic removal of a fragment [92] [96] [97]) or an internal fixation of the fracture [92] [91] [98] is indicated.

Chronic degenerative disease of the sesamoid bones is designated **sesamoiditis** or **sesamoidosis**. [99] This is brought about by an alteration of the arterial blood supply of the sesamoid bones [100] and results in a chronic recidivistic lameness. [99] This is seen especially in racehorses (thoroughbred and trotter), but also other athletic horses may have such alterations of the sesamoid bones. [101] [102] The most important radiographic findings are that, in the abaxial region of the sesamoid bones, the vascular canals are increased in number and altered in form, which can sometimes be observed already in yearlings. [102] Beyond that, sometimes an increase in bone spurs may also be observed in the region of attachment of the suspensory ligament (m. interosseus) or of the distal sesamoid ligaments (proximoabaxially or distally on the sesamoid bone) or osteolytic areas (local dissolution within the bone) may be determined. [103] [102]

4.18. The **navicular bone** (distal sesamoid bone) belongs to the complex of the podotrochlea and may exhibit radiographically visible changes in outline and structure (see also podotrochleosis, section 12.7).

The typical radiographic outline of the navicular bone develops within the first year after birth and is genetically dependent. Differences are possible in the shape of its proximal border, which in the adult horse is concave, undulating, straight, or convex. The form of the distal sesamoid bone is a predisposing factor in the pathogene-

sis of podotrochleosis, in which possibly a different distribution—depending on the form—of the forces acting on the distal sesamoid bone plays a role. [104] Fractures of the navicular bone are usually traumatically induced and affect mainly the thoracic limb. [105] Sagittal fractures occur most frequently [105], in which case the fracture-fragments are usually only a little displaced. [106] Conservative and surgical treatments (external or internal fixation) are in accordance with the procedures in fractures of the coffin bone [105] [106] In persistent lameness as *ultima ratio* (a last procedure) a neurectomy of the medial and lateral palmar digital nerves is performed. [106]

6.1. Lesions of the **brachial plexus** may result in a total loss of sensory and motor function of the thoracic limb. According to the location of the nerve lesion one differentiates a **peripheral paralysis**, in which a lesion is external to the vertebral column (for example in fractures of the scapula or other traumata brought about by space-consuming processes) and a **central paralysis**, in which the lesion is within the vertebral canal (for example, following vertebral fractures or space-consuming processes). [107]

6.2. Sometimes only individual nerves are affected, in which a lesion of the **subcapular and suprascapular nerves** may result in instability of the shoulder joint and by this in gait irregularities owing to loss of function of the shoulder muscles (especially of the subscapular as well as the supra- and infraspinatus muscles). [108] The **suprascapular nerve** is moreover readily injured as it turns around the cranial border of the neck of the scapula (*collum scapulae*). This may lead to a temporary or permanent loss of function and by this to atrophy of the supra- and infraspinatus muscles (so-called “**Sweeny-syndrome**”). [109] [108] Besides conservative therapy, surgical decompression of the nerve (by partial osteotomy of the scapula beneath the nerve or lifting and padding of the nerve at its reflection site) is described in the case of a persisting injury. [109]

6.3. Occasionally lesions of the **radial nerve** may develop which may lead to a loss of function of the extensors of the thoracic limb. [107] [13] In a **distal radial paralysis**, only the extensor muscles of the carpus and digit are affected. The cause is usually trauma in the region where the radial nerve turns proximal to the humeral condyles. [107] In a case of **proximal (total) radial paralysis**, additionally the triceps brachii muscle is paralyzed. This results in a typical attitude of the limb with a dropped elbow and flexed carpal and digital joints (so-called “**kiss hand attitude**”). Proximal radial paralysis may be caused among other things by trauma or a pressure-conditioned lesion of the radial nerve owing to an unfavorable position during anesthesia. Besides that, also an ischemia of the muscles by compression of the vessels (especially the axillary artery) during anesthesia in lateral recumbency is described as a cause of the mentioned symptoms. [107]

6.4. Anesthesia of the **median nerve** that is possible in the scope of the lameness examination will be described with conduction-anesthesia of other nerves of the thoracic limb (section 10.1, k).

6.5. For anesthesia of the **ulnar nerve**: See conduction anesthesia of the thoracic limb (section 10.1, i).

8.1. Anesthesia of the **musculocutaneous nerve**, which, with the ulnar and median nerves, is responsible for cutaneous anesthesia of the distal limb, is also described in conduction anesthesia of the thoracic limb (section 11.1, l).

8.2. Especially in foals, the **cephalic vein** on the medial aspect of the antebrachium can be used as an alternative to the external jugular vein for venepuncture or for the placement of an indwelling venous catheter. [110]

8.3. **Palmar common digital artery II** is the **main metacarpal artery** of the thoracic limb. It is palpable **proximomedially** on the cannon bone beside the deep digital flexor tendon or the distal check ligament. In the case of inflammatory processes of the distal limb (for example laminitis or sole abscess) an increased pulsation is palpable. Moreover, it is possible to check the pulsation of the medial and lateral palmar digital arteries at the level of the fetlock joint. [53]

10.1. Nerve Anesthesia of the Thoracic Limb

Diagnostic nerve anesthesia within the scope of lameness examinations implies a directed nerve block by which precisely defined areas of the limb are desensitized. For this, a 2 % local anesthesia solution is injected into the neighborhood of a particular nerve. As a rule the procedure is begun distally and advanced step-by-step proximally for the purpose of localizing the lameness. For conclusions as to the cause of the lameness, knowledge of the area supplied by the desensitized nerves is essential. A further possible application of nerve anesthesia is local elimination of pain for preparation or facilitation of certain surgical procedures (for example, care of wounds on the distal limb). Nerve anesthesia is contraindicated if there is suspicion of fissures or fractures as well as a subtotal rupture of tendon. In this case, the elimination of pain could lead to stress of the limb concerned and by this to a worsening of the condition.

In the following, the most important sites for blocking nerves shall be described. For didactic reasons, the description will be done from distal to proximal (see also Figs. 10.1.1. and 10.1.2.).

a) For anesthesia of the *rami tori* of the medial or lateral palmar digital nerve (anesthesia of the *ramus pulvinus*, deep distal anesthesia of the palmar digital nerves [TPA 1]), the foot is lifted and the injection done on each side axial to the ungular cartilage, parallel to the deep digital flexor tendon, and 3–4 cm deep in the direction of the sole of the hoof [111]. Two cc of local anesthesia solution is injected. [112] In addition, the other terminal branches of the medial or lateral palmar digital nerve are anesthetized [112] so that besides the heel also the podotrochlea (navicular bone including ligaments of the navicular bone, distal part of the deep digital flexor tendon and podotrochlear bursa [= navicular bursa]), the palmar and abaxial parts of the coffin joint, the palmar part of the coffin bone and the ungular cartilage as well as the solear and cuneal dermis and parts of the laminar corium are desensitized. [112] [111] The unintentional puncture of the coffin joint or the navicular bur-

sa is a possible complication of this method of anesthesia, which is not very often implemented. [112]

b) An alternative is **anesthesia of the medial or lateral palmar digital nerve (TPA 2, palmar digital block)**. This nerve can be palpated in the fetlock region, together with the same-named blood vessels (from dorsal to palmar: vein, artery and nerve) at the border of the deep digital flexor tendon or at the insertional parts of the superficial digital flexor tendon, which are abaxial to the deep tendon here (see Fig. 10.1.2., Q 6). Basically, the entire palmar digital nerve in its extension between the ungular cartilage and the distal border of the proximal sesamoid bone can be anesthetized when a subcutaneous deposit of 1–2 cc of anesthesia solution is injected directly palmar to the neurovascular bundle. [113] [112] An anesthesia as far distal as possible in the fetlock region has the advantage that only a slight danger exists in involving the dorsal branches of the nerve and is for this reason more specific. [114] The same structures are desensitized as in TPA 1, which means 70–80 % of the hoof including the palmar and abaxial parts of the coffin joint as well as also the entire sole. [114] If the anesthesia is realized in the proximal third of the fetlock region, additionally also the palmar part of the pastern joint (= proximal interphalangeal joint), the distal part of the digital flexor tendons including the distal synovial sheath of the flexor tendons as well as the straight sesamoidean ligament (*lig. sesamoideum rectum*) and the oblique sesamoidean ligaments (*ligg. sesamoidea obliqua*) are involved. [112]

c) In addition to TPA 2, also the **dorsal branches (= rami dorsales)** of the medial or, respectively, lateral palmar digital nerve can be anesthetized, in which case the needle is introduced through the skin in the middle of the fetlock in a direction dorsal to the neurovascular bundle. [114] Injection is 2–4 cc of local anesthesia solution subcutaneously. [115] In this way, also the rest of the dorsal part of the hoof (including the dorsal part of the coffin joint) will be desensitized. [114] Desensitization of the dorsal pastern joint is uncertain. [115]

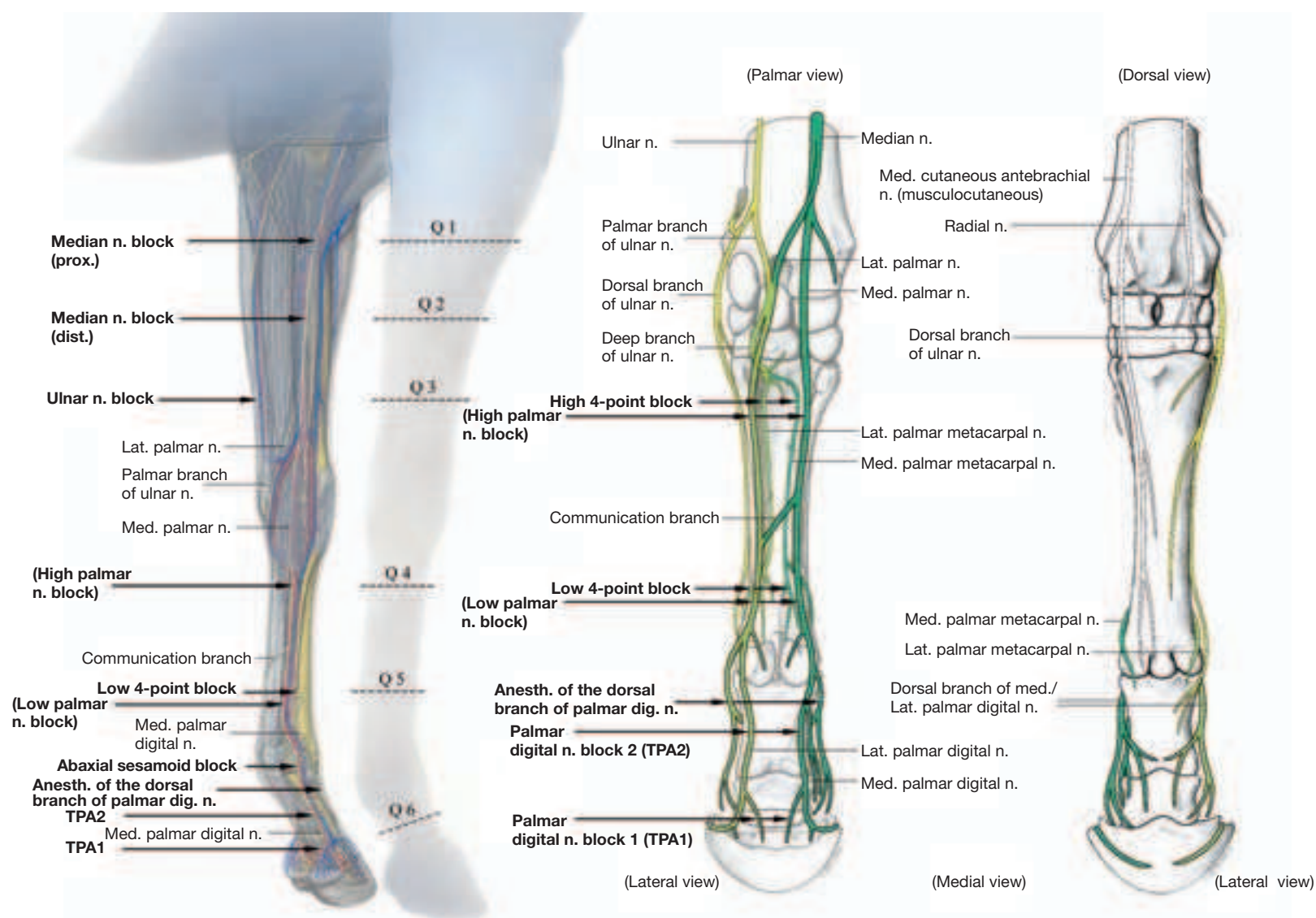


Fig. 10.1.1. For diagnosis of lameness, relevant nerves of the thoracic limb and their most commonly applied sites for anesthesia. Q1–Q6 give the levels of cross-section shown in Fig. 10.1.2. In the right part of the figure, the ulnar nerve with its branches is yellow and the median nerve including its distal continuation is dark green. Nerves colored light green mediate a dual innervation by the ulnar and median nerves (after Muylle *et al.*, 1998).

HPA: high palmar nerve block, **MPA:** low 4-point block, **TPA 1 and 2:** deep (distal and proximal) palmar digital nerve block.

d) To anesthetize the medial and lateral palmar digital nerves at the level of the base of the sesamoid bones (**abaxial sesamoid block**), the neurovascular bundle (consisting of the lateral or medial palmar digital vein, artery and nerve) is palpated on the abaxial surface of the corresponding sesamoid bone. A subcutaneous deposit of 2–3 cc of anesthesia solution is injected directly palmar to this. [113] This block desensitizes the distal digit, including coffin and pastern joints as well as the palmar part of the fetlock joint. [112] Misinterpretations are possible if, by diffusion of the solution proximally, desensitization of the entire fetlock joint and sesamoid bones occurs. [114] [112]

e) Proximal to the fetlock joint, the **medial or lateral sesamoid nerve** proceeds from the medial or lateral^c palmar nerve. To anesthetize it, the needle is introduced between the attachment of the interosseous muscle and the dorsal, abaxial border of the sesamoid bone in a direction toward the apex of the sesamoid. A deposit of 0.5 cc of

local anesthesia is injected. This desensitizes the sesamoid bones and the distal part of the interosseous muscle. [116]

f) The medial or the lateral palmar nerves can be anesthetized at the level of the distal ends of the splint bones, directly proximal to the synovial sheath of the flexor tendons (**middle palmar nerve anesthesia, [MPA], low palmar block**). [113] [112] For this, the needle is introduced between the deep digital flexor tendon and the interosseous muscle and 1.5–5 cc of anesthesia solution is deposited subcutaneously. [114] Anesthesia of the medial and lateral palmar nerves combined with a desensitization of the medial and lateral metacarpal nerves is designated a **deep 4-point anesthesia (low four-point block, Fig. 10.1.2, Q 5)**. [113] [112] For anesthesia of the palmar metacarpal nerves (which course parallel and axial to the splint bones), the needle is introduced directly distal to the “button” of the splint bone, about 1–2 cm perpendicularly through the skin [114], and 1–3 cc of solution injected. [113] [112] Here, perforation of the proximal palmar pouch of the fetlock joint capsule is to be avoided. Deep 4-point anesthesia desensitizes the entire fetlock joint, including the sesamoid bones and all structures located distal to the block. [112] Cutaneous sensation dorsal to the fetlock

^c According to the Nomina Anatomica Veterinaria (1994) synonymous designation for the N. digitalis palmaris communis II or III

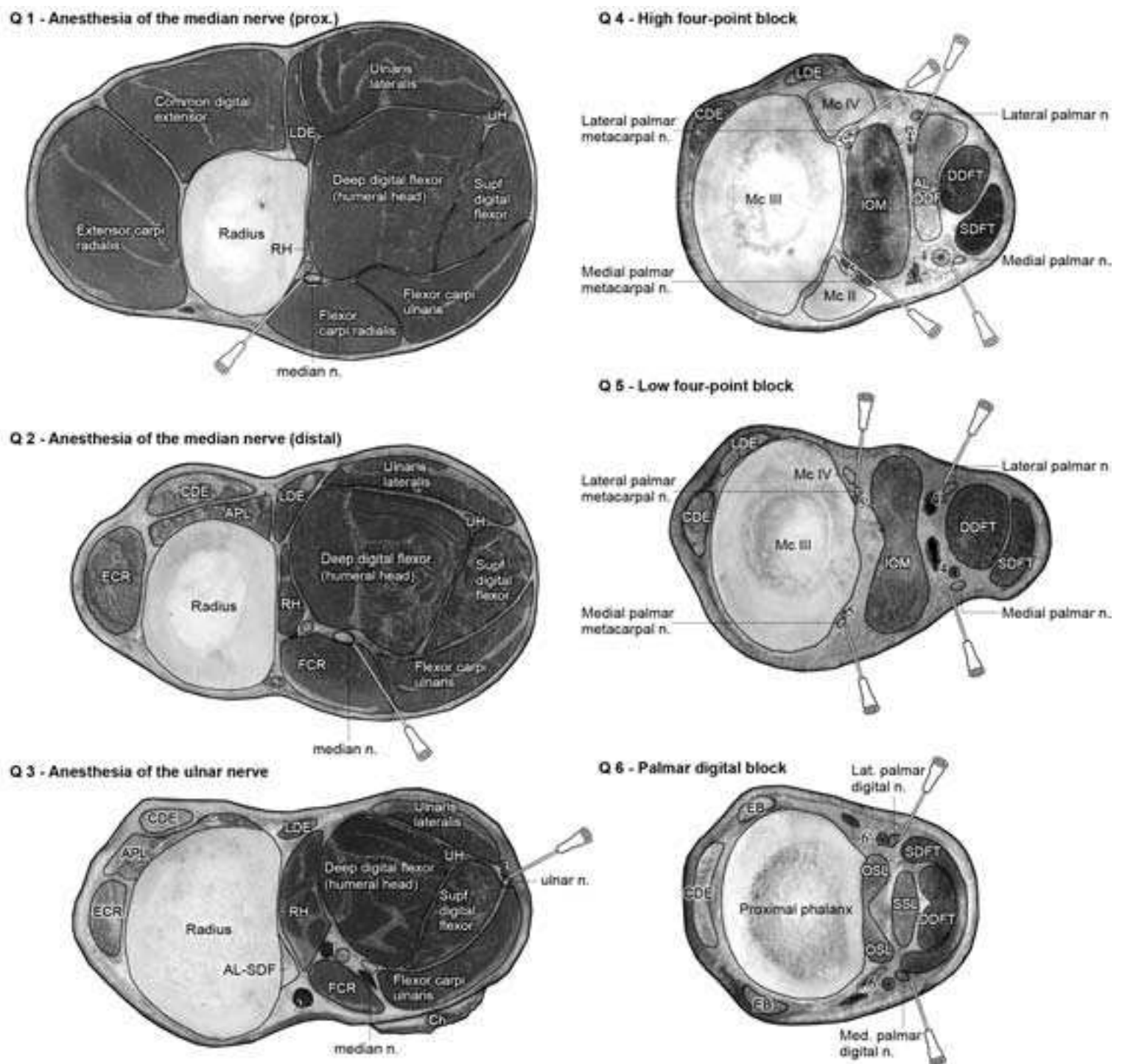


Fig. 10.1.2. Cross-section of the right thoracic limb of a horse to demonstrate the most common sites of local anesthetic nerve blocks. (Level of the cross-sections: see Fig. 10.1.1.).

1: A./V. mediana, 2: V. cephalica, 3: A./V. collateralis ulnaris, 4/4': A./V. dig. palm. com. II/III, 5/5': A./V. metacarp. palm. II/III, 6/6': A./V. dig. palm. med./lat., **AL-DDF**: accessory ligament of the deep digital flexor muscle, **AL-SDF**: accessory ligament of the superficial digital flexor muscle, **APL**: M. abductor pollicis longus (oblique carpal extensor), **CDE**: common digital extensor muscle, **Ch**: chestnut, **DDFT**: deep digital flexor tendon, **EB**: Extensor branch of interosseus, **ECR**: extensor carpi radialis muscle, **FCR**: flexor carpi radialis muscle, **IOM**: suspensory ligament (interosseous muscle), **LDE**: lateral digital extensor muscle, **OSL**: oblique sesamoid ligament, **RH**: radial head of the deep digital flexor muscle, **SDFT**: superficial digital flexor tendon, **SSL**: straight sesamoid ligament, **UH**: ulnar head of the deep digital flexor muscle. (Courtesy of Dr. Patan)

joint remains intact, to be sure, retained by cutaneous branches of the ulnar and musculocutaneous nerves. [113]

g) In the proximal third of the cannon bone, the lateral or medial palmar nerves that course subfascially at the dorsal border of the deep digital flexor tendon may be anesthetized either individually (**high palmar nerve anesthesia [HPA], high palmar block**) or together with the lateral and medial palmar metacarpal nerves located parallel and axial to the splint bones (**high 4-point anesthesia, high four-point block**), Fig. 10.1.2, Q 4). [112] For anesthesia of the medial and lateral palmar nerves, the injection is placed, proximal to the communicating branch, between the deep flexor tendon and the *m. interosseus*. [114] [112]. At this site, medially and laterally on each side, 6 cc. of anesthesia solution is injected subfascially and an additional 2 cc is injected subcutaneously. [117] This desensitizes the distal part of the suspensory ligament, the middle and distal portion of the deep and superficial flexor tendons, as well as the distal limb including the fetlock joint. [117] [112] Desensitization of the accessory ligament (distal check ligament) of the deep digital flexor tendon remains doubtful. The proximal part of the suspensory ligament is not involved in this anesthesia. [118] For high 4-point anesthesia, the needle is introduced proximal to the communicating branch medially or laterally beside the deep digital flexor tendon, and advanced between the suspensory ligament and splint bone up to the cannon bone. [112] A deposit of ca. 5 cc of local anesthesia solution is injected around the medial or, respectively, lateral palmar metacarpal nerve. [114] If the HPA (= high palmar anesthesia) has not been previously carried out, then the lateral and medial palmar nerves each can be anesthetized with withdrawal of the needle. The largest part of the suspensory ligament as well as the palmar part of the metacarpus and the structures anesthetized by the HPA are desensitized. [113] [112] The origin of the suspensory ligament will not be included with high 4-point anesthesia. [118] [112] Misinterpretations are possible if the carpal synovial sheath of the flexor tendons or the carpometacarpal joint (or its distopalmar joint pouch between the proximal splint bone and the suspensory ligament) were unintentionally injected. [119] [112]

h) The proximal portion of the *m. interosseus* is innervated by the deep branch (= *ramus profundus*), which originates from the palmar branch of the ulnar nerve. [118] By its communication with the lateral palmar nerve, the deep branch also receives fibers from the median nerve. [118] This dual innervation from the ulnar nerve and median nerve is also found in the lateral palmar metacarpal nerve as well as the distal continuation of the lateral palmar nerve (Fig. 10.1.1). [118] For anesthesia of the **deep branch** (= *ramus profundus*) (**lateral palmar block**), the needle is introduced, with the carpus slightly flexed, between the accessory carpal bone and the lateral splint bone. It is directed perpendicular to the skin in a dorso-medial direction below the flexor retinaculum [118] [112] and, in withdrawing the needle, about 5 cc of anesthesia solution are injected. [114] [112] In this way, at the same time, the lateral palmar nerve is also desensitized. Perineural injection of the lateral palmar nerve proximal to the origin of its deep branch is also possible at the medial aspect of the accessory carpal bone [199a]. By additional anesthesia of the medial palmar nerve (**high 2-point block**) besides the origin of the suspensory ligament, the same structures are desensitized as in high 4-point anesthesia. [114]

i) To anesthetize the **ulnar nerve**, the ulnar sulcus (a groove between the flexor and extensor carpi ulnaris^d muscles, caudal to the antebrachium is palpated about 10 cm proximal to the accessory carpal bone. This is in proximity to where the nerve courses beneath the antebrachial fascia. [114] [113] [112] At this site, the needle is introduced perpendicular to the skin, slightly laterally directed, and inserted 0.5–1 cm (Fig. 10.1.2, Q 3). [112] With the injection of at least 10 cc of local anesthesia solution [114] [112], the proximal metacarpal region, parts of the carpal canal and of the carpal synovial sheath of the digital flexor tendons as well as the caudal parts of the carpal joint are desensitized. [113] In the region of origin of the suspensory ligament there is only a partial elimination of pain owing to the dual innervation by branches of the ulnar and median nerves. [118]

k) Anesthesia of the median nerve can take place at two locations in the antebrachium. The proximal injection site is found at the distal border of the superficial pectoral muscles. [114] [113] The needle is

inserted perpendicularly through the skin directly caudal to the well visible cephalic vein, between the radius and the flexor carpi radialis muscle,. The needle is advanced 2.5–4 cm in a lateral direction. The median nerve is accompanied by the median artery and vein and is located at this site medial to the artery (Fig. 10.1.2, Q 1). The distal site of injection is found about 10 cm proximal to the chestnut at the caudal border of the flexor carpi radialis muscle. [113] [112] The needle is inserted slightly cranial in the direction of the caudal contour of the radius. At a depth of about 3–4 cm the anesthesia solution is injected. [114] [113] [112] At this site, the median nerve lies between the flexor carpi radialis and deep digital flexor muscles and somewhat caudal to the blood vessels (Fig. 10.1.2, Q 2). [113] [112] Usually anesthesia of the median nerve is done in combination with anesthesia of the ulnar nerve. With this anesthesia, there is desensitization of the entire carpal joint as well as the carpal canal, including the flexor tendons and carpal synovial sheath of the flexor tendons as well as all distally located structures. [112]

l) For cutaneous anesthesia of the medial distal limb (e.g., for care of surgical wounds), the cutaneous branch of the **musculocutaneous nerve** (*N. cutaneus antebrachii medialis*) can be anesthetized additionally. To do this, a subcutaneous deposit of local anesthesia solution is injected medially on the antebrachium, 10 cm proximal to the chestnut, at the cranial and caudal border of the cephalic vein and accessory cephalic vein. [114] [113]

10.2. In the case of chronic degenerative diseases in the palmar half of the hoof (e.g., in persistent lameness of a podotrochleosis or after fractures of the coffin bone or navicular bone) a **neurectomy** of the lateral and medial palmar digital nerves in the palmar pastern region can be carried out as a last measure (*ultima ratio*). [120] [121]

10.3. The carpal canal is bordered palmaromedially by the flexor retinaculum, laterally by the accessory carpal bone and dorsally by the deep palmar carpal ligament or, respectively, by the bony structures (distal radius, carpal and proximal metacarpal bones). [122] Within the carpal canal are located the superficial and deep digital flexor tendons, including the carpal synovial sheath of the flexor tendons as well as the median artery and medial palmar nerve (Fig. 10.3). An increased pressure within the carpal canal (triggered by a primary or secondary inflammation of the flexor tendons or synovial sheath, a fracture of the accessory carpal bone or by other

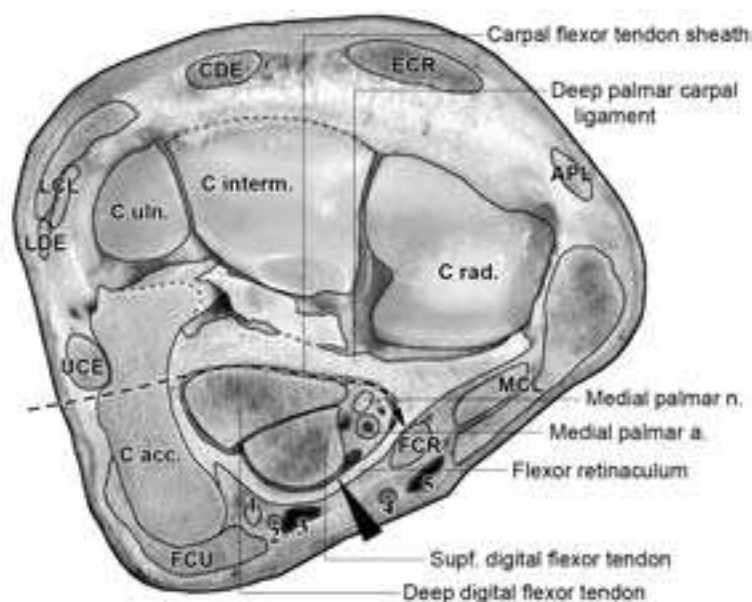


Fig. 10.3. Cross-section through the left forelimb at the level of the carpal canal. Surgical separation of the flexor retinaculum; conventional access from medial (arrowhead) or endoscopic access from lateral (proximal to the accessory carpal bone (dashed arrow).

1: lateral palmar nerve, 2/3: ramus palmaris (palmar branch) of the median a./v., 4/5: radial a./v., APL: abductor pollicis longus (oblique carpal extensor) muscle, C acc.: accessory carpal bone, CDE: common digital extensor muscle, C interm.: intermediate carpal bone, C rad.: radial carpal bone, C uln.: ulnar carpal bone, ECR: extensor carpi radialis muscle, FCR: flexor carpi radialis muscle, FCU: flexor carpi ulnaris muscle, LCL/MCL: lateral/medial collateral ligament of the carpal joint, LDE: lateral digital extensor muscle, UCE: ulnar carpal extensor (ulnaris lateralis) muscle. (Courtesy of Dr. Patan)

^d According to the Nomina Anatomica Veterinaria (1994) synonymous designation: *M. ulnaris lateralis*

space occupying processes) may—especially with flexion of the carpus—result in a painful compression of the flexor tendons or the medial palmar nerve and artery (**carpal canal- or carpal tunnel-syndrome**). [31] [123] [122] The bone or soft tissue changes brought about by the increase in pressure within the carpal canal can usually be demonstrated either radiographically or sonographically. Treatment consists of a cutting of the flexor retinaculum, in which the conventional access is from the medial aspect. [31] [123] Alternatively, an endoscopic approach through the wall of the carpal synovial sheath of the flexor tendons is possible. [122]

10.4. The palmar anular ligament (*Lig. anulare palmare*) attaches to the abaxial surface of the sesamoid bones and forms together with the intersesamoid ligament a canal, which transmits the flexor tendons including their digital synovial sheath (Fig. 10.4). [124] A stricture of the flexor tendons caused by the palmar anular ligament may result in a chronic lameness (**palmar tunnel- or palmar anular ligament-syndrome**) in which thoracic and pelvic limb are affected equally. [124] [125] As a rule, there is a primary or secondary inflammation and thickening of the flexor tendons or of the palmar anular ligament or an inflammation and increased filling of the digital synovial sheath of the flexor tendons. [124] [126] In lateral view, one observes particularly an indentation in the region of the palmar anular ligament or a bulging of the digital synovial sheath proximal to the palmar anular ligament. [124] [125] Frequently, increases of bone tissue as an insertional desmopathy are observed in the region of attachment of the anular ligament on the proximal sesamoid bone. [127] To demonstrate the extent of the changes, radiographic and especially sonographic studies are very suitable. [124] [127] Often surgical treatment in the form of section of the palmar anular ligament is indicated, [124] [125] which also can be realized endoscopically via the synovial sheath of the digital flexor tendons. [128]

12.1. The tendon of the biceps brachii muscle runs in the region of the shoulder joint cranial to the intermediate tubercle of the intertubercular groove and is underlain at this site by a synovial bursa (**intertubercular bursa or bicipital bursa**). Occasionally the bursa together with the tendon is inflamed, which may cause a typical shoulder lameness. The tendon of the biceps muscle, the synovial bursa and the surface of the underlying bone can be demonstrated very well by sonography. [129] [130]

12.2. With thoroughbred horses, occasionally a complete loss of function of the **suspensory apparatus** may occur in which the thoracic limb is almost exclusively involved. [131] [87] Owing to the loss of palmar support, there is a substantial hyperextension of the fetlock joint, which may result in the fetlock's contacting the ground (**breakdown**). [87] [88] A stress-related severe overextension of the fetlock joint at high speed is regarded as a main reason, together with fatigue of the superficial and deep digital flexor muscles (the tendons of which support the suspensory apparatus). [132]

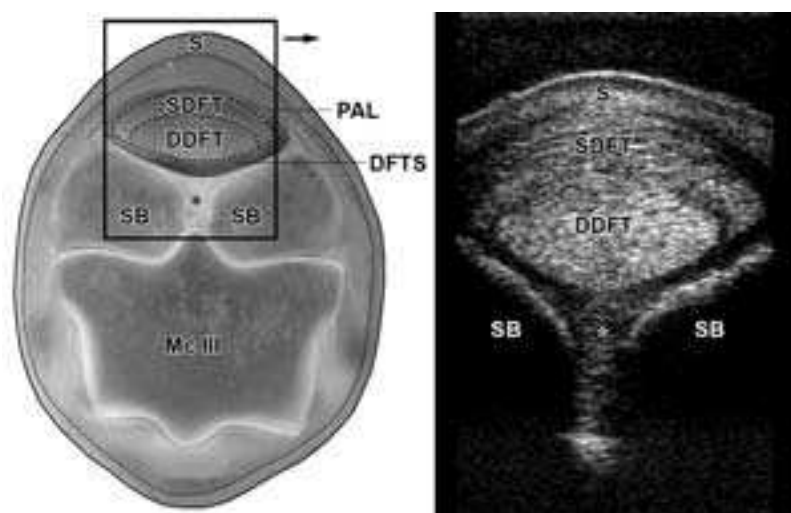


Fig. 10.4. Cross-section at the level of the proximal sesamoid bones with sonogram of the palmar region (transverse, linear array scanner 7.5 MHz with stand-off pad).

DDFT: deep digital flexor tendon, **DFTS:** digital flexor tendon sheath, **PAL:** palmar anular ligament, **S:** skin, **SB:** sesamoid bone, **SDFT:** superficial digital flexor tendon, **asterisk:** intersesamoid ligament (palmar ligaments).

Racehorses are especially involved during intensive training or during the race [131] as well as foals, which in the field follow their mothers over a long distance at high speed. [95] Most often, the reason for the loss of function of the suspensory apparatus is a fracture of both sesamoid bones, [133] [95] but also a rupture of the distal sesamoidean ligaments is often observed. [88] A typical radiographic sign is the proximal location of the sesamoid bones. [88] Rupture of the suspensory ligament is on the contrary relatively rarely seen [135] and occurs more often in untrained racehorses. A distal dislocation of the proximal sesamoid bones can be observed by radiography. [88] Besides conservative treatment (external support by rigid bandaging), different surgical treatments are also described such as the removal or internal fixation of the fracture fragments of the proximal sesamoid bone, arthrodesis (surgical fixation of a joint) of the fetlock joint by suitable osteosynthetic procedures or the application of “transfixation casts” (see 4.14.). [133]

12.3. The suspensory ligament (interosseous muscle), which is an important constituent of the suspensory apparatus, is supplied in the thoracic limb by branches of the median and ulnar nerves. [118] It originates proximopalmarly at **Mc III** as well as with a minor part at the *Lig. carpi radiatum* (part of the deep palmar carpal ligament, Figs. 12.3.1. and 12.3.2., a). Distally it divides into rounded branches, each of which inserts on the abaxial surface of the apex of the sesamoid bone (Figs. 12.3.1. and 12.3.2., b). On the standing

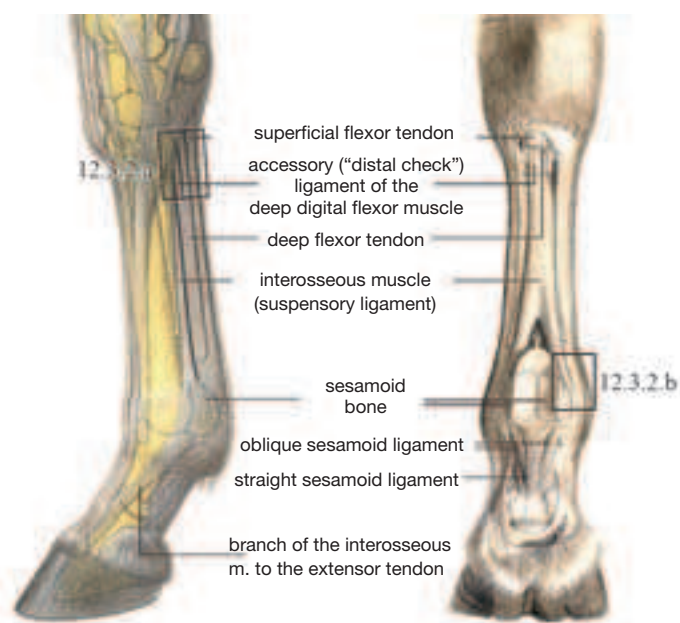


Fig. 12.3.1. Tendons and ligaments in the palmar region of the distal limb (the rectangular frame gives the location of the sonogram in Fig. 12.3.2. (Courtesy of Institut f. Veterinär-Anatomie, Berlin)

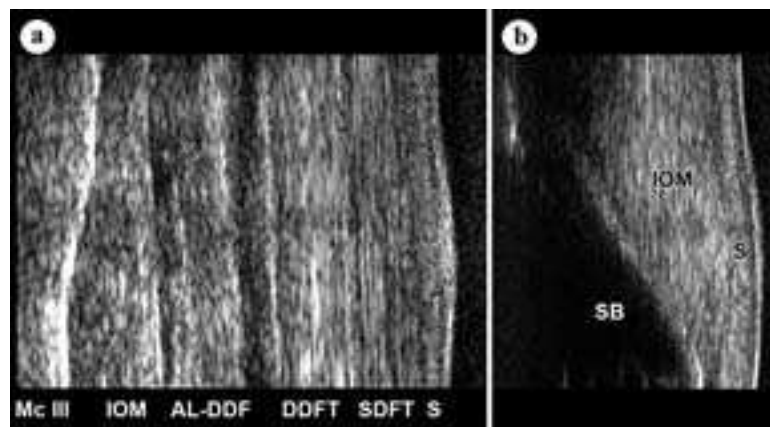


Fig. 12.3.2. a) Sonogram of the proximopalmar metacarpal region (longitudinal, linear array scanner 7.5 MHz with stand-off pad), b) Sonogram of the attachment of the suspensory ligament (interosseous muscle) on the sesamoid bone (longitudinal, linear array scanner 7.5 MHz with stand-off pad), **AL-DDF:** accessory ligament of the deep digital flexor muscle, **DDFT:** deep digital flexor tendon, **IOM:** suspensory ligament (interosseous muscle), **S:** skin, **SB:** sesamoid bone, **SDFT:** superficial digital flexor tendon. (Courtesy of Dr. Patan)

limb, they are palpable as relatively firm structures. [134] Inflammatory changes of the proximal part of the suspensory ligament (origin of the suspensory ligament) are a relatively frequent cause of lameness in athletic horses (especially racehorses, but also dressage and jumping horses). The pelvic limbs are somewhat more often involved (see 24.3). [135]

12.4. Also, the distal sesamoidea ligaments (especially the **oblique sesamoidean ligaments**, but also the **straight sesamoidean ligament**) have a clinical importance. Especially in athletic horses there occurs a low- to moderate-degree lameness that is due to a desmitis of these ligaments. For confirmation of the diagnosis, sonographic examination is the method of choice. [136] [137] [138]

12.5. Tendinitis of the **superficial digital flexor tendon** is the most frequent tendon disease of athletic horses, [139] in which case, the damage to the tendon is chiefly localized in the middle to distal third of the metacarpus. [140] [141] In this region, the superficial digital flexor tendon has a sickle-shaped cross-section in the physiological state, and is on the lifted limb easily differentiated by palpation from the more oval cross-section of the deep digital flexor tendon (see also Fig. 10.4.). With the inflammatory changes, it is frequently difficult to delimit these tendons. With an acute inflammation, there is moreover a painful, warm swelling of the tendon. [141] The main cause of tendinitis of the superficial digital flexor tendon is considered to be an overstress of the tendon, which leads to a rupture of tendon fibers. [139] On the basis of the very restricted adaptability of the tendons, there is an accumulation of stress-dependent microtraumata and with that a degeneration of tendon tissue. [142] Besides that, direct traumata can also bring about a tendonitis secondarily. [139] Healing of the tendon damage results with the formation of scar tissue, which decreases the elasticity of the tendon. Consequently, especially in trotter racehorses, in which the superficial digital flexor tendon is exposed to a high stress, there are relatively often recidivists. [139] The extent of the damage to the tendon is best assessed sonographically. In checking the course of healing, sonographic examination is also the method of choice, [141] [143] but it is problematic to demonstrate the chronic scar tissue. [144] In this case especially the MRI (magnetic resonance imaging) is very suitable. [144] [145] Different physical, medical, and

surgical procedures are described for treatment, concerning which a controlled program of exercise adapted to the course of healing is considered especially important. [141]

The **accessory ligament of the superficial digital flexor tendon (proximal check ligament)**, which originates about 7–14 cm proximal to the antebrachio-carpal joint caudomedially at the radius, may exhibit spontaneous injuries, especially in sport and racehorses. [147] [148] The changes can usually be demonstrated well sonographically [147] and occur often together with a tendinitis of the superficial digital flexor tendon [139] or with the carpal canal syndrome. [148] Also, surgically the accessory ligament is of importance, because in case of a severe tendinitis of the superficial digital flexor tendon [139] or in certain forms of flexural limb deformities a desmotomy (section) of the ligament in the region of its origin is done therapeutically. This can be done endoscopically, in which case access is possible either from lateral via the carpal synovial sheath of the digital flexors [149] or from medial via the synovial sheath of the flexor carpi radialis muscle. [139] Alternatively, direct access to the accessory ligament from medial at the level of the chestnut, cranial to the cephalic vein, is possible.

12.6. In contrast to the superficial digital flexor tendon, tendinitis of the **deep digital flexor tendon** in the region of the cannon bone is rather rare. Lesions of this tendon are more often localized in the distal part (*i.e.*, at the pastern or in the region of the podotrochlea), concerning which in the majority of cases a primary lesion of the tendon is present. Secondary tendon lesions in connection with alterations of the navicular bone are remarkably more rare, for which reason, there is sometimes no radiographic indication of the podotrochleosis syndrome. Since lesions in this area very frequently can also not be demonstrated sonographically, an additional MRI is of great diagnostic value. [151]

The **accessory ligament of the deep digital flexor tendon (distal check ligament)** originates in the area of the palmar carpus from the *ligamentum carpi radiatum* (a part of the deep palmar carpal ligament) and passes over into the deep digital flexor tendon at the middle of the metacarpus. [134] Also, this check ligament, which on the thoracic limb in the proximal metacarpal region has roughly the same caliber as the deep digital flexor tendon, is of clinical relevance (Fig. 12.5). Owing to overstress, especially in athletic horses, lesions of this ligament may develop, which can usually be demonstrated very well sonographically. [142] Moreover, in certain forms of flexural limb deformities (see below) a desmotomy of the check ligament of the deep digital flexor tendon is performed in the proximal third of the metacarpus. [152] For that, the access is mostly from lateral (to take care for the medial palmar artery), but is also possible from medial. [150]

Due to shortening of the flexor tendons, restrictions of the mobility of different joints may develop, so that the limb cannot be fully extended (flexural limb deformities). [152] Newborn foals or younger horses are especially involved; however, older horses may also develop a flexural limb deformity. [8] In the case of an **inherited flexural limb deformity of foals**, a disproportion between the mus-

^e Computer supported cross-sectional imaging procedure for the differentiation of various soft tissues. The phenomenon which forms the basis of this is the inherent rotation (so-called "spin") of hydrogen nuclei (protons). These are disposed across an appropriate magnetic moment and are aligned in the direction of an external magnetic field. This alignment is disturbed for a short time by brief impulses of electromagnetic waves that exhibit the same frequency as the inherent rotation (resonance) of the protons. Following the impulse, protons revert to their original orientation, releasing electromagnetic waves that can be recorded with corresponding registering devices. The intensity of the signal is specific and is based on the variable proton density of the tissue.

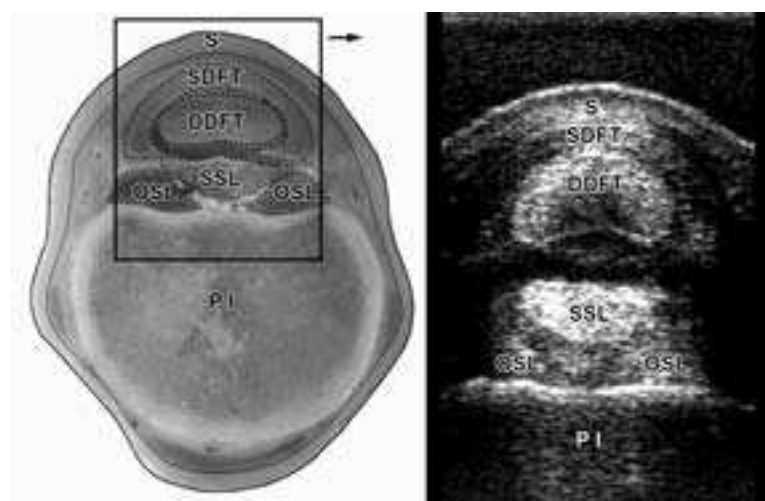


Fig. 12.4. Cross-section at the level of the proximal phalanx with sonogram of the palmar region (transverse, linear array scanner 7.5 MHz with stand-off pad). **DDFT:** deep digital flexor tendon, **OSL:** oblique sesamoid ligament, **PI:** proximal phalanx, **S:** skin, **SDFT:** superficial digital flexor tendon, **SSL:** straight sesamoid ligament. (Courtesy of Dr. Patan)

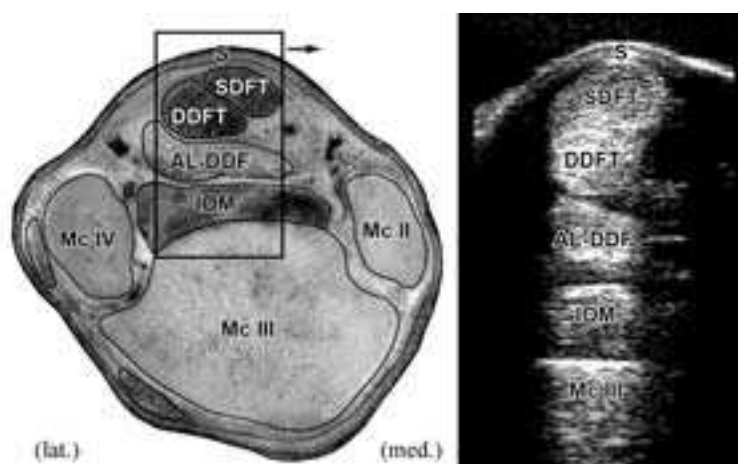


Fig. 12.5. Cross-section at the level of the proximal metacarpus with sonogram of the palmar region (transverse, linear array scanner 7.5 MHz with stand-off pad). **AL-DDF:** accessory ligament of the deep digital flexor tendon, **DDFT:** deep digital flexor tendon, **IOM:** suspensory ligament (interosseous muscle), **S:** skin, **SDFT:** superficial digital flexor tendon. (Courtesy of Dr. Patan)

cle-tendon-length and the length of the bone is frequently present. Occasionally, however, deformation of the joint-forming bones is responsible. [152] [154] Usually the digital joints cannot be extended, but sometimes also the carpal joints and rarely the hock joints are involved. [152] [153] [154] In the case of **acquired flexural limb deformities of foals**, which develop mostly at an age of 6 weeks to 8 months, especially the coffin joint cannot be extended because of a contracture of the deep digital flexor tendon. [152] [8] With persistence of the condition, there usually develops a club hoof (angle of the toe will be up to 90° or even more). [152] [8] [153] With the more rare form in which the carpal joint is also involved, predominantly foals of an age between 1–6 months are encountered. [154] The **acquired flexural deformity of the young horse** appears usually at an age between 9–24 months. [8] [154] A non-physiological flexure of the fetlock joint (so-called “knuckling over”) is typical, in which case the dorsal angle of the fetlock joint is 180° and more (an angle of about 140° is physiological). [152] The disease develops primarily by a shortening of the superficial digital flexor tendon in relation to the skeleton. The deep digital flexor tendon and the suspensory ligament can, however, be secondarily involved. [152] As a cause, especially different painful conditions in the region of the limbs are considered. [8] [154] [153] Treatment of the inherited and acquired flexural limb deformity depends on the location and the degree of severity of the disease. In mild cases, a conservative treatment is successful; whereas, in severe cases, different surgical procedures are customary. [152] [8] [153] In the case of an acquired flexural limb deformity of foals, a desmotomy of the check ligament of the deep digital flexor tendon and/or a tenotomy of the deep digital flexor tendon in the middle metacarpal region may be necessary. [152] For the acquired flexural limb deformity of the young horse, often a desmotomy of the check ligament of the superficial and/or deep flexor tendons, sometimes also a tenotomy of the deep and/or superficial flexor tendon is indicated. [152] [154] Section of the suspensory ligament is only performed in exceptional cases. [152] In newborn foals with non-physiological flexure of the carpal joint, tenotomy of the tendons of the flexor and extensor carpi ulnaris muscles about 2 cm proximal to the accessory carpal bone is possible as a final resort (*ultima ratio*). [152] [8]

12.7. The podotrochlea consists of the gliding surface (*facies flexoria* or *distal scutum*) of the navicular bone, the podotrochlear bursa (navicular bursa), and the part of the deep digital flexor tendon that passes upon the gliding surface. [155] In the broader sense, the entire navicular bone, including its ligaments, as well as the palmar part of the coffin joint belong to the podotrochlea. [156] Disease of the podotrochlea (**podotrochleosis**, **navicular-bone-syndrome**, **navicular disease**) is one of the most frequent causes of lameness in riding horses. [155] Usually both thoracic limbs are involved and the horses have a stiff, stumbling gait. [157] [121] The pathogenesis is presumably multifactorial, in which a main cause of reduced blood

supply (ischemia) in the distal region of the podotrochlea as well as excessive static-mechanical stress are discussed. [121] The most frequent radiographic signs are alterations in the contour of the distal border of the navicular bone in the form of sesamoid canals (out-pouchings of the coffin joint surrounded by vessels and nerves). [155] [157] Here, knobby, deformed or branched canals are to be regarded in each case as pathological; whereas narrow sesamoid canals of variable depth can be observed even in clinically normal horses. [158] The pathological dilatation of these little canals presumably arises either from an increased intraarticular pressure in connection with an inflammation of the coffin joint [155] or by an elevated intraarterial pressure due to arteriosclerotic changes of the vessels within the sesamoid canals. [156] Beyond that, also cartilaginous and osseous defects of the gliding surface of the navicular bone, inflammation of the navicular bursa, as well as lesions of the distal part of the deep flexor tendon are possible causes. [159] A further change that appears is insertional desmopathy of the different ligaments of the navicular bone. [155] [157] [38] Excessive stress of the ligamentous apparatus is considered the cause that leads to the reactive increase of bone. [38] The consequence is a deformation of the contour of the navicular bone in the form of sharp-pointed extensions at the ends or excrescences of bone on the proximal or distal border of the navicular bone. [155] [38] Sometimes, chip fractures of these bony excrescences also occur. [155] The lesions on the navicular bone are usually well demonstrated radiographically, in which case the so-called Oxspring technique is of particular importance. [160] [161] Using this technique, the navicular bone is projected onto the second phalanx by flexion of the coffin joint and a dorso-palmar path of the x-ray beam (Fig. 12.7.1., a). [161] An evaluation of the gliding surface for the tendon as well as the bone structure of the navicular bone can be accomplished by latero-medial (Fig. 12.7.1., c) or tangential (palmaroproximal-palmarodistal, Fig. 12.7.1., b) radiographs. [121] [161] To obtain additional information on the gliding surface for the tendon of the navicular bone as well as of the deep flexor tendon, which passes here, a sonographic examination can be attempted over the area of the frog (after hoof trimming). [162] A further aid to diagnosis would be scintigraphy of the navicular bone region, which, to be sure, even in clinically healthy horses can yield a positive reading. [163] It is possible to obtain a good representation of the navicular bone or the surrounding soft tissues with CT^f or MRI.

^f Computer supported cross-sectional imaging procedure, which rests upon the principle of tissue-specific absorption of x-radiation. In this procedure, a multiplicity of projections of a designated layer of the body is generated. In the computer, these are reworked by way of measurements of density to form an image. The different density values are represented as grey-tones and permit a certain differentiation of the tissues.

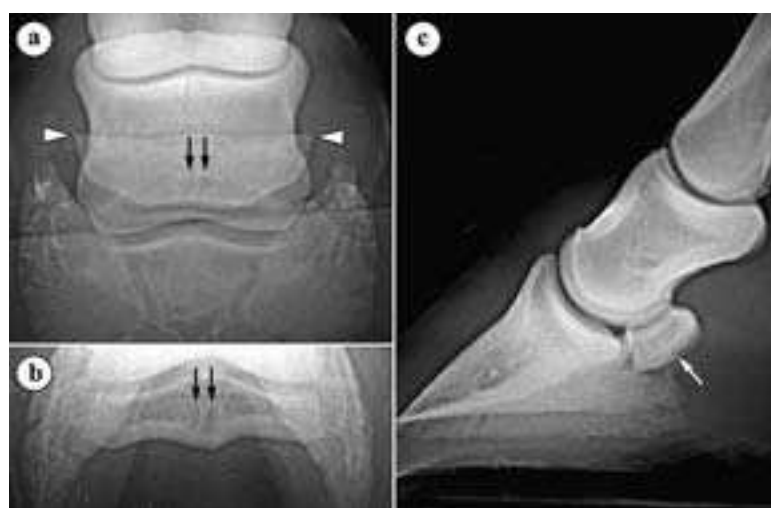

Fig. 12.7.1. Radiographs of the distal limb of a 5 years quarterhorse mare with podotrochleosis; three different exposures: a) Oxspring exposure: knobby, enlarged sesamoid canals (arrow) and drawn-out extensions at the lateral borders of the distal sesamoid bone (arrowhead), b) Tangential (palmaroproximal – palmarodistal) exposure: enlarged sesamoid canals (arrow), c) Lateral (latero-medial) exposure: slight degree of concavity in the region of the distal scutum (gliding surface for the deep flexor tendon) (arrow). (Radiographs: Klinik für Orthopädie bei Huf- u. Klautentieren, Veterinärmed. Univ. Wien)

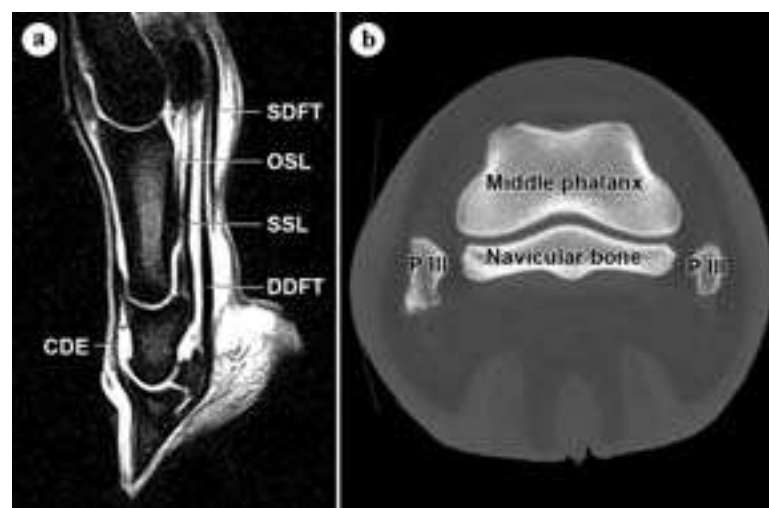


Fig. 12.7.2. a) Nuclear magnetic resonance image: distal limb, paramedian longitudinal section, b) CT scan: cross-section at the level of the distal sesamoid bone. CDE: tendon of the common digital extensor muscle, DDFT: deep digital flexor tendon, OSL: oblique sesamoid ligament, P III: palmar process of the distal phalanx, SDFT: superficial digital flexor tendon, SSL: straight sesamoid ligament. (Courtesy of Prof. Dr. W. Henninger, Universitätsklinik für Radiologie, Veterinärmed. Univ. Wien)

[164] [165] [166] Possible conservative therapy consists of an orthopedic horse shoeing including hoof trimming, systemic and local medication as well as an adequate exercise regime. [167] [168] [169] Recently also the application of shock-wave-treatment (extracorporeal shock wave therapy) is recommended. [170] Beyond that, also different surgical procedures are described. To promote perfusion of the digit, perivascular sympathectomy (section of sympathetic nerve fibers) in the region of the medial or lateral palmar digital artery and vein, in combination with a fasciotomy, has been proposed. [99] As a further possibility, desmotomy of the ligaments between the long pastern bone and the navicular bone is described. [171] [172] With a positive result from anesthesia of the palmar digital nerves (TPA 2), neurectomy of the lateral and medial palmar digital nerves at the pastern can be performed as a final measure. [121] [168]

14.1. Synovial structures on the Thoracic Limb

Besides the diagnostic nerve anesthetics, also often intrasynovial anesthetics of joints or certain synovial sheaths of synovial bursae are performed in examination for lameness. For this reason the most often used sites of injection of these structures are important for diagnosis of lameness. Also, for the implementation of an endoscopic examination (arthroscopy, tendovaginoscopy or bursoscopy) knowledge of the anatomy of the concerned structure is a basic precondition. Besides that, the synovial structures are of a special clinical importance, because the lesions in the region of these structures are always connected to a risk of its infection and by this to the necessity of an immediate adequate therapy. A solid knowledge of the exact localization and extension of the synovial spaces is for this reason also essential for the evaluation of lesions.

14.2. The shoulder joint is covered by relatively strong muscles. For this reason, the danger of an infection caused by a wound is more rare. But also non-infectious inflammation of the shoulder joint is relatively rarely observed. Occasional causes of lameness are lesions of the articular cartilage or of the subchondral bone, related to a disorder of endochondral ossification (**osteochondrosis**). [173] [108] In radiographs a flattening or indentation of the bony contour or of isolation of a cartilage-bone-chip is visible. Such alterations can be observed both in the region of the glenoid cavity of the scapula and the humeral head. Usually the caudal half of the joint is involved. [173] [108] Moreover, cyst-like defects may occur in the subchondral bone. These are usually localized at the transition between the middle and caudal thirds of the glenoid cavity of the scapula. [108] Therapy can be conservative [108] or surgical (arthroscopic curettage of the altered cartilage or removal of the osteochondral fragment [173]).

Especially in Shetland ponies, there occasionally appears also a **dysplasia** (defective development) of the shoulder joint, which is accompanied by subluxation and a secondary degenerative arthri-

tis. [174] [175] As collateral ligaments are absent in the shoulder joint, the insertional tendons of the subscapularis, infraspinatus and supraspinatus muscles are responsible for the collateral stability of the joint. [176] Collateral instability of the shoulder joint can be caused by a lesion of the nerves of the brachial plexus and the accompanying loss of function of the muscles, which act as a replacement for the collateral ligaments.

Injection of the shoulder joint for intraarticular anesthesia or local therapy is performed cranial to the tendon of the infraspinatus muscle, which is easily palpable. To do this, the needle is introduced at the depression between the cranial and caudal parts of the greater tubercle of the humerus and advanced about 6–8 cm in a caudomedial and slightly distal direction (in a direction toward the elbow of the opposite side; Fig. 14.2., 1). [114] [177] If a second access is necessary to flush the joint, the shoulder joint can be injected additionally about 10 cm caudal and 4 cm distal to the site just described. The needle is directed 20° dorsally and to a depth of 8 cm. [177] Anesthesia of the shoulder joint is obtained with 25–30 cc of a 2% local anesthesia solution [114], in which case the injection of a larger volume (more than 10 cc) may, owing to diffusion, lead to a paresis of the adjacent suprascapular nerve. [177]

For **arthroscopy of the shoulder joint**, access is as a rule also cranial to the tendon of the infraspinatus and directly proximal to the depression between the cranial and caudal parts of the greater tubercle of the humerus. [178] [179] The needle is introduced at an angle of about 25° in a caudodistal direction. [179] The second access for the instruments will be chosen depending on the location of the lesion. Usually a caudolateral portal for the instruments (about 6 cm caudal and 4 cm distal to the arthroscopic portal) is utilized. [178] [179] Sometimes also a cranial access of the instruments directly distal to the arthroscopic portal is possible. An alternate access is located about 1 cm caudal to the tendon of the infraspinatus (between the infraspinatus muscle and the teres minor muscle) muscle. Access for the instruments is, in this case, about 2–4 cm caudal to the arthroscopic portal. [179]

14.3. Pathologic changes in the region of the elbow joint are likewise relatively seldom the cause for lameness. Occasionally, **cyst-like subchondral defects** occur, which are usually located medially in the proximal epiphysis of the radius. [180] [181] Osteochondral changes or traumata are discussed as the cause. [182] Besides conservative therapy, a surgical procedure in the form of an extra-articular curettage of the subchondral lesion is described. [180]

In contrast to the shoulder joint, the lateral part of the elbow joint is covered only by little soft tissue. For this reason, in the event of lacerations of the elbow joint region, the joint is relatively easily




Fig. 14.2. Injection of the shoulder joint (1) and the intertubercular bursa (2). (Courtesy of Institut f. Veterinär-Anatomie, Berlin)

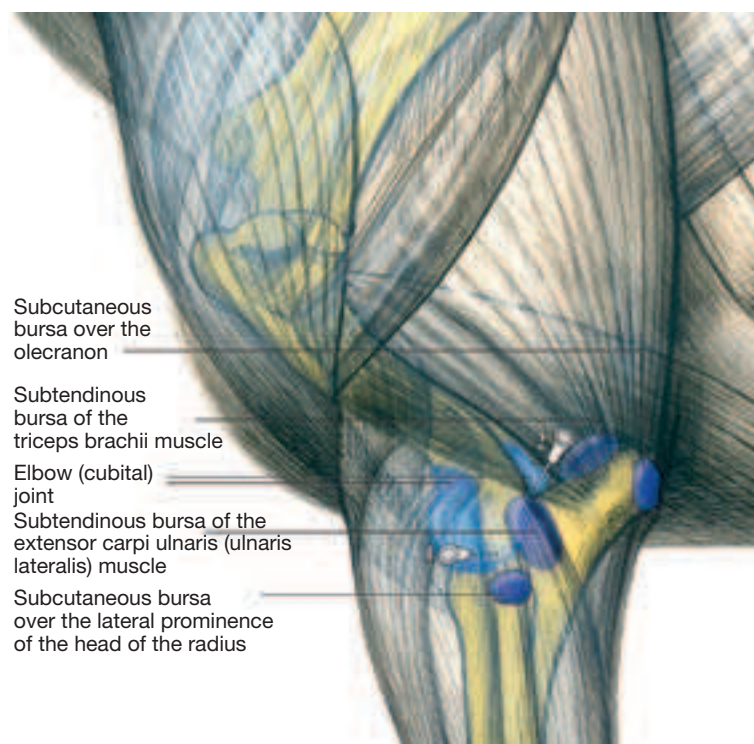


Fig. 14.3. Injection of the elbow joint: 1) cranial access, 2) proximalateral access. (Courtesy of Institut f. Veterinär-Anatomie, Berlin)

opened and can become infected. In such a case, a possible communication of the joint with the 5 cm long subtendinous bursa of the ulnaris lateralis muscle [183] as well as a shift of the skin over the articular region during movement of the limb must be taken into consideration, so that even a supposed distant wound may have a communication with the elbow joint. To examine for possible articular infection, the joint is penetrated and the synovia is examined cytologically.

Injection of the elbow joint is traditionally performed cranial to the lateral collateral ligament, which is found between the lateral epicondyle of the humerus and the tuberosity of the radius for the attachment of the ligament (both bony points are readily palpable). [177] [184] The needle is introduced about 2.5 cm cranial to the collateral ligament and about 3.5 cm proximal to the ligament's insertion on the radius. The skin is penetrated horizontally and the needle directed slightly caudally and advanced to a depth of 5–6 cm (Fig. 14.3. 1). [114] [177] Alternatively, the joint can also be penetrated by way of the proximolateral part of the caudal recess in the region of the olecranon fossa. To do this, the needle is introduced into the palpable depression between the olecranon and the lateral supracondylar crest of the humerus at an angle of about 45°. The needle is advanced mediolaterally and slightly cranially about 4–7 cm (Fig. 14.3. 2). [114] [183] For intra-articular anesthesia of the elbow joint, about 20–25 cc of a 2% local anesthesia solution is injected. [114] The anesthesia of the elbow joint that was performed in former times by way of the subtendinous bursa of the ulnaris lateralis muscle is very uncertain owing to the fact that the two synovial structures communicate only in about one-third of horses. [183]

For **arthroscopy of the elbow joint**, access can be caudomedial, between the flexor carpi radialis muscle and the flexor carpi ulnaris muscle, where a large part of the **caudal articular surfaces** of the humerus, radius and ulna can be demonstrated. [185] A second access for the instrumentation is possible caudal and slightly proximal to the arthroscopic portal. To avoid injury to the ulnar nerve as well as the collateral ulnar artery and vein, access should not be proximal to the articular cavity of the humeroradial joint. [185] Alternatively, access to the caudal region of the elbow joint is also possible laterally by way of the large synovial outpouching in the olecranon fossa. [179] To demonstrate the **cranial articular surface** of the humeral condyles, arthroscopic access can be gained directly cranial to the lateral collateral ligament. In this case, access for instrumentation is located in the region of the belly of the extensor carpi radialis muscle or of the common digital extensor muscle. [185]

14.4. The carpal joint is composed of three horizontally arranged joints. The proximal joint (**antebrachiocarpal joint** or **radiocarpal joint**) is located between the radius and the proximal row of carpal bones and permits flexion of about 95°. [186] The middle joint (**mediocarpal joint**, in clinical usage also **intercarpal joint**) is between the proximal and distal row of carpal bones and can be flexed about 45°. [186] It communicates always with the distal joint (**carpometacarpal joint**), in which case the synovial spaces—among others—communicate between the third and fourth carpal bones. A communication of the intercarpal joint with the antebrachiocarpal joint is rare. [187] The carpometacarpal joint has palmarodistal outpouchings, which are present laterally and medially between the corresponding splint bone and the cannon bone. They extend about 2.5 cm in a distal direction. [187]

Besides the chip and slab fractures in the region of the carpus, degenerative changes of the carpal joints are the most frequent problems. They are usually associated with an increased filling of the joint, which can be most easily palpated on the flexed limb medially and laterally beside the tendon of the extensor carpi radialis muscle. [31]

In the carpal joint region, also a great number of synovial sheaths and bursae are found (Fig. 14.13.). These can also be excessively filled due to inflammatory processes and have to be considered in the differential diagnosis. Also, with injuries in the carpal region, which are accompanied by effusion of synovia, an opening of the carpal joint, of the synovial sheaths or of the synovial bursa must be considered in the differential diagnosis.

For **injection of the antebrachiocarpal joint and the intercarpal joint**, the named joints are flexed, in which case they open dorsally. Medial to the insertion tendon of the extensor carpi radialis muscle or between this tendon and the tendon of the common digital exten-

sor muscle, both joints are palpable as a depression. The needle is inserted in this depression perpendicular to the skin and advanced into the particular joint (Fig. 14.4., 1/2). Care must be taken for the tendons and their tendon sheaths. [114] [184] An additional access to both joints is possible by way of the corresponding **palmarolateral recess**. [114] [188] The corresponding articular outpouching of the antebrachiocarpal joint extends proximal to the accessory carpal bone and lies directly cranial to the carpal synovial sheath, which in case of increased filling of these synovial structures can easily lead to mistakes. [114] Injection of the joint is performed between the readily palpable tendon of the lateral digital extensor muscle and the tendon of the ulnaris lateralis muscle, directly proximal to the accessory carpal bone (section 14.4., 3). [114] Alternatively, the injection can also be performed farther distal, about the level of the middle of the accessory carpal bone. [188] At this site, a slight depression is palpable between the distal radius and the ulnar carpal bone into which the needle is introduced perpendicular to the skin (section 14.4., 4.). [114] [188] In doing this, care must also be taken for the surrounding tendons and tendinous sheaths. The palmarolateral recess of the intercarpal joint is located about 2–2.5 cm farther distal between the palmar border of the ulnar carpal bone and the fourth carpal bone (section 14.4., 5.). [114] [188] For anesthesia of each corresponding joint about 5–10 cc of a 2% local anesthesia solution is injected, [114] The carpometacarpal joint does not have to be injected individually, because it will be desensitized by anesthesia of the intercarpal joint owing to the communication of the synovial spaces. In doing this, consideration must be given to the fact that it is possible for a diffusion of anesthesia solution from the palmarodistal outpouching of the carpometacarpal joint to the origin of the suspensory ligament as well as to the palmar metacarpal nerves. This can lead to misinterpretations. [114] Moreover, diffusion processes have been described between the intercarpal joint and the antebrachiocarpal joint. [189]

For **arthroscopy of the antebrachiocarpal and of the intercarpal joint**, access is also medial to the terminal tendon of the extensor carpi radialis muscle or between that tendon and the tendon of the common digital extensor muscle. [179] [190] The palmar part of the joints is accessible via the respective palmarolateral articular recess, in which case, after filling of the joint, the instruments are introduced in the center. [179] Besides that, also an access to the antebrachiocarpal joint from caudomedial is described. [191]

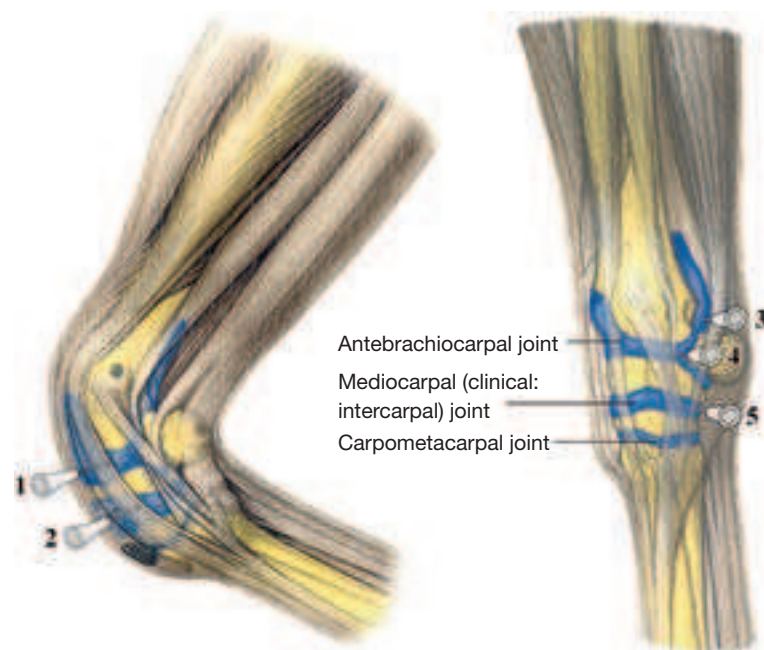


Fig. 14.4. Injection of the carpal joint: dorsal access into the antebrachiocarpal joint (1) or into the mediocarpal- (middle carpal-) joint (2), proximal (3) or distal (4) access into the palmarolateral recess of the antebrachiocarpal joint, (5) access into the palmarolateral recess of the mediocarpal- (middle carpal-) joint. (Courtesy of Institut f. Veterinär-Anatomie, Berlin)

14.5. The fetlock joint is a compound hinge joint, which permits a slight side-to-side movement only in extreme flexion. [176] In the weight-bearing limb, the joint is in hyperextension, in which the dorsal extension angle is about 140°. [152] To prevent excessive hyperextension of the joint, the fetlock joint is supported palmarly by different ligamentous and tendinous structures (so-called suspensory apparatus). [176]

The **collateral ligaments** of the fetlock joint consist each of two parts, which are well demonstrated sonographically. The somewhat more dorsally located superficial part is relatively thin and runs in a vertical direction. The deeper part is on the other hand obliquely distopalmarly oriented and attaches not only to the proximal phalanx, but also to the corresponding sesamoid bone. [192] Lesions of the collateral ligaments, which can arise from avulsion fractures of the proximal phalanx, are usually due to trauma and lead to an instability or luxation of the fetlock joint. [193] The joint capsule forms a dorsal and a palmar articular recess, in which case the dorsal recess extends proximally about 2 cm and the palmar recess about 4–5 cm proximally. With increased filling, the latter is palpable or even visible (so-called “windpuffs”) between the insertional branches of the suspensory ligament and the cannon bone (McIII). It must not be confused with the proximal part of the digital synovial sheath of the flexor tendons, which is palmar to the suspensory ligament. [176]

Diagnostic or therapeutic **injection of the fetlock joint** can be performed in the region of both articular outpouchings, in which case access to the **palmar recess** is the easier. The traditional proximal injection site lies between the cannon bone (McIII) and the suspensory ligament at the level of the “button” of the splint bone and proximal to the collateral ligament of the sesamoid bone, in which case the needle is advanced in a slightly distal direction (Fig. 14.5., 1). [188] [184] [194] Owing to the fact that at this site there are prominent villi of the joint capsule, which often cause an obstruction of the needle and, besides that, the danger of hemorrhage into the joint is relatively high, it would be better to tap the joint somewhat farther distally. [195] To do this, the fetlock joint is slightly flexed. The needle is inserted perpendicularly through the skin dorsal to the neurovascular bundle in the palpable depression between McIII and the lateral sesamoid bone and advanced through the collateral ligament of the sesamoid bone (Fig. 14.5., 3). [195] [188] Injection into

the dorsal joint sac can be lateral or medial to the extensor tendon at the level of the articular cleft. The needle is advanced horizontally under the extensor tendon (Fig. 14.5., 2). [188] For anesthesia of the fetlock joint, 10 cc of 2% local anesthesia solution is injected. [114]

For **arthroscopy of the fetlock joint** in the region of the dorsal articular outpouching, access is also medial and lateral to the tendon of the common digital extensor muscle, in which case, lateral access is directly through the lateral digital extensor tendon. For demonstration of the palmar parts of the joint, there is besides medial or lateral access possible in the center of the palmaroproximal articular recess. The instrument portal is installed either distal or proximal to the arthroscopic portal according to where the lesion is found. [190]

In athletic horses, inflammatory changes of the fetlock joint are relatively often associated with lameness. A possible cause is osteochondrotic lesions in the region of the articular cartilage or of the subchondral bone. These can be demonstrated radiographically as irregularities of contour or fragmentation and are usually located dorsally on the sagittal ridge of the cannon bone. [51] [52] Occasionally there also occur intra-articular fragments dorsoproximally or palmaroproximally on the proximal phalanx (chip-/Birkeland fractures, section 4.13.). [67] [61] [51] If lameness is present, usually surgical therapy (arthroscopic curettage of the altered articular cartilage or removal of fragments) is indicated. [61] [51] [52]

Subchondral cystoid defects are a further possible cause of lameness. These are mostly found on the weight-bearing surface of the medial condyle of the cannon bone. [196] Therapy can be arthroscopic or by extra-articular curettage (eventually with drilling of the subchondral bone [196] or by an additional transplantation of bone substance from the coxal tuber). [197]

A special form of arthritis of the fetlock joint is chronic proliferative synovitis (**villonodular synovitis**) which is characterized by a great increase in the synovial pads (localized duplicatures of the synovial membrane medial and lateral in the region of the dorso-proximal fixation of the joint capsule to the bone). Repeated trauma and irritations of the tissue as a result of hyperextension of the fetlock joint at high speed are considered to be the cause. A striking feature is chronic filling of the joint as well as typical radiographic changes in the form of an indentation in the region of the dorsodistal cannon bone (directly proximal to the sagittal ridge). Therapy can be performed conservatively or surgically (arthroscopic removal of altered tissue). [198] [199]

14.6. The pastern joint is a saddle joint, which—besides movement in the sagittal plane (to flex and extend)—also allows a slight passive side-to-side and torsion-movement (about 4°). [200] [176] The joint capsule forms a proximal palmar and dorsal recess. [176] Injection into the dorsal pouch of the pastern joint is performed lateral or medial to the extensor tendon about 1 cm distal to the attachment of the collateral ligament at the well palpable distal tubercles of the proximal phalanx. The needle is directed horizontally or slightly distally under the extensor tendon (Fig. 14.5., 4). [188] Alternatively, injection into the palmar recess of the pastern joint can be realized from lateral (Fig. 14.5., 5). [201] [188] To do this, dorsal to the neurovascular bundle, the depression between the palmar border of the proximal phalanx and the lateral branch of the superficial flexor tendon (proximal to its insertion at the flexor tuberosity) is palpated. At this depression proximal to the distal tubercles of the proximal phalanx, the needle is introduced and advanced into the joint pouch in a slightly distal direction. [201] Additional access is possible at the palmaroproximal border of the middle phalanx (directly proximal to the proximal tubercle of the middle phalanx); the needle is directed as nearly horizontally as possible. [188] For anesthesia of the pastern joint, 5–10 cc of 2% anesthesia solution is injected. [114]

Arthroscopy of the pastern joint is necessary only in rare cases. For this, access is in the region of the dorsal pouch of the joint, medially and laterally beside the tendon of the common digital extensor muscle. [179]

Arthrotic changes of the pastern joint (high ringbone) are usually observed bilaterally. They are relatively frequently the cause of lameness in athletic horses. [202] [203] Increased deposition of bone dorsally on the proximal middle phalanx and distally on the proximal phalanx are typical and radiographically visible (Fig. 4.13., b). In advanced cases, these may result in bridge-like formations and ankylosis (stiffening of the joint) and then they are usual-

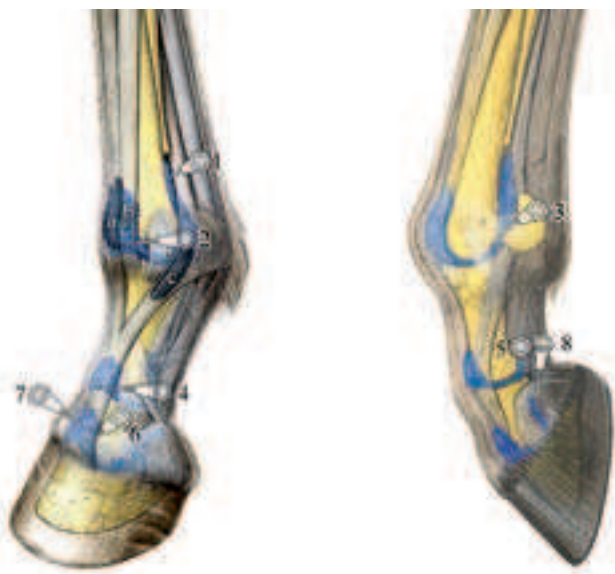


Fig. 14.5. Injection of the digital articulations: (1) proximal access into the palmar recess of the fetlock joint, (2) injection of the dorsal fetlock joint recess, (3) distal access into the palmar recess of the fetlock joint with the limb flexed, (4) injection of the dorsal pastern joint recess, (5) palmar access into the pastern joint, (6/7) injection of the dorsal coffin joint recess, (8) injection of the palmaroproximal coffin joint recess. **a:** subtendinous bursa of the common digital extensor muscle, **b:** subtendinous bursa of the lateral digital extensor muscle, **c:** bursa under the extensor branch of the suspensory ligament (interosseous muscle). (Courtesy of Institut f. Veterinär-Anatomie, Berlin)

ly also palpable and even visible. [204] Treatment depends on the degree of the disease. For advanced stages an arthrodesis (surgical stiffening of the joint by different procedures of osteosynthesis) is possible, [202] [205] [203] [206] in which case arthrodesis of the pastern joint of the pelvic limb is described as having a better chance of success than the thoracic limb. [205] [202]

14.7. The coffin joint is a compound saddle joint, which besides flexion and extension, has also a certain side-to-side movement and torsion movement (thoracic limb up to 15°, pelvic limb to 18°) that permit a compensation for irregularities of the ground. [207] [200] The joint capsule has a palmar and a dorsal pouch, [176] in which case the dorsal pouch, which is located under the tendon of the common digital extensor muscle, extends 1–2 cm proximal to the hoof capsule. With increased filling of the coffin joint it is palpable as a fluctuating swelling directly above the coronet. [111]

Especially in case of injuries in the dorsal region of the coronet, there may be an opening of the dorsal joint pouch and by this an infection of the coffin joint. Beyond that, also foreign bodies (nail) may enter via the solear surface of the hoof and lead to an opening of the joint in the palmarodistal recess. Here usually the deep flexor tendon and the distal sesamoid impar ligament (distal sesamoid–distal phalanx ligament) will be penetrated. [208]

Injection of the coffin joint for local treatment or intra-articular anesthesia is usually performed in the region of the **dorsal joint-pouch**. Here the skin is penetrated about 1.5 cm proximal to the coronet and 1.5–2 cm from the midline of the limb. The needle is advanced in a palmarodistal and axial direction into the articular pouch. (Fig. 14.5, 6.). [188] [112] Alternatively the joint may also be injected in the midline with the needle directed slightly distally (Fig. 14.5.7.). [114] [188] Further access is by way of the **palmaro-proximal recess**, in which the needle is introduced in the depression between the proximal border of the ungular cartilage and the palmarodistal border of the middle phalanx in a dorsodistal and axial direction (Fig. 1.5., 8). [209] [188] For anesthesia, maximally 6 cc of 2% local anesthesia solution is injected. [114] Because of the direct proximity to the navicular bursa and navicular bone, including ligaments of the navicular bone, a diffusion of the anesthetic solution to these structures is possible. [210] [189] [211] For this reason, anesthesia of the coffin joint is not entirely specific. [211] Also, diffusion of the adjacent palmar digital nerves is discussed, [112] which would explain the observed desensitization of the entire sole following anesthesia of the coffin joint. [212] [213]

Arthroscopy of the coffin joint is also possible in the region of the dorsal joint pouch. Access is 2–3 cm proximal to the coronet, directly beside the extensor tendon (about 2 cm lateral or medial to the midline of the limb). [214]

Because of the enormous biomechanical stress on the coffin joint (especially upon uneven ground or turning) the joint is relatively frequently subject to pathological changes. [207] In addition to inflammation of the coffin joint, also arthrotic changes (low ring-bone) that result in lameness are not rare. Radiographically demonstrable articular or periarticular increases in bone substance are typical. In advanced cases, proximal to the coronet, these form a prominence which is palpable or even visible. [204]

Occasionally there are also cystoid defects in the coffin bone, which usually communicate with the coffin joint and often are associated with a lameness. [215] Such lesions are usually found centrally in the proximal coffin bone and can be well demonstrated radiographically. [215] [216] Besides conservative therapy, a surgical procedure in the form of a curettage of the lesion (arthroscopic or extra-articular via a defect of the hoof wall) is described. [182]

14.8. The intertubercular bursa (bicipital bursa) is located between the intermediate tubercle of the humerus and the tendon of the biceps brachii muscle that rides on it. Inflammation of the synovial bursa may cause a typical shoulder lameness. **Injection** is performed from lateral, in which case the needle is introduced about 4 cm proximal to the distal border of the deltoid tuberosity of the humerus, between the biceps brachii muscle and the humerus in a proximomedial and slightly cranial direction. It is then advanced along the cranial margin of the bone (Fig. 14.2., 2). Alternatively, the cranial part of the greater tubercle of the humerus can serve as a landmark. Here, the injection site is about 3–5 cm distal and 6–7 cm caudal to this readily palpable bony point. For anesthesia of the bursa, 10–20 cc of 2% local anesthesia solution is injected. [114]

For **endoscopy of the intertubercular bursa**, the access is 2–3 cm

proximal to the deltoid tuberosity. A second access is possible 2–3 cm proximal to the cranial part of the greater tubercle of the humerus near the tendon of origin of the biceps brachii, in which case the instrument is introduced and directed distomedially. [217]

14.9. A subcutaneous olecranon bursa frequently arises over the olecranon tuber, often as a result of contusions (*e.g.*, by insufficient bedding or the pressure of a horseshoe while lying down). With inflammation, it usually becomes visibly enlarged (so-called “capped elbow”). [218]

14.10. Also, the precarpal subcutaneous bursa can be increasingly filled due to inflammation (hygroma), which as a rule can be traced to trauma in the region of the dorsal carpus. In a differential diagnosis, this has to be distinguished from an increased filling of the extensor tendon sheaths or a rather more rare synovial hernia of the intercarpal or antebrachio-carpal joint. [31]

14.11. The navicular bursa (podotrochlear bursa) is located between the navicular bone and the deep flexor tendon that rides over it (Fig. 14.11., a). It belongs to the complex of podotrochlea (see podotrochleosis, section 12.7). For **injection of the navicular bursa**, the projection of the navicular bone onto the side wall of the hoof serves as a landmark. This is located 1 cm distal to the coronet in the middle between the dorsal and palmar borders of the hoof capsule. [219] The needle is introduced on the palmar midline about 1 cm proximal to the coronet and advanced in the direction of the navicular bone until bone-contact is made (usually at a depth of 4–5 cm; Fig. 14.11., b). [219] This is best performed under radiographic control to avoid an erroneous injection of the adjacent coffin joint. [114] Alternatively, the needle may be introduced at the deepest place between the heels and advanced dorsodistally in the direction of the navicular bone. For anesthesia, 3–5 cc of 2% anesthesia solution is injected into the bursa. Owing to diffusion, certainly after 20 minutes a desensitization of the coffin joint is also possible. [189] [220]

For **endoscopy of the navicular bursa**, access is proximal to the ungular cartilage between the border of the deep flexor tendon and the neurovascular bundle, in which case, entry is dorsal to the deep flexor tendon in a distoaxial direction. In this way, the synovial membrane of the synovial bursa, the insertion of the navicular ligaments, the palmar or plantar surface of the navicular bone as well as the dorsal surface of the deep flexor tendon can be demonstrated. [221]

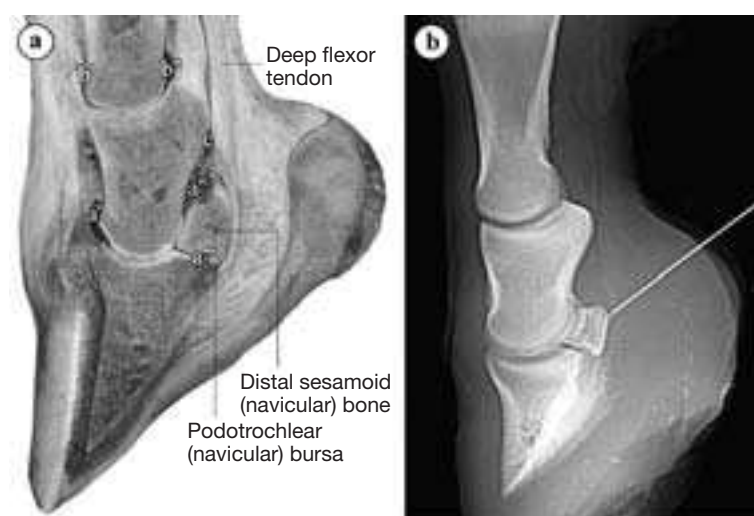


Fig. 14.11. a) Longitudinal section through the distal limb to demonstrate the podotrochlea. Observe the close relationship of the podotrochlear bursa to the palmar recess of the coffin joint and to the distal outpouching of the digital synovial sheath, b) Radiograph used to monitor the position of the needle in injection of the podotrochlear bursa.

a: coffin joint (**a'**: dorsal recess, **a''**: palmaroproximal recess, **a'''**: palmarodistal recess), **b:** pastern joint (**b'**: dorsal recess, **b''**: palmar recess), **c:** digital synovial sheath. (Courtesy of Dr. Patan)

14.12. An increased filling of the **synovial sheath of the common digital or lateral digital extensor muscle** in the carpal region occurs occasionally in newborn foals or foals a few days old, in which case especially immature foals are involved. The cause is as a rule a rupture of the corresponding extensor tendon. With the typical swelling, a knuckling over (non-physiological flexure of the fetlock joint) is usually observed when the limb is advanced. [154]

14.13. The **carpal flexor sheath** surrounds the superficial and deep flexor tendons in the carpal canal and, with an increased filling, is visible proximal and distal to the flexor retinaculum. [114] **Injection of the synovial sheath** is possible caudolaterally, about 5 cm proximal to the accessory carpal bone between the tendons of the lateral digital extensor muscle and the ulnaris lateralis muscle (Fig. 14.13., 1). [114] [112] Because the palmarolateral recess of the antebrachiocondylar joint is in the immediate neighborhood at this site, there is always the danger of an unintentional articular injection. [114] Alternatively, the synovial sheath can be injected directly distal to the flexor retinaculum, in which case the needle is introduced between the lateral splint bone and the deep flexor tendon in a slightly proximal direction (Fig. 14.13., 2). [114] [112] For anesthesia of the carpal synovial sheath, 10–15 cc of 2% local anesthesia solution is necessary. [114] Owing to diffusion, also here a desensitization of the palmar or palmar metacarpal nerves is possible, which can lead to misinterpretation. [112]

Endoscopy of the carpal flexor sheath is performed on the slightly flexed carpal joint in the lateral forearm region. The arthroscopic portal is located about 3 cm proximal to the distal epiphysis of the radius and about 2.5 cm caudal to the radius between the tendons of the lateral digital extensor and ulnaris lateralis muscles. [222] Access for the instrumentation is distal to this point. Among other things, the radial head of the deep digital flexor muscle, the proximal check ligament (accessory ligament) of the superficial digital flexor muscle, the distal radial epiphysis, the tendons of the superficial and deep digital flexor muscles, the accessory carpal bone as well as the adjacent articular pouches of the antebrachiocondylar and intercarpal joints can be demonstrated. [223] [222]

The other tendon sheaths located in the carpal region, which have to be considered in differential diagnosis in case of injuries in the carpal region, are shown in Fig. 14.13.

14.14. The (about 14–20 cm long) **fetlock flexor tendon sheath (digital synovial sheath)** surrounds mainly the deep digital flexor tendon and only partially the superficial digital flexor tendon. [224]

[134] It begins proximally at the level of the button of the splint bone and reaches distally to the middle of the pastern bone. [224] At the latter site, it borders directly on the navicular bursa and the coffin joint (Fig. 14.11., a). [134] [225] With increased filling, the synovial sheath is visible proximal to the palmar annular ligament between the suspensory ligament and the deep flexor tendon or distal below and at the sides of the four-cornered plate formed by the proximal digital annular ligaments. [224] Because an expansion of the synovial sheath is not possible in the region of the palmar annular ligament, an indentation can be observed here in lateral view (see annular-ligament-syndrome, section 10.4.). Proximal to the fetlock joint, the superficial flexor tendon forms within the synovial sheath a ring-like sleeve around the deep flexor tendon (*manica flexoria*), which is very well demonstrated sonographically. [225] Especially with filling of the tendon sheath, proximal to the manica flexoria, the lateral and medial attachment of the deep flexor tendon to the wall of the tendon sheath (so-called mesotendon) is easily recognized sonographically. [225] In the fetlock region the deep flexor tendon is dorsally connected with the wall of the tendon sheath (*vinculum tendinis*), which likewise with increased filling can be well demonstrated sonographically. [226]

Injection of the fetlock flexor tendon sheath (digital synovial sheath) is possible in the proximolateral pouch about 2 cm proximal to the sesamoid bones between the suspensory ligament and the deep flexor tendon or between the deep and superficial flexor tendons (Fig. 14.14., 1). [112] Because at this site a distinct hypertrophy of the villi of the synovial membrane can be present, obtaining synovial fluid is sometimes difficult. [114] An alternate site of injection is in the midline of the pastern in the region of the distal blind sac, which is bounded by the four-cornered plate of the proximal digital annular ligaments and the distal digital annular ligament (Fig. 14.14., 2). [114] With a slight filling of the tendon sheath, this injection is also difficult, for which reason a further access was described. Here, with the fetlock joint slightly flexed, the needle is inserted at the level of the middle of the sesamoid bone, palmar to the neurovascular bundle between the sesamoid bone and the flexor tendons nearly perpendicularly through the skin and advanced through the palmar annular ligament in the direction of the interse-samoid region to a depth of 1.5–2 cm (Fig. 14.14., 3). [227] For anesthesia of the digital synovial sheath, 10–15 cc of 2% anesthesia solution is injected. [114] Because of diffusion, here also a desensitization of the medial and lateral palmar digital nerves is possible, which may lead to misinterpretations. [112]

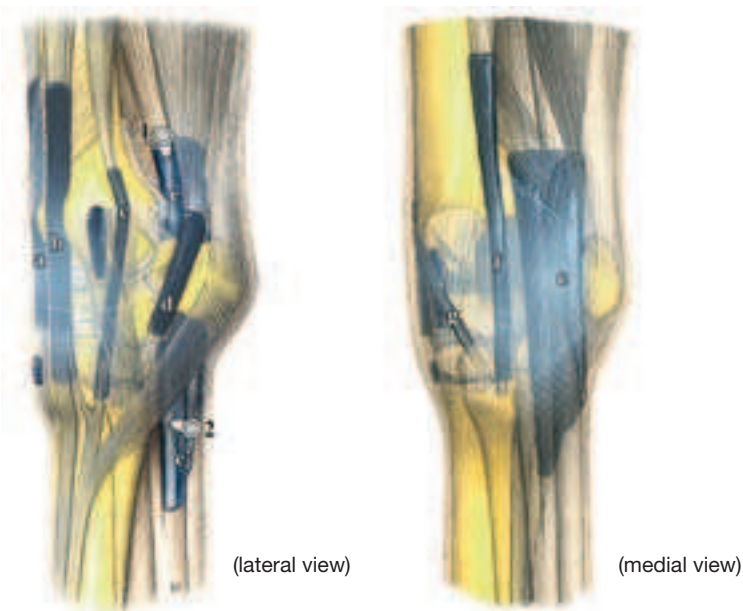


Fig. 14.13. Tendon sheaths and synovial bursae in the carpal region.

a: tendon sheath of the extensor carpi radialis muscle, **b:** tendon sheath of the common digital extensor muscle, **c:** tendon sheath of the lateral digital extensor muscle, **d:** tendon sheath of the extensor carpi ulnaris (ulnaris lat.) muscle, **e:** carpal flexor synovial sheath with proximal (1) and distal (2) sites of injection, **f:** tendon sheath of the flexor carpi radialis muscle, **g:** tendon sheath of the abductor pollicis longus (oblique carpal ext.) muscle. (Courtesy of Institut f. Veterinär-Anatomie, Berlin)

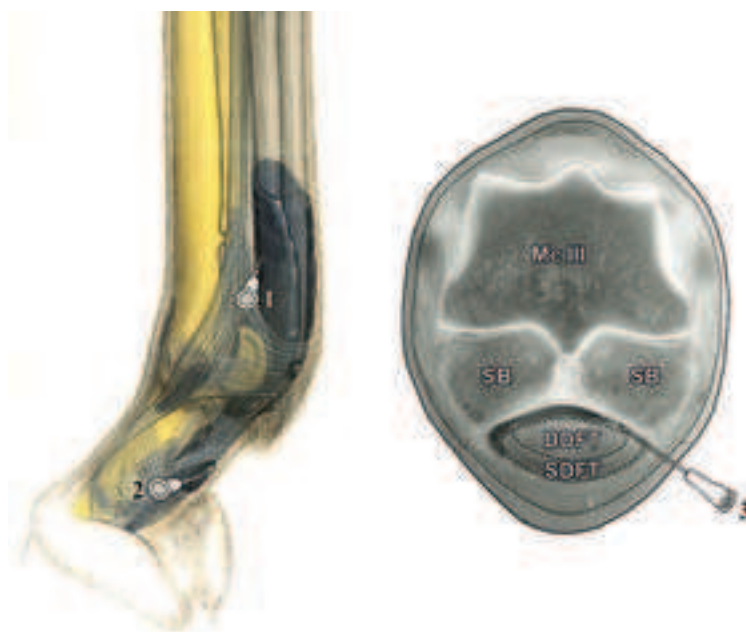

Fig. 14.14. Injection of the digital synovial sheath: **1)** proximal access, **2)** access to the distal, blind, end, **3)** injection at the middle of the proximal sesamoid bones. McIII Third metacarpal (cannon) bone, **DDFT:** deep digital flexor tendon, **SB:** sesamoid bone, **SDFT:** superficial digital flexor tendon. (Courtesy of Institut f. Veterinär-Anatomie, Berlin)

For **endoscopy of the digital synovial sheath**, access is at the proximal border of the palmar annular ligament; [228] a second access is possible directly distal to the palmar annular ligament. [229] Here entrance into the synovial sheath is at each border of the superficial digital flexor tendon about 1–2 cm palmarly from the neurovascular bundle. [229] [225] In this manner, both the region between the palmar annular ligament and superficial flexor tendon as well as the region between superficial and deep flexor tendons can be inspected. [225]

Pelvic Limb

BIANCA PATAN

16.1. For the fusion of the **epiphyses and apophyses** of the pelvic limb, basically, the same holds as for the thoracic limb. Closure of the epiphyses of the pelvic limb is given in Fig. 16.1. Epiphyseal fractures are most often located in the region of the proximal and distal growth plates of the femur and tibia, [4] [5] as well as distally on the cannon bone (Mt III). [4] One of the most frequent angular limb deformities of the pelvic limb is *tarsus valgus*, which how-

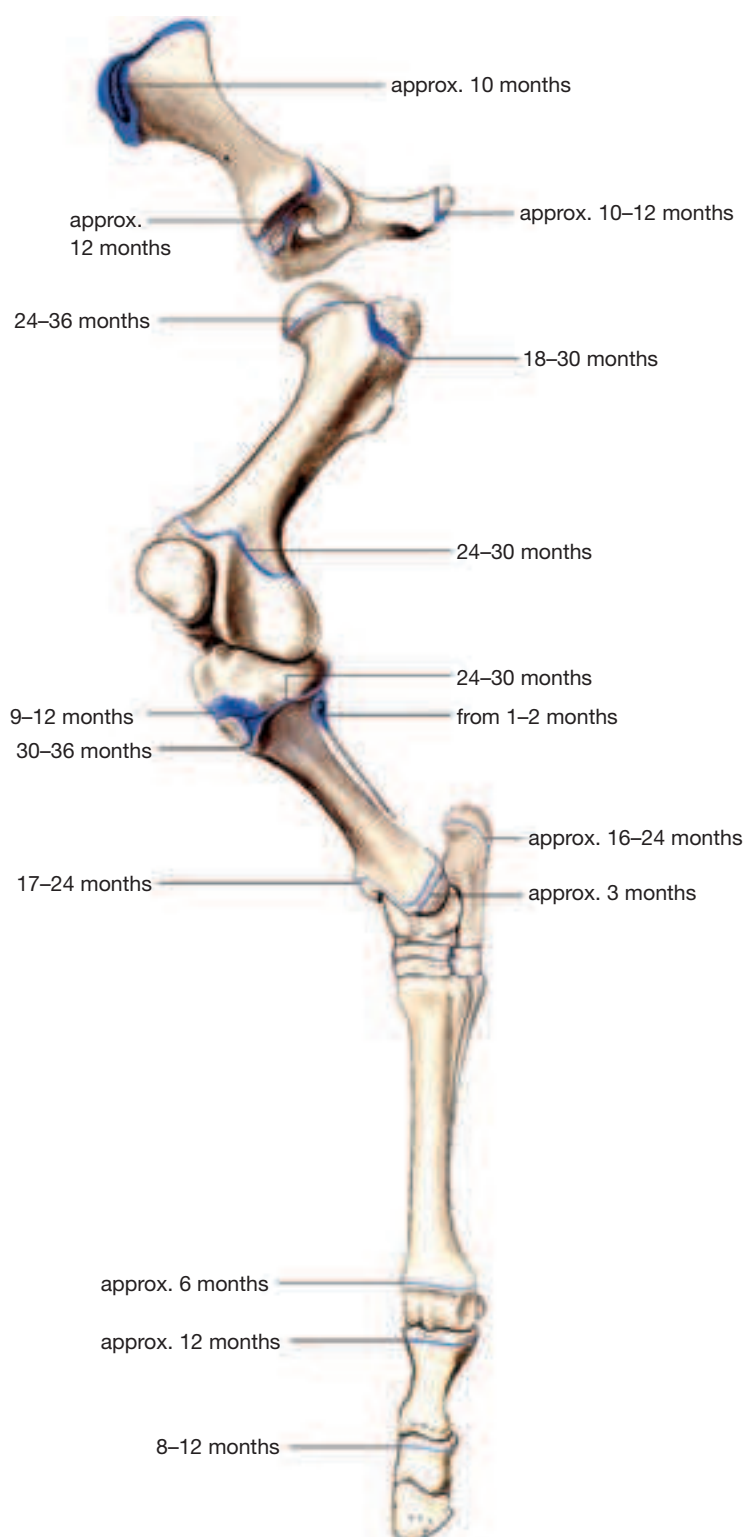


Fig. 16.1. Apophyseal and epiphyseal lines of fusion of the pelvic limb of the horse (closure of the growth plates after Butler *et al.*, 2000). (Courtesy of Institut f. Veterinär-Anatomie, Berlin)

ever is observed much more rarely than *carpus valgus* (cause and therapy, see *carpus valgus*, section 4.1.). *Tarsus varus* deformities are on the other hand rather rare. A special form is the so-called “windswept foal”, in which on the one pelvic limb a *tarsus valgus* and on the other a *tarsus varus* is present. Another relatively frequent deviation of the axis of the pelvic limb is the varus position at the fetlock joint, where usually the distal epiphyseal growth plate of Mt III, more rarely the proximal one of the proximal phalangeal bone is involved. Valgus deformities of the fetlock joint are rather rare. With surgical correction of limb deformities of the fetlock joint it is to be noted that in this region the epiphyses close much earlier than the distal epiphysis of the radius or of the tibia. [8]

16.2. With respect to **pelvic fractures**, two different forms can be differentiated according to the location of the fracture lines. Fractures at the pelvic border (blow-up fractures of the tuber coxae, ischiadic or sacral tubers) are usually accompanied by a slight to moderate lameness of the pelvic limb and heal usually within 3–4 months. On the other hand, pelvic ring fractures (*e.g.*, symphyseal fractures) result in a severe lameness or the horse is unable to rise. Here the pelvis fractures usually at several sites because of its configuration as a relatively rigid ring. Such fractures are always associated with the danger of rupture of blood vessels, which may result in a greater blood loss. If the acetabulum is not involved in the fracture, healing can also take place with conservative treatment. With acetabular fractures, a severe arthrosis of the hip joint (coxarthrosis) must be expected and with this a permanent lameness. Fractures of the pelvic symphysis in large horses are untreatable. [230]

Also, spontaneous stress fractures of the wing of the ilium occur occasionally in young thoroughbreds in training (especially in hurdle-racehorses). If the dorsal surface is involved, then the fracture can occasionally be demonstrated sonographically; otherwise, to make the diagnosis, scintigraphy is the procedure of choice. [231]

16.3. For the **femur**, occasionally fractures of the **third trochanter** are observed, fewer of the **greater trochanter**, in which the fracture fragments are usually displaced owing to the pull of the attaching musculature. Sometimes such fractures can be demonstrated sonographically; besides that, scintigraphic examination is valuable in pointing to the diagnosis. [231]

Especially in foals there occasionally occur diaphyseal fractures, which frequently exhibit several fracture lines. The success rate of the surgical therapy by suitable osteosynthetic procedures depends on the age or the weight of the foals. [232]

Moreover, sometimes avulsion fractures occur in the region of the **origin of the peroneus tertius muscle and long digital extensor muscle** at the lateral femoral condyle. [233] [234] This chiefly involves young horses in which the bone tissue is still weakly developed. On the other hand, in older animals rather a rupture of the peroneus tertius muscle in its middle is observed. [233] The therapy is usually surgical, in which, depending on its size, the fracture fragment is removed arthroscopically or fixed by internal fixation. [233] [234]

16.4. The **medial ridge of the femoral trochlea** is distinctly larger than the lateral and has a nose-like bulge upon which the patella can hook.

16.5. Fractures of the **patella** usually have a traumatic origin and are especially often observed in show-jumpers in which the horse has collided with an obstacle in the stifle region. [235] Sagittal fractures of the medial part of the patella occur most often. This involves the patellar cartilage and with this the attachment of the medial patellar ligament, in which an involvement of the femoropatellar joint is usually also present. [235] [236] Beyond that, also transverse or crush fractures or fractures of the *basis patellae* may occur. [236] Especially fractures of the apex are described in connection with desmotomy of the medial patellar ligament (see proximal fixation of the patella, section 24.1). [231] Conservative therapy is possible in case of a fracture without involvement of the joint or with smaller, non-dislocated fragments. [236] On the other hand a surgical approach is indicated where fragments up to the size of one quarter of the patella can be arthroscopically or arthrotomically removed. [235] [236] For larger fracture-fragments, internal fixation is necessary. [237]

16.6. Besides traumatic fractures of the **tibia**, especially in two year old thoroughbreds and trotters in training, incomplete stress or fatigue fractures (fissures) also occur. [16] [238] In young thoroughbreds often the caudolateral corticalis of the middle or distal diaphysis is involved, [15] [16] but also such fractures are not rarely observed proximolaterally or proximocaudally. [15] [238] On the other hand, stress fractures in trotters are almost exclusively in the middle region of the diaphysis. [238] Because the fissure lines often are not radiographically demonstrable, investigation by scintigraphy is the method of choice to find the diagnosis. [231] [15]

Occasionally, also traumatic intra-articular fractures are observed in the region of the **lateral malleolus** of the tibia. Therapy is surgical, in which case the fracture-fragment is usually arthroscopically removed. [239]

16.7. The **intercondylar eminence** of the tibia has two prominences that are well demonstrated on radiographs. The medial tubercle is the more prominent and more frequently involved in fractures than the lateral (Fig. 16.7., b). Such fractures are sometimes seen in association with lesions of the cranial cruciate ligament, which attaches cranial to the intercondylar eminence. Therapy depends on the size of the fracture-fragment (arthroscopic removal or internal fixation). [240] [241]

16.8. Owing to the exposed position of the **tibial tuberosity**, trauma in this region (e.g., by collision with an obstacle during jumping) may easily result in a fracture. The fracture-fragment is often displaced proximocranially by the pull of the inserting middle patellar ligament (terminal tendon of the quadriceps femoris muscle). [243] The femoropatellar joint is not usually involved. In young horses (less than 3 years), the growth plate of the tibial tuberosity, which is not yet closed, must be considered in the differential diagnosis (Fig. 16.7., a). In fractures without joint involvement, therapy can be conservative; otherwise, a surgical approach is indicated (internal fixation or removal of smaller fracture-fragments). [243]

16.9. The **fibula** often has several ossification centers, between which a radiographically demonstrable split (radiolucent area) may persist (Fig. 16.7., b). Such translucent lines must not be confused with a rather rare fracture of the fibula. [244] In most horses the distal fibula is reduced. Its distal epiphysis corresponds to the lateral malleolus of the tibia, which thus has its own ossification center. [3] In some pony breeds, a complete fibula (**fibula completa**) is developed in an isolated case. Such a malformation occurs often combined with flexural limb deformities or angular limb deformities (especially *tarsus valgus*). [17]

16.10. With respect to **incomplete ossification** of the tarsal bones principally the same is valid as for that of the carpal bones, in which on the pelvic limb the **central tarsal bone** and the **third tarsal bone**

are especially involved (Fig. 16.10). [27] Stress on the insufficiently ossified tarsal bones may result in a collapse and consequently in a wedge-like deformity in the dorsal^a region. Sometimes there also appears fragmentation of the bones concerned. [23] [27] Such form changes of the tarsal bones are connected usually to limb deformities (*tarsus valgus* or cow-hocked). [245] [23]

16.11. Fractures of the tarsal bones are sometimes hard to demonstrate owing to the complex radiography (Fig. 16.11.). Most often slab fractures are present (but distinctly more rarely than on the carpus), which are usually located dorsolaterally on the **third tarsal bone** and **central tarsal bone**. [246] [247] Thoroughbreds and trotters are mainly involved, occasionally also quarterhorses. [248] A wedge-shaped conformation of the bone is considered a predisposing factor. In young thoroughbreds, this is relatively frequently observed in the dorsolateral region of the third tarsal bone. [249]

^a Remarks concerning the designation of direction on the pelvic limb: Corresponding to the relations on the forelimb, in the region of the distal limb (up to and including the tarsus) the terms “dorsal” or “plantar” (toward the sole of the foot) are used in place of the designations “cranial” or, respectively, “caudal.”

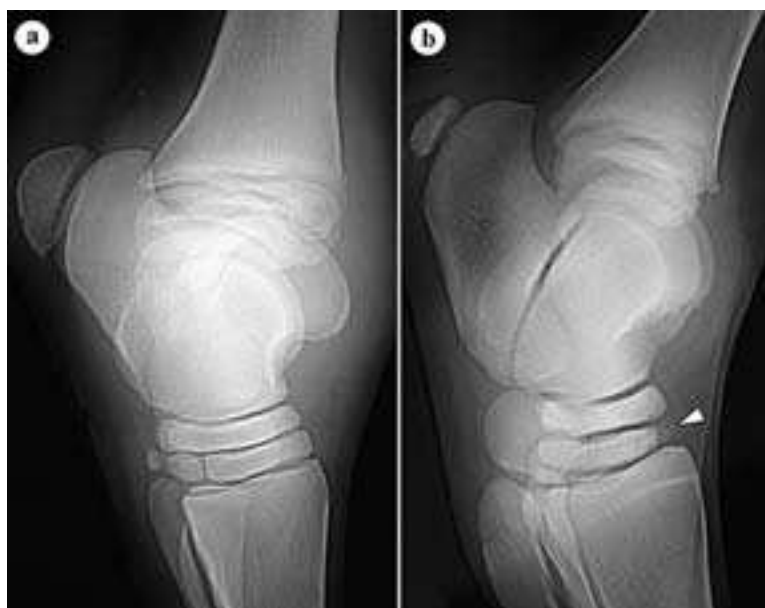

Fig. 16.10. a) Physiologic development of the tarsal bones of a 13 days old warmblood foal, b) Incomplete ossification of tarsal bone III (arrowhead) of a 14 days old warmblood foal. (Radiographs: Klinik für Orthopädie bei Huf- u. Klauentieren, Veterinärmed. Univ. Wien)

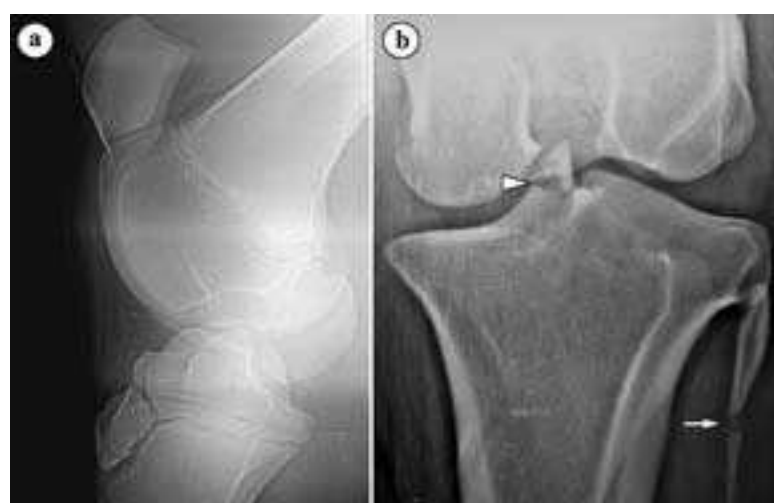

Fig. 16.7. a) Growth plate lines of fusion in the stifle joint region of a 6.5 months old warmblood foal, b) Fracture of the intercondylar eminence of the tibia (arrowhead), fibula with radiolucent line (arrow) between separate ossification centers, 13 years Shetland pony. (Radiographs: Klinik für Orthopädie bei Huf- u. Klauentieren, Veterinärmed. Univ. Wien)

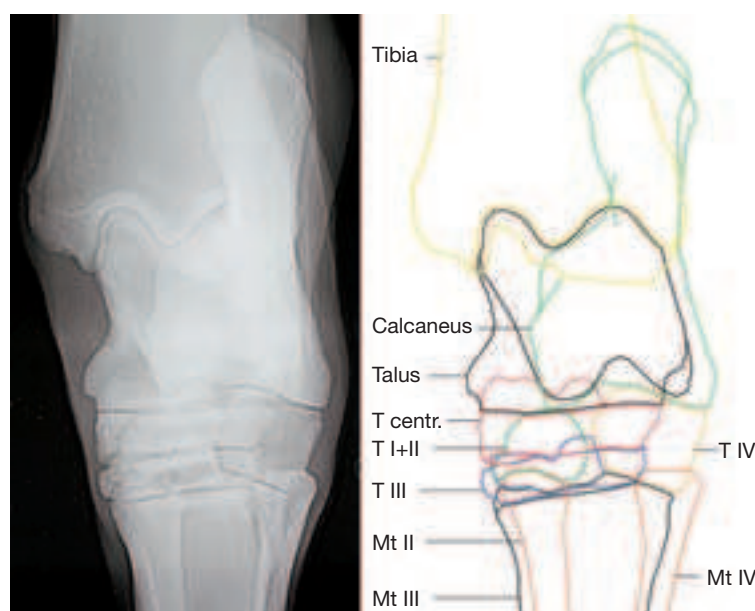


Fig. 16.11. Tarsal joint of an adult horse (dorsoplantar radiograph) with schematic representation of the individual bones. **Mt II – IV:** metatarsal bones II – IV, **T I+II, III – IV:** tarsal bones I+II, III – IV, **T centr:** central tarsal bone. (Courtesy of Klinik für Orthopädie bei Huf- u. Klauentieren, Veterinärmed. Univ. Wien)

[250] Because in cases of conservative therapy, secondary degenerative changes are to be expected in adjacent joints (tarsometatarsal-, distal or proximal intertarsal joints), especially in racehorses a surgical therapy (internal fixation) is recommended. [246] [247]

16.12. Fractures of the **talus** and **calcaneus** are altogether rather rare and mostly brought about by trauma. [251] To be sure, in thoroughbreds and trotters, incomplete sagittal fractures of the talus occasionally occur. These usually start from the proximal articular surface and are located between the ridges. [252]

Occasionally there occur rounded, accessory bone pieces plantarly at the proximal end of the trochlea of the talus (**trigonal bone of the tarsus**) or distally at the medial ridge of the talus. These are to be regarded as rare anatomical variations. [253]

16.13. The **first and second tarsal bones** are ordinarily fused at the time of birth. [3] In some horses this fusion is incomplete, or even two independent bones are developed. [253]

18.1. An injury of the **obturator nerve** (e.g., as a result of a dystocia or pelvic fractures) may lead to a loss of function of the adductors of the pelvic limb. In case of unilateral damage the horses stand with the pelvic limbs widely spread; with bilateral damage the horses lie immovably with straddled pelvic limbs. [107]

18.2. The **gluteal muscles** can be utilized for **intramuscular injection**. The injection site is midway between the coxal tuber and the root of the tail and the needle is introduced in a craniodistal direction. [110]

A painful condition of the musculature (especially of the **accessory gluteal muscle**) in the region between the coxal tuber and the greater trochanter of the femur is designated as the “**gluteal syndrome**”. This is especially observed in trotters; athletic horses are also occasionally involved. The cause is not exactly known. Presumably the basis is a partial rupture of the muscle in the area of its origin on the wing of the ilium. [254]

18.3. Severe trauma in the hip, thigh or gluteal region as well as a deeply intramuscularly located abscess may lead to a paralysis of the **ischadic nerve**. The result is a loss of sensory and motor functions in the area of supply of the tibial and peroneal nerves, which have their origin from the ischiadic nerve. The affected limb can only be elevated and flexed to a slight degree. Besides this, a collapse of the hock joint is typical as well as a knuckling over of the fetlock joint (non-physiological flexure). [107]

18.4. If only the **tibial nerve** is injured, it may result in a loss of function of the extensors of the hock and flexors of the digits. As a consequence, the involved limb can be lifted, but weight bearing by the hock joint is not possible. Besides the collapse in the hock joint, a knuckling over of the fetlock joint is usually also observed. [107]

Anesthesia of the tibial nerve, which may be a part of the lameness examination, will be described with the nerve blocks of the pelvic limb (section 22.1., c).

18.5. An occasionally occurring abnormality of the gait of the pelvic limb is designated “**fibrotic/ossifying myopathy**.” It is characterized by fibrotic changes in the region of the flexor muscles of the stifle joint and is particularly observed in quarterhorses. [255] [256] The **semitendinosus muscle** is predominantly involved; more rarely, also the semimembranosus, gracilis or biceps femoris muscles. [255] [257] [258] Besides degenerative lesions, [259] trauma and infections (e.g., after intramuscular injections), [258] a cause that is also considered is an increased tension on the insertion of the semitendinosus muscle in case of an intensive stress on the pelvic limb (e.g., by sliding stops in western riding). [255] A typical clinical sign is a shortened forward phase in the stride, [256] in which the forward movement is abruptly broken off and the hoof is brought back to the ground after a short backward movement. [260] [231] Usually also a thickening in the area of insertion of the muscle involved is palpable. [256] [261] Sonographic investigation gives additional indications of altered areas within the musculature. [256] [261] As therapy, three different surgical procedures are described: myotomy or myectomy of the semitendinosus muscle (section or partial removal of the muscle at the level of the stifle joint and removal of intramuscular adhesions), [256] [261] tenoto-

my (section of its tibial insertion tendon) [257] [261] as well as myotenyotomy (section of muscle and tendon of insertion). [258]

The **thigh musculature** (semimembranosus or semitendinosus) like the rump musculature can be used for **intramuscular injection**. The injection site is midway between the ischiadic tuber and the back of the stifle. [110] A possible complication is the development of a “fibrotic myopathy.” [258]

18.6. In the region of the calcanean tuber, the tendon of the superficial digital flexor muscle is broadened to form the **calcanean cap**. [134] It is kept in position by tendinous bands, which are attached laterally and medially at the calcanean tuber. [262] [134] Damage to these bands may result in a luxation of the superficial digital flexor tendon, in which case usually a lateral displacement is observed. [262] Besides conservative therapy, also a surgical fixation of the calcanean cap is described. [262] [263]

18.7. Paralysis of the **peroneal nerve** (e.g., by an unfavorable position in anesthesia, trauma or tissue-irritating intramuscular injections) may lead to a loss of function of the flexors of the hock and extensors of the digit. A nearly complete loss of the angulation of the hock joint with maximal flexion of the digital joints is typical. With advance of the affected limb, the hoof is dragged on the ground. If the horse has to bear weight on the limb, then it stands on the dorsal region of the fetlock. [107]

For **anesthesia of the peroneal nerve**, see anesthesia of the pelvic limb [Fig. 22.1.1.).

18.8. The **peroneus tertius muscle** is discussed together with the passive stay-apparatus of the pelvic limb (section 24.2).

18.9. The **medial tendon of insertion of the tibialis cranialis muscle** is also designated the **spavin tendon**. It attaches medioplantarly on the fused first and second tarsal bones, occasionally on the medial splint bone (Mt II) and is underlain by a synovial bursa. [264] Sometimes inflammatory changes of the tendon or synovial bursa are observed in connection with spavin.

18.10. Myotenyectomy (section/partial removal of the tendon and muscle belly) of the **lateral digital extensor muscle** is a possible option for surgical therapy of **stringhalt**. [265] This disease is an abnormality of the gait of the pelvic limb, which is triggered by different neuromuscular disturbances (among others, by a herbal intoxication, a trauma or a painful process in the region of the distal limb). [265] [266] [267] Affected horses typically demonstrate an exaggerated action of the pelvic limb with each stride, in which the hock joint and stifle joint are suddenly moved convulsively and the limb raised high.

20.1. A thrombotic occlusion in the region of the termination of the aorta may lead to the clinical picture of **intermittent limping**. [268] The thrombus is usually located in the **aorta** or in the **external iliac artery** or **internal iliac artery**, sometimes also the femoral artery is involved. [269] [268] The cause is not exactly known. Besides hemodynamic factors and disorders of blood clotting, also parasitic causes are mentioned. [268] A typical clinical sign is a stress-induced lameness of the pelvic limb, [269] [268] which presumably has its origin in hypoxemia of the affected limb. To confirm the diagnosis, a rectal sonographic examination can be performed. Additional information may be obtained from Doppler sonography^a of the femoral artery. [271] Besides medicinal therapy, also surgical removal of the thrombus by way of the femoral artery (access in the region of the femoral triangle) is described. [270]

^a Doppler sonography yields information concerning blood-flow velocity and changes in the hemodynamic. The basic physical phenomenon is the change in the frequency of sound waves in their reflection from locally changing (moving) interfaces (Doppler effect) in which case the erythrocytes in the bloodstream act as moving reflectors.

22.1. Anesthesia of Nerves of the Pelvic Limb

Basically, diagnostic nerve anesthesia of the distal limb (up to and including high four-point anesthesia) corresponds to what was given on the thoracic limb (Fig. 22.1.1.).

a) **High 4-point anesthesia** is performed about 3 cm distal to the tarsometatarsal joint. Similar to the thoracic limb, it may be misinterpreted by an unintentional injection of the tarsal synovial sheath or the distoplantar outpouching of the tarsometatarsal joint. [114]

b) In addition to the medial and lateral plantar metatarsal nerves, which both are derivatives of the deep branch of the lateral plantar nerve^b and thus from the tibial nerve, there are on the pelvic limb also **dorsal metatarsal nerves II and III**, which originate from the deep peroneal nerve (Fig. 22.1.1.). [113] To eliminate cortical pain in the dorsal region of Mt III, the dorsal metatarsal nerves are also anesthetized by a subcutaneous deposit of 2–3 cc of anesthesia solution (**high 6-point anesthesia**). [114] [113] With this procedure, injection of dorsal common digital vein II or the great metatarsal artery III (*a. metatarsae dorsalis III*) should be avoided.

c) With the limb lifted up, the **tibial nerve** is palpable as a firm cord, about 6 mm thick, between the common calcanean tendon and the lateral digital flexor muscle. [114] Anesthesia of the tibial nerve is performed from the medial side, about 10 cm proximal to the calcanean tuber. Subfascially, fan-like, 10–20 cc of anesthesia solution is injected (Figs. 22.1.1. and 22.1.2.). [114] [113] The plantar part of the tarsus, the distal Achilles tendon (common calcanean tendon)

as well as the structures which were already considered in the 4-point block are desensitized. [113]

d) Anesthesia of the tibial nerve is usually combined with anesthesia of the **fibular nerve (peroneal nerve)**. With this technique, the distal tibia, the entire hock joint, the tarsal synovial sheath as well as the total distal limb are desensitized. [114] Anesthesia of the peroneal nerve is performed from the lateral side, about 10 cm proximal to the tarsus, where its superficial branch is well palpable between the long digital extensor muscle and the lateral digital extensor muscle. [114] [113] At this site, the needle is introduced directed toward the tibia and the deep peroneal nerve deeply with 10–15 cc anesthesia solution fan-like injected. [114] Since the nerve takes its course near the cranial tibial artery and vein, injection of the vessels demonstrates roughly the proper site for the needle. In withdrawing the needle, the superficial peroneal nerve is also anesthetized by a subcutaneous injection of 5–10 cc anesthesia solution (Fig. 22.1.1. and 22.1.2.). [114]

22.2. Dorsal metatarsal artery III, the great metatarsal artery, is the **main artery of the metatarsus of the pelvic limb**. To take the pulse, this vessel can be palpated proximolaterally on the cannon bone between Mt III and the lateral splint bone (Mt IV). [272] [273] The distal continuation of the vessel runs between Mt III and Mt IV in a gradually oblique distoplantar direction, [272] which has to be considered if the distal splint bone is surgically removed. [274]

^b According to the Nomina Anatomica Veterinaria (1994), synonymous designation for the N. digitalis plantaris com. III

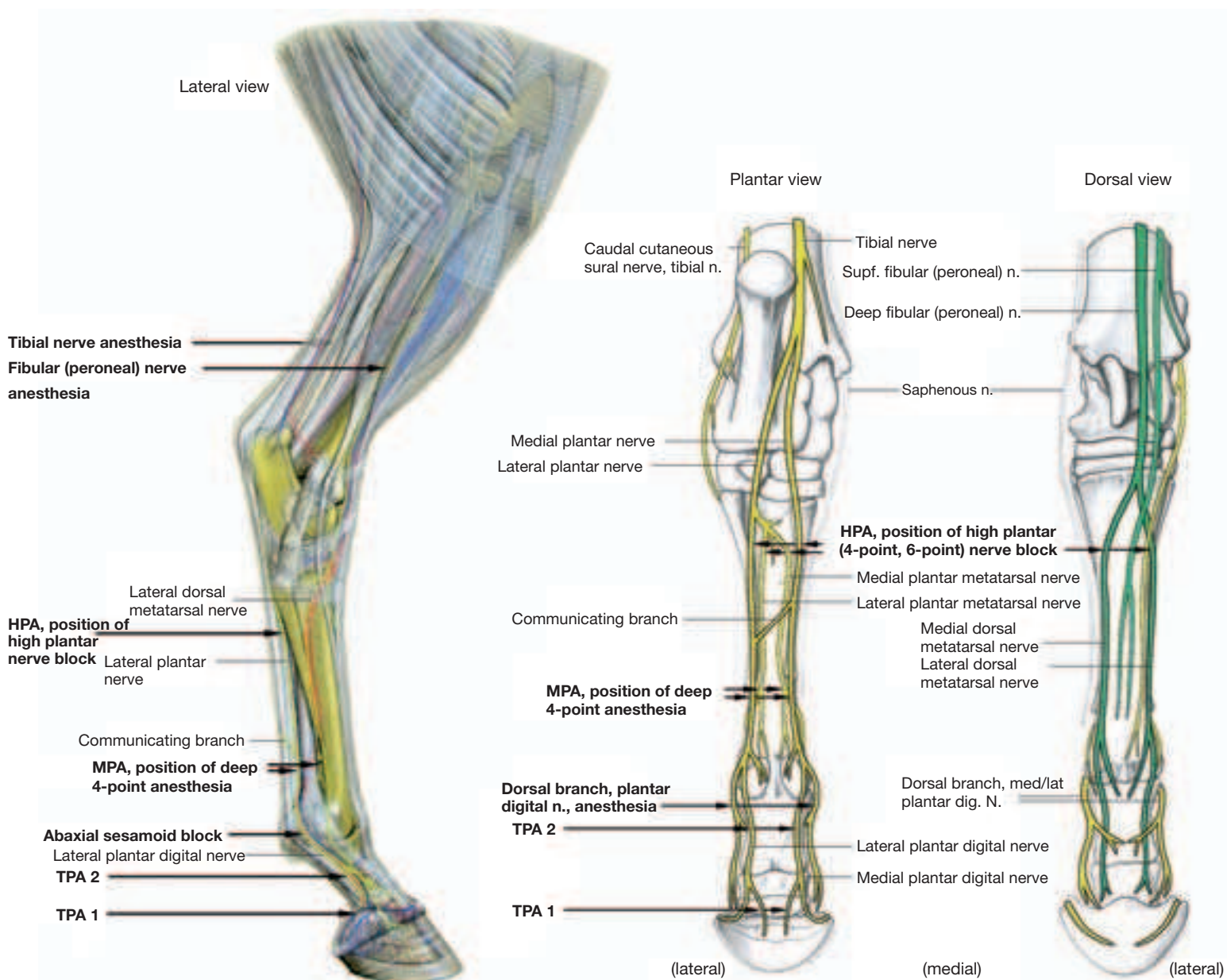


Fig. 22.1.1. Relevant nerves of the pelvic limb and their sites for anesthesia for lameness diagnosis. In the right part of the figure the tibial nerve including its distal continuation is yellow and the terminal branches of the common fibular (peroneal) nerve are dark green. **HPA**: high plantar nerve block, **MPA**: low 4-point anesthesia, **TPA 1 and 2**: deep (distal and proximal) plantar digital nerve blocks. (Courtesy of Institut f. Veterinär-Anatomie, Berlin)

22.3. The medial saphenous vein (or its **cranial branch**) is located medially on the crus. Especially in foals, it can be used as an alternative to the external jugular vein for venepuncture or installation of a catheter. [110]

24.1. The alternate passive fixation of the pelvic limb in the stifle joint, which enables the horse to stand without fatigue is determined predominantly by the action of the quadriceps femoris muscle. [275] [134] By that, the stifle joint is so far extended by contraction of this muscle, that the patella, drawn proximally, glides on the nose-like bulge of the medial ridge of the trochlea and can be anchored there with the help of the medial parapatellar fibrocartilage and the middle and medial patellar ligaments. [134] The dislodging of the fixed patella is brought about again by the contraction of the quadriceps femoris muscle, whereby the patella is turned simultaneously by the pull of the biceps femoris muscle. [275] [134] Disorders of the gliding movement of the patella on the medial ridge of the trochlea are designated **proximal patellar fixation**. If the freeing of the patella is only delayed (*habitual patellar fixation*), with flexion of the stifle joint there is a typical jerky movement of the affected limb. [275] The uneven movement of the patella is sometimes audible as a snapping sound. [276] With *stationary patellar fixation*, flexion of the stifle joint is impossible. The limb is kept stiff and extended since, owing to the reciprocal apparatus, the hock joint also cannot be flexed. [275] [276] Proximal patellar fixation usually occurs bilaterally. A decrease in tonus of the quadriceps femoris muscle is regarded as a main cause. For this reason especially young horses or horses in poor condition are affected. Beyond that, a steep attitude of the pelvic limbs is predisposing. [277] [275] [276] Initially, therapy can be conservative, whereby the exclusion of predisposing factors as well as a monitored training for muscle build-up have a special importance. [231] [277] [276] As a last measure, surgical therapy is also possible in the form of a desmotomy of the medial patellar ligament 1–2 cm proximal to its attachment to the tibia. [231] [275] Certainly, as a sequel often fragmentation of the distal patella or contour changes of the cranial border of the tibia are observed. [231] These, however, as a rule, have no clinical relevance. [275] Recently also a percutaneous splitting of the proximal third of the medial patellar ligament is described. [278] [276]

Particularly in newborn Shetland pony foals a **lateral subluxation or luxation of the patella** is occasionally observed. To differentiate a traumatically induced patellar dislocation from this inherited change, the term “patella-ectopy” is also employed. [279] [280] Usually this condition has its basis in an inherited dysplasia (lack of development) of the trochlea of the femur, in which mainly the lateral ridge of the trochlea is affected. [281] [282] [283] Patellar dislocation can vary according to the extent of the defective deve-

lopment. In severe cases affected foals demonstrate a typical dog-sitting posture because an extension of the stifle joint is impossible. [281] Therapy consists of a surgical deepening of the trochlear groove with an associated repositioning of the patella. [281] [283] This can be combined with a tightening of the medial joint capsule including the fascia as well as a section of the lateral femoropatellar ligament and parts of the aponeurosis of the biceps femoris muscle. [281]

24.2. The reciprocal apparatus in the crural region allows only an equal movement of stifle and hock joints. It is formed cranially by the tendinous peroneus tertius muscle and caudally by the common calcanean tendon (especially by the plantar tendon of the superficial digital flexor muscle (Fig. 24.2.). [284] Occasionally the **peroneus tertius muscle** suffers a traumatically induced rupture, which is often located in the middle crural region. [233] [284] A typical clinical sign is loss of the reciprocal apparatus and with this the possibility of extension of the hock joint with the stifle joint flexed. In this condition, the common calcanean tendon is an entirely relaxed and undulating structure. [284] To demonstrate the lesion of the peroneus tertius muscle as well as to monitor the healing process, sonographic examination is the first choice. [285]

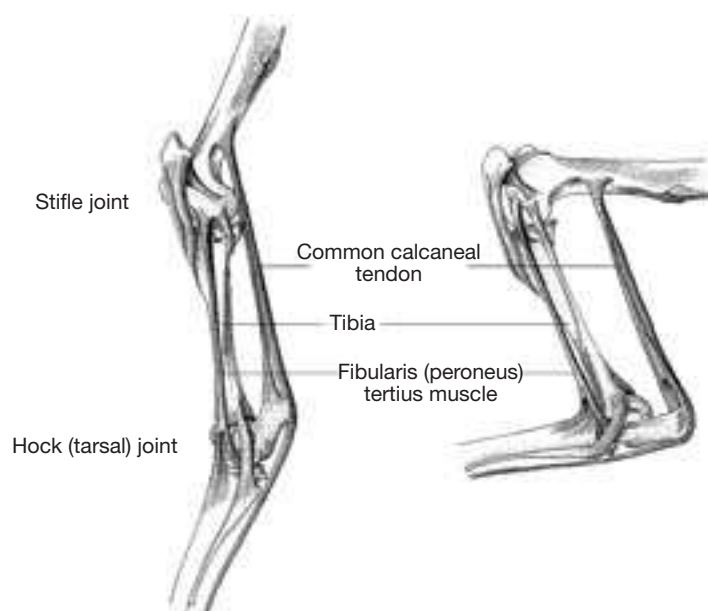


Fig. 24.2. Semidiagrammatic representation of the reciprocal apparatus of the pelvic limb of the horse. (Courtesy of Institut f. Veterinär-Anatomie, Berlin)

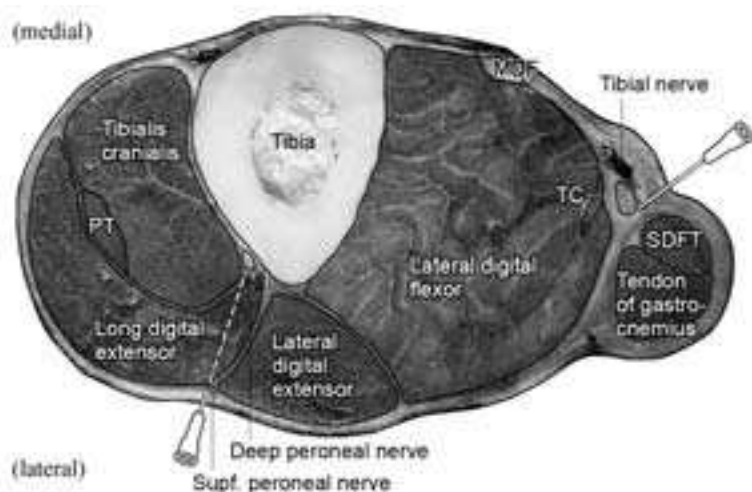


Fig. 22.1.2. Cross-section of the left hind limb of a horse (about a handsbreadth proximal to the tuber calcanei) to demonstrate the sites of injection of the tibial nerve and deep and superficial fibular (peroneal) nerves. 1: cranial tibial a./v., 2: cranial branch of the medial saphenous v. and saphenous a./n., 3: caudal branch of the saphenous a./medial saphenous v., **MDF**: medial digital flexor muscle, **PT**: fibularis (peroneus) tertius muscle, **SDFT**: superficial digital flexor tendon (plantar tendon), **TC**: tibialis caudalis muscle. (Courtesy of Dr. Patan)

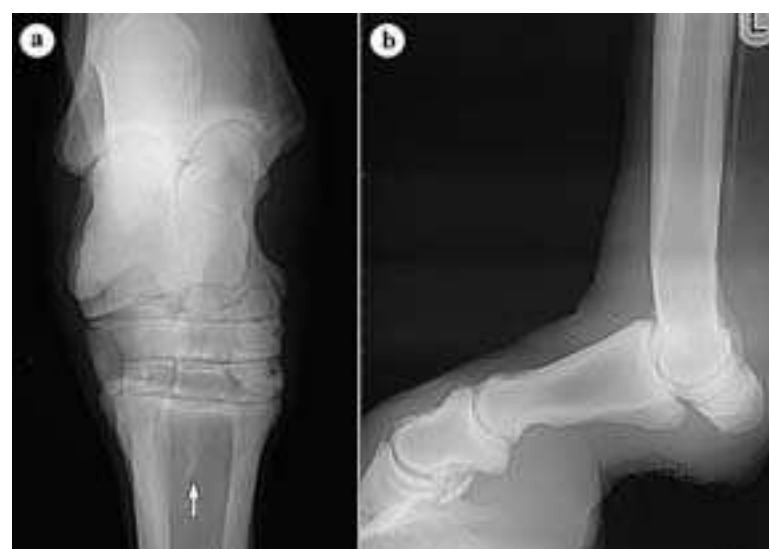

Fig. 24.3. a) Dorsoplantar radiograph of the tarsal joint with desmopathy of the insertion of the suspensory ligament (interosseous muscle) at its origin (**arrow**), 11 years warmblood mare, b) high degree of hyperextension of the fetlock joint and distal displacement of the proximal sesamoid bones because of a functional loss of the proximal portion of the suspensory apparatus (damage to the suspensory ligament), 24 years old warmblood gelding. (Courtesy of Klinik für Orthopädie bei Huf- u. Klauentieren, Veterinärmed. Univ. Berlin)

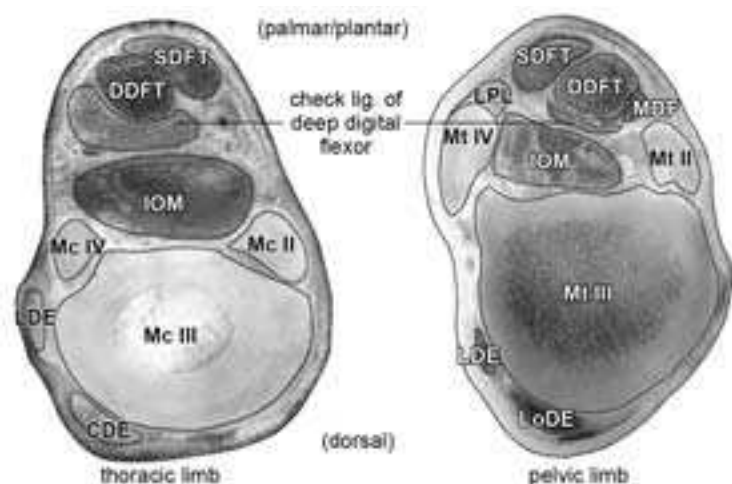


Fig. 24.4. Comparison of the strength of the accessory (check) ligament of the deep digital flexor on the thoracic and pelvic limbs.

CDE: common digital extensor muscle, **LDE:** lateral digital extensor muscle, **LoDE:** long digital extensor muscle, **MDF:** medial digital flexor muscle, **IOM:** suspensory ligament (interosseous muscle), **LPL:** long plantar ligament, **SDFT:** superficial digital flexor tendon, **DDFT:** deep digital flexor tendon. (Courtesy of Dr. Patan)

24.3. The suspensory ligament (m. interosseus), which originates proximoplantarly on Mt III and on calcaneus, on the pelvic limb is innervated only by branches of the tibial nerve. [244] [325a] Inflammatory changes in the proximal region of the suspensory ligament are a relatively frequent cause of lameness in athletic horses (especially in racehorses, but also in show jumper and dressage horses). [48] [286] [287] The lameness is usually more distinctly expressed than in the case of corresponding changes on the thoracic limb, which is traced back to a **compartment-like syndrome** (similar to the carpal-canal syndrome). The cause is considered to be the relatively strongly developed fascia in this region, which in case of a thickening of the suspensory ligament probably results in an increased pressure on the adjacent medial and lateral plantar metatarsal nerves. [244] [151] The lesions in the region of the origin of the suspensory ligament are usually well demonstrable sonographically; sometimes also demonstrated by radiographic changes in the form of avulsion fractures or bone densities at the proximal Mt III (Fig. 24.3., a). [151] Besides conservative therapy (among others, monitored activity program, local and systemic medication, autogenic bone marrow injection, shock-wave therapy) also different surgical procedures are described such as fasciotomy [48] or neurectomy of the tibial nerve or the medial and lateral plantar metatarsal nerves. [48] [151] Percutaneous osteostixis is a relatively new procedure, by which several small holes are drilled through the cortical substance in the region of origin of the suspensory ligament. [50]

24.4. On the pelvic limb, the accessory ligament of the deep flexor tendon (distal check ligament) is weaker than on the thoracic limb.

Hoof

BIANCA PATAN, KLAUS-DIETER BUDRAS

26.1. In the toe region, the **normal hoof of the forefoot** has an angle of 50–54° [288] with the ground and a length relationship of the wall of the toe with the wall of the quarter of 2:1 [289] to 3:1 [290] In the case of the **normal hind hoof** the angle of the toe is 53–57° [288] and the length relationship between the wall of toe and quarter is 3:2 [289] to 4:2 [290]. An obtusely angulated hoof with a toe angle of 60–90° and high quarters is designated **clubfoot**. A wide, acutely angulated hoof with a flat sole in the same plane as the bearing surface of the wall is designated **flat foot**. If the sole is dropped beyond the level of the bearing surface of the wall, then it is a **pumice foot (dropped foot)**. In the **contracted hoof**, there is a gradual narrowing of the hoof, in which case according to the location of the narrowed portion, quarter-narrow, coronet-narrow, sole-narrow, and a narrowing of the bearing surface of the wall are distinguished. [289] [290]

In the ideal case, the **length of the hoof** is kept constant by loss of horn (especially, wearing off) and horn formation. If the wearing of

horn predominates, the hoof can be protected by shoeing (horses in large cities). If the horn formation predominates and attrition is deficient, then the hoof is trimmed professionally by the farrier.

On account of **seasonal changes in the annual rhythm**, wild or semi-wild living horses (Przewalski horses) develop an autoregulative mechanism for maintenance of hoof form and angulation, including the length of the hoof. This mechanism is approximately constant and takes place after about a one year adaptive phase in the wild or semi-wild reservation. This is reached through the seasonal rhythm in the rate of horn formation (1), in horn quality (2), in ring formation of the hoof (3), in horn attrition (4) and in the physiological (directed) growth of the bearing surface (5), which comes about through physiological (directed) longitudinal and transverse fissures (6).

1. The horn formation rate is least with about 3 mm in the month of January and highest in August with a threefold intensity.

2. The change in horn quality can be demonstrated by differences between the summer horn (formed in the summer months) and the winter horn. As a result of measurements of toughness and structural changes, the winter horn can be assessed as firmer and more stable than the loosened up summer horn.

3. Hoof rings develop owing to changes of food or seasonal changes in the vegetation as “growth rings”, which are directed out parallel to the coronary border. After illnesses pathological horn rings may develop, which are not parallel to the coronet (for example, the rings of hoof laminitis). Formally, convex hoof rings (elevated hoof rings) can be differentiated from concave hoof rings (furrows between the elevated rings). Elevated rings resemble the summer horn of the ring-free areas and accordingly display a lower strength in comparison to the ring-like furrows and winter horn.

4. In its annual course, horn attrition has a curve similar to the rate of horn formation. It depends on the seasonal quality of the horn in wear as well as the seasonal changes in body weight and activity and also the condition of the ground.

5. Physiologic growth of the wall border of the hoof in May to September, when the hooves are longest, lead to a sudden shortening of the hoof, because roughly rectangular horn chips with a border length of several centimeters break out one after the other. Because the break away of the wall border is found roughly a fingerbreadth distal to the solear border of the hoof, the living tissue remains undamaged in painless condition.

6. For the transverse fractures necessary for this break out, the differences in horn quality along the ring-shaped projections and furrows are predisposing as fracture sites. The longitudinal fractures arise owing to the inclination for dessication and shrinkage of the inner coronary horn masses near the wall border, the horn cells of which are porous like a sponge. Further factors are increased tissue tension and the influence of force in the course of the hoof mechanism. These physiological fissure-formations and growth of the wall border are to be distinguished from pathological forms, which expand proximally as well as into the depth and can lead to scarred painful, often suppurative inflammations of the corium. [291] [292] [293] If the animals are kept in the zoo, the autoregulation mechanism is not working, because the mentioned seasonal changes are lacking or underdeveloped. Comparable facts are found in domestic horses kept in barns. Whether semi-wild domestic horses on a semi-reservation develop an autoregulation mechanism shall be studied in a current research project, in which case genetic influences are to be separated from environmental factors.

26.2. Contusions of the **corium (dermis)** of the hoof (for example, by entrance of small stones, but also mistakes in trimming the hoof or shoeing) may result in an aseptic laminitis in which local discoloration of the hoof horn may occur because of hemorrhages in the corium (so-called “corns”). [294] [208]

If bacteria enter the corium, because of discontinuities in the horn structure, then a suppurative laminitis (so-called **hoof abscess**) may develop. [208] Since with the formation of pus usually an increase of pressure develops within the hoof capsule, the horses frequently show a high degree of lameness. [294]

Hoof canker is the name given to a chronic proliferative laminitis characterized by excrescences of the affected area of dermis. [295] Typically, there is in addition a caseous, bad-smelling coating on the proliferating masses, which develop as a result of a disturbed epithelialization and cornification of the corresponding hoof epidermis. [296] [121] The changes are mostly concentrated in the heel-frog segment, but can spread to the sole- and wall-segment. [296]

The exact cause is unknown but anaerobic bacteria (especially *Fusobacterium necrophorum* and *Bacterioides* spp.) seem to play an important role in the disease. [121] The most important surgical therapeutic measure is the removal of the entire altered tissue. [296] [297]

26.3. The hoof horn, formed by the **epidermis of the hoof**, shows in part considerable segment-specific qualitative differences, which affect both horn structure and the mechanical-physical characteristics of the horn. Thus, the coronary and also the solear segment are characterized by very hard horn, whereas in the periople as well as the heel-frog segment a relatively soft and elastic horn is formed. [298] [304] The differences in hardness and elasticity, which are based to a great extent on the different moisture content of the hoof horn as well as on variations of different structural parameters, represent an adaptation to the mechanical demands of the hoof capsule to the footing of the equine hoof. [298] [299] [300]

26.4. There are different criteria for the evaluation of the **quality of the horn** in the different parts of the hoof. [299] In no way is it to be equated with the hardness of the horn. In adaptation to the different demands of the individual segments of the equine hoof, horn of good quality can completely fulfill a protective function against mechanical, chemical and microbial noxious agents. Horn of poor quality is functionally limited and for that reason represents a predilection site for hoof diseases. Horn masses are comparable to a brick wall, in which the horn cells correspond to the bricks and the intercellular substance to the binding mortar. The integrity and functional “teamwork” of both components is qualitatively significant. The horn cell consists of keratin filaments (diameter about 8 nm) and the proteins associated with the keratin filaments, which with one another and at the cell membrane of the horn cell are among others stabilized by disulfide bridges. In interaction with the horn cell, the intercellular substance guarantees a great stability of the horn cell association, when, as much as possible, it fills evenly and entirely the narrow intercellular gap. In dependence on its affiliation to a hoof segment, it contains different concentrations of glycoproteins with good intercellular adhesion ability, enzymatic proteins for cell detachment with horn cell desquamation, and structural lipids to assure a semipermeable epidermal barrier. Besides that, water and lipid content influence horn quality. The hardness of the horn increases with decreasing moisture content, and in view of the high variation in moisture, the differences in the individual hoof segments are remarkable. This concerns especially the soft

horn of the periople and the closely neighboring extremely hard coronary horn. That the hardness of the horn within a segment can vary considerably with water content is shown by the example of coronary horn, which from inside to outside and also from proximal to distal becomes distinctly harder with decreasing water content. [293] [301] [302] [303]

Lipid content likewise influences the firmness and consistency of the horn masses. Numerous lipid droplets in the horn cells function as an elasticity-giving factor and lend the typical eraser-like consistency to the frog and heel-horn, which are rich in fat. In cooperation with the increased lipid-rich intercellular substance in numerous vesicular dilatations of the intercellular space, the lipid droplets effect an elastic absorbance of the stress loads, which predominate in the horn of the frog and heel. [304]

Epidermal differentiations during cell replacement extend from the **synthesis stage (keratinization)**, where the parts of the horn cell are synthesized, across the **transformation stage (completion of keratinization)** with pre-programmed cell death, across the **stage of maturity with maximal resistance** of the horn mass, to the **ageing stage with increasing cracks in the horn**, that finally passes over into the **stage of decay**. In the horn tubule medulla, this differentiation is passed through rapidly. The age-dependent decay of the medullary cells is certainly significant for that reason, since it occupies a considerable extent, because horn tubules with medullary portion are found everywhere in the hoof horn, except in the parietal laminar horn. The early decay of medullary cells is already preprogrammed at the beginning of differentiation in the phase of synthesis during keratinization, because in the process of cell replacement the keratinizing epithelial cells are removed rapidly from their blood supply in the dermal papillae, in which case their nutrition becomes increasingly more critical. [305] The result of this is an incomplete keratinization and finally, during keratinization, a looser structure of the horn. On the one hand the decay of the medullary cells provides a favorable effect on the light weight construction of the tubular horn; on the other hand it impairs its barrier function against ascending colonizing germs. However, this impairment is less grave in the coronary horn with its very long tubules than in the white line where it may result in “white line disease”, because the barrier for the protection of the vital suspension of the coffin bone is destroyed. With the decay of the medullary cells a further important function, the storage of moisture, is lost. This is connected with the high lipid content and contributes in case of loss to the dessication of the surrounding horn portions.

26.5. The **hoof mechanism** is brought about by segment-specific differences in the quality of the horn masses, and results in shock absorption with the footing of the limb. We are dealing with an elastic variation of the hoof capsule during the weight-bearing of the hoof, which is characterized by an expansion of the quarters, a lowering of the frog and heels and a flattening of the sole in the caudal part of the hoof as well as a narrowing of the coronet in the dorsal half of the hoof. [290]

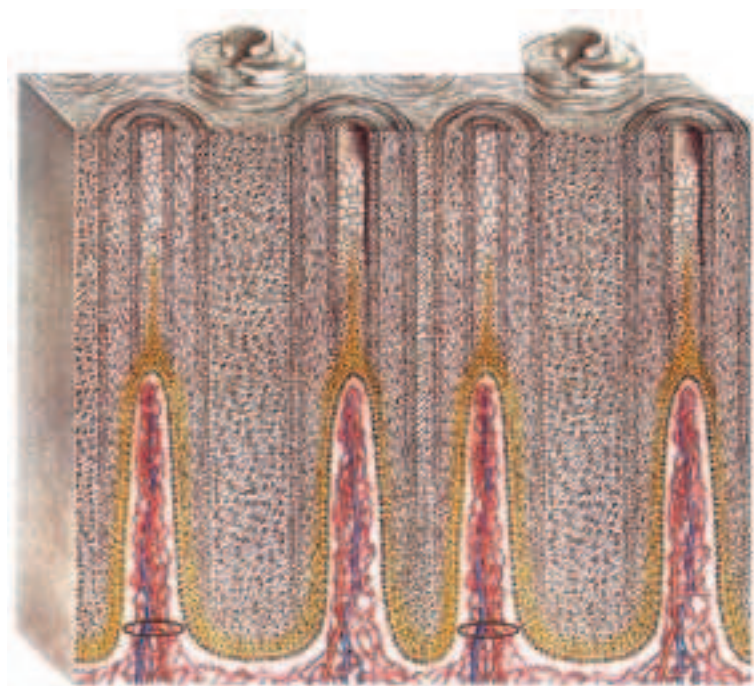


Fig. 26.4.1. Interaction between the dermal papillae, which convey blood vessels, and the epidermal tubules. The intertubular horn arises between the dermal papillae. The peripapillary cortex of the tubule is formed by living epidermal cells (marked yellow). The suprapapillary medulla of the tubule is formed above the apex of the dermal papilla. It breaks down prematurely in many places and thus brings about the formation of the horn tubule. (Modified from Ellenberger and Baum, 1943)

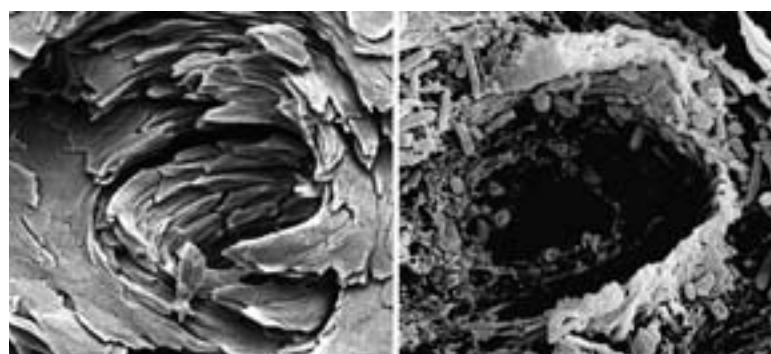


Fig. 26.6. Scanning electron microgram of the horn tubules. The fountain-shaped tubules can be destroyed by bacterial decay (right).

26.6. The horn of the periople, heels and sole in this sequence reach relatively rapidly the **stage of decay**. Contrary to widely spread opinion the decay of horn cells is considerable. It fulfills to a physiologic, normal, extent important biological functions such as the formation of the decay horn of the sole for the maintenance of the normal concavity of the sole, a precondition for the hoof mechanism. Of all parts of the hoof, the coronary horn is most constant and is normally not subjected to decay, if one disregards the medullary part. The normal ageing of the coronary horn with increase of cracking and decrease in moisture is observed only distal to the coffin bone-sole border and scarcely impairs the protective function of the hoof. So far as the decay of the horn cells begins prematurely and reaches pathological dimensions, it impairs the health of the hoof depending on its location, by which the bearing border of the hoof including the fixation bed of the hoof nails is increasingly destroyed. To maintain hoof health, it is especially important to arrest a premature ageing process. To do this, balanced food rations can contribute with a sufficient supply of minerals such as zinc and selenium as well as trace elements such as sulphur (by way of sulphur-containing amino acids such as methionine and cysteine) and finally with vitamins (especially biotin). [305] [306]

26.7. The **white line** plays a special role in horseshoeing because in this region the hoof nails are driven. [289] [290] In case of a mistaken placing of a hoof nail, injury to the solear or wall dermis (direct mis-nailing, nail prick) or the bruising of the parietal dermis (indirect mis-nailing, nail pressure) may be the result. Nailing is omitted in the region of the quarters, to maintain the hoof mechanism. [294] [289] [290]

White line disease is the name given to a disease of the hoof, which is characterized by a progressive separation in the region of connection between the inner coronary horn and the laminar horn of the wall. [307] [308] The horn defect is as a rule filled in by crumbling, gray-black masses.[308] In severe cases a rotation of the coffin bone may develop as in laminitis. [309] Up to now, the exact cause is not known; animal husbandry, mechanical, and nutritional factors as well as infection with certain fungi and bacteria are discussed. [307] [310] [309] [308] A predisposition to white line disease is also given by changes in the hoof horn resulting from chronic laminitis (founder). [310] [309]

26.8. A columnar thickening on the inner surface of the hoof plate (horn wall), which is made up of scarred laminar and tubular horn, is designated a **zylindric keratoma**. [82] [290] The cause is often unknown; in discussion are traumata or chronic irritations, which lead to a circumscribed inflammation of the parietal (wall) dermis. [311] [290] Keratomas occur most frequently on the dorsal wall and may cause a pressure atrophy of the parietal dermis and of the coffin bone. [311] If the keratoma extends to the wall border of the hoof (bearing surface of the wall), a locally circumscribed expansion

of the white line directed toward the solear horn is observed on the sole surface. [82] [290] If a lameness develops, then the horn column in its entire extent is surgically removed. In doing this the suspensory apparatus of the coffin bone will be partially destroyed, and thus the danger of a rotation of the coffin bone exists. [311] [82]

Disconnections in the region of the **hoof plate** (also called **horn wall**), which course in the longitudinal direction of the horn tubules, are called **horn cracks**. [290] They can arise due to wounds at the coronet or by extreme stress of certain parts of the wall (for example, as a result of mistakes in hoof trimming or horse shoeing).

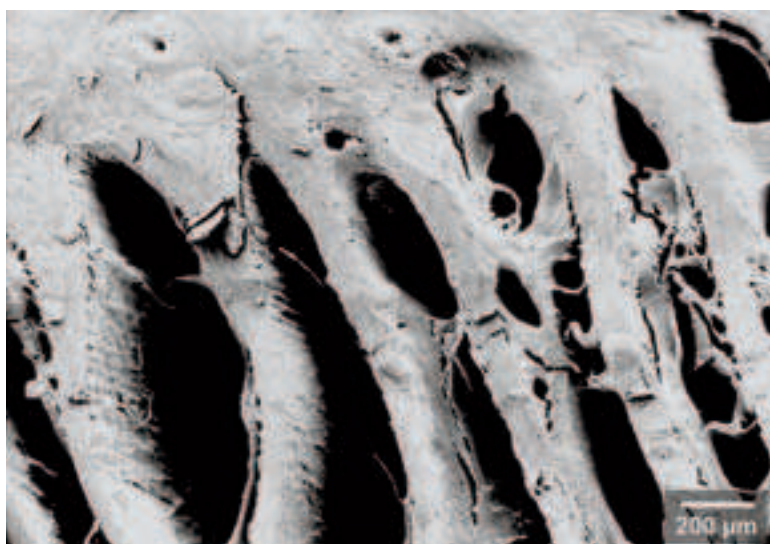


Fig. 26.7. "White line disease" in chronic laminitis. As a result of the necrosis of the dermal papillae, the formation of full horn tubules (cf., page 27, below) in the vicinity of the terminal papillae remains incomplete so that the barrier function of the white line is severely limited.

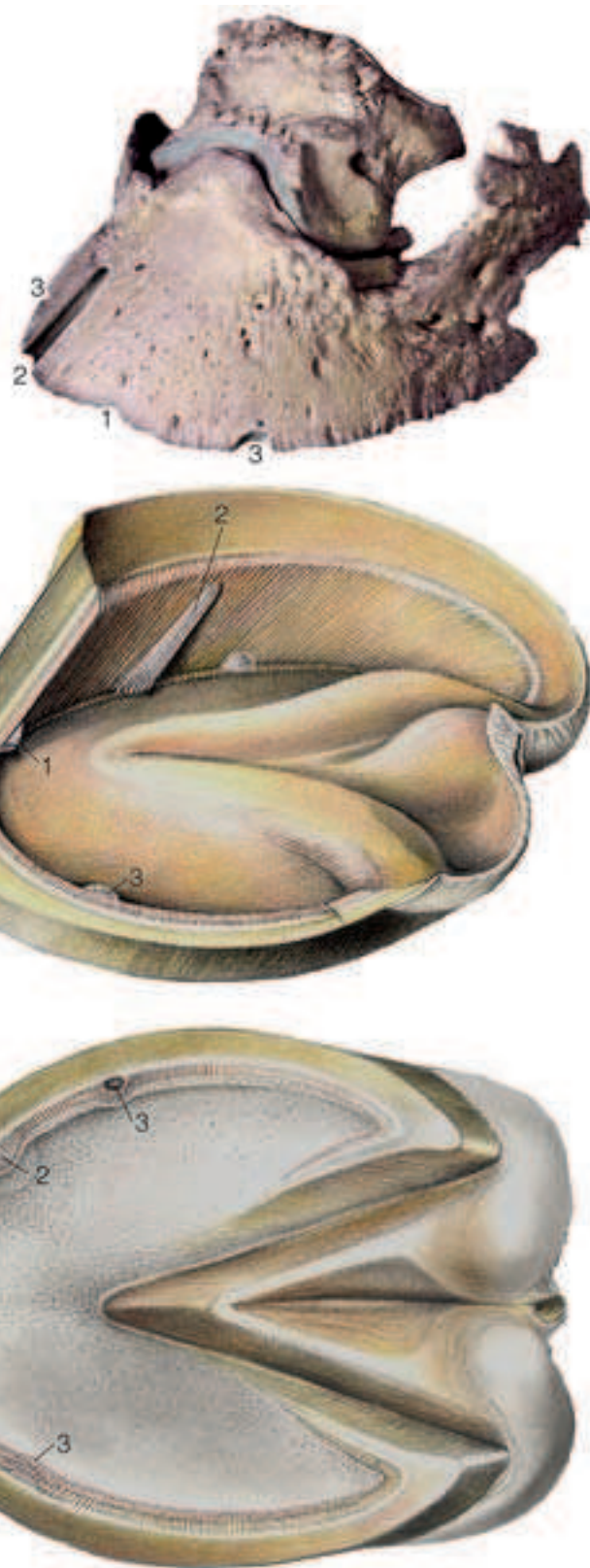


Fig. 26.8. In the middle figure are pictured the (often also normally occurring) sole-spur (1, apically at the wall-sole border, in prolongation of the central cuneal sulcus), a zylindric keratoma (2), which tapers toward the coronary segment, and two horn calluses (3, hemispherical horn structures at the wall-sole border). These normal or diseased horn structures can be recognized on the solear surface as expansions of the white line (lower figure). On the distal phalanx (upper figure with ossified ungular cartilage), the sole spur sculpts a crenation at the solear margin (1), the zylindric keratoma an elongate defect in the bone (2), and the horn callus marks a hemispherical defect at the solear margin (3).

[294] Horn cracks are usually only associated with a lameness, if they penetrate the entire hoof wall and reach the dermis. [294] [312] For healing to take place, the hoof capsule must be stabilized in the region of the crack. [312] On the other hand, a **horn cleft** is a defect in the horn wall that runs within the hoof plate parallel to the coronet and is usually a sequela of earlier wounds at the coronet. [290] A separation within the hoof plate, which usually shows up between the internal coronary horn and the laminar layer, [290] sometimes also between the internal and middle coronary horn, [305] is designated **hollow wall**. **Loose wall** develops after a loss of horn of the white line, by which a separation between the hoof plate and horny sole develops. [290]

26.9. On the basis of its elastic and soft consistency, the **horn of the heel-frog segment** is especially susceptible to penetrating wounds by pointed or acute objects (puncture wound by nails). [296] In this case, the foreign object most frequently enters in the area of the col-

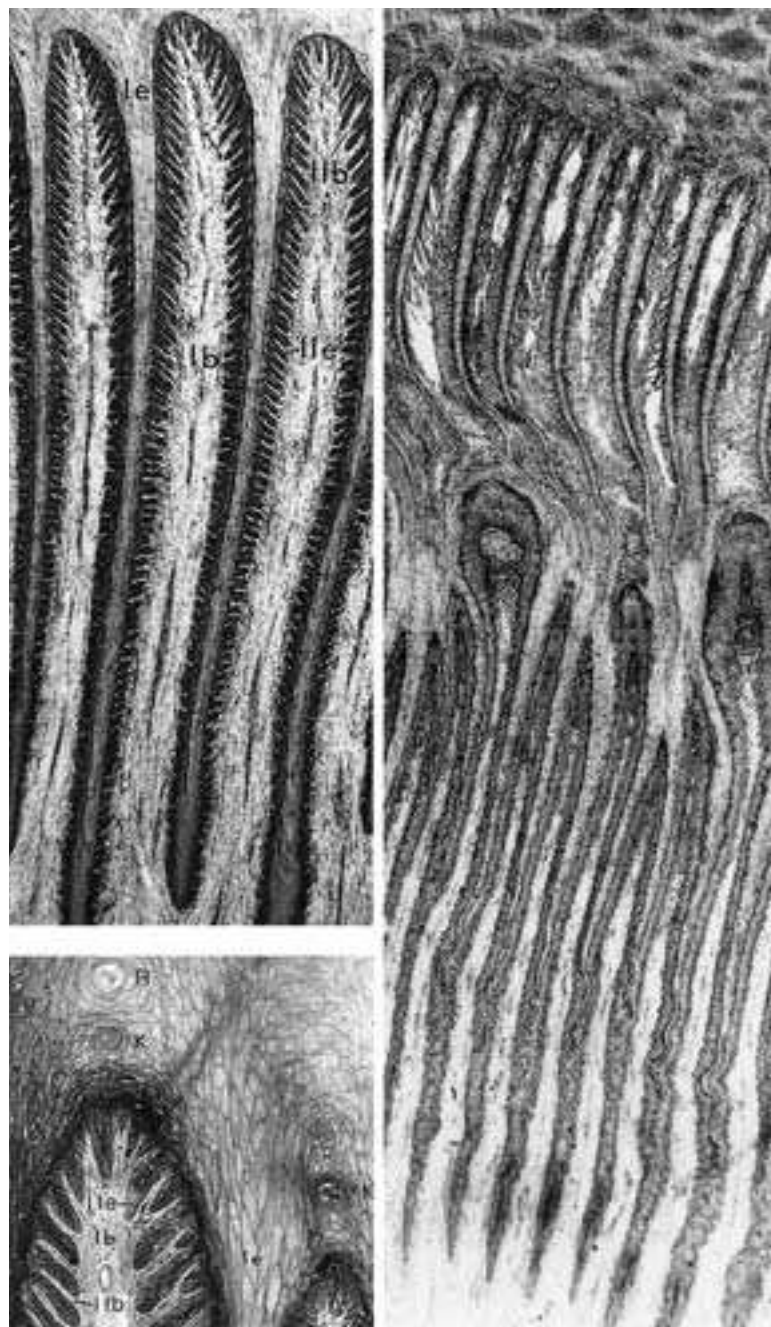


Fig. 28.1.1. left: Dermal and epidermal suspensory apparatus of the coffin bone from the proximal (above, enlarged about 10x) and distal half of the wall segment (below, enlarged about 90x).

lb connective tissue of the primary lamella; **le** epidermal primary lamella; **R** tubular horn from the coronary segment, which serves the springy-elastic anchoring of the epidermal part of the suspensory apparatus of the coffin bone; **llb** connective tissue secondary lamella; **lle** epidermal noncornified secondary lamella, between llb and lle there is a basal membrane; **K** cap-horn tubule.

Right: Histological section through the hoof capsule in chronic laminitis with coronary horn tubules (above), old necrotic (middle) and new vital suspensory apparatus of the coffin bone (below). The new suspensory apparatus projects with knobby thickenings between two necrotic lamellae of the old suspensory apparatus and, with the formation of dyskeratotic horn, produces a reparative connection between old and new lamellar structure that is scarcely loadable. 10x. (Photo: Dr Marks)

lateral cuneal sulcus. [289] [208] The consequence is usually an injury and wound infection of internal hoof structures. According to the location of the nail-penetration, the dermis, coffin or navicular bone, the digital cushion, the deep flexor tendon, the podotrochlear (navicular) bursa or the coffin joint may be affected. [289] [208] [296] A precise knowledge of the affected structures is enormously important for adequate treatment and prognosis. [304]

Thrush is an infection in the region of the frog by the development of which keratolytic microorganisms (especially *Fusobacterium necrophorum*) play a role. An accumulation of black, foul-smelling masses in the region of the central or collateral cuneal sulci is characteristic. Lameness is usually observed only if the infection is spread to the more deeply located structures. [294] [191]

28.1. The Suspensory Apparatus of the Coffin Bone

The phylogenetic development of an animal adapted to run swiftly came about by an elongation and extension of the limbs with the acquisition of a long stride for an increased speed. For this a lengthening and extension of the limbs is essential. These culminated in the footing (contact of the limb with the supporting surface) at the border of the tip of the digit, of the weight-bearing border, where the horseshoe is fixed (related to human conditions, it is comparable to the loading of the free border of our middle fingernail, by which the total body weight would be borne). With the rhythm of the stride, the coffin bone sinks and rises to a slight degree at weight-bearing and non-weight bearing. With this, according to the principal of a hammock, the coffin bone is kept in a suspended position, by the suspensory apparatus of the coffin bone, a nearly closed, caudally open, surrounding suspension, which is balanced by the extensor tendon and the deep flexor tendon. At the tip of the coffin bone, there is manifest a break in the fan-shaped reinforcement of the suspensory apparatus of the coffin bone, reflected in a backward shift of the coffin bone with an expansion of the white line as a result of the powerful pull of the deep flexor tendon. By the suspension, the bony border of the solear surface of the coffin bone is protected against a non-physiologic pressure load (comparable to the protection of the bony dental alveolus by the periodontium for the "suspended tooth"). A loss of function means an exungulation (or loss of the tooth). Because the suspensory apparatus of the coffin bone in the case of laminitis is overextended and partially ruptured, when the coffin bone sinks down from its suspended position and is loaded (bearing significant weight) fractures can arise or a brim-like upward bending of the bony border of the sole (Fig. 28.1.2.). At the dorsum of the hoof, the bearing elements, the dermo-epidermal laminae are best developed, *i.e.*, they are longer and broader than in the other regions. By the extreme enlargement of their surface, they guarantee the highest traction load (Fig. 28.1.1. left), but also the highest susceptibility with a view to laminitis. The suspensory apparatus is less developed in the region of the quarter and the angle of the wall, and serves for the indirect anchoring of the hoof capsule to the underlying ungular cartilage. The enormous loading of the suspensory apparatus contains risks—for example at the overcoming of an obstacle—for ruptures, which are lessened by special protective mechanisms. At both ends there is a spring-like elastic end-fixation and intermediary fixations between. [313] [314]

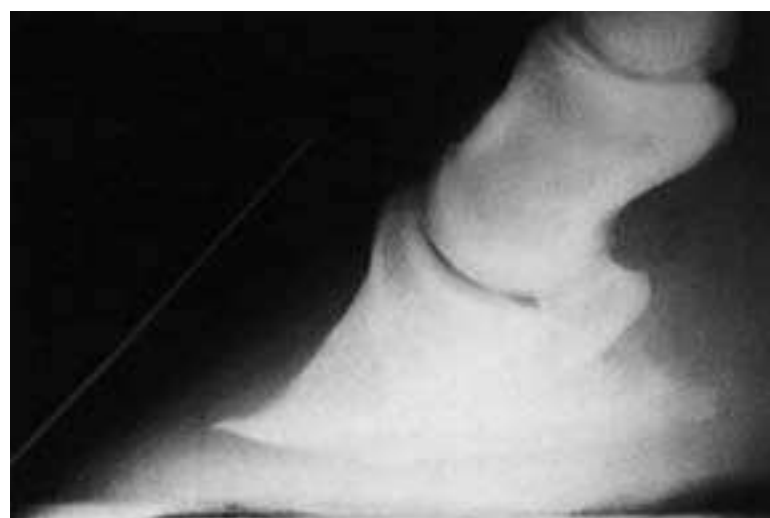

Fig. 28.1.2. Chronic laminitis with brim-like drawn out apical part of the coffin bone owing to rotation of the bone. With this, the parallelism between the dorsal contour of the coffin bone and the hoof capsule (marking line) is lost. (Radiograph, Prof. Dr. Huskamp)

At the coffin bone this is realized by a four-zoned insertion. The collagen fibers radiating out from the coffin bone penetrate one after the other the osseous tissue (1), mineralized (2) and non-mineralized (3) cartilage and thickened connective tissue (4). The decrease in hardness from inside to outside serves to protect against rupture.

The spring-like elastic fixation at the inner coronary horn of the hoof-plate is obtained by the fact that spongy parietal (wall) horn cells, which are structured according to the principle of a subdivided water cushion, “wrap around” and anchor the spongy inner coronary horn tubules in a trajectorial (wagon-like) one-after-the-other arrangement. With laminitis the elasticity of the anchoring is lost because the horn cells of the laminae and the inner coronary tubules lose their sponginess and by this their elasticity.

Besides the two end-fixations, there are two elastic, spring-like intermediary fixations between the parts of the suspensory apparatus of the coffin bone, namely one time at the basement membrane at the level of the dermal-epidermal border (see below) and the other in the epidermal part of the suspensory apparatus at the keratinization border, where ductile vital and keratinized, stiffened avital epidermal cells lie on one another. Because on the one hand the vital cells are stationary owing to their direct or indirect anchoring on the basement membrane (by way of hemidesmosomes) and, on the other hand, the keratinized cells migrate by the thrust of growth, there are two functions (gliding-adhesive-mechanism) combined at the keratinization border, and for this reason, this border is considered the point of fracture in disease of the suspensory apparatus (laminitis).

28.2. Laminitis

Regarding its origin and significance, the German term “Hufrehe” is disputed. The English concept of “laminitis” is more unequivocal and means inflammation of the laminar apparatus, which is located in the wall segment. The concept coincides with our interpretation of laminitis as a disease of the suspensory apparatus of the coffin bone. Laminitis passes through several stages of the disease, which in each case is characterized by typical destructions of the suspensory apparatus.

a. The initial symptomless phase is characterized by disturbances of the blood circulation, especially ischemia, in the blood vascular system of the suspensory apparatus. The cascade of destructions is very difficult and not known in detail (see pathogenesis), and the reactions are partially realized at the molecular level. Depending on the etiology of the laminitis, the initial phase lasts only a few hours in case of traumatic and toxic laminitis, but in case of overloading laminitis lasts much longer, namely about 9 days, before the typical laminitis symptoms set in. [316]



Fig. 28.2.1. Grass-founder in a Przewalski horse. The extremely suffering animal shows the typical body posture with disease of all hooves. Since the front hooves bear about 60% of the weight, they are usually more strongly affected and are for that reason more distinctly relieved than the hind hooves, which are placed forward under the belly. By the forward displacement of the hooves the initially still healthy quarter (hind part) is more strongly loaded and thus the toe of the hoof, the site of the initially strongest disease is somewhat relieved. In a herd of 16 Przewalski horses at the same nutritional level, only the three heaviest horses were diseased; whereas the remaining members of the herd reacted with strong diarrhea. The grass founder episodes appeared during a longer high pressure influence in May with cold nights and high daily temperatures, when certain grasses exhibit a very high fructose content. (Photo, Dr. Scheibe)

b. In case of a peracute, lightning-like, course of the disease, in rare cases it may come to an early loss of the function of the suspensory apparatus, which is reflected in an “exungulation” (loss of the shoe [hoof capsule]).

c. In case of acute or subacute laminitis there is a loosening, overextension and/or partial rupture of the suspensory apparatus, which leads to a slight lowering of the coffin bone. This is visible above the coronet by the formation of an easily palpable cutaneous groove. In the area of expansion of the suspensory apparatus (wall segment), acute inflammations occur, which can spread to the remaining areas of the hoof.

d. With chronic laminitis, considerable destructions in the suspensory apparatus lead to a distinct lowering of the coffin bone or to a more or less distinct rotation of the coffin bone. The latter occurs if the fan-shaped reinforcement of the suspensory apparatus at the tip of the coffin bone is ruptured and the deep flexor tendon exerts a powerful pull (see page 29, below left). The pivot of rotation of the coffin bone is located centrally in the coffin joint, and the parts of the coffin bone, which appear as the points of a triangle – the extensor process (1), palmar/plantar process of the coffin bone (2) with attaching ungular cartilage and the tip of the coffin bone (3) – have the greatest radius of action and cause the worst lesions of the tissues. The blood vessels are most strongly affected. Through them the disorder extends beyond the suspensory apparatus and finally can involve the entire hoof. The tip of the coffin bone may penetrate the horn of the sole and provoke a prolapse of the solear dermis. Especially with neglect of hygiene there develops a colonizing of the coffin bone by germs (osteomyelitis), in which case the prognosis becomes distinctly worsened. According to its severity, there is initially a lengthening (stretching) and finally a necrosis (dying away) of the laminae of the suspensory apparatus, including its vascular bed, and the formation of a new second suspensory apparatus (Fig. 28.1.1. right). This is comparable to the rejection of a traumatized fingernail with a subsequent new nail formation. Under the influence of further existing disease, the new suspensory apparatus forms large masses of degenerated laminar horn with filling horn between them (lamellar wedge under the old hoof capsule = scarhorn shield in clinical usage). The increase in tension in the tissue is an obstacle to growth, hinders the healing of the new suspensory apparatus and contributes to the severe deformation of the hoof, to the formation of the “laminitis hoof” (extreme form = nosed hoof = Knollhuf). If the new suspensory apparatus grows down to the hoof border, it appears as a second white zone (“double white line”). The old suspensory apparatus and the new suspensory apparatus are connected to each other entirely insufficiently by dyskeratotic (pathological) horn masses. Stresses (weight-bearing) result in more ruptures and further steps in the lowering of the coffin bone and rotation of the coffin bone with the symptoms of further

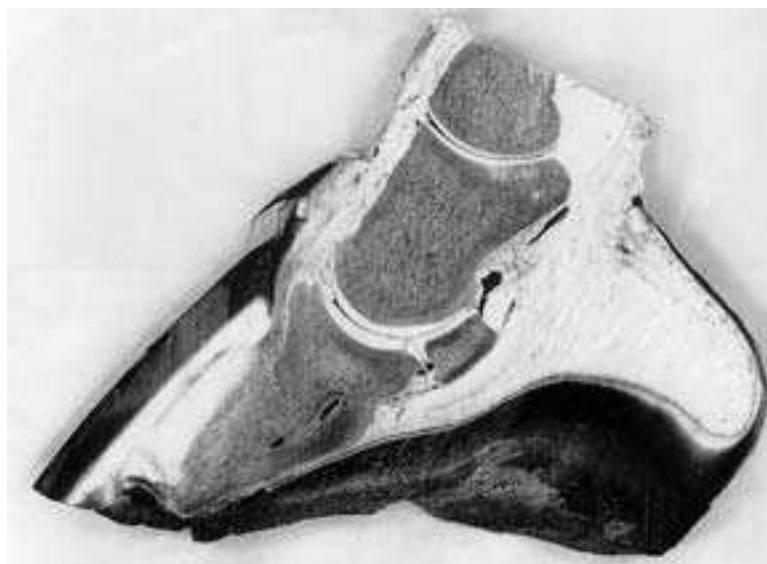


Fig. 28.2.2. Median section through the right front hoof in chronic laminitis. The coffin bone is distinctly rotated and its apex perforates the solear horn. Linear (dark) inclusions of air and exudate characterize the border between the old and the newly arising suspensory apparatus of the coffin bone, whose dyskeratotic lamellar horn masses are called “scarhorn shield.” (Specimen and photo: Dr. Marks)

episodes of laminitis. With this, the tissue just newly formed is destroyed again by massive hemorrhages with toxin formation. e. A phase of exhaustion may follow. In this case, destruction predominates over regeneration. The result is a late exungulation, without prospects for healing.

The **pathogenesis**, the development of the disease with its different phases, is still not clard in all particulars. There are two controversial opinions on the initial events of the disease, the one resting on blood vascular disturbances, the second on a dermoepidermal separation of the basal membrane.

The blood vascular disturbances with dominant vasoconstriction and reduced flow in the capillary bed are caused — according to the advocates of this theory — by vasoactive mediators, among others by biogenic amines. Following this, the thrombocytes are unable, to initiate the necessary elimination of 5-hydroxytryptamine. This substance then develops its vasoconstrictive properties and leads to damage to the tissues. [317] Consequences of the reduced flow and ischemia are later vasoconstrictor paralysis with dilatation of arterioles and venules, which mark the phase of inflammation. [318]

The most recent theory on pathogenesis rests upon a separation in the basal membrane at the dermoepidermal connection area as a result of an imbalance of the metalloproteinases, which among others are activated by endotoxins (*Streptococcus bovis*). [319] The metalloproteinases regulate the anabolism, catabolism and turnover of all compounds of the basal membrane. The basal membrane, consisting of a basal lamina (laminin, fibronectin, collagen type IV) and a fibroreticular lamina (collagens type III and VII), plays a key role in the protection of the epidermis and dermis and accordingly for the suspensory apparatus of the coffin bone. All nutrients and messengers for epidermal differentiation and keratinization pass through the basement membrane in both directions. Reduction in function or even loss of the basement membrane has the most severe effects especially on the avascular epidermis, namely on the mechanical composition (adhesion, separation), the nutritive function and differentiation especially of the epidermis (keratinization and cornification). The abnormal, pathological activation of the metalloproteinases leads to a breakdown of all components of the basal membrane and subsequently to a dermoepidermal separation, whereby the epidermis and parts of the dermis of the suspensory apparatus are sloughed off like a glove from the hand. Inhibitors of the metalloproteinases allow hope for a successful treatment of laminitis. [319] Separations are observed in all forms of laminitis of different etiology also outside of this border region at many sites, both in the dermis and the epidermis. [315]

According to my own assessment there is no validity for the one or other theory to be exclusively right. Both theories have, according to the form of laminitis with specific cause, a right to exist. On the contrary, to the advocates of the separation theory it is not reasonable that metalloproteinases should be exclusively directed to the components of the dermoepidermal basal membrane; whereas, the similarly structured basal membrane of directly adjacent blood

capillaries is unaffected. To that extent, pathological changes of both the epidermal border region and the blood vascular system are significant for the pathogenesis of the laminitis. In the case of overloading laminitis (see below), vascular disturbances are of dominant or exclusive importance.

The etiology of laminitis is manifold. The causes of the disease are decisive for the special designation of the form of laminitis, which can be classified into local and systemic (affecting the entire body) diseases.

A local disease exists in the case of overloading laminitis and traumatic laminitis (perhaps by faulty shoeing) including march-laminitis (a kind of traumatic laminitis with attrition of the terminal dermal villi and hemorrhages provoked by that). Individual hooves may be affected (overloading laminitis) or all hooves. An overloading laminitis can at first develop on a healthy limb if the limb is permanently and doubly loaded because the contralateral limb is primarily diseased (for example by a fracture) and, for that reason, permanently relieved of weight-bearing.

Systemic laminitis comprises the following forms: toxic laminitis including feeding-laminitis and hormonal, including iatrogenic laminitis (caused by the veterinarian owing to application of certain glucocorticoids).

With systemic-toxic laminitis, induction is primarily by endotoxins from general infectious diseases (for example, salmonellosis) or from certain organs (for example, the retention of fetal membranes in the uterus or colic of the intestinal tract). Also in case of a feeding-laminitis an endotoxin effect is present. The feeding-laminitis may develop after uptake of raw grain (whoole corn, rye) or brought about artificially for experimental purposes. The associated grain laminitis depends on weather and season and is triggered by fructanes. At high daytime and low nighttime temperatures with predominating high air pressure (often in the month of May), there occurs in certain grasses a very high content of fructose (fructan).

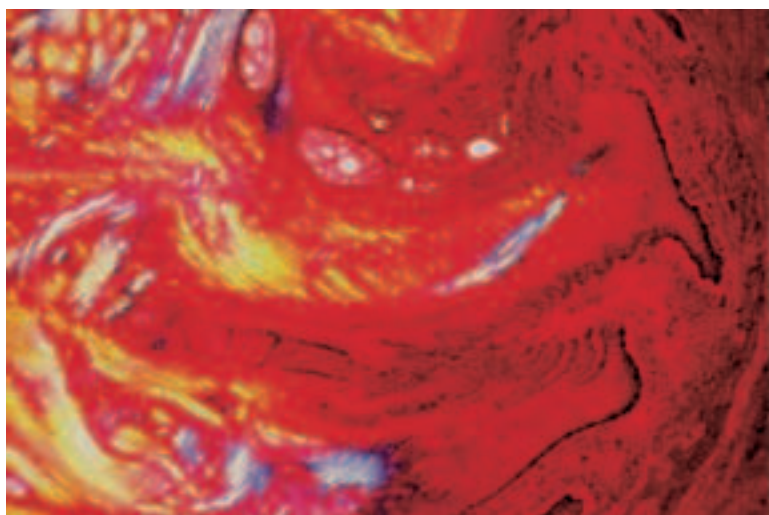


Fig. 28.2.3. Newly formed suspensory apparatus of the coffin bone, whose dermo-epidermal lamellar apparatus is degenerated as a result of pressure-loading and by impediments to growth. The newly formed dystrophic horn-masses (yellow) show no trajectorial alignment of the traction elements. (Specimen photo: Dr. Marks)




Fig. 28.2.4. Chronic hormonal laminitis. Shown are comparable horizontal sections directly above the solear border of the coffin bone, that is to say in the computed tomography section picture (above) and in the anatomical, sawed, section (below). In the dorsal region of the (light) coffin bone, the terminal anchoring of the suspensory apparatus of the coffin bone exhibits lamella-like (serrated) projections of bone (sign of insertional desmopathy). The following intermediary dermis appears dark (radiolucent) and the outer-lying (gray) hoof-plate reveals on the outer end-anchoring of the suspensory apparatus complexes of lamellar horn (individual horny lamellae cannot be seen). In the lamellar horn complexes, the individual horny lamellae are fused with one another by tubular filling horn-nasses similar to the zona alba. This structural change is typical for hormonal laminitis and is probably caused by an elevated cortisol level, which disturbs epidermal differentiation and causes a loss of synchronization in keratinization.

This normally is absorbed in the small intestine. Offered in abundance, this can result in a concentration in the cecum, which is connected to an explosive multiplication of certain bacteria (e. g., *Streptococcus bovis*). The endotoxins produced break the barrier of the cecum and reach the blood circulation. The direct or indirect effect in producing disease of the suspensory apparatus of the coffin bone is still not known in all particulars. [320]

Systemic-hormonal laminitis may develop secondarily due to a tumor (adenoma) of the intermediate part of the pituitary gland. Such tumors occur more often than expected. At the University of Utrecht, The Netherlands, 48 cases were treated. [321] In these cases mostly (secondarily) the adrenal cortex is altered by hypertrophy (Cushing's syndrome). The primary disease and the secondary result are in most cases associated with an elevation of the cortisol and ACTH-level in the blood. The cortisol elevation is also seen in (primary) Cushing's syndrome, which is caused by an adenoma or adenocarcinoma of the adrenal cortex. The elevated endogenous cortisol level induces or reinforces laminitis, because it potentiates the vasoconstrictive action of biogenic amines. Moreover, horn quality is reduced because epidermal differentiation (keratinization and cornification) is affected. Horn of low quality (scar horn) is produced in excess (see Fig. 28.2.4.). [322]

The medicinal application of exogenous cortisol is contraindicated in case of suspected or an outbreak of laminitis, because an existing disorder may be aggravated. Certain cortisol medications may even trigger laminitis (iatrogenic laminitis). [296]

From the knowledge of structural changes and the course of the disease, the following conclusions can be drawn for the precise diagnosis and individual treatment-strategy as well as the prognosis, which is based on it.

In most cases, the diagnosis of "laminitis" can be placed without doubt from the manifestation of pain, posture and movement as well as from the clinical parameters (pulsation, temperature and anamnesis). A differentiating fine diagnosis by application of imaging procedures (x-ray, possibly computed tomography (CT), NMR (nuclear magnetic resonance)) has this objective: To separate pathologically altered and healthy parts of the hoof from each other, to evaluate the degree of lowering and rotation of the coffin bone and – depending on that – the broadening of the white line, which is also relevant prognostically. The computed tomography gives information concerning possible osteomyelitic changes in the coffin bone, concerning location and extent of possible separations between the parts of the suspensory apparatus of the coffin bone and perhaps concerning necrosis of the old and new formation of a replacement suspensory apparatus and – in this case – on the thickness and spread of the "scar-horn-shield" (of the lamellar core of dyskeratotic masses of horn).

In view of the great variety in the course of the disease, the **orthopedic treatment strategy** must take care for the individual needs of the patient.

1. The primary cause of the disease (e.g., a bacterial infection) must be eliminated by treatment of its cause.
2. To reduce the tremendous pain – among other reasons, on account of the inflammation-dependent increase in tissue tonus in the tight hoof capsule – pain medications are applied. These have also an anti-inflammatory effect, because they inhibit the distribution of neuropeptides that foster inflammation at **nerveendings**. [323] Admittedly the "warning signal of pain" will be lacking and may mislead the patient to careless movements, which again possibly may provoke further separations in the diseased suspensory apparatus.
3. To **spare the diseased suspensory apparatus**, stressing movements are restricted to an essential minimum (medications to rest the animal with extension of periods of lying down are supportive in avoiding further phases of coffin bone rotation).
4. Stress (weight-bearing) of the healthy parts of the hoof and the **sparing (unloading) of the diseased parts of the hoof** is necessary. This is done by appropriate horseshoeing or cast bandaging ("suspension" of the dorsal weight-bearing border and thus the sparing of the dorsal part of the suspensory apparatus, which is most strongly affected). [316] [324]
5. **Relief of the tissue tonus** is achieved by orthopedic measures, by rasping off or cutting grooves in the dorsal part of the hoof plate at the level of the coronary wall border, where in many cases an accessory ungular cartilage (*cartilago accessoria*) is formed. This results according to the principle of causal histogenesis and is an expression of increased tissue pressure (see figure, page 29 below).

6. The **aftercare** requires hygienic antimicrobial protection for the barrier of the vital suspensory apparatus of the coffin bone; namely, for the white line [306] so long as this is still defective. This continues up to one year after the inflammation subsides, because the main part of the white line, the horn cells of the parietal laminae, need this time, to grow down from their site of formation at the coronary wall border to the weight-bearing hoof border below. The second component of the white line, the filling horn, is formed much farther distally, beneath the tip of the coffin bone and for this reason is able to regenerate much faster – within about 2 months. For further treatment measures, see textbooks of equine medical science.

Joints of the Pelvic Limb

BIANCA PATAN

30.1. In case of lamenesses of the pelvic limb, the cause of lameness is relatively rarely located in the region of the **hip joint**. Occasionally in small horses and ponies trauma-dependent luxations or subluxations of the hip joint are observed, in which case, the head of the femur is usually displaced craniodorsally. [231] [325] Hip joint dysplasia, which occurs relatively often in human beings and the dog, is described in foals likewise only in isolated cases. [326] Also degenerative changes are rather rare and found usually secondarily following fractures of the acetabulum, injuries to the ligament of the head of the femur or after hip joint dysplasia. Radiographic examination of the hip joint is usually obtained under full anesthesia in dorsal recumbency, but it can also be attempted in the standing position. Sonographic or scintigraphic examination furnishes additional information. [231]

The landmark for **injection of the hip joint** is the greater trochanter, which is sometimes difficult to palpate in horses with a well developed musculature. [114] The needle is introduced between the cranial part (convexity) and the somewhat more proximally directed caudal part (summit) in a slightly craniodistal direction. The needle is advanced along the neck of the femur up to a depth of about 13–14 cm. (Fig. 30.1.). [114] [177] For anesthesia of the hip joint, 25–30 cc of 2% local anesthesia solution is required. [114]

For **arthroscopy of the hip joint**, access can also be selected between the cranial and caudal parts of the greater trochanter in a craniodistal direction. In this way, a large part of the head of the femur and acetabulum, including the ligament of the head of the femur, is demonstrable. Further access for instruments is possible 4–6 cm cranial to the arthroscopic portal. [327]

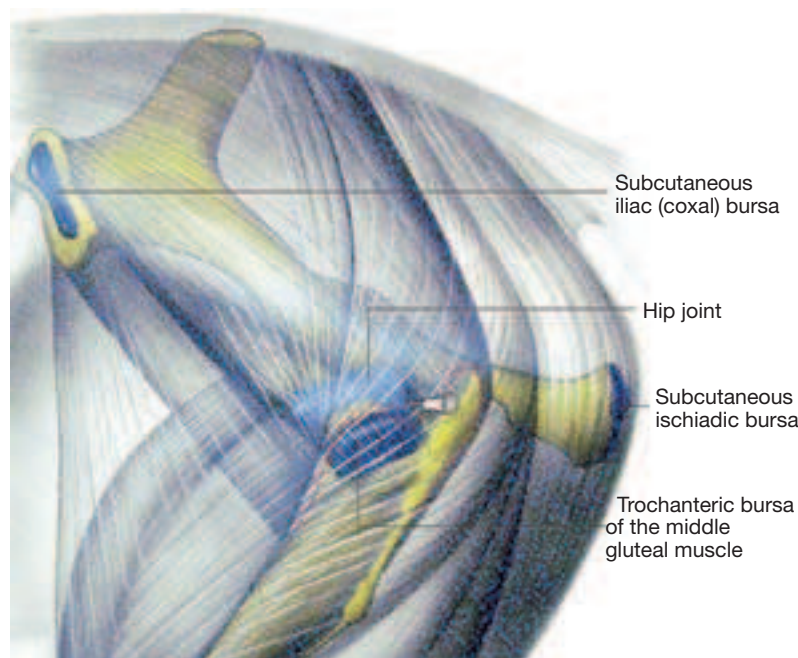


Fig. 30.1. Injection of the hip joint. (Courtesy of Institut f. Veterinär-Anatomie, Berlin)

30.2. The stifle joint is composed of three synovial spaces (femoropatellar joint as well as lateral and medial femorotibial joints), which are connected to one another in a variable manner. A communication between the femoropatellar and the medial femorotibial joint is most frequent (60%–80%); whereas, the lateral femorotibial joint communicates with the femoropatellar joint relatively rarely (about 3%). [328]

The joint capsule of the femoropatellar joint comprises a spacious joint cavity, which extends proximally under the quadriceps muscle (**suprapatellar recess**). [179 [176] The lateral femorotibial joint forms the **subextensor recess**, which projects about 4–7 cm distally beyond the bony joint plane and ensheaths the common tendon of origin of the long digital extensor muscle and fibularis (peroneus) tertius muscle in the extensor groove of the tibia. [329] This relatively large joint outpouching is to be monitored especially in case of injuries in the region of the stifle joint. A further outpouching of the lateral femorotibial joint is present under the tendon of origin of the popliteus muscle. [186]

An increased filling of the femoropatellar joint sac is usually palpable as a fluctuating increase in girth between the patellar ligaments. If the limb is weight-bearing the latter are present as firm, band-like structures between the patella and the proximal tibia (Fig. 30.2.1.). The intermediate patellar ligament, which corresponds to the end-tendon of the quadriceps femoris muscle, is underlain by a bursa (proximal or, respectively, distal infrapatellar bursa) in its region of origin on the patella as well as at its insertion on the tibial tuberosity (Fig. 30.2.3.). An inflammatory increase in size of the synovial bursa, like the infrapatellar fat pad between the medial or intermediate patellar ligament and the joint capsule, may simulate an increased filling of the femoropatellar joint sac. [176]

The stifle joint has great clinical importance, because about 15% of the cases of pelvic limb lameness are caused by changes in the region of the stifle joint. [231] Bone lesions due to osteochondrosis as well as subchondral bone cysts or cyst-like defects play a special role. [277] The most frequent soft tissue problem is proximal patellar fixation; whereas, injuries to the menisci or the different ligamentous structures (cruciate ligaments, collateral ligaments, patellar ligaments, and meniscal ligaments) are rather rarely diagnosed in the horse. [277]

A developmental disorder in the region of the articular cartilage is designated **osteochondrosis**, in which case, on the pelvic limb the talocrural and stifle joint are affected most often. [330] Osteochondrotic changes of the stifle joint develop mostly at foal age between the 2nd and 11th months of postnatal life [277]. They are for the most part temporary and may spontaneously reduce. [330] Lesions, which are still demonstrable at the 8th month of postnatal life, are on the other hand usually permanent. [330] To be sure, the osteochondrotic lesions become clinically relevant frequently only distinctly later when training or heavy work begins. [231] [331] The

cause of such defects is multifactorial, in which case, among others, nutrition, husbandry and genetic factors as well as endocrinologic dysfunctions, mineral imbalances, biomechanical trauma and rapid growth rate are discussed. [332 [333] [334] Most often the osteochondrotic changes are located in the middle area of the lateral ridge of the trochlea; [330] [277] more rarely, the changes occur on the distal articular surface of the patella, on the medial ridge of the trochlea or between the two ridges. [277] [331] Typical radiographic changes are large surface irregularities in contour or a flattening of the bone surface or a fragmenting of a cartilage-bone squame. [231] [335] Sonographic examination gives additional information about the surface of the cartilage. [329] Treatment of the affected foals may be a conservative one. [335] In the case of older horses with clinical signs a surgical procedure (arthroscopic curettage of the altered cartilage or removal of the fragment) is indicated. [231] [331]

Subchondral bone cysts or **cyst-like defects** in the stifle joint are most often located in the medial condyle of the femur, more rarely distolaterally on the femur in the neighborhood of the intercondylar fossa or proximally on the tibia. [231] [277] The exact cause of such lesions is not known. Discussion of triggering factors includes, among others, traumatic defects of cartilage and subchondral bone, [336] gonitis as well as osteochondrotic changes. [337] Besides conservative treatment also a surgical procedure is described in the form of an arthroscopic curettage of the defect. [231] [337]

The two **menisci** of the stifle joint are fixed to the tibia by cranial and relatively short caudal ligaments. Additionally, the lateral meniscus is fixed to the caudomedial femur by the meniscofemoral ligament; whereas, the medial meniscus is associated with the medial collateral ligament (Figs. 30.2.1. and 30.2.2.). [176] Lesions of the menisci in the form of vertical and longitudinal tears involve predominantly the medial meniscus, in which case the lesions are mostly localized at the cranial pole. [231] [277] [338] Often lesions occur at the same time on the articular cartilage as well as at the cranial, more rarely at the caudal, meniscal ligament, which may result in instability of the meniscus. [231] [339]

The **collateral ligaments** originate on the medial or, respectively, lateral epicondyle of the femur. [186] The attachment of the medial collateral ligament is to the medial condyle of the tibia with an intermediate insertion to the medial meniscus; [176] whereas, the lateral collateral ligament inserts only on the head of the fibula (Fig. 30.2.1.). [186] Lesions of the collateral ligaments due to trauma are observed especially in jumpers, in which case the medial ligament is more often involved and may be damaged together with the medial meniscus. [277] Beyond that, especially in jumpers, there sometimes occur also lesions of the intermediate, more rarely of the lateral, patellar ligament. [231]

The **cruciate ligaments** connect the femur to the tibia in the center of the stifle joint and give the joint its cranio-caudal stability.

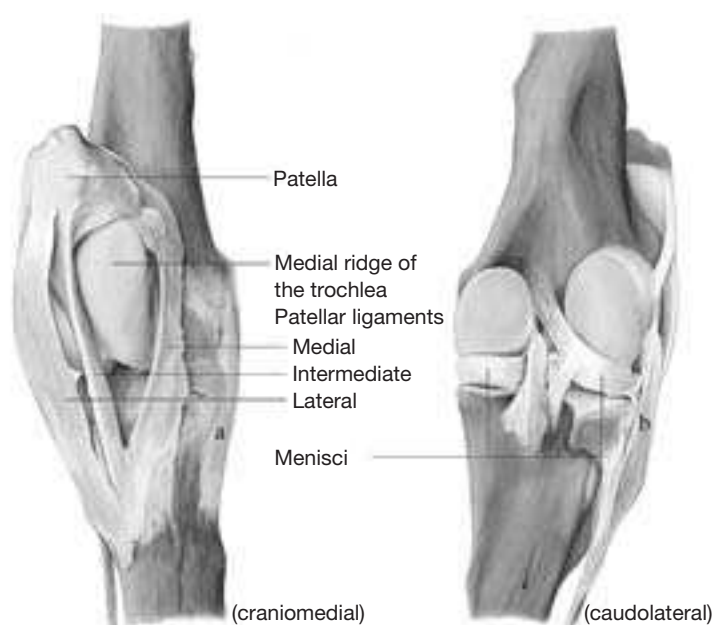

Fig. 30.2.1. Knee (stifle) joint of the right pelvic limb. **a:** medial collateral ligament, **b:** lateral collateral ligament. (Courtesy of Institut f. Veterinär-Anatomie, Berlin)

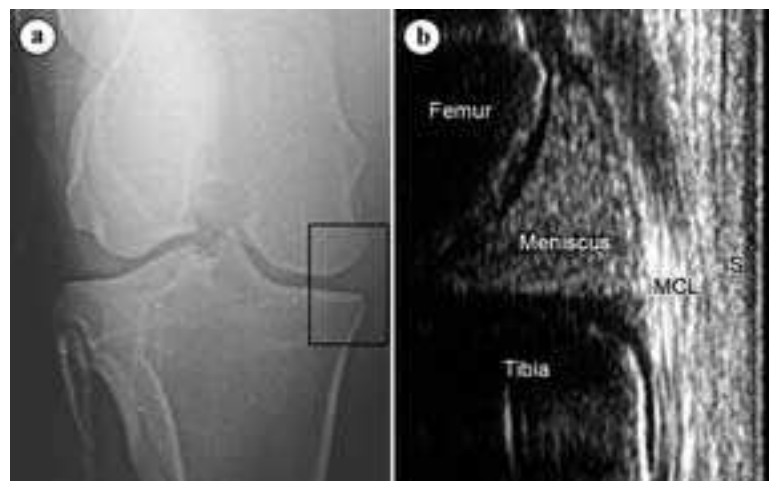

Fig. 30.2.2. **a)** Craniocaudal radiograph of a stifle joint. The rectangular frame shows the location of the sonogram. **b)** sonogram of the medial meniscus (longitudinal, linear array scanner 7.5 MHz). **S:** skin, **MCL:** medial collateral ligament. (Sonogram: Dr. J. Edinger, Chirurgische Tierklinik, Universität Leipzig)

The cranial cruciate ligament originates craniomedial to the intercondylar eminence of the tibia and inserts caudolaterally in the intercondylar fossa of the femur. The origin of the caudal cruciate ligament is caudomedial on the tibia, its insertion is craniomedial in the intercondylar fossa of the femur. [329] Traumatically conditioned lesions concern predominantly the cranial and only seldom the caudal cruciate ligament. [231] Frequently, partial tears develop either in the middle of the ligament or near its cranial attachment to the tibia, [231] [277] in which case occasionally also avulsion fractures of a bone fragment can occur. [277] Defects in the region of the caudal insertion on the femur are rather rare. [277] Sometimes lesions of the cruciate ligaments appear together with other soft tissue changes (for example, lesions of the menisci) or fractures in the region of the intercondylar eminence of the tibia. [340] [341] The so-called “drawer syndrome” (abnormal displacement of the thigh and crus against one another) can be produced manually in man and dog to demonstrate cranio-caudal instability in cruciate ligament ruptures. It cannot as a rule be demonstrated in the standing horse with cruciate ligament rupture. [231] [277]

The soft tissue changes mentioned are, for the most part, demonstrable by **sonography** (Fig. 30.2.2.). In doing this, the stifle joint is examined from cranial and caudal, in which case the following can be demonstrated: the collateral ligaments, patellar ligaments, the joint capsule of the femoropatellar and femorotibial joints, parts of the cartilaginous or bony surface of the joints (especially the cranial and caudal third of the ridges of the femoral trochlea), the meniscal ligaments (but not the caudal ligament of the medial meniscus), parts of the menisci, the common origin of the long digital extensor and peroneus tertius muscles as well as the tendon of origin of the popliteus muscle. [329] [231] Even the cruciate ligaments can be identified; however, the diagnostic value of sonographic demonstration is questionable. [231] Diagnostic arthroscopy of the stifle joint provides additional information (section 3.2). If soft tissue lesions are associated with chip-fractures or bony excrescences, then radiographic changes can sometimes also be demonstrated. [231] [277]

Because of the varying communications between the three synovial compartments of the stifle joint, the synovial cavities must be injected individually in performing **intra-articular anesthesia**. [177] The medial femorotibial joint is accessible between the medial patellar ligament and the medial collateral ligament. For the injection of the joint, the needle is introduced about 1–2 cm proximal to the palpable border of the tibia perpendicularly through the skin and advanced nearly horizontally into the joint. [114] [184] Injection of the lateral femorotibial joint is possible between the tendon of the long digital extensor muscle and the lateral collateral ligament, directly proximal to the lateral border of the tibia. In doing this, the needle is introduced in a horizontal and slightly caudal direction (Fig. 30.2.3., 1). Alternatively, the joint can be injected at

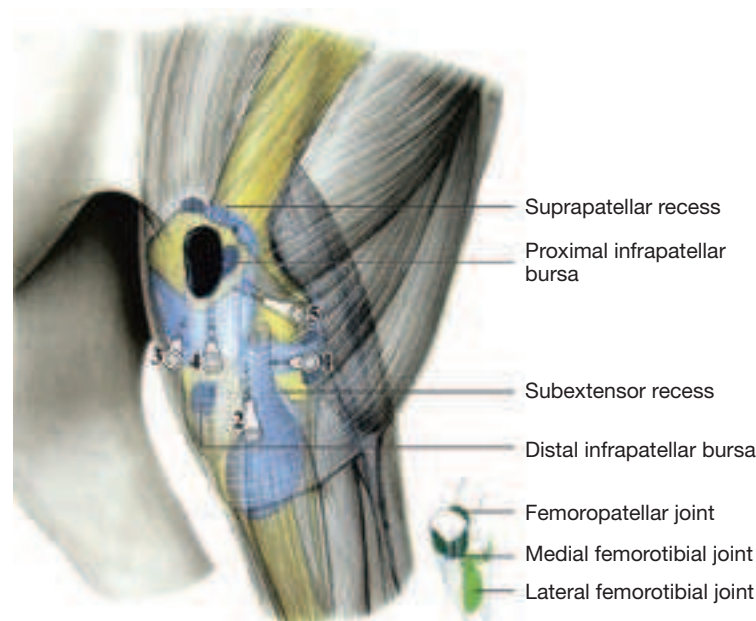


Fig. 30.2.3. Injection of the lateral femorotibial joint: between the long digital extensor muscle and the lateral collateral ligament (1) or in the subextensor recess (2), injection of the femoropatellar joint: (3)/(4) cranial access, (5) lateral access. (Courtesy of Institut f. Veterinär-Anatomie, Berlin)

the same level between the tendon of the long digital extensor muscle and the lateral patellar ligament. [114] [184] A further possibility for injection of the joint is by way of the subextensor recess. In doing this, the needle is introduced directly cranial to the common tendon of origin of the long digital extensor and peroneus tertius about at the level of the tibial tuberosity. The needle is directed proximomedially (Fig. 30.2.3., 2). [176] [273] Injection of the femoropatellar joint is lateral or medial to the middle patellar ligament 2–4 cm proximal to the tibial tuberosity. [328] In this case, the needle is introduced perpendicular to the skin or directed slightly proximally (30.2.2., 3/4). Alternatively, injection of the femoropatellar joint is possible from the lateral side. For this, the needle is introduced caudal to the lateral patellar ligament about 5 cm proximal to the lateral tibial condyle and perpendicular to the long axis of the femur. The needle is advanced (about 1.5–2 cm) into the joint between the lateral patellar ligament and the lateral ridge of the trochlea (Fig. 30.2.3., 5). [343] For anesthesia, about 20–30 cc of 2% anesthesia solution is injected into the corresponding joint. [114] In interpreting joint anesthesia, the fact that the three joints can partially communicate is a consideration. [328] Moreover, in the stifle joint a diffusion of the anesthesia solution into the neighboring joint compartments must be taken into account. [344]

For **arthroscopy** of the stifle joint, see p. 113.

30.3. The hock joint (tarsal joint) is composed of different joints, which in part have their own synovial cavities. The **tarsocrural joint** (talocrural joint), which is located between the tibia and the talus, is mainly responsible for the mobility of the tarsal joint. It has four recesses, which bulge outward with increased filling of the joint (so-called **bog spavin**). [176] The two dorsal outpouchings lie medial and lateral to the extensor tendons (long digital extensor m., peroneus tertius m. and cranial tibial m.). [345] The two plantar pouches are found proximoplantar to the medial and lateral malleolus of the tibia. [176] There is always a communication with the **proximal intertarsal joint** (talocalcaneal-centroquartal joint)^a, a tight joint between the proximal and middle rows of the tarsal bones. [114] [176] A second tight joint with a certain clinical relevance is the talocalcaneal joint, which is between the talus and calcaneus and also communicates with the tarsocrural joint. [346] Also the **distal intertarsal joint**^b (centrodistal joint) between the middle and distal rows of the tarsal bones as well as the **tarsometatarsal joint** (between the distal row of tarsal bones and Mt II–IV) are tight joints, which scarcely permit mobility. [176]

In about one third of horses the tarsometatarsal joint communicates with the distal intertarsal joint, [347] [348] in which case the synovial cavities communicate in particular in the region of the tarsal canal as well as between the third tarsal bone and the fused first and second tarsal bones. [65] In very rare cases even a communication of the tarsometatarsal joint with the proximal intertarsal and tarsocrural joint was observed. [347]

Diseases of the tarsal joint are one of the most frequent causes of lameness in the athletic horse. Degenerative joint changes (**spavin**), which usually appear bilaterally, play a special role. [349] The distal intertarsal and the tarsometatarsal joint are encountered most frequently [349] [350] more rarely, the proximal intertarsal or talocalcaneal joint. [346] [350] The disease commonly appears in older athletic horses, but it may occur also in young animals (juvenile spavin). [349] Icelandic horses seem to have a special predisposition. [351] A frequent clinical sign is a lameness or stiffness of the hind limb, which improves with movement. The flexion test of the hock joint (so-called “spavin test”) as a rule exacerbates the lameness and also pressure palpation in the medial region of the distal tarsus (Churchill test) is often painful. [349] Radiographically, there can be demonstrated, among others, a narrowing of the joint space, subchondral areas with sclerosis (bone densities) or osteolysis (bone dissolution) as well as periarticular bone excrescences (Fig. 30.3.1., a). [349] [352] Typically the radiographic changes are first developed dorsomedially (in Icelandic horses, to be sure, rather dorso-lateral) at the level of the distal tarsal joints and may be palpable or even visible in advanced cases. [349] [351] Especially in trotters, sometimes also inflammatory changes in the region of the medial

^a according to the Nomina Anatomica Veterinaria (1994) two joints are distinguished: Art. talocalcaneocentralis and Art. calcaneoquartalis

^b according to the Nomina Anatomica Veterinaria (1994): Art. centrodistalis

end-tendon of the cranial tibial muscle (cunean tendon) or the underlying synovial bursa (cunean bursa) are present. [264] [353] Increases in bone tissue or soft tissue changes can lead to an increase in girth in the medial region of the distal tarsal joints (so-called “spur-knot”). [349] Conservative possibilities of treatment include orthopedic shoeing, including correction of the hoof, systemic and local medication as well as an adaptive exercise program. [354] [352] More recently, the application of shock waves is recommended. [355] If the conservative treatment is insufficient, different surgical measures of treatment can be applied. There is described, among others, a partial removal of the articular cartilage of the distal intertarsal or of the tarsometatarsal joint to further ankylosis (stiffening) of the corresponding joint, [356] [354] [352] a tenectomy (section and partial removal) of the cunean tendon, [354] [353] drilling of the subchondral bone of tarsal III, the central tarsal bone, and metatarsal bone III for the reduction of intraosseous pressure, [354] [357] as well as a neurectomy of the deep peroneal and partially the tibial nerve. [358]

A further important disease of the hock joint is **osteocondrosis** within the talocrural joint, which is relatively often present especially in trotters and warmblood horses. [359] [330] [65] [360] Typical locations of osteochondrotic changes are the cranial sagittal ridge of the tibia (86–95%), and the distal region of the lateral ridge of the trochlea of the talus (5–11%). [330] [65] Occasionally also the medial malleolus of the tibia or the medial ridge of the trochlea of the talus is encountered. [361] [362] Radiographically, there is visible an irregular contour or flattening of the subchondral bone-surface or fragmentation of a cartilage-bone chip (Fig. 30.3.1., 6) is established, [330] in which case the changes frequently occur bilaterally. [65] Additional information on the cartilage-bone surface can be obtained by sonographic examination. [363] Osteochondrotic lesions often develop already in the first postnatal month, are for the most part only temporary, and can regress spontaneously. Changes that are still found at 5 months are on the other hand usually permanent. [330] Clinical signs (increased filling of the joint/lameness) however occur often at a later time, when the heavy work begins. [361] If such clinical signs are present, a surgical treatment (arthroscopic curettage of cartilage or removal of the fragment) is indicated. [361] [362]

Injection of the tarsometatarsal joint is realized plantarolaterally, directly proximal to the lateral splint bone, where a slight depression can be palpated. The needle is introduced into this depression between the splint bone and the tarsal bone IV in a dorsomedial and slightly distal direction (Fig. 30.3.2., 5). [114] [364] For anesthesia of the tarsometatarsal joint, 4–8 cc of 2% local anesthesia solution

is injected. [114] In interpreting joint anesthesia, the relatively frequent communication of the tarsometatarsal joint with the distal intertarsal joint is to be noted. [347] [348] Also, owing to diffusion, desensitization of neighboring structures (proximal joint compartments of the tarsal joint, [344] tarsal synovial sheath, insertion of the peroneus tertius and cranial tibial muscles as well as dorsal and plantar metatarsal nerves [348]) are possible.

Injection of the distal intertarsal joint is performed from the medial side in the region of a depression between the fused tarsal bone I+II, tarsal bone III and the central tarsal bone. [365] [364] The needle is introduced through or directly distal to the medial end-tendon of the cranial tibial muscle (cunean tendon) perpendicular to the skin (Fig. 30.3.2., 3). [114] [365] Alternatively, arthrocentesis of the distal intertarsal joint can be performed via a dorso-lateral approach, directly lateral to the long digital extensor tendon (Fig. 30.3.2., 4). [365a] For anesthesia of the joint, an injection of 4–5 cc of 2% local anesthesia solution is needed. [114]

Injection of the talocrural joint is usually realized at the dorso-medial outpouching of the joint sac, in which case the needle is introduced perpendicularly through the skin about 2.5–4 cm distal to the well palpable medial malleolus of the tibia either cranial or caudal to the cranial branch of the medial saphenous vein (Fig. 30.3.2., 1). [188] [194] In case of greater filling of the joint, alternatively the plantarolateral recess may also be injected (Fig. 30.3.2., 2). [114] For anesthesia of the talocrural joint, 20–30 cc of 2% anesthesia solution is injected into the joint, [114] in which case the proximal intertarsal joint is always also desensitized, since both synovial spaces communicate. [114] [188]

For **arthroscopy of the talocrural joint**, see p. 113.

The details of the digital joints of the pelvic limb correspond to the relations on the thoracic limb.

The **long plantar ligament** originates proximoplantarly on the calcanean tuber, runs distally plantarolaterally and attaches to the lateral splint bone (Mt IV) as well as the fourth tarsal bone and distally on the calcaneus. An inflammatory thickening of this ligament is visible in lateral view as a swelling (curb) on the plantarodistal region of the tarsus. [366]

30.4. The trochanteric bursa, which lies deep to the tendon of insertion of the middle gluteal muscle on the greater trochanter of the femur (Fig. 30.1), can occasionally be affected by inflammation. For injection of this synovial bursa, the needle is introduced directly at the level of the cranial part of the greater trochanter. It is directed horizontally through the skin and advanced until there is contact with bone. [367]

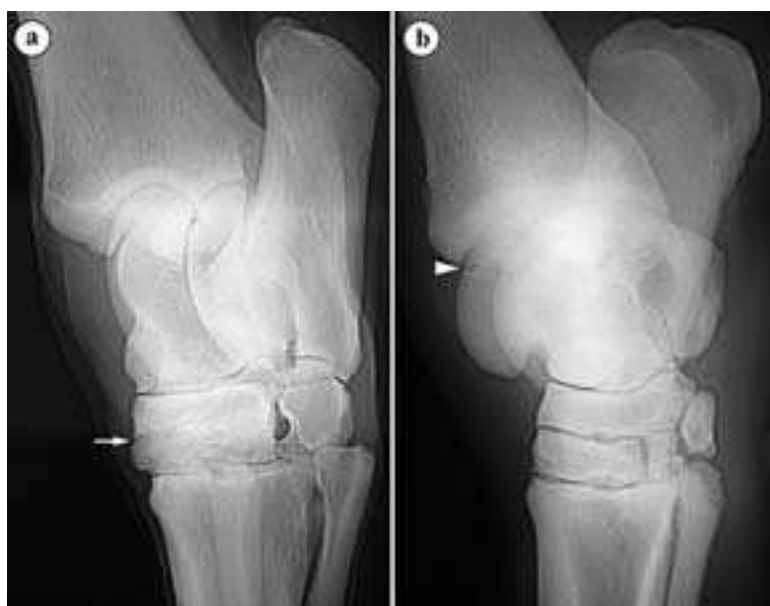


Fig. 30.3.1. a) hock joint with spavin changes: distal intertarsal joint nearly completely fused (arrow), 15 years Arabian mare, b) osteochondrosis dissecans in the hock joint: chip on the sagittal crest of the tibia (arrowhead), 2 years Appaloosa stallion. (Courtesy of Klinik für Orthopädie bei Huf- u. Klautentieren, Veterinärmed. Univ. Wien)

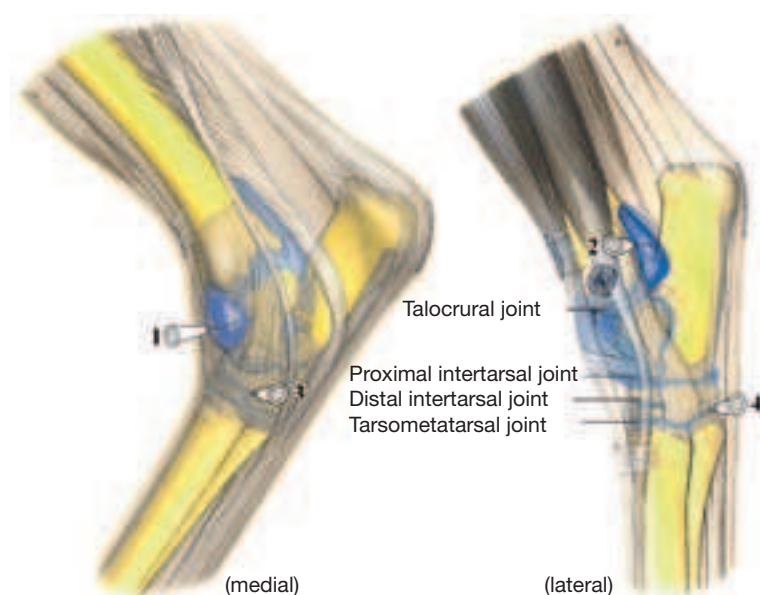


Fig. 30.3.2. Injection of the hock joint: Access in the dorsomedial (1) or plantarolateral (2) recess of the talocrural joint, medial (3) and dorsolateral (4) approach to the distal intertarsal joint, (5) injection of the tarsometatarsal joint. (Courtesy of Institut f. Veterinär-Anatomie, Berlin)

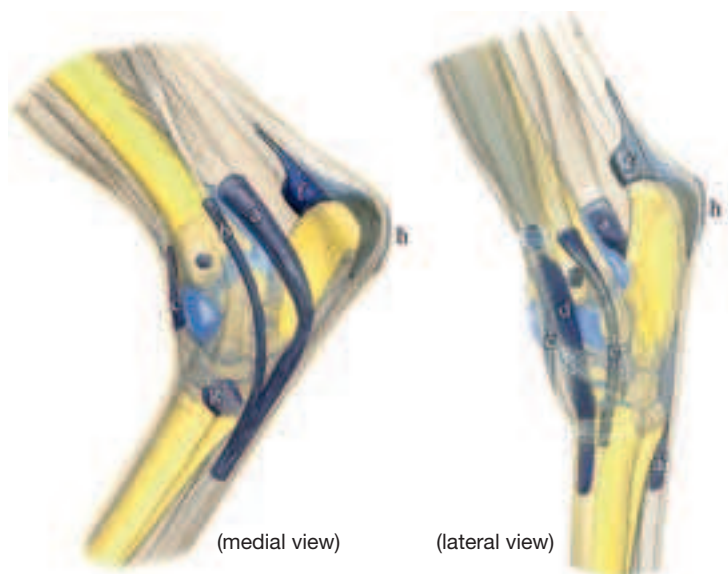


Fig. 30.5. Tendon sheaths and synovial bursae in the tarsal region.

a: common tendon sheath of the lateral digital flexor muscle and the caudal tibial muscle, **b:** tendon sheath of the medial digital flexor muscle, **c:** tendon sheath of the tibialis cranialis muscle, **d:** tendon sheath of the long digital extensor muscle, **e:** tendon sheath of the lateral digital extensor muscle, **f:** subtendinous calcaneal bursa of the superficial digital flexor muscle, **g:** subtendinous bursa (cunean bursa) of the tibialis cranialis muscle, **h:** subcutaneous calcaneal bursa. (Courtesy of Institut f. Veterinär-Anatomie, Berlin)

30.5. An increased filling of the **subtendinous calcaneal bursa of the superficial digital flexor muscle** is also called “**deep capped hock.**” [273] A typical sign is an increased thickening medially and laterally under the superficial digital flexor tendon in the region of the calcaneus. It is, as a rule, a fluctuating swelling. [114] If, on the other hand, the **calcaneal subcutaneous bursa** is increasingly filled, then a locally circumscribed increase in girth can be observed over the calcaneal tuber between the superficial flexor tendon and the skin (so-called “**capped hock**”; Fig. 30.5.). [273]

30.6. The **subtendinous bursa of the cranial tibial muscle** (*B. diekerhoffi*, **cunean bursa**) is found under the cunean tendon in the area of its insertion at the fused first and second tarsal bones (Fig. 30.5.). Inflammation of the synovial bursa or tendon may occasionally play a role in spavin. [264] For the injection of the bursa, the needle is introduced through the cunean tendon and advanced until bone is contacted. [114] [307] Alternatively the injection can be made directly distal to the cunean tendon, in which case, following this, the needle is advanced proximally under the tendon. [114] For anesthesia of the bursa, 3–5 cc of 2% local anesthesia solution is necessary. [114] [367]

30.7. The **tarsal flexor tendon sheath** surrounds the different constituents of the deep flexor tendon in the tarsal region. [114] It begins proximally at the level of the tuber calcanei and extends distally up to 7 cm distal to the tarsometatarsal joint. [114] [368] In case of an increased filling of the synovial sheath, this becomes visible especially medial to, sometimes also lateral to, the calcaneus as a swelling (**thoroughpin**). [369] [368] Owing to the relatively tight flexor retinaculum, an indentation is visible in the middle region. [114] Because the proximal part of the tarsal flexor tendon sheath lies in the direct neighborhood of the plantar recess of the tarsocrural joint (Fig. 30.5.), [114] [368] in cases of injuries in the plantar tarsal region an opening of the two synovial structures must be taken into consideration in a differential diagnosis. Injection of the synovial sheath can be realized in its proximal or distal out-pouching, in which case 10–15 cc of 2% local anesthesia solution is required for the anesthesia. [114]

The other synovial structures in the tarsal region, which have to be considered in case of injuries, are demonstrated in Fig. 30.5.

32.1. Temporal fossa (p. 33.j): The temporal fossa lies dorsal and medial to the zygomatic process of the squamous part of the temporal bone as well as caudal to the zygomatic process of the frontal bone. Besides the temporalis muscle, it contains fat tissue (= extraperiorbital fat body). In old and chronically sick horses, the fat body is for the most part reduced and for this reason, this part of the temporal fossa becomes distinctly visible.

32.2. Age-determination by Examination of the Teeth

Age-determination by examination of the teeth permits a fairly exact determination of age up to about the 8th year. After that, race, feeding and maintenance play an increasing role as factors of uncertainty, which permit only an approximate estimation of age and require a cautious diagnosis. Phrasings like “an estimate of dental age of 14–15 years” are advisable. For age determination or estimation by examination of the teeth the criteria mentioned below are considered. These should be applied, as much as possible, in combination and not individually. The ranking corresponds to the importance in respect of the accuracy of age estimation by examination of the teeth.

Eruption of the deciduous premolars, P2–P4, takes place before, and that of the other teeth after, parturition in certain time-intervals. An approximate rule of thumb for age determination is that deciduous incisor 1 erupts on the 6th day, deciduous incisor 2 in the 6th week, and deciduous incisor 3 in the 6th month. Eruption of the first molar of the mandible takes place just before the end of the first year after parturition. During the intensive growth of the tooth at the time of eruption, the root of the tooth causes temporarily a more or less distinctly visible and palpable elevation (“**bump**”) at the ventral margin of the mandible, which can be considered for the estimation of dental age (see radiograph, Fig. 32.2.1.) with a bump under the root of the first molar). Corresponding bumps occur temporarily and in succession under the roots of the erupting permanent premolars of two to four years old horses. The growth of these permanent premolars causes a pressure on the deciduous teeth that “ride” above them and in the same manner in the opposite direction on the ventral margin of the mandible, which is bowed ventrally as bumps in the region of the concerned dental roots. After the eruption of the teeth and the elimination of the deciduous teeth, the upper obstacle is removed, the ventrally directed pressure ceases, and the bumps disappear (Fig. 32.2.1.).

The **change** of the incisor teeth takes place at 2? years (incisor tooth 1) or 3? years (incisor tooth 2) or 4 years (incisor tooth 3). A premature loss of deciduous teeth, for example in case of fraudulent “breaking of teeth”, causes a premature eruption of the permanent tooth, by which an older age would be simulated. The inspection of the eruption of the teeth requires a clear separation between deciduous and permanent teeth. The deciduous teeth are much smaller and on the incisor teeth reveal a narrowing as a dental neck. The crown, which is not covered by the gums (clinical crown), is brightly white because it is not covered by yellowish cementum.

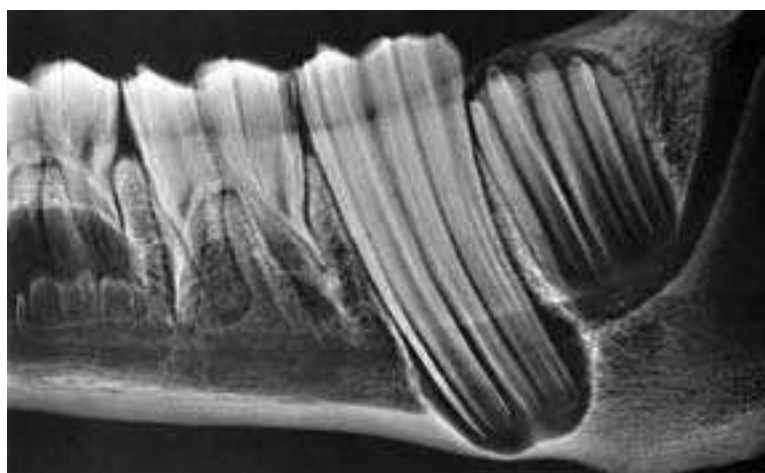


Fig. 32.2.1. Mandibular cheek teeth. The last premolar (left) is found as a deciduous tooth in wear and is underlain by the permanent tooth. The 2nd molar is shortly before its eruption. M1 causes a bump on the ventral margin of the mandible. (Courtesy of Prof. Dr. Poulsen Nautrup)

The **attrition of the tooth** starts about 6 months after eruption, when the antagonists come into contact. With physiological attrition the permanent incisor teeth will be worn down about 2 mm annually. Because the cups of the mandibular incisors with about 6 mm are perhaps half as long as those of the incisors of the upper jaw with at least 12 mm, it is clearly understandable that the cups of the mandibular incisors disappear earlier (Fig. 32.2.4.).

The **disappearance of the cup** is finished with the loss of the enamel spot (and of the cementum filling at the bottom of the cup). Because the cup and the pulp cavity labial to it overlap each other, the dental star becomes visible before the final disappearance of the cup. The dental star corresponds to the distal part of the pulp cavity, which is filled by secondary dentine. Exposure of the pulp cavity is prevented by formation of the secondary dentine. The disappearance of the cup is important for ageing by teeth and takes place on the deciduous mandibular incisors at the age of 1 year (i1), or 1, 5 (i2), or 2 years (i3); on the permanent mandibular incisor teeth at the age of 6 years (I1), or 7 years (I2) or 8 years (I3).

The **change of the form** of the occlusal surface is also an important criterion for the ageing by teeth. The originally transverse-oval occlusal surface (from 6 years on I1) is continued by a round (from 12 years on I2), then by a triangular (from 18 years on I3) and final-

ly by a long-oval occlusal surface (from 24 years at I1) (Fig. 32.2.4., A-E).

The **curvature of the incisor arcade** is at first semilunar and flattens more and more to a “flattened” arch at 17 years of age, which extends up to the 23rd year of age to a nearly straight arch and after that finally appears “straight” (Fig. 32.2.5.).

The **angle between the incisor teeth** of the upper and lower jaws becomes increasingly more acute. Up to the age of 8 years the teeth meet at an angle of about 180°. They stand roughly perpendicularly to one another. Up to the 16th year of age the position of the mandibular incisors flattens distinctly in comparison to the still steeply located incisors of the upper jaw. At the age of about 16 years, the angle is about 135°. In older animals also the incisors of the upper jaw stand increasingly flatter and from this results an angle of about 90° (angular dentition at the age of about 25 years). After this, the angle becomes still smaller in very old age (pointed angular dentition at the age of about 30 years; Fig. 32.2.6.).

Galvayne's (G) groove is a longitudinal groove on the vestibular surface of the corner incisor of the upper jaw. At an age of about 10 years the groove appears proximally under the gum. At about 15 years it extends over the proximal half and at the age of about 20 years over the entire extent of the (clinical) dental crown of the



Fig. 32.2.3. Longitudinal section through permanent P3 and I1 of the mandible. Both teeth still show signs of growth by their wide access to the pulp cavity. The premolar cheek tooth (left) is still not in wear and distinctly reveals the three tooth constituents. The bright white enamel borders externally on the dark cementum and internally on the lighter (striped) dentine, which is completely retained the entire length of the tooth up to the occlusal surface. The incisor tooth (right) is extensively covered by the gum and is fixed within the bony alveolus and anchored by the periodontium. (Courtesy of Institut f. Veterinär-Anatomie, Berlin)

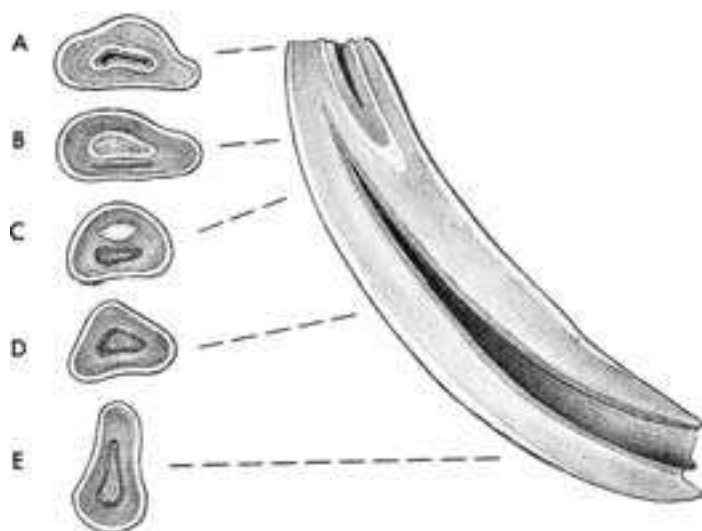


Fig. 32.2.4. Longitudinal section through the middle incisor (I2) of the lower jaw with opened pulp cavity and infundibulum. The occlusal surfaces show from above to below: A. Beginning in wear, occlusal surface transverse-oval (5 years). B. On the occlusal surface, which is still transverse-oval, the dental star appears as a dark streak labial to the infundibulum (9 years). C. On the rounded occlusal surface the transverse-oval, dark dental star lies labial to the white enamel spot (12 years). D. Triangular occlusal surface with dental star (18 years). E. Long-oval occlusal surface with dental star (24 years).

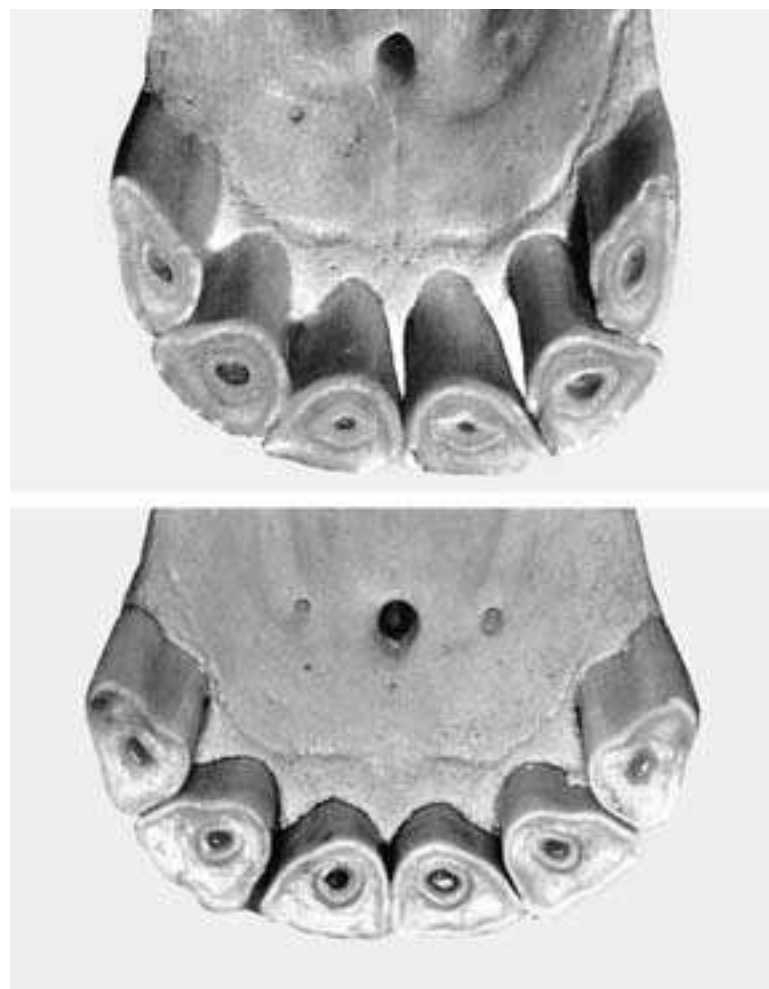
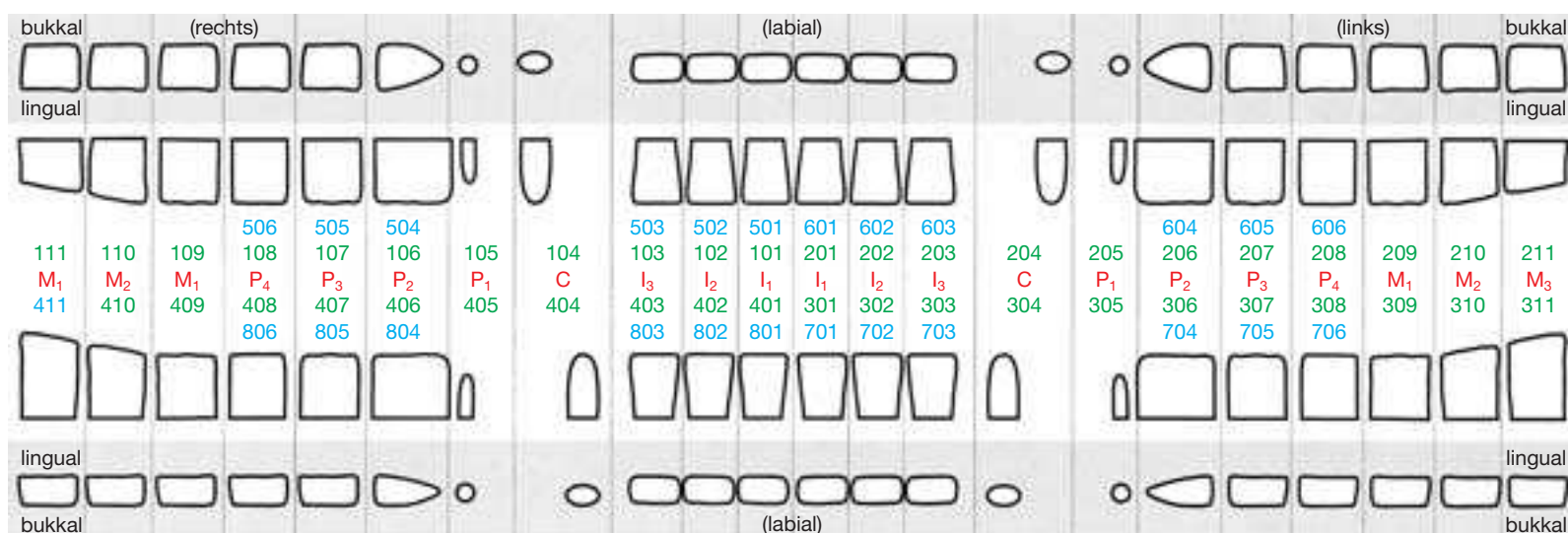


Fig. 32.2.5. Semilunar arcade of the incisor teeth (Fig. above) and flatter arcade of the incisor teeth (Fig. below).

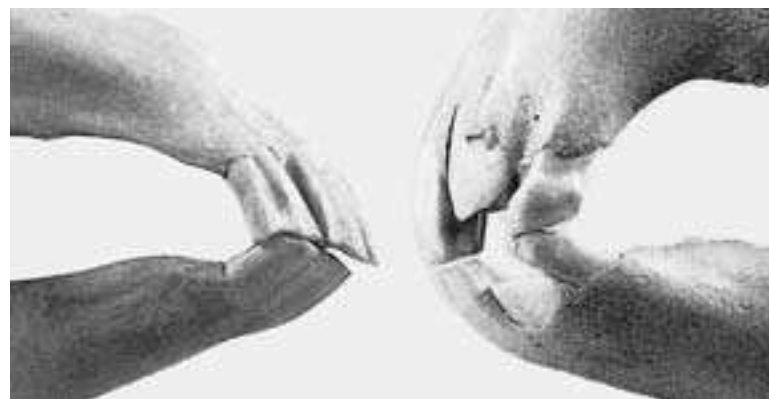

Fig. 32.2.6. Right: Profile of the incisor dentition at 3.5 years. Left: Profile of the incisor dentition at 16 years with Galvayne's groove up to half the length of the crown and caudolingual hook at I3.



greater in the mandible than in the maxilla, and the increase in size of the maxillary sinus with advancing age.

Punching out of maxillary M1: In punching out M1 of the maxilla, attention must be paid to the facial artery and vein.

Shortening of the teeth: A shortening of the teeth is indicated in case of an *exsuperantia dentis* (where one tooth projects farther than the others), shear-mouth, and step-mouth as well as superior and inferior brachygnathia. In this way, the hooks, edges and exsuperantia are smoothed off to the level of the other teeth. Attention has to be paid to the physiological oblique inclination of the occlusal surfaces.

Trephination in case of tooth disease in the maxilla: Diseases of the teeth are found more often in older horses. The trephination sites for the premolars and molars are on a line through the most ventral point of the orbital margin and the ventral border of the infraorbital foramen. For P2 the trephination site is in a transverse plane through the caudal end of the naso-incisive notch; for P3, 2 cm rostral to the infraorbital foramen; for P4, about 2 cm caudal; and for M1, about 4 cm caudal to this foramen; and for M2, about 4 cm rostral to the medial angle of the eye. The root of M3 is reached by a trephination site of the frontal sinus (in the middle between the medial angle of the eye and the median plane). M1 is the most frequently diseased cheek tooth in older horses.

Lateral nasal artery and trephination: In trephination for punching out of P4, the lateral nasal artery may be injured.

Trephination of mandibular cheek teeth: In 5 years old and older horses the apices of the roots of P2 through M1 are located on a line directly above the ventral border of the mandible. The trephination site for P2 is found in a transverse plane through the middle of the clinical crown, that for P3 and P4 in a plane through the caudal border of the clinical crown of the same tooth, that for M1 about 4 cm rostral to the vascular notch of the mandible as also that for M2 about 4 cm above the ventral border of the mandible and 2 cm caudal to the vascular notch.

Masseteric artery and trephination. At trephination of M2 and M3 the masseter muscle must be transected. In this procedure, care must be taken for the masseteric artery.

Cribbing: A vice of the horse, in which the incisor teeth are pressed against the crib and the pharynx widened in order to swallow air (windsucking). The best treatment-results were obtained by a combined resection of the sternothyroid, sternohyoid and omohyoid muscles together with a transection of the ventral branch of the accessory nerve. The latter is easily found, namely there, where it enters the sternocephalic (= sternomandibular) muscle, close to the muscle-tendon connection.

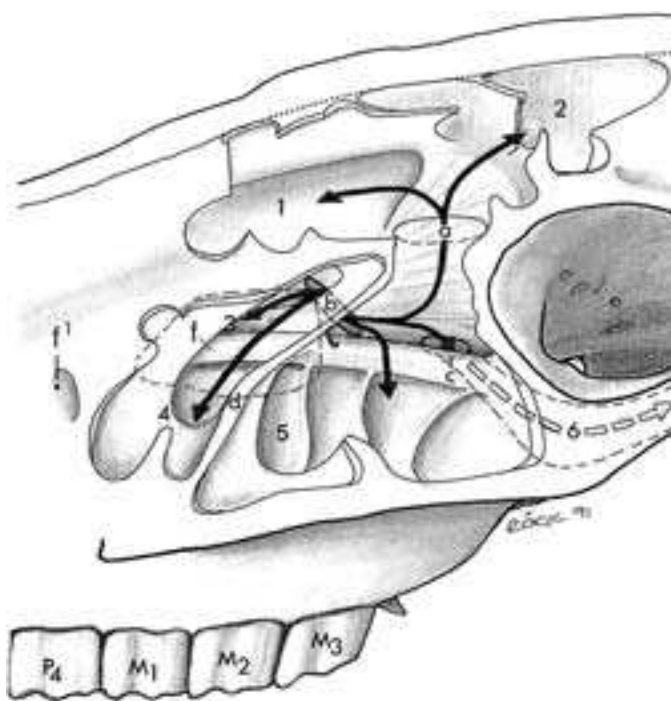


Fig. 34.2. Communication of the paranasal sinuses
Paranasal sinuses in rostralateral view. 1. dorsal conchal sinus, 2. frontal sinus, 3. ventral conchal sinus, 4. rostral maxillary sinus, 5. caudal maxillary sinus, 6. sphenopalatine sinus, a. frontomaxillary aperture, b. nasomaxillary aperture, c. septum of the maxillary sinus, e. orbit, f. infraorbital canal, f', infraorbital foramen.

Major palatine artery and tooth extraction: In case of tooth extractions, the position of the major palatine artery at the hard palate should be taken into account. On the one hand it has a close topical relationship to the maxillary cheek teeth (courses beside the alveolar processes in the palatine sulcus); on the other hand, after having united with the artery of the other side, it passes through the interincisive canal and forms an important anastomosis with the superior labial artery, the palatolabial artery (supplies the upper lip).

Parotid duct: At the punching out of maxillary M1, care should be taken to avoid an injury to the parotid duct.

34.2. Connection of the paranasal sinuses (p. 35, above): In the horse, all paranasal sinuses are connected to the maxillary sinus. Clinically, that means that from here any infection, which is derived from the roots of the last maxillary cheek teeth—the alveoli of which form its floor—may spread to the other paranasal sinuses. Practically, an infection of the frontal sinus may follow an infection of the caudal maxillary sinus, since both are connected by way of the frontomaxillary aperture (located dorsomedial to the medial angle of the eye).

Disease of the paranasal sinuses: “Secretion streets”, which come from the ventral nasal meatus at the level of the 2nd molar tooth out of the middle nasal meatus and run ventrally (rostrally), are an indication of disease of the paranasal sinuses.

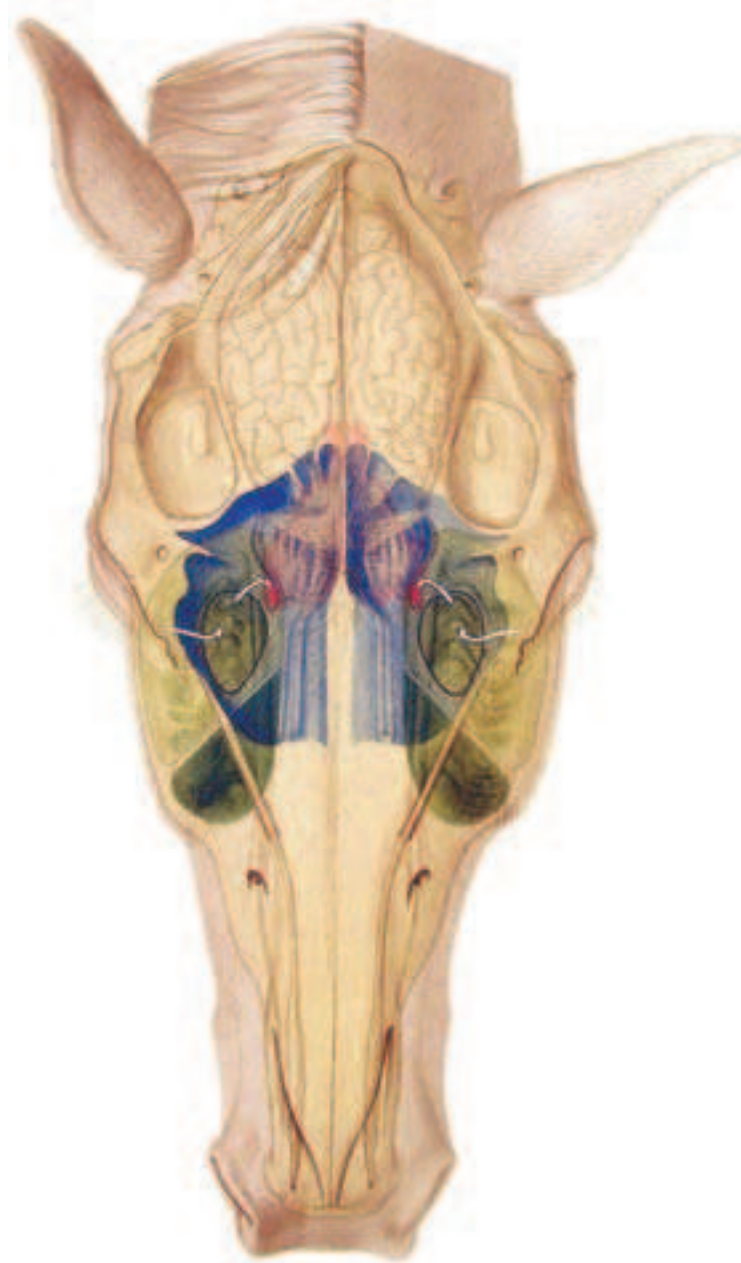


Fig. 34.3. Flushing of the maxillary sinus. Opened paranasal sinuses, dorsal view (see also Fig. 34.1.)

Light blue: Dorsal nasal conchal sinus; dark blue: frontal sinus; red: sphenopalatine sinus; yellow/green: caudal/rostral maxillary sinus with septum separating them. The lower arrow points into the maxillopalatine aperture; the upper, into the sphenopalatine sinus. (Courtesy of Institut f. Veterinär-Anatomie, Berlin)

Empyema of the sinus: Because of the anatomical communication between the maxillary sinus and the ventral nasal concha, an empyema of the sinus in the horse can spread to the nasal concha. Purulent changes of the concha occur also without simultaneous empyema of the sinus, and may result in a necrosis of the affected part of the nasal concha. In the horse, a similar communication exists between the dorsal nasal concha and the frontal sinus (conchofrontal sinus).

34.3. Flushing of the maxillary sinus: Sometimes it is possible to reach the large maxillary sinus from the middle nasal meatus and the nasomaxillary aperture. This yields the possibility of flushing, which is of diagnostic and therapeutic value. Otherwise, the paranasal sinuses are accessible by a small trephination opening and viewed with an endoscope.

Trephination of the maxillary sinus: For trephination of the maxillary sinus, knowledge of its borders as projected onto the surface is of importance. Because the floor of the maxillary sinus is formed by the alveoli of the maxillary cheek teeth, tooth diseases with rupture into the sinus may also provide an occasion for trephination as pathological content fills the maxillary sinus. It is important to know that in the horse all paranasal sinuses, and this includes the maxillary sinus, communicate with the middle nasal meatus (= sinus meatus) of the nasal cavity. There are **two maxillary sinuses**: the large caudal maxillary sinus, and the small rostral maxillary sinus. The trephination site for the first is located at a point, which is reached 5 cm caudal to the rostral end of the facial crest on it and, from here, 2–3 cm dorsal. The trephination site for the rostral maxillary sinus lies at a point, which is 2–3 cm dorsal to the rostral border of the facial crest. In most cases, the two sinuses are separated from one another by a septum (*septum sinuum maxillarium*), which is 4–6 cm caudal to the rostral end of the facial crest. This septum is located about the middle of a line connecting the medial angle of the eye and the rostral end of the facial crest.

Cysts of the paranasal sinus: Although somewhat uncommon in yearling foals, still a cyst appears most frequently at this age—compared with other age-stages. On the affected side of the face, there is commonly demonstrated a swelling somewhat dorsal and rostral to the facial crest.

34.4. Trephination of the frontal sinus and conchofrontal sinus. For trephination a line is drawn from the medial angle of the eye to the median line of the head. The midpoint of this line is the site for entrance with the trephine. The trephination opening is in the area of the rostral conchofrontal sinus.

36.1. Venepuncture of the deep facial vein (p. 36.30): The deep facial vein can be used for venepuncture. The site of venepuncture is at the transition from the rostral to the middle third of the facial crest (see also transverse facial vein).

36.2. Venepuncture of the transverse facial vein (p. 36.19): The transverse facial vein can be used to obtain venous blood or for intravenous injection. It runs directly ventral to the facial crest. The injection site is found directly at the transition from the rostral to the middle third.

36.3. Central paralysis of the facial nerve is a central injury to the facial nerve (cranial nerve VII). The facial nerve can also be injured peripherally. In the case of central paralysis of the facial nerve, the injury can be located on the line between the exit from the stylo-mastoid foramen and the reflection around the caudal border of the mandible or between the origin of the nerve from the medulla oblongata and its exit from the stylomastoid foramen.

Peripheral paralysis of the facial nerve: The facial nerve (cranial nerve VII) is primarily the motor nerve for the superficially located muscles of the head, that is, the muscles of facial expression. Although some of these muscles participate in mastication, they should not be mistaken for the masticatory muscles, which are supplied by the mandibular nerve (= mandibular musculature). Furthermore, it is to be noted that the facial nerve is not the sensory nerve for the skin over these muscles; that is the trigeminal nerve. The extent of the paralysis of the facial nerve is decisive for prognosis. Usually the facial nerve is damaged where it turns around the caudal border of the mandible (= peripheral paralysis of the facial nerve; e.g., after pressure from the halter, being put down under general anesthesia). Here it divides into its dorsal and ventral buc-

cal branches. Both cross the masseter muscle ventral to the temporomandibular joint. Injury to the nerve at this site paralyzes the lip, nostrils, as well as the cheeks of the horse and causes a hyperalgesia of the area of supply of the branches of the auriculotemporal nerve (V3), which run with the transverse facial artery and the buccal branches of the facial nerve. The tonus of the contralateral normal muscles pulls the nose and lips to their side.

36.4. Anesthesia of the auriculopalpebral nerve (p. 37.15): The auriculopalpebral nerve proceeds dorsally from the facial nerve near the caudal border of the mandible and extends, caudal to the superficial temporal artery and vein, in the parotid gland or in relation to the parotid lymph nodes. Here it divides into rostral auricular branches for the rostral ear muscles as well as the zygomatic branch, the nerve destined for the motor supply of the eyelids. The latter extends across the zygomatic arch or, respectively, the temporalis muscle rostradorsal to the lateral angle of the eye, where it ends in a dorsal branch for the dorsal part of the orbicularis oculi muscle and the levator of the medial angle of the eye and a ventral branch for the ventral part of the orbicularis oculi muscle. Anesthesia of the auriculopalpebral nerve (= motor innervation of the orbicularis oculi muscle) does not result in an analgesia, but in a paralysis of the orbicularis oculi muscle, which enables a detailed examination of the eyelids. The site for anesthesia lies just caudal to the caudal border of the mandible at the ventral border of the temporal part of the zygomatic arch. The needle is directed dorsally.

36.5. Paralysis of the buccinator muscle: The consequence of paralysis of the buccinator muscle is the accumulation of food within the oral vestibule. Normally this muscle presses the food between the dental arcades (maxillary and mandibular) back into the oral cavity proper and by this has an action opposite to the tongue during mastication. The accumulation of food in the oral cavity because of damage to the facial nerve should not be confused with an inability to swallow.

38.1. Temporomandibular joint: The temporomandibular joint has clinical importance in cases of partial or total resection of the **articular disc (p. 39.22)**. The latter is about 3–5 mm thick. The joint capsule is short and tight and connected to the articular disc. The transverse facial artery and vein as well as the auriculotemporal nerve run ventral to the temporomandibular joint.

38.2. Anesthesia of the mandibular nerve (p. 39.23): Anesthesia is performed at the oval notch of the foramen lacerum. The injection site is on a line drawn from the lateral angle of the eye to the lower base of the ear. The needle is introduced about 1 cm ventral to the middle of this distance. The direction of the needle is the opposite ear. The needle passes the mandibular notch and penetrates the temporal fossa, where the local anesthesia solution is deposited. The same procedure must be repeated on the other side. With successful anesthesia, the paralyzed lower jaw hangs down. In this way, it is possible to examine manually the oral cavity, the pharynx and the initial part of the esophagus. The **mandibular foramen (p. 35.74)** can be utilized to anesthetize the inferior alveolar nerve for treatment of the teeth of the lower jaw. To find the mandibular foramen, a line is drawn between the condylar process of the mandible, obliquely across the masseter muscle, to the rostral border of the vascular notch of the mandible. The mandibular foramen lies about at the middle of this line.

38.3. The inferior alveolar nerve (Fig. 38.5., 3, p. 150) can be reached for local anesthesia by introducing a needle medial to the mandible from a caudal or ventral direction. The entrance of the nerve into the mandibular foramen and mandibular canal is palpable from the oral cavity. The mandibular foramen can also be located externally. It is located on the medial surface of the mandible, at the cross-point of an extended line of the occlusal surfaces of the molar teeth and a line connecting the condylar process of the mandible and the vascular notch of the mandible. For anesthesia, a needle about 20 cm long is advanced from the vascular notch medial to the mandible in the direction of the temporomandibular joint, until this cross-point is approximately reached. [376]

38.4. Anesthesia of the mental nerve (Fig. 38.5., 4, p. 150) is realized at the mental foramen (p. 35.75), where the site of exit of the mental nerve can be found with the help of the “two finger grip.”

The thumb palpates the rostral end of the intermandibular space; the index finger palpates the mental foramen about 2–3 cm dorsal and perhaps slightly rostral to the thumb,. The tendon of the depressor labii inferioris muscle must be displaced somewhat dorsally.

After piercing the skin, which may cause greater pain, the following will be anesthetized:

1. with the mental nerve the corresponding halves of the lower lip and chin;
2. with the rostral inferior alveolar branch the incisor teeth and the canine tooth of the corresponding side;
3. with the terminal part of the inferior alveolar nerve the area up to the first cheek tooth. [377]

38.5. Anesthesia of the maxillary nerve (Fig. 38.5., 1): A block of the maxillary nerve anesthetizes the maxillary cheek teeth, but it is essential only for the last four. For anesthesia of first two cheek teeth and the incisors the more simple anesthesia of the infraorbital nerve is to be recommended. The maxillary nerve runs through the **pterygoplatine fossa** (p. 33.A) and reaches the **maxillary foramen** (p. 33.58), where it should also be anesthetized. The site for anesthesia of the maxillary nerve is located about 2.5 cm ventral to the lateral angle of the eye and ventral to the zygomatic arch. The needle is directed medially and somewhat rostradorsally and advanced deeply about 6.5–7.5 cm.

38.6. Anesthesia of the infraorbital nerve (Fig. 38.5., 2): The site for blocking the infraorbital nerve is located in the infraorbital region. The **infraorbital foramen** (p. 33.59) is found on a line between the naso-incisive notch and the beginning of the facial crest. The middle of the line is sought and then proceeded a fingerbreadth in direction toward the eye. It is to be noted that the infraorbital foramen is covered by the levator labii superioris muscle and levator

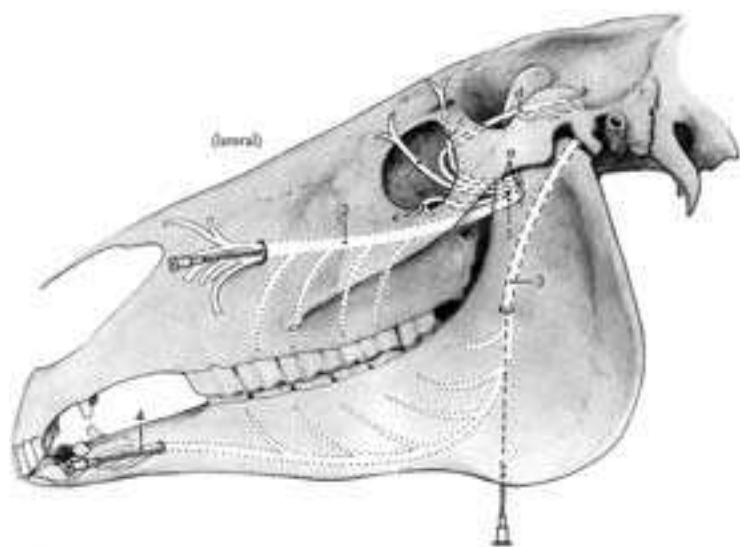


Fig. 38.5. Anesthesia of the maxillary nerve (1) and its infraorbital nerve (2) in the infraorbital canal, of the inferior alveolar nerve (3) at the mandibular foramen and its mental nerve (4) at the mental foramen. Ophthalmic nerve (a) with the infratrochlear nerve (b), frontal nerve (c) and the zygomaticotemporal nerve (d). Zygomaticofacial nerve (e) of the maxillary nerve.

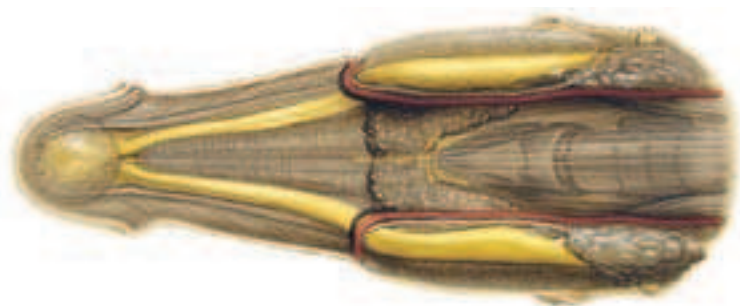


Fig. 38.8. Salivary glands. Ventral view at the throat. The facial a. and v. as well as the parotid duct extend on the inner surface of the mandibular ramus. At the vascular notch they reflect onto the lateral surface of the mandible (*cf.*, p.33). The mandibular lymph nodes and, caudal to them, the larynx lie between the rami of the mandible. The mylohyoid muscle is found ventral to the mentum (chin), between the right and left halves of the body of the mandible.

nasolabialis muscle. By light pressure, these muscles can be displaced dorsally and the infraorbital foramen palpated. The position of the infraorbital foramen can be determined by the “three finger grip” (middle finger lies in the arch of the naso-incisive notch—thumb on the rostral end of the facial crest—index finger is placed on the infraorbital foramen).

For implementation of the anesthesia the infraorbital artery and vein should be kept in mind. Anesthesia of the infraorbital nerve at the infraorbital foramen enables operations on all premolars, on the first molar, on the incisor teeth, on the nasal wall, the hard palate, the gums, the periosteum of this area, the maxilla, the upper lip and on the nasal diverticulum of the corresponding side. During trephination for punching out P4 of the maxilla, the infraorbital nerve can be injured. [377]

38.7. Atrophy of the masticatory muscles can be the result of a paralysis of the mandibular nerve. The **masseter muscle** may also atrophy due to a chronic myositis. [378]

38.8. The salivary glands and their excretory ducts are compromised by injuries, fistulas, dilatations and salivary calculi. Plant constituents (*e.g.*, oats) may penetrate into the salivary papilla and function as a point of crystallization for the development of salivary calculi (sometimes palpable). [379] [380]

38.9. At the vascular notch of the mandible the **facial artery** is used for taking the pulse. The parotid duct also runs here. On its way to the oral vestibule, the duct reflects from medial to ventral to lateral around the bone. Its injury may have severe consequences for the animal. In view of a saliva production of about 15 liters per day by the parotid gland, the loss of fluid due to an external injury of the duct may result in an irreversible exsiccosis (drying out). [381] [382]

38.10. Mandibular lymphcenter (p. 39.16): The mandibular lymphcenter comprises the clinically important mandibular lymph nodes (Fig. 38.8.). These are located at the level of the vascular notch directly beneath the skin of the intermandibular space, have an arrowhead form and are palpable on the patient. Their efferent ducts pass to the retropharyngeal lymphcenter.

Eye

BETTINA WOLLANKE, HARTMUT GERHARDS

40.1. Knowledge of normal anatomy is a basic precondition for examination of the eye and, at the same time, is a great help in localizing and interpreting abnormal findings. The eye examination is accomplished in the first instance visually as well as by simple tests for visibility and light perception. Further possibilities for the examination are the application of imaging procedures. In this regard, the ultrasound examination is of particular importance. An electroretinogram (ERG) can give additional clarification as to functional impairment of the retina (Fig. 40.1.1). Finally, in individual cases, slice-picture procedures like magnetic resonance tomography or computed tomography can also be useful (Fig. 40.1.2).

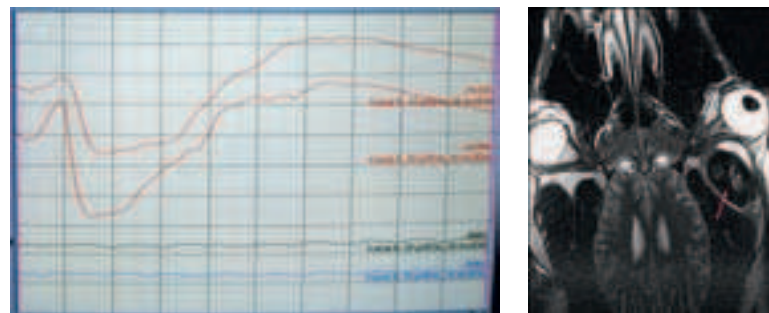


Fig. 40.1.1 (left): Electroretinogram. The upper two curves were obtained from the right, normal eye. There is a normal reaction to flashes of light. The lower two curves were taken from the left eye, which was blinded by retinal detachment. No reaction to the light-signal is observed.

Fig. 40.1.2 (right): Magnetic resonance tomography. So-called coronary (crown-like) section through the head of a horse with a tumor behind the eye (arrow).

In examination of the eye, it is advisable to view and evaluate the anatomical structures of the adnexa of the eye as well as the eyeball itself in a sequence from external to internal. In the following, the eye examination is described with selected clinical cases.

Prerequisites for the Eye Examination. A room which can be darkened is essential for the eye examination. The most important instrument in examination of the equine eye is a direct ophthalmoscope (Fig. 40.1.6). The ophthalmoscope has different possibilities for adjustment. It can be used as a simple, bright-focal, light source, as a magnifying lens, as a slit-lamp, as a Placido's disk (keratoscope) as well as for direct ophthalmoscopy of the interior of the eye. Additional instruments, for example, a head-band magnifying lens or a qualitatively better slit-lamp than the one that is integrated into the ophthalmoscope are good options for persons interested in ophthalmoscopy. Additionally, in rarer cases, instruments can be useful for the opening or ectropionization of the eyelids (Desmarres lid-holder, Fig. 40.1.3a) or even the rostral displacement of the nictitating membrane (for example, Graefe tissue-forceps, Fig. 40.1.3b). Knob-cannulas (Fig. 40.1.3c), teat cannulas (Fig. 40.1.3d) or even simple venous in-dwelling cannulas (Fig. 40.1.3e) may be used for flushing the nasolacrimal duct. Medications used for ocular examinations are mydriatics (substances that dilate the pupil; *i.e.*, the short acting Tropicamid), surface anesthetics and dyes for demonstration of epithelial defects (fluorescein drops, in rare cases also Bengal-pink). Sedation of the horse for examination of the eye is needed only in individual cases. Also, local anesthesia (auriculopalpebral nerve; reduces the movement of the upper eyelid) for the examination of the eye is indicated only in very rare cases.

Conduct of the Examination. One should always conduct the eye examination in a systematic way so as not to overlook pathological changes of the eyeball or its adnexa. In doing this, it is useful at first to watch the horse during movement, most favorably in entering an unknown room. A tilted head or an unsure, staggering gait can indi-

cate a visual disturbance (Fig. 40.1.4). The examination of the eye begins with an inspection of the region around the eye. In doing this, the horse is examined from anteriorly, comparing both sides, and checked for injuries, lacrimal flow, and asymmetries of the area around the eye, the eyeball itself, as well as the eyelids and the position of the cilia (Fig. 40.1.5a–c). In addition simple visual tests should be carried out such as the menace gesture with the hand approaching from different directions. After that, there follows the examination of the eye and adnexa: eyelids, conjunctiva, lacrimal apparatus, the anterior chamber of the eye, iris (including the granula iridica and the pupillary reflex), lens, the vitreous chamber and the ocular fundus with the retina. For the examination up to and including the lens a bright focal light is necessary, a magnifying lens where appropriate and, in individual cases, a slit-lamp. For the examination of the vitreous body and the fundus of the eye, the direct ophthalmoscope is the instrument of choice. Moreover, for the examination of the parts of the eye posterior to the iris, a dilated pupil ("mydriasis") is prerequisite. Mydriasis often arises spontaneously in young and excited horses owing to a sympathetic tonus (activation of the dilatator pupillae muscle). If, however, the pupil is not sufficiently wide to check the lens, vitreous body and retina up to the periphery then a pupil dilated by a mydriatic is essential for a meaningful examination of the eye.

Direct ophthalmoscopy of the back-side of the lens and the vitreous body is best realized at a distance of about 30 cm from the eye of the horse at a dioptric value of +2 to +3. For the fundus of the eye it is recommended to approach the equine eye as near as possible (so long as the cilia are not contacted) in order that the view of the fundus is as large as possible. The adjustment of the diopters here is about -4 to -5. Each investigator must find the dioptric values on the ophthalmoscope that are suitable for that person's use, and there are distinct individual differences. In addition to the adjustment of the dioptric values of the ophthalmoscope, focusing

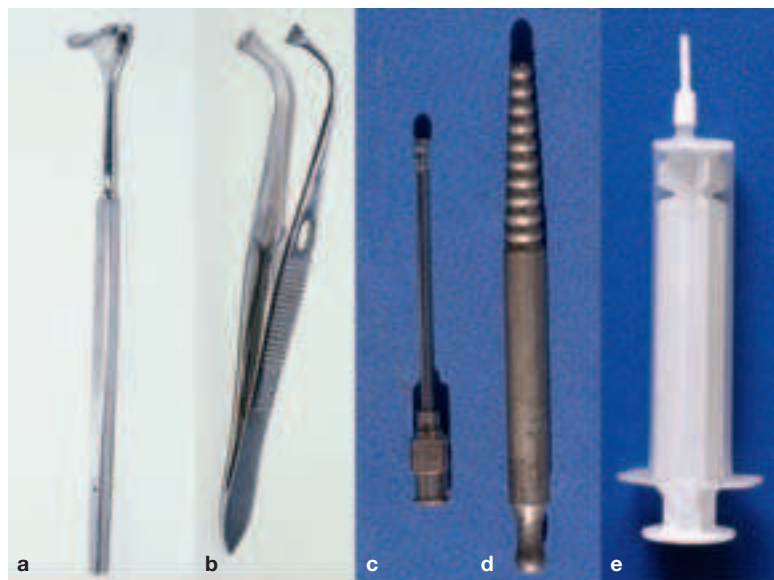


Fig. 40.1.3a–e: Useful instruments for the examination of the eye in the horse.



Fig. 40.1.4: Oblique posture of the head in unilateral blindness.

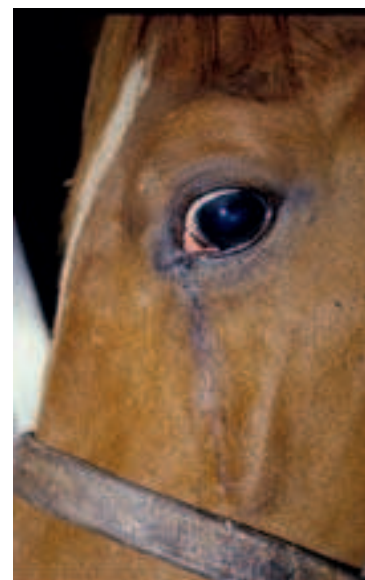


Fig. 40.1.5a: Loss of hairs with chronic lacrimation.




Fig. 40.1.5b: Ocular bulbs of different size.




Fig. 40.1.5c: Orbital fracture of the right eye.

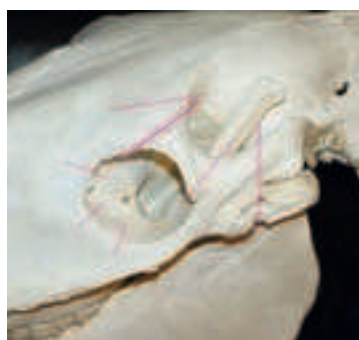

Fig. 40.1.5d: Predilection-places for orbital fractures in the horse. The supraorbital foramen is especially frequently encountered.

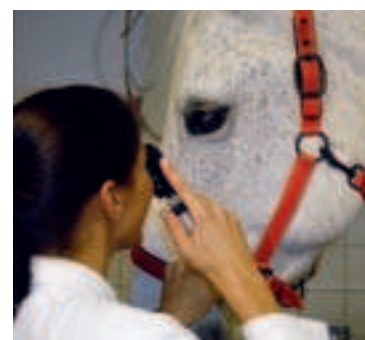


Fig. 40.1.6: Examination of the eye. One hand holds the halter, the other hand holds the ophthalmoscope. An assistant draws the attention of the horse (rustles with paper, if necessary, so the horse will open the palpebral fissure).

can be improved by a slight variation in the distance from the ophthalmoscope to the eye. Persons wearing eyeglasses can leave their glasses off and adjust their vision by an appropriate dioptric choice on the ophthalmoscope. Example: With nearsightedness of -3 diopters means that correspondingly 3 diopters have to be subtracted from the recommended setting.

During the examination of the eye the hand of the investigator should rest on the halter of the horse to sense defensive movements timely. The free hand holds the ophthalmoscope or another lamp for examination of the eye (Fig. 40.1.6). If possible, touching the horse in the neighborhood of the eye or even to spread the lids should always be avoided since otherwise, inevitably, an increased effort to close the lids makes further examination more difficult or thwarted. Should the horse close the lids when light strikes the eye, then it is better to rustle with paper or to attract the attention of the horse by other sounds in order to open the palpebral fissure again.

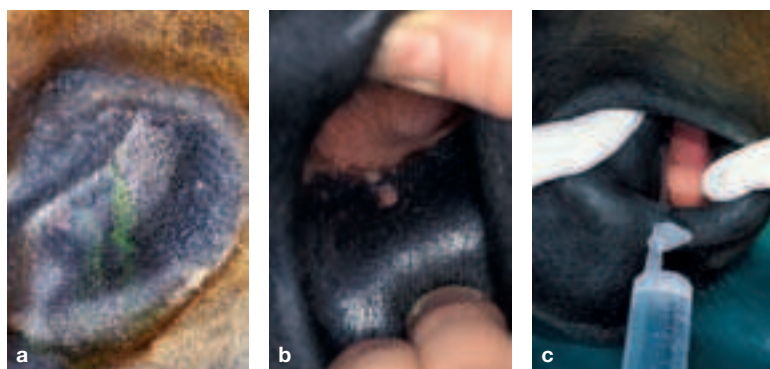


Fig. 40.2.1a: After application of fluorescein drops, if the nasolacrimal duct is patent, the green color can in a short time be seen in the nasal vestibule.

Fig. 40.2.1b: Opening of the nasolacrimal duct (nasolacrimal ostium), near the transition of the pigmented to the nonpigmented skin.

Fig. 40.2.1c: Flushing of the nasolacrimal duct from the nostril. The catheter is introduced into the nasolacrimal ostium.

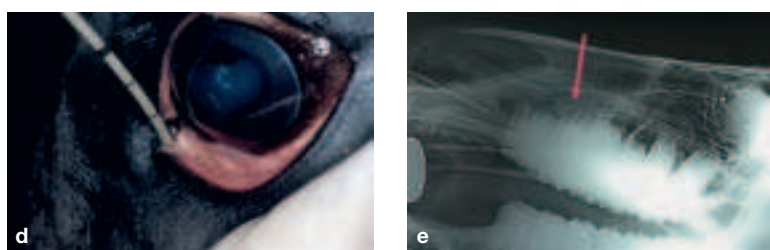


Fig. 40.2.1d: A catheter is introduced from the lacrimal punctum of the lower eyelid into the nasolacrimal duct.

Fig. 40.2.1e: Radiograph of the nasolacrimal duct with introduced catheters (from the nasolacrimal ostium in the nasal vestibule as well as from the lacrimal punctum of the lower eyelid). In the region of the maxillary sinus a shadow presents itself (arrow), which points to a growth in this region and can represent a cause for compression of the nasolacrimal duct. The small round shadows are lead balls for marking of the lacrimal punctum of the lower eyelid as well as the nasolacrimal ostium in the nasal vestibule.




Fig. 40.2.2 (left): Bulbar protrusion and exposure of the cornea in an orbital fracture.

Fig. 40.2.3 (middle): Enophthalmos on the right side in a fracture of the floor of the orbit.

Fig. 40.2.4 (right): Bulbar protrusion on the left side due to retrobulbar tumor growth.

40.2. The Area Around the Eye. If the palpebral fissure is opened normally and no painful eye disease exists, a chronic lacrimal flow (Fig. 40.1.5a) points to a clogging of the lacrimal conduction system (lacrimal puncta of the upper and lower eyelids, lacrimal canaliculi, lacrimal sac, nasolacrimal duct, nasolacrimal ostium; Fig. 40.2.1b). To determine if the lacrimal canal (nasolacrimal duct) is clogged, fluorescein drops may be applied. If the lacrimal canal is patent, the dye should be visible in the nostril after a few minutes (Fig. 40.2.1a).

Causes of obstruction of the lacrimal canal may be inherited (for example, agenesis of the nasolacrimal ostium or, in rarer cases, of other structures of the lacrimal conducting system) or acquired (for example, obstruction of the nasolacrimal duct by inflammatory products, compression of the nasolacrimal duct by inflammatory products, compression of the nasolacrimal duct by space-occupying processes, or eyelid lacerations with involvement of the lacrimal puncta or of the lacrimal canaliculus (Fig. 40.2.1e). In some cases an irrigation or exploration of the lacrimal canal, in individual cases also by surgical intervention, succeeds in restoring the drainage of the lacrimal fluid via the proper channels (Fig. 40.2.1c, d).

Orbital fractures appear frequently in the horse and are the result of being kicked or running against hard objects (Fig. 40.1.5c). In certain cases they may remain unnoticed and heal without clinical intervention. In some cases the eyeball may be dislocated from the orbit by the impressed orbit (notably fractures of the zygomatic process of the frontal bone through the supraorbital foramen as well as the zygomatic process of the temporal bone; see the Figs. 40.1.5d, 40.2.2). In these cases the cornea is no longer sufficiently moistened by the blinking of the lids. An operative reposition of the bone-fragments is needed to avoid a corneal ulcer. More rarely, there arise fractures of the floor of the orbit (sphenoid bone, palatine bone, lacrimal bone), which lead to a sinking of the eyeball into the orbit (Fig. 40.2.3). If at the same time as the periorbital fractures injuries (impressions) have developed in the region of the paranasal sinuses, then a bloody nasal discharge may be observed.

If, in comparing the two sides, the ocular bulbs are of different size, then either one of the two ocular bulbs is diseased or it is not in its physiological position (Figs. 40.2.3 and 40.2.4). Measurement of bulbar diameter by ultrasound is helpful to comparatively determine the size of the bulbs. If the diameter is different, examination of the ocular bulbs must establish whether the larger bulb or the smaller is diseased (for example, after a glaucoma = chronically increased internal pressure). A decreased ocular bulb can be inherited (designated as “microphthalmus” or develop after traumata or as a result of uveitis (inflammation of the uvea = iris + ciliary body

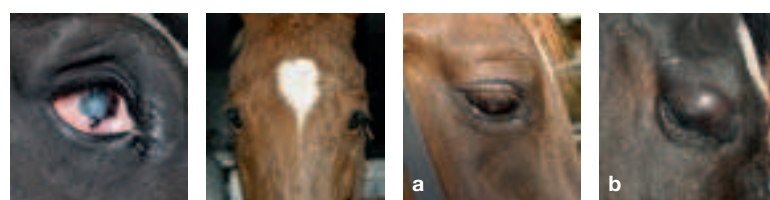


Fig. 40.2.5 (first left): High degree of bulbar atrophy following chronic uveitis.

Fig. 40.2.6 (second left): Different position of eye lashes. The cilia of the left eye stand in a more acute angle to the cornea than those of the normal right eye; that is, the palpebral fissure is increasingly closed (indication of ptosis, bulbar atrophy or blepharospasm; in this case, ptosis with HORNER's syndrome, cf., Fig. 40.3.6).

Fig. 40.3.1a: Physiological fine folds of the lid.

Fig. 40.3.1b: Erased lid folds in palpebral edema.




Fig. 40.3.2 (left): Old, poorly adapted lid injury with exposure of the cornea and resulting corneal inflammation (exposure keratitis).

Fig. 40.3.3 (middle): Anesthesia sites for the (sensory) frontal nerve (2) as well as the (motor) auriculopalpebral nerve (1).

Fig. 40.3.4 (right): Equine sarcoid in the upper lid.

+ choroidea). The terms for that are “*atrophia bulbi*” or “*phthisis bulbi*” (Fig. 40.2.5). A different position of the eyelashes may point to a difference in size or non-physiological position of the eyeball, provided that there is no pain-conditioned closure of the palpebral fissure (Fig. 40.3.6) and no ptosis (Fig. 40.2.6).

40.3. Eyelids. Healthy eyelids have fine folds and the border of the lid lies on the corneal surface (Fig. 40.3.1a). Swellings of the lid lead to a loss of the fine folds and develop very rapidly in the loose connective tissue (Fig. 40.3.1b). They may be produced by edema, phlegmon, hematoma, emphysema or tumor. If there is no tumor, then the lid swellings may be reduced rapidly and effectively by dressings.

Injuries of the lids should be treated as rapidly as possible to prevent exposure of the cornea and the development of corneal defects. The main goal in treatment of an injury to the eyelid is, insofar as it is possible, physiological restoration of the border of the lid (Fig. 40.3.2). As a rule, the conjunctiva need not be sutured. The skin of the lid is sutured by small stitches in which no suture material is to touch the cornea. Uncomplicated lid injuries of cooperative patients can be sutured in the standing position under sedation and local anesthesia (anesthesia of the frontal nerve in the region of the supra-orbital foramen; Fig. 40.3.3). Only very rarely is anesthesia of the motor auriculopalpebral nerve indicated if excessive blepharospasm exists (Fig. 40.3.3). Among the tumors of the lid, equine sarcoids occur most frequently. Since this kind of tumor can assume different forms and can lie under the skin, it is sometimes not identified as a tumor. The earlier this tumor is treated, the more favorable is the prognosis for preservation of the lid without impairment of function (Fig. 40.3.4).

The most frequent defects of the lids are **entropion** (inward turning of the border of the lid) and **ectropion** (outward turning of the border of the lid) (Figs. 40.3.5a and b). Both may be the consequence of lid injuries and can be treated in these cases by different techniques of plastic surgery. Entropion occurs often in neonate foals with hypovolemia and leads to corneal defects. In these cases the position of the lids should not be treated by resection of the skin of the lids, because this may later lead to the development of an ectropion. The entropion of foals is better treated by the injection of well tolerated and slowly resorbed substances into the lower eyelid. The border of the lid is brought into a physiological position by this injection, in which it also remains after reduction of the swelling. In persistent cases a temporary tightening of the lid by skin sutures without resection of lid skin can be performed. A surgical treatment with resection of lid skin is in general not required.

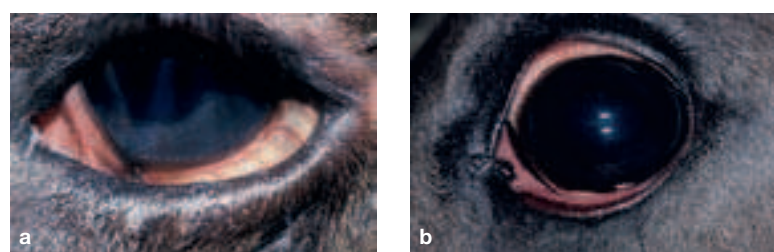

Fig. 40.3.5a: Entropion of the lower lid. Note the corneal defect and corneal inflammation (keratitis, cloudiness of the cornea and corneal vascularization) as a result of hairs rubbing on the cornea.

Fig. 40.3.5b: Ectropion of the lower lid.



Fig. 40.3.6 (left): Blepharospasm in painful eye disease.

Fig. 40.4.1a (right): Protrusion of the nictitating membrane in tetanus.

Fig. 40.4.1b: Protrusion of the nictitating membrane in bulbar atrophy.

An incompletely opened palpebral fissure due to lack of motor innervation is designated ptosis and points to a nerve injury. Unless (for diagnostic or therapeutic reasons) anesthesia of the **auriculopalpebral nerve** had been performed, the cause is often a central facial paralysis or damage to the sympathetic innervation in connection with a Horner's syndrome (for example, mycosis of the guttural pouch with damage to the cranial cervical ganglion of the sympathetic trunk, Fig. 40.2.6). If on the other hand the palpebral fissure is spasmodically closed (blepharospasm), then it is an indication of a painful ocular disease and belongs to the so-called “defense triad” (blepharospasm = spasmodic closure of the palpebral fissure + photophobia = sensitivity to light + epiphora = increased lacrimal flow; Fig. 40.3.6).

40.4. A bilateral protrusion of the **third eyelid** is in most cases an indication of tetanus infection (Fig. 40.4.1a). This is especially the case if this protrusion can be provoked by raising the head of the horse. The cause in this case is the contraction of the retrobulbar muscles, which pull the ocular bulb caudally into the orbit. A protrusion of the third eyelid (usually unilaterally) may also occur in the case of an ocular bulb reduced in size (bulbar atrophy) or a bulb displaced caudally into the orbit for other reasons (for example, fractures of the floor of the orbit, Fig. 40.4.1b, 40.4.2).

40.5. Conjunctiva. The most frequent disease of the conjunctiva is conjunctivitis, which is noticeable by a reddening of the conjunctiva and an increased lacrimal flow. Conjunctivitis usually occurs bilaterally. It may be an independent disease or an accompanying sign of another ocular disease. With every conjunctivitis, and especially with unilateral and recurring conjunctivitis, a detailed eye examination must be performed to recognize more dangerous eye diseases (for example, of the cornea and uvea), which always bring about an accompanying conjunctivitis.

Eosinophilic inflammation is a special form of conjunctivitis that results in deposition of hard, yellowish, crumbly material in the conjunctiva, which can lead to a painful inflammation. In this condition, both the conjunctiva and the cornea are frequently affected (Fig. 40.5.1). More rarely, foreign bodies are found in the conjunctiva, which can lead to an irritation and, depending on the location, to corneal defects. Most frequently, we are dealing with hay or straw, chips, splinters of wood and metal.

Squamous cell carcinoma is the most frequently occurring tumor of the conjunctiva. A predilection site for the growth of this tumor is the unpigmented conjunctiva of the third eyelid (Fig. 40.5.2a) as well as the temporal bulbar conjunctiva of the limbus (“corneo-lim-

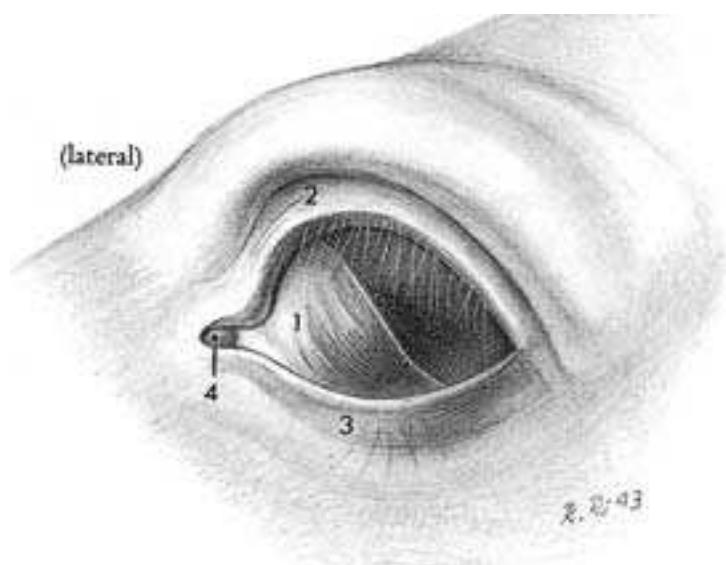


Fig. 40.4.2: Third eyelid covering the medial (nasal) half of the cornea. 1, Third eyelid; 2, 3, upper and lower lids; 4, lacrimal caruncle.

bal squamous cell carcinoma”; Fig. 40.5.2b). The affected eye is usually not painful over a long period, and the tumor growth is to be recognized by a chronic, increased mucopurulent discharge as well as by a conjunctiva-colored and slightly elevated finely tuberculate formation in the conjunctiva. Treatment consists of resection of the tumor as early and as completely as possible (partial resection of the third eyelid, resection of the bulbar conjunctiva and subsequent treatment of the tumor bed by laser). If the tumor growth is already advanced and the cornea is also involved, then the prognosis is more cautious. In very far advanced diseases, metastases may be found in the regional lymph nodes or other organs.

40.6. Lacrimal Apparatus. The clogging of the lacrimal apparatus (page 40), which may lead to a chronic lacrimal flow, was discussed in “Section 1. The structures, which are involved in the production of tears also belong to the lacrimal apparatus. The mucin layer of the lacrimal film is produced by the goblet cells of the conjunctiva and the most external (lipid) layer of the lacrimal film is produced by the Meibomian (tarsal) glands near the border of the lid. Diseases are known only of the Meibomian glands. These may lead to inflammation and the formation of small abscesses. The serous layer in the middle of the lacrimal film is produced by the lacrimal gland. The dorsotemporal, flat lacrimal gland is located between the ocular bulb and orbit and releases its secretion via several openings of pinhead caliber into the dorsotemporal fornix (Fig. 40.5.3). The smaller accessory lacrimal gland (gland of the nictitating membrane, superficial gland of the third eyelid) is located under the third eyelid, at its base. This releases its secretion by way of several small openings, which open in a mucosal fold on the corneal (bulbar) surface of the third eyelid. With ectropionization (outward rotation) of the third eyelid, this fold becomes visible in the middle of the bul-

bar surface (Fig. 40.5.4). In the horse, contrary to other species, a tear production that is too slight is a cause for disease only in very rare cases. However in both lacrimal glands often an infection with *Thelazia lacrimalis* is present, which usually takes its course without symptoms. Adult worms can be grossly diagnosed with a more precise inspection of the conjunctiva and the mouths of the lacrimal glands. The parasites are often found within the excretory ducts of the lacrimal gland and their surroundings. In rare cases they can also be detected on the cornea. In individual cases, infection with *Thelazia lacrimalis* may lead to a chronic inflammation of the lacrimal gland (adenitis) and of the conjunctiva. It may even lead to a purulent abscessing adenitis, which requires the surgical removal of the lacrimal gland. Inflammation of the lacrimal gland can be diagnosed by palpation after surface anesthesia of the conjunctiva.

42.1. Cornea. Keratitis (inflammation of the cornea) is a very frequent disease of the cornea, which is characterized by opacities of the cornea and the invasion of blood vessels into the cornea, which is normally not vascularized (Fig. 42.1.1). There are forms of keratitis, which are scarcely or not at all painful and identify themselves more by opacities than by pain. Other keratitides, however, are extremely painful, even when the corneal alterations are very unobtrusive and can be recognized only by detailed observation under magnification. Although the cornea is physiologically entirely transparent and non-vascularized, it is very well supplied with nerves (unmyelinated nerve fibers) and sensitive to pain. Corneal inflammation may incline to recidivism (repeated occurrence). If the corneal epithelium is intact and no infection exists, then most corneal inflammations respond well to an anti-inflammatory treatment. If injuries result in tears of the corneal epithelium or if there is an increased internal ocular pressure, corneal edema can develop due to penetration of aqueous

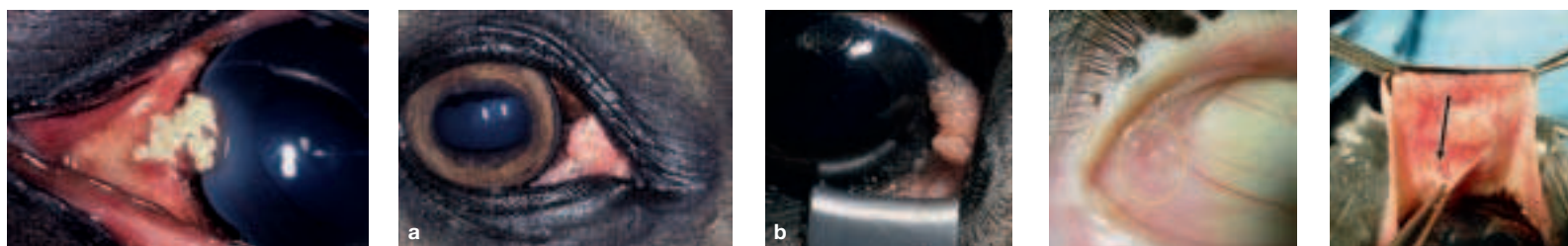


Fig 40.5.1 (left): Eosinophilic keratoconjunctivitis with hard, crumbly inclusions and coating under the third eyelid.

Fig. 40.5.2 (middle): Squamous cell carcinoma of the conjunctiva a) on the nictitating membrane; b) temporal in the region of the limbus.

Fig. 40.5.3 (second right): Excretory ducts of the lacrimal gland in the temporal angle of the eye with a rostrally rotated ocular bulb, usually only visible as an indication.

Fig. 40.5.4 (right): Excretory duct in a mucosal fold under the third eyelid (see arrow).



Fig. 42.1.1 (first left): Keratitis: Cloudy cornea and vascularization of the cornea.

Fig. 42.1.2 (second left): Elevated intraocular pressure (glaucoma): a) corneal edema; b) ribboned (banded) opacities (= tears of the corneal endothelium and DESCEMET's membrane) a consequence of increased intraocular pressure.

Fig. 42.1.3 (second right): Corneal defect stained with fluorescein.

Fig. 42.1.4 (right): Infected ulcer of the nasovenal cornea. Blood vessels grow from ventral into the cornea in the direction of the defect.



Fig. 42.1.5 (left): Corneal ulcer from Fig. 42.1.4 after debridement (removal of infected corneal tissue).

Fig. 42.1.6 (2nd to 4th left): Placement of a subpalpebral catheter: (a) the spike of the catheter is pushed out from the dorsal fornix through the palpebral skin; (b) the T-shaped end of the catheter is drawn into the dorsal fornix and in that way does not irritate the cornea; (c) placement of the catheter dorsally on the neck, attached to the mane. The catheter facilitates the administration of medication also in the case of a temporary ankyloblepharon (lid closure).

Fig. 42.1.7 (second right): Perforating injury of the cornea: Brown iridic tissue protrudes from the corneal wound, seals the injury with fibrin and prevents continuous loss of aqueous humor.

Fig. 42.1.8 (right): Endophthalmitis: Very painful infection of the bulb, which leads to a disturbance of the general condition and which is frequently caused by streptococci or staphylococci.

humor into the cornea (Fig. 42.1.2a). Even if the fluid would be absorbed again from the cornea and it was possible to successfully lower the elevated internal ocular pressure, so-called “band-like opacities” may persist (Fig. 42.1.2b).

After injuries, superficial and medicamentally well treatable defects within the cornea may develop. Some of these defects are visible with the naked eye, others can be easily identified only after staining with fluorescein. With any injury to the corneal epithelium (positive fluorescein test; that is, the primary stain remains adherent to the cornea), it is important to abstain from the use of cortisone containing ointments (Fig. 42.1.3). If an initially harmless defect is treated with cortisone, then the painfulness of the eye subsides rapidly; however, the danger of an infection of the injury is increased considerably. If an infection of the cornea develops, which leads to lysis of corneal tissue, one speaks of a corneal ulcer (Fig. 42.1.4). Certain, very aggressive microorganisms (collagenase producing *Pseudomonadae*) can breakdown the corneal parenchyma within a short time and lead to a rupture of the cornea. Some ulcers for that reason must be cleaned up surgically (Fig. 42.1.5) and stabilized by a sutured “conjunctival flap.” In these cases it is advisable to bring in a subpalpebral catheter into the dorsal fornix in order to prevent the loss of the flap by the blinking of the eye and by rubbing of the eye (to be able to apply medicaments from the neck via a catheter) and to install a temporary ankyloblepharon (temporary artificial closure of the palpebral fissure), until the cornea is stabilized (about 12 days duration) (Fig. 42.1.6a, b, and c).

Perforating corneal injuries are recognizable with the bulging of iris tissue within the corneal lesion (Fig. 42.1.7). In uncomplicated cases the cornea can be stabilized by suture, installation of a subpalpebral catheter and a temporary ankyloblepharon (see corneal ulcer), and often even visibility can be retained. If there is considerable intraocular hemorrhage, the lens dislocated and the retina detached (if necessary, ultrasound examination), it is sometimes advisable to remove the eyeball. If there is a bacterial or mycotic infection of the interior of the eye (septic endophthalmitis) after corneal injuries (ulcer or perforation), the danger exists that it may lead to an ascending infection by way of the optic nerve and finally to an encephalitis. The distance to the brain via the optic nerve is only a few centimeters. For this reason, often eyes that are involved in a severe ophthalmitis have to be removed (Fig. 42.1.8).

42.2. Anterior Eye Chamber and Iridocorneal Angle. The anterior chamber of the eye is the space between the cornea and the iris. In adult warmblood horses it contains about 2.4 ml aqueous humor and, in the center of the anterior chamber of the eye, the distance from the corneal endothelium to the iris is about 5 mm. The posterior chamber of the eye is located between iris and lens. It is distinctly smaller than the anterior chamber and not completely observable (see the upper figure on page 43). With different diseases deposits can be found in the anterior chamber. The most frequent finding is fibrin in the anterior eye chamber, which develops after traumata or inflammation of the iris (“iritis”). It may be in the form of very fine and tiny coagula, which are only visible with a very precise inspection of the anterior chamber (Fig. 42.2.1a). But there may also be a great deal of fibrin in the anterior chamber (Fig. 42.2.1b) and sometimes the entire anterior eye chamber is filled by fibrin. More rarely blood is found in the anterior chamber (“hyphema”, Fig. 42.2.1c). Blood may reach the anterior chamber following traumata or severe inflammation of the iris. Leukocytes may reach the anterior chamber as a result of severe corneal inflammation, infectious processes of the cornea or in the interior of the eye, as well as in rare cases in the course of uveitis (hypopyon). Very rarely, foreign bodies (for example, glass, metal, or wood splinters) can also be found in the anterior chamber. Fibrin coagula in the anterior chamber usually dissolve by themselves, larger amounts of blood must be dissolved with the use of medication or be surgically removed, and foreign bodies are removed surgically.

The ligamentum pectinatum is located circularly in the periphery and meets the sclera at a right-angle. The ligamentum pectinatum in the horse is directly observable and gonioscopy of the iridocorneal angle applied in other species is unnecessary in the horse (Fig. 42.2.2). The iridocorneal angle of the horse is wide open and a “narrow-angle glaucoma” (clogging of the iridocorneal angle by iris-tissue, especially with a dilated pupil) does not exist. The predominant drainage of the aqueous humor in horses is realized via the suprachoroidal space, which exhibits a low resistance to drainage (“uveoscleral drainage of aqueous humor”). Glaucoma of the horse is almost always an “open-angle glaucoma.” This is associated with a diminished drainage of the aqueous humor owing to a clogging of the trabecular meshwork at the chamber angle by products of inflammation and with that an increase in intraocular pres-

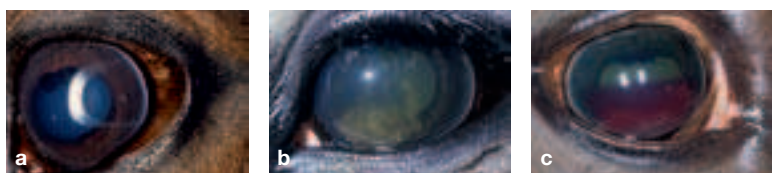

Fig. 42.2.1: Nonphysiological content within the anterior eye chamber: (a) very small and scarcely perceptible coagulum of fibrin; (b) large and easily recognizable coagulum of fibrin; (c) hyphema (blood within the anterior eye chamber).



Fig. 42.2.2 (left): Open and visible iridocorneal angle of the horse. The grey strip at the temporal corneal border is the pectinate ligament, which meets the cornea at a right angle. Nasally and temporally it is normally easily seen, dorsally and ventrally it can be hidden by the eyelids or by pigmentation of the cornea near the limbus.

Fig. 42.2.3 (2nd left): Endoscopic view of the lens (L), zonule fibers (Zo), ciliary body (Zi) and ora serrata (OS) (beginning of the retina) from the vitreous body out. Above-left, the pupil is visible though the lens.

Fig. 42.3.1 (3rd left): Remnant of the pupillary membrane circularly on the anterior surface of the iris.

Fig. 42.3.2 (4th left): Iris coloboma: Nasal and temporal of the pupil. Temporally, the border of the lens and the folded part (*pars plicata*) of the ciliary body are visible.

Fig. 42.3.3 (2nd right): Iris hypoplasia and “stromal cyst” ventral (cyst-like projection of the thin iris tissue owing to the flow of aqueous humor). Additionally, the consequences of posterior synechiae and a cloudy lenticular nucleus are present (the lens has a normal size, the cortex is however normally transparent and therefore not visible).

Fig. 42.3.4 (right): Iridic granular cysts on the ventral border of the pupil.

sure (“secondary glaucoma”). In individual cases the iridocorneal angle may be clogged even by blood or connective tissue (after hyphema), iris melanomas, iris cysts or a lens loosened by a partial rupture of zonular fibers, which may also be a reason for increase in the intraocular pressure (Fig. 42.2.3).

Because narrow-angle glaucoma does not play a role in horses and uveoscleral drainage of aqueous humor is fostered by atropine, the administration of atropine is indicated in horses with increased intraocular pressure (in contrast to other species in which glaucoma must be regarded as a contraindication for the dispensing of atropine). In addition, elevated intraocular pressure is treated with anti-inflammatory drugs as also with medications, which lower the production of aqueous humor.

42.3. Iris, Granula iridica and Pupil. The stroma of the iris is normally brownish pigmented and well vascularized. Frequently, in the middle of the iris, there can be recognized a somewhat irregular prominent ring of dark iris tissue, which represents a remnant of the embryonal pupillary membrane (Fig. 42.3.1). Congenital malformations are rare such as a persisting pupillary membrane or iris coloboma (Fig. 42.3.2). More often there appears a deficiency of pigment of the iris tissue, which may involve one or both eyes, partially (heterochromia) or completely (“wall-eye”; *albinismus iridis externum*). Often these color variants go along with a broad white blaze or another white marking extended onto the orbital region. Depending on the degree of pigment deficiency, the iris tissue appears then blue, white—very seldom—reddish (albinism). In connection with a deficiency of pigment the iris stroma can be very thin to transparent (iris hypoplasia). The concerned tissue will then be pushed anteriorly by the aqueous humor formed behind the iris, and looks similar to a cyst (stromal cyst; Fig. 42.3.3). Within the iris is located, the sphincter pupillae muscle which is innervated by parasympathetic fibers, as well as the dilatator pupillae muscle, which is innervated by sympathetic fibers. In very excited horses the pupil is then sometimes very wide. A wide pupil can be obtained by medication, either by sympathomimetics (less effective) or by parasympatholytics (for example, atropine, very effective).

In any case, the reaction of the pupil to the incident light (pupillary constriction, pupillary reflex) should be checked, before the pupil is enlarged by medication. In the case of nervous horses the constriction of the pupil may be somewhat delayed and incomplete. Movement should, however, always be observed. Also, in the presence of cataract, the reaction of the pupil is maintained, provided there is no retinal damage. If the eye has been treated with a mydriatic prior to the examination and, for this reason, the pupil is unre-

sponsive to the incident light, in a doubtful case (if, for example, no response or only a weak response to a menace gesture results) the “consensual pupillary reflex” can also be checked. The consensual pupillary reflex arises by the fact that in the optic chiasm a partial decussation of nerve fibers of the left and right eyes takes place and the sphincter pupillae muscle of the second eye is activated via the reflex arc. This means that in the case of light directed into the eye with the pupil widened by medication, the pupil of the partner eye, which must not be brightly illuminated, must constrict. The movement of the pupil of the partner eye should be observed with minimal tangential lighting of the anterior eye chamber from temporal. If the consensual pupillary reflex does not appear, then there is retinal damage of the brightly illuminated eye or a pathological process in the area of the visual pathways. If a pupillary reaction to light results, then as a rule vision is present.

Iridic granules (*granula iridica*) are found at the dorsal margin of the pupil. These have in each horse a variable size and shape and should not be confused with a tumor. Relatively often iridic granular cysts (fluid-filled, vesicularly enlarged iridic granules) are found, which as a rule are an incidental finding and have no pathological importance (Fig. 42.3.4). Only rarely a problem may appear, if the pupil is altered by large cysts and vision is correspondingly limited by this or if the iridic granular cysts reach the corneal endothelium, where they irritate. In an individual case therefore it may be necessary to remove the iridic granules surgically. Adhesions between the iris and the lens (posterior synechiae) are a frequent result of painful inflammations of the iris, accompanied by miosis (constriction of the pupil) and fibrin accumulation in the anterior eye chamber. Sometimes these synechiae can be recognized only if the pupil is dilated. The synechiae may concern small portions of the iris tissue. In some eyes, however, a larger area of adhesion occurs between iris and lens (Fig. 42.3.5a and b). With posterior synechiae there often arises a deformation of the normally transverse-oval pupil (dyscoria; Fig. 42.3.5b). Sometimes, with enlargement of the pupil, some iris tissue rips off, remains sticking on the anterior surface of the lens (iris residuum), and is the only indication of a former iritis (Fig. 42.3.6). If the border of the pupil is circularly connected to the lens, then one speaks of a *secclusio pupillae*. If then the pupil is still covered by fibrin, we are dealing with an *occlusio pupillae* (Fig. 42.3.7). In both cases, flow of aqueous humor from the posterior chamber through the pupil into the anterior chamber is impaired, in which case the iris tissue that is not adherent to the lens may bulge anteriorly (“Bundt-cake iris”). In white horses, rarely also in differently pigmented horses, intraocular melanomas (darkly pigmented tumors), which originate from iris tissue, can arise (Fig. 42.3.8). In



Fig. 42.3.5: (a) Small posterior synechiae (adhesions between iris and lens) at “10 o’clock”; (b) areolar posterior synechiae and dyscoria. Additionally a cataract is present.

Fig. 42.3.6 (3rd left): Iris residuum in the center of the anterior surface of the lens.

Fig. 42.3.7 (2nd right): Pupillary occlusion (pupil closed by fibrin) and “Bundt-cake iris” (Bundt-cake-like projection of the iris, the border of the pupil is adherent to the lens).

Fig. 42.3.8 (right): Melanoma of the iris (pigmented tumor, which starts from the iris). Dorsonasally a brown pigment can be seen in the cornea. Additionally there is a smoky-milky cloudiness of the cornea and individual delicate ribbon-like opacities. In the left half of the pupil there is irregular brown tumor tissue.

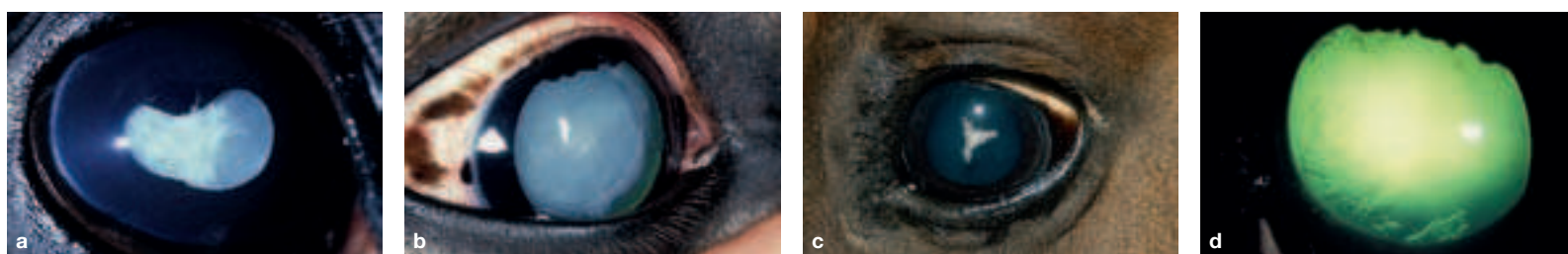


Fig. 42.4.1: (a) Mature cataract (complete milky cloudiness of the lens); (b) Nuclear cataract (cloudiness of the nucleus of the lens); (c) “Suture-star cataract” (cataract in the area of the lenticular sutures); (d) Vacuolar cataract in the region of the posterior surface of the lens.

contrast to the iridic granular cysts, the melanomas have an irregular structure and prefer to grow at the iridocorneal angle. With these, corneal opacities often develop. With continuing growth a brown pigment can be observed within the cloudy cornea. If, with expanding cloudiness, sight in the eye is no longer possible, ultrasound examination can be helpful to assess the extent of the tumor in the eye.

42.4. Lens. The most frequent alteration of the lens is a cloudiness (cataract; Fig. 42.4.1a–d). The cataract may be congenital, in young horses genetically conditioned in the first months or years of life (juvenile) or as a consequence of inflammation, posterior synechiae or traumata (*cataracta complicata*). In old horses a senile cataract can develop. The cataract may involve the entire lens or only parts of it. According to the location of the cataract, one speaks of a “suture star” (turbidity or cloudiness in the region of the former lens sutures), a nuclear cataract (concerning the lens nucleus), a cortical cataract (concerning the cortex of the lens), subcapsular cataract (lying beneath the capsule of the lens) or capsular cataract (concerning the lens capsule) cataract (Fig. 42.4.1a–c). In a normally transparent cortex, the cloudiness of the nucleus of the lens may simulate a microphakia. In these cases an examination by slit-lamp is helpful, because the slit-lamp makes the normally invisible cortex visible. Often, as a consequence of an uveitis, a vacuolar cataract is present in the region of the posterior surface of the lens (Fig. 42.4.1d). Lens operations by phacoemulsification are now technically possible (Fig. 42.4.2). (Phacoemulsification is a minimally invasive operative technique by which the lens material is shattered by ultrasound and aspirated by way of a small incision in the cornea. Simultaneously, the internal pressure of the eye is maintained by infusion.)

Subluxations (partial tearing out of the zonule fibers) of the lens may be inherited, a consequence of traumata, a chronic uveitis or a chronic glaucoma with gradual enlargement of the ocular bulb. With a widely dilated pupil, they can be recognized because the border of the lens and possibly torn out zonular fibers become visible in the periphery of the lens (Fig. 42.2.3). Complete **luxations** of the lens can take place into the anterior eye chamber or into the vitreous chamber. The lens, which is usually cataractous, is then often well visible (Fig. 42.4.3a) or, in case of considerable cloudiness of the cornea, may be easily localized by ultrasound (Fig. 42.4.3b).

Concentric rings within the lens (Berlin rings), striking in appearance, are to be regarded as normal variants. Refraction anomalies of the lens appear in connection with its deformation (for example, lenticonus, bulging of the posterior surface of the lens into the

vitreous chamber), but may show up first in the examination of the fundus of the eye, in that uncommon dioptric values are needed for focusing. Rarely, also colobomas of the lens can be observed with a more dilated pupil (indentation of the lens border in the periphery) (Fig. 42.4.4).

42.5. Vitreous Body. Direct ophthalmoscopy is imperative for examination of the vitreous body. A frequent finding, which becomes visible in the course of time in every horse older than perhaps 8 years, is liquefaction of the vitreous body. This liquefaction presents itself ophthalmoscopically as two mixed clear phases of fluids (for example, egg-white in water). Sometimes also filamentous structures of the framework of the vitreous body can be recognized. A diffuse turbidity of the vitreous body as well as cloudy inclusions, which present themselves as dark inclusions in direct ophthalmoscopy, are as a rule the result of an uveitis (Fig. 42.5.1). Since these inclusions are not resorbed as fibrin is from the anterior eye chamber, in the inflammation-free interval that follows the abatement of an acute ocular inflammation they are also of importance as an indication of the existence of a recidivistic equine uveitis (formerly “periodic ophthalmia”). The first changes are always observable entirely in the periphery of the vitreous body, near the ciliary body. In the further course of the disease, the cloudinesses may be present in the entire vitreous chamber. A diffuse yellowish cloudiness of the vitreous body, a result of inflammation in the posterior portion of the eye, is best seen by shining a light into each pupil in a bilateral comparison (Fig. 42.4.2a–c). By superimposition of the yellowish color in the vitreous chamber with the blue to greenish color of the fundus of the eye, the color that is observed in the pupil with lateral lighting appears strikingly green. Rarely the diffuse cloudinesses of the vitreous body or inclusions in the vitreous body are the result of hemorrhage and then, with illumination, reddish in color (Fig. 42.5.3).

42.6. Fundus of the Eye and Retina. The fundus of the eye bears the tapetum lucidum in its upper 2/3. The tapetum lucidum has a greenish to bluish color and is set through with small brown dots (WINSLOW’s stars = transverse sections of small vessels running from the choroidea to supply the retina). The ventral part of the ocular fundus is brown in color. The optic disc (papilla of the optic nerve) is found just ventral to the transition from the tapetum lucidum (Fig. 42.6.1a–d). Only a few short blood vessels extend from the entrance of the optic nerve into the periphery.

For ophthalmoscopic examination of the fundus, it is advisable to focus first on the WINSLOW’s stars to find the proper ophthal-

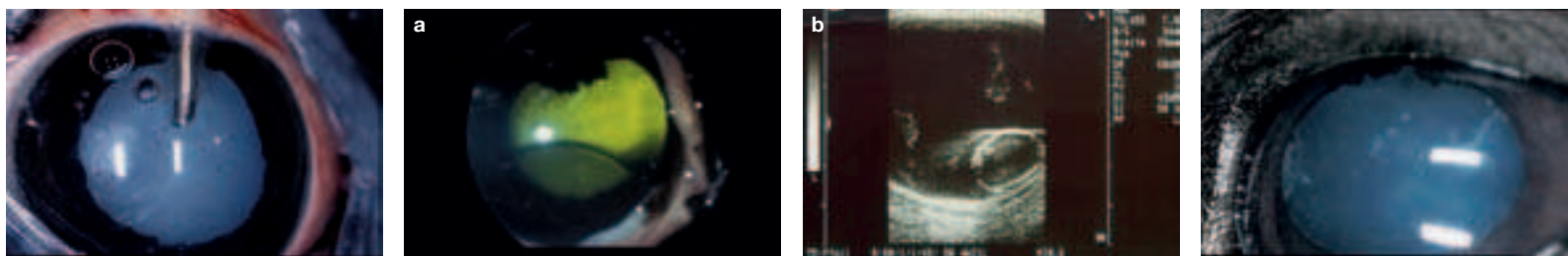


Fig. 42.4.2 (left): Phacoemulsification: Using a metal cannula the lens material is shattered by ultrasound and aspirated. At the same time, fluid is injected by means of the surrounding plastic cannula and the metal cannula is cooled.

Fig. 42.4.3 (middle): Luxation of the lens: (a) into the vitreous chamber (*luxatio lentis posterior*); (b) ultrasound image of posterior luxation of the lens.

Fig. 42.4.4 (right): Coloboma of the lens.

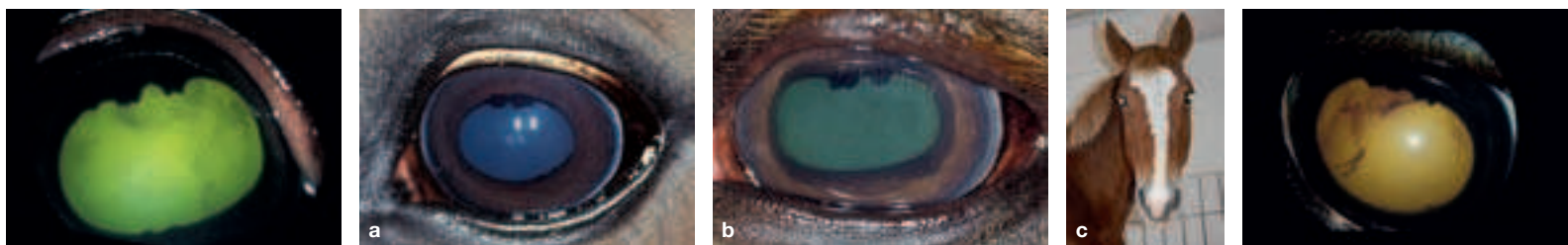


Fig. 42.5.1 (left): Cloudy, dark grey-brown inflammatory inclusions in the vitreous chamber as viewed by direct ophthalmoscopy.

Fig. 42.5.2 (middle): Color of the pupil: (a) normal eye; (b) diffuse cloudiness of the vitreous body in uveitis; (c) color of the pupil in a comparison of both sides: the right (normal) eye glimmers bluish, the left eye yellowish-green owing to cloudiness of the vitreous body in uveitis.

Fig. 42.5.3 (right): Hemorrhage of the vitreous body after trauma.

moscopic setting. After that, the fundus is examined in a meandering manner and checked for alterations. The clinically important changes are normally found in the region of the optic disc. Early stages of retinal detachment (Fig. 42.6.2a) as well as signs of chorioiditis (Fig. 42.6.2b–d) and formations (structural changes) as a rule are revealed first in this region. Atrophy of the optic nerve is recognizable as a strikingly pale color of the optic disc as well as an absence of the few blood vessels that are normally present.

The retina consists of the layers of the neurosensory retina and the pigment layer (*stratum pigmentosum*). In retinal detachment (*amotio* or *ablatio retinae*), the neurosensory retina separates from the pigment layer of the retina, so that there is only a light, curtain-like structure in folds, vesicles or in extended areas loosened from the ocular fundus (Fig. 42.6.3); however, the pigmentation of the fundus is entirely maintained (Fig. 42.6.2d).

After detachment of the retina, the pigment of the fundus appears still lighter and more iridescent, since the otherwise anteriorly located retinal layers are lacking (hyperreflection). A red color of the fundus (*fundus albinismus*) has no pathological significance and is a normal finding in human beings and swine. The red background does not represent a hyperemia in connection with an inflammation, but shows only the absence of pigment, so that the view of the choroidal blood vessels becomes possible (Fig. 42.6.1b). If the pigment is absent, then in horses an impairment of vision in dim light

and darkness can be assumed, since the tapetum lucidum otherwise reflects the light and enables a weaker intensity of light to be utilized.

Application of Ophthalmic Ointments and Ophthalmic Drops
For the application of ophthalmic ointments, the upper eyelid is pushed dorsally with the index finger in the palpebral sulcus and the lower eyelid somewhat lifted off the eyeball with the thumb. The application of medication is preferably realized from temporal into the space between the lower eyelid and the ocular bulb (Fig. 42.7). By blinking, ointments and drops are distributed over the entire cornea.

Subconjunctival injection. For subconjunctival injection, surface anesthesia of the conjunctiva should be done initially. After the action of the anesthetic has begun, a twitch is applied and a DES-MARRES lid retractor fixed under the margin of the upper eyelid. By raising the upper lid with the lid retractor the bulbar conjunctiva can be exposed dorsally (Fig. 42.8). The injection is done with a thin needle and the volume amounts to about 1–1.5 ml. This technique can be applied for the administration of mydriatics or cortisone, insofar as the administration of ophthalmic ointments is not possible or has shown no effect. The injection of crystalloid solutions should however be abandoned.

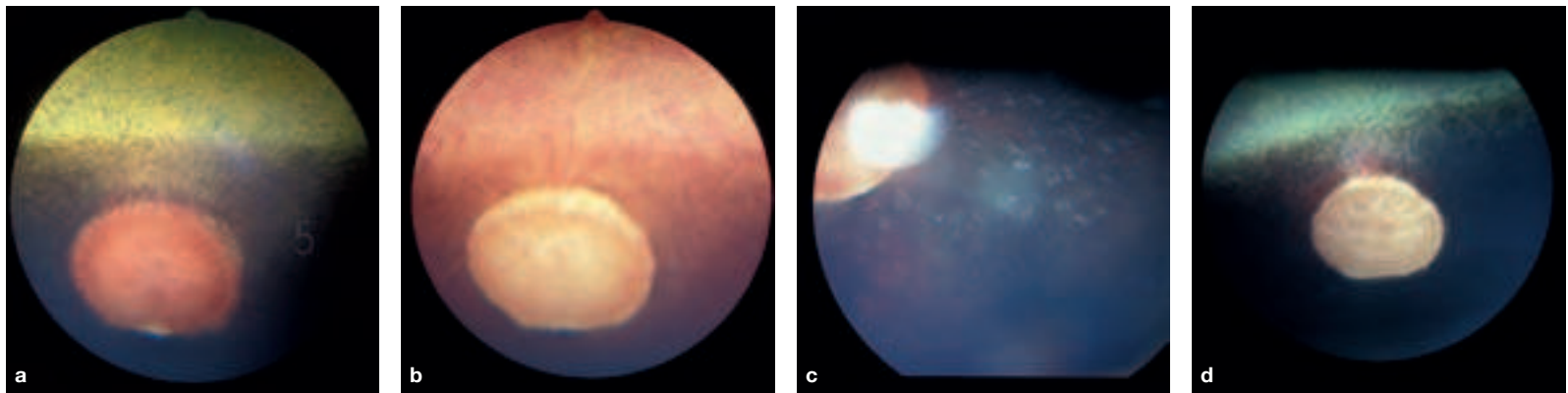


Fig. 42.6.1: (a) View of the physiological (normal) fundus of the horse: tapetum lucidum with WINSLOW's stars dorsal, tapetum nigrum ventral, optic disc and individual, centrifugally running short blood vessels. (b) Albinism of the fundus (deficiency of pigment). Especially frequent if there are broad white markings on the head. (c) Choroiditis (inflammation of the choroidea) with pigment changes following vasculitis; may also develop independently from uveitis. (d) Atrophy of the optic nerve (regression of blood vessels and pale color of the optic disc).

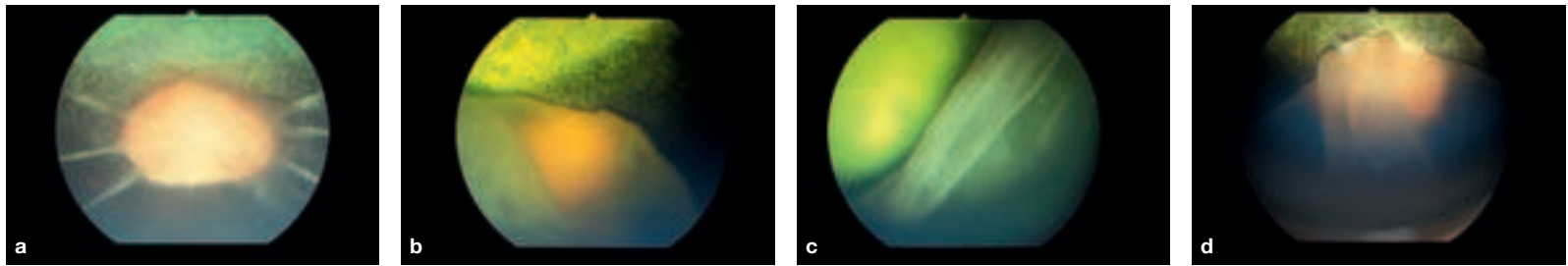


Fig. 42.6.2: (a) Beginning "star-shaped" detachment of the retina (*ablatio retinae*, *amotio retinae*); (b–d) Extended retinal detachment. The pigment is retained in the fundus of the eye.



Fig. 42.6.3 (left): Retinal detachment, ultrasound image: At the optic disc as well as at the ora serrata, it remains attached a longer time; in between it is completely detached ("gullwing shaped"). [R = retina; G = vitreous chamber; L = lens; NO = optic nerve]

Fig. 42.7 (middle): Application of ophthalmic ointments. The index finger is in the palpebral sulcus of the upper eyelid (the first distinct fold above the border of the lid; see Fig. 40.3.1a) and lifts this; the thumb opens the lower conjunctival sac.

Fig. 42.8 (right): Subconjunctival injection beneath the dorsal bulbar conjunctiva.

44.1. Scars in the region of the nostril: Scar tissue in the vicinity of the nostril may restrict the ability to completely widen the nares, whereby the influx of air is reduced.

44.2. Nasal diverticulum (= soft nose or also nasal trumpet, p. 45.20): The nasal diverticulum is a caudally blind-ending cutaneous pouch about 3–6 cm long, which is located in the naso-incisive notch and accessible through the “false nostril.” It is formed owing to the presence of the alar fold (*plica alaris*) and is lined internally by a pigmented, predominantly hairless, skin. One ends up in this diverticulum with the introduction of instruments (e.g., nasogastric tube, catheter for the guttural pouch, laryngoscope) if care is not taken that these are led onto the floor of the nasal vestibule. An **atheroma of the nasal diverticulum (epidermal inclusion cyst)** may occur as a unilateral, rarely bilateral, fluctuating mass in the caudal region of the “false nostril.” Usually, this atheroma does not obstruct the airway and its elimination is rather a cosmetic problem.

44.3. Endoscopy of the nasal cavity (p. 45): Ventral and middle nasal meatuses, medial part of the nasal cavity, nasal septum, external surfaces of the dorsal and ventral nasal conchae (see to the left of the figure).

Parts of the middle nasal concha and parts of the ethmoidal labyrinth are accessible for inspection endoscopically. A flexible endoscope facilitates an almost complete examination of the ventral and middle nasal meatuses and of the nasal conchae. If necessary, it can also be introduced into the dorsal nasal meatus. The ethmoidal labyrinth can be better and more safely examined with a fiberscope. Endoscopy of the middle nasal meatus is of importance because of the presence of the nasomaxillary aperture, which occasionally can be identified as a slit in the caudal part of the meatus. Mostly the aperture is covered by the dorsal nasal concha, under the caudal part of which exudates can be observed should the occasion arise.

Introduction of the nasogastric tube (p. 45): In the horse, the most ventral and most spacious of the three nasal meatuses is used for the introduction of instruments, especially the nasogastric tube (stomach tube). The ventral nasal meatus leads via the nasopharyngeal meatus (*choana*) directly into the pharynx. In doing this, at the beginning, the tube passes a nasal mucosal fold, the basal fold, which contains a well developed venous plexus (*plexus cavernosus conchae*), which extends caudally upon the ventral nasal concha. With the introduction of the tube this fold can be injured and there results more or less considerable **hemorrhage** from the venous plexus (epistaxis). Improper handling may even fracture a nasal concha, because these are very delicate and fragile. This happens especially if the instruments introduced are not pushed down upon

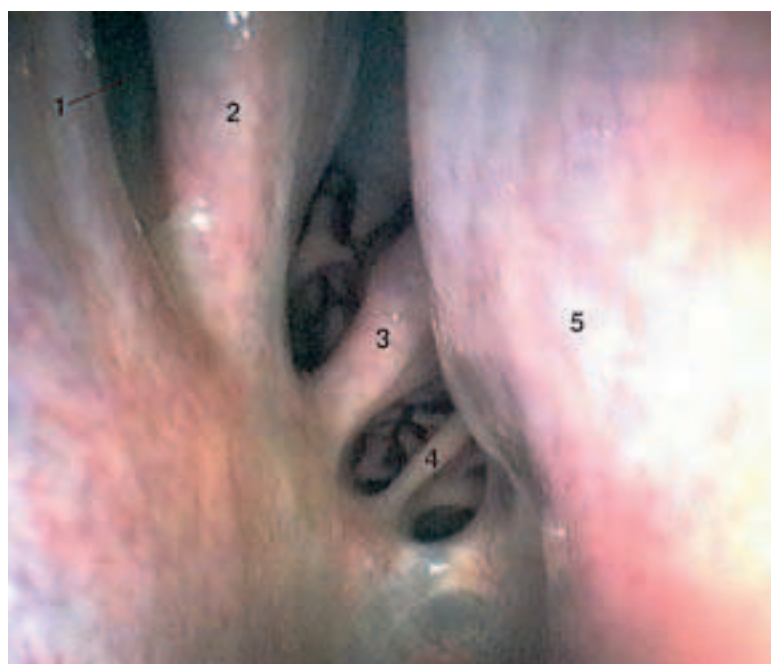


Fig. 44.3. Endoscopy of the nasal cavity. Endoscopic view in the right caudal nasal region. 1. dorsal nasal concha; 2. middle nasal concha; 3., 4. ethmoidal conchae, 5. nasal septum. (Photo, Prof. Dr. Grabner)

the floor of the nasal vestibule. Apart from that, it is also possible to end up involuntarily in the nasal diverticulum.

Trephination of the nasal cavity: The site of trephination depends on the location of the pathological process. The caudal boundary is a line between both medial angles of the eye. In the middle of the head, the nasal cavity can be approached immediately beside the median line, maximally 4 cm lateral.

44.4. Inspection of the nasal mucosa (p. 45) is of clinical importance. Externally, the pink mucosa of the horse is very well visible in the rostral part of the nasal cavity.

Ethmoidal hematomas are slowly spreading angiomatous masses, which develop from the mucosa of the ethmoidal conchae in the caudal part of the nasal cavity (see Fig. 44.3.). They occur in horses of middle age or older and show a preference to thoroughbreds. The most frequent signs are mostly unilateral hemorrhages of the nose. With increasing size of the hematoma, the nasal cavity, commonly the ventral nasal meatus, becomes partially or entirely occluded. With progressive expansion, the hematomas may intrude into the maxillary and frontal sinuses and occasionally result in a distortion of the facial bones.

44.5. Resection of the nasal conchae: In foals up to 2 years of age a mucoid degeneration of the nasal conchae may occur. Owing to the long roots of the teeth, the caudal maxillary sinus at this time is still very flat. Since with the mucoid degeneration of the ventral nasal concha an empyema of the maxillary sinus is to be expected, initially the latter is trephined in the region of the maxillary septum (= *septum sinuum maxillarium*). Here, there is commonly found the cupola whose wall consists of a softer, less firm, bone. The degenerated and expanded dorsal nasal concha fills large parts of the nasal and maxillary cavities.

44.6. The **site for trephination of the dorsal nasal concha** is at the caudal part of the nasal bone, paramedian at the level of the medial angle of the eye (Fig. 34.3.).

44.7. Malformed nasal septum (see p. 51.a'–a''): The nasal septum may be thickened or bent by a congenital abnormality or fracture. Horses with such a nasal septum demonstrate usually a noise in the upper respiratory way.

44.8. Olfactory components, for example, of the vaginal secretions or urine of mares in heat, are received by the **vomer nasal organ**. In stallions, this olfactory stimulus leads to sexual excitement and a behavioral response, which is designated *Flehmen*. In this response, the lips are curled (contraction of the levator labii superioris muscle on each side) and the head is fully extended.

44.9. The **oral cavity** of the horse is very long and narrow. The narrowness of the mouth opening and the great depth of the oral cavity make clinical examination difficult. Nevertheless, the organs and structures are accessible to an examination of the oral cavity for an average-sized hand.

Endoscopy of the oral cavity offers the possibility of an inspection of the oral mucous membrane, the hard and soft palate, the cheek teeth, the gums and the root of the tongue. It is the one possibility for inspection of the oropharynx and especially the palatine tonsil in the horse.

44.10. The **palatine plexus (p. 45.q)** is a venous cushion of the palatine mucous membrane. These veins can fill greatly and swell the palatine mucous membrane up to the mouth, which can be observed especially in foals. Laymen call this appearance “frog” (veterinary: “lampas” or “lampers”).

44.11. Vascularization of the tongue—intralingual injection: The body of the tongue is well vascularized. The effective concentration of a medicament within the blood may be reached rapidly by an intralingual injection. Intralingual injection is an extraordinary injection, done if other intravenous injection is impossible because of venous collapse.

For **intravenous lingual injection**, the branches of the sublingual and lingual veins are used. These veins are visible on the ventral surface of the apex of the tongue and run about 1 cm from the lingual border. As experience shows, the rate of successful intravenous lingual injection in the horse is 82%.

46.1. Lymphoid hyperplasia of the pharynx: In its mucosal lamina propria and in its submucosa the pharynx contains collagenic and elastic fibers mixed with lymphatic tissue and mucous glands. The average degree of pharyngeal lymphoid hyperplasia in the foal or yearling is higher than in the adult horse. Even if this finding is usually considered normal for the juvenile horse, the dorsal displacement of the soft palate occurs more easily and more often in those horses that have a pharyngeal lymphoid hyperplasia of third or fourth degree. Higher degrees of pharyngeal lymphoid hyperplasia diminish with increasing age of the horse.

In an endoscopic examination, **paresis of the pharynx** can be observed as a collapse of the walls of the nasopharynx, which restricts the respiratory way. These signs may occur in horses with a mycosis of the guttural pouch and dysphagia.

46.2. The intrapharyngeal ostium (Fig. 46.4.) is an opening with a “sphincter muscle” for the laryngeal crown and guarantees a direct respiratory way (Fig. 48.2.): nasal cavity-respiratory pharynx-laryngeal crown-trachea. A dislocation of the laryngeal crown into the oropharynx during high oxygen need (extreme stress, races) results in a sudden breakdown of the horse owing to an anoxemia. This phenomenon, called “choking up”, has its cause in a cramp of the sternohyoid and sternothyroid muscles with backward displacement of the larynx. Also retraction of the tongue can dislodge the laryngeal crown in such a way from the intrapharyngeal ostium (“swallowing of the tongue”).

46.3. The pharyngeal ostium of the auditory tube: This opening is the entrance into the guttural pouch in the nasopharynx and is in a transverse plane through the lateral angle of the eye.

The **guttural pouch valve** is a prominent structure of the nasopharynx. It borders the pharyngeal openings of the Eustachian tubes and is about 3 cm in length. It is pressed against the pharyngeal wall of each side and exhibits an oblique, sinuous course of its ventral free border. It is reinforced by a continuation of the medial cartilage that supports the auditory tube. The slit-like pharyngeal ostium of the auditory tube lies lateral to the guttural pouch valve, is closed normally, and is opened if the horse swallows. In this way, the pressure on both sides of the eardrum becomes equalized.

46.4. Soft palate (Fig. 46.4): It is the caudal continuation of the hard palate and is remarkably long in the horse. In the resting state, it hangs down in front of the epiglottis and is in contact by its free border with the base of the epiglottis. This topographical relation explains the inability of the horse to exert an oral respiration in respiratory problems and, on the other hand, the course of the ingesta through the nasopharynx and the nasal cavity in case of vomitus (in the horse, to be sure, very rare).

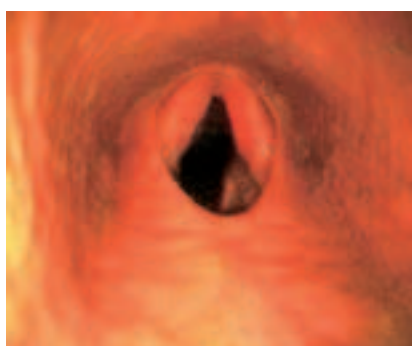

Fig. 46.4. Dorsal displacement of the soft palate. With the position of the instrument in the nasal pharynx (ventral in the picture), the endoscopic picture shows a view of the soft palate (in the picture, below) and the intrapharyngeal ostium (in the middle of the picture), as well as the continuing esophageal vestibule. The mucosa-covered corniculate process of the arytenoid cartilage projects from ventral into the intrapharyngeal ostium and accordingly into the laryngeal pharynx. As a result of the extension of the soft palate, that does not however apply to the epiglottis, which cannot be seen. The intrapharyngeal ostium is closed rostrally by the free border of the soft palate (below in the picture), which caudally passes over bilaterally into the palatopharyngeal arch. The reddening is the result of inflammation. (Photo, Prof. Dr. Grabner)

Dorsal displacement of the soft palate is diagnosed by the non-visibility of the epiglottis in endoscopic examination. Normally the epiglottis lies on the soft palate and projects into the nasopharynx. If these conditions are inverse, the soft palate obstructs the aditus laryngis during inspiration and disturbs expiration. It occurs more often in horses that are not yet adult and seems to have a relation to a high-degree of lymphoid hyperplasia of the pharynx. Young horses with a smaller, flabby epiglottis are more inclined to a displacement of the soft palate than adult ones. Tissues of the pharynx and larynx seem to “mature” with increasing age with respect to size, rigidity and coordination.

The **cleft soft palate (palatoschisis totalis)** is a rare cleft formation in foals and may reach a variable extent; sometimes it involves the total soft palate. In such foals, ingested material is discharged from the nostrils (one or both) and usually they die of pneumonia.

A **lateral buccotomy** (severance of the cheek from lateral) is a method for treating *palatoschisis totalis*. Others are access by way of the oral cavity, mandibular symphysiotomy or laryngopharyngotomy.

Mandibular symphysiotomy (Fig. 38.8.): For the purpose of a successful implementation of larger surgical operations (e.g., cleft soft palate, *palatoschisis totalis*), the mandibular symphysis (inter-mandibular synchondrosis) can be split.

46.5. Guttural pouch: In the horse the auditory tube, which runs between the pharynx and the middle ear, has a characteristic caudoventral diverticulum, the guttural pouch. The opening between tube and guttural pouch is a long slit in the caudoventral tubal wall. Since both the guttural pouch and the auditory tube open into the nasopharynx, they are often involved in respiratory diseases. Since the guttural pouch has a secretory mucous membrane, essentially catarrhal inflammations are found here. The guttural pouch may be subject to a mycotic infection, which erodes its dorsal wall by a diphtheritic inflammation and is responsible for several signs that point to a damage of important blood vessels and nerves. The most spectacular case would be a fatal epistaxis owing to rupture of the internal carotid artery.

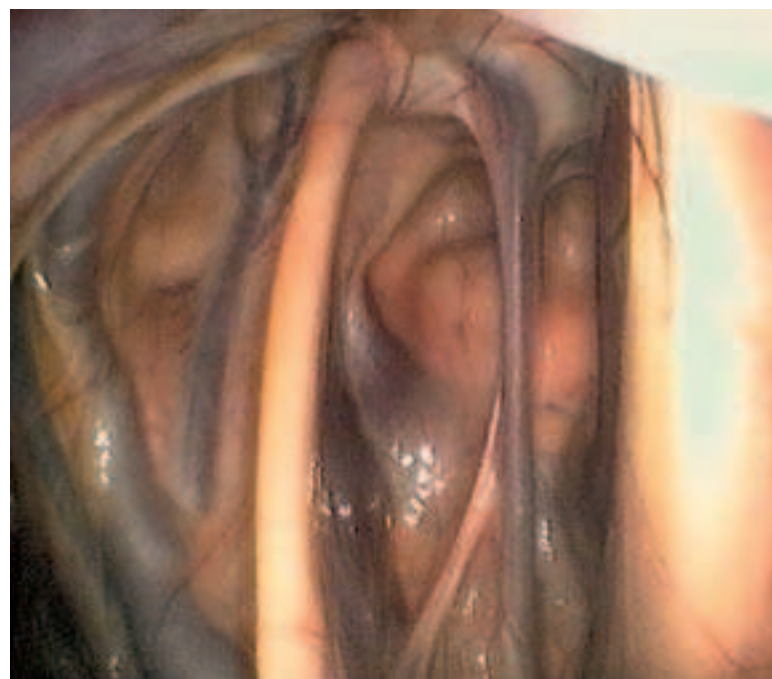


Fig. 46.5.1. Endoscopic picture of the right guttural pouch, rostral view. The endoscope was introduced into the guttural pouch through the slit-like opening of the pharyngeal ostium of the auditory tube (see text-figure, p. 46). With its perpendicular orientation, the broad, bright stylohyoideum separates the lateral recess (left) from the medial recess (right). The medial recess contains the perpendicular neurovascular fold, whose distinct (bluish) internal carotid artery reaches the lower border of the picture and whose lighter glossopharyngeal nerve (central in the picture) shears off toward the stylohyoideum. At the upper border of the picture the bean-shaped cranial cervical ganglion of the sympathetic trunk lies to the right in the neurovascular fold. (Photo, Dr. Grabner, Berlin)

Cranial nerves VII, IX, X, XI and XII can be irritated by diseases of the guttural pouch. Damage to cranial nerve IX may cause loss of taste and sensibility at the root of the tongue, partial anesthesia of the pharyngeal mucous membrane and paralysis of the pharyngeal muscles. The horse is then unable to swallow. The *ramus sinus carotici*, which is responsible for the regulation of blood pressure and heart frequency, may also be encountered with damage to the glossopharyngeal nerve. In this situation, the corresponding regulation by afferent impulses of the pressoreceptors of the carotid sinus and of the chemoreceptors of the glomus caroticum to the medulla oblongata and to the nucleus of origin of the vagus nerve will be disturbed. Such a dysregulation continues on the corresponding efferents to the sinus node and AV-node of the heart.

Damage to cranial nerve X results additionally in partial loss of the sensory and motor functions of the pharynx. With this there exists the danger of an incurable swallow-pneumonia. A possible loss of the cranial and caudal laryngeal nerves causes an absence of the sensory and motor functions of the larynx, with signs of laryngeal paralysis. Injury to cranial nerve XI is clinically not so grave (perhaps twisted neck in case of loss of innervation to the trapezius and sternocleidomastoid [sternocephalicus and cleidomastoid] muscles). If the XIIth cranial nerve is paralyzed, the lingual muscles are involved. The tongue droops from the mouth and cannot be retracted into the oral cavity. A late sequela is an atrophy of the tongue, which occurs also unilaterally if the nerve is damaged unilaterally. Damage to the cranial cervical ganglion of the sympathetic is reflected in a narrowing of the palpebral fissure (loss of tonus of smooth musculature of the eyelids) and by miosis (narrowing of the pupil due to denervation of the dilatator muscle of the pupil). Paralysis of the facial nerve occurs only rarely in connection with diseases of the guttural pouch. Of course, paralysis of the facial nerve and the spread (of the disease process) onto the temporal bone may damage the inner ear and result in vestibular signs. [394] [395] [396] [397] [398] [399]

Tympanic guttural pouch of foals: The accumulation of air (tympany) in the guttural pouch of 2–3 weeks old foals is probably caused by a functional disturbance, produced less by an organic defect of the guttural pouch (mucosal fold on the floor of the slit-like opening of the guttural pouch).

VIBORG's triangle: A triangle located at the transition from the head to the neck, which facilitates external access to the inflamed guttural pouch (Fig. 46.5.2). Its borders are dorsally the tendon of the sternomandibular muscle (sternocephalicus muscle), rostrally the cervical border of the mandible and ventrally the linguofacial vein. Here the skin and cutaneous muscle are first incised, then the parotid gland separated bluntly from the mandible. The blunt dissection process is continued on the medial aspect of the occipito-mandibular part of the digastric muscle in a direction toward the ear to reach the guttural pouch. Furthermore, if abscessed, the medial retropharyngeal lymph nodes are incised from Viborg's triangle. Normally, they are not palpable.

46.6. Anesthesia of the hypoglossal nerve: For anesthesia of the tongue, the lingual nerve and hypoglossal nerve are important. Both nerves are anesthetized from one location. The anesthesia is per-



Fig. 46.5.2. Ventral region of the head-neck border demonstrating Viborg's triangle (surgical access to the guttural pouch). (Photo, Prof. Dr. McCarthy, Sydney)

formed bilaterally. By palpation, the rostral end of the lingual process of the hyoid bone is established. From here one moves 2–3 fingerbreadths rostrally and introduces the needle in a median and perpendicular direction into the body of the tongue.

46.7. Retropharyngeal lymphocenter: This includes the medial (p. 47.27) and lateral retropharyngeal lymph nodes. The former lie on the dorsolateral pharyngeal wall, medial to the mandibular gland and the digastric muscle. They are normally not palpable but, if abscessed, can be incised from VIBORG's triangle. The less numerous and smaller lateral retropharyngeal lymph nodes lie ventral to the wing of the atlas on the internal carotid artery and the lateral side of the guttural pouch (p. 47.22).

48.1. The larynx of the horse is of special importance for the veterinarian. The purchase-examination should include a thorough palpation and inspection of the larynx. With the so-called “**laryngeal roarer**”, in 90% of the cases there is in the forefront an unilateral (left-sided) paralysis of the **dorsal cricoarytenoid muscle** caused by damage to the corresponding recurrent laryngeal nerve. In this case, there occurs a lowering of the arytenoid cartilage (Fig. 48.3. above, right) and—connected to this—a slackening of the vocal fold on the same side. There originates here also the respiratory sound which is characteristic for this disease. In observing the laryngeal lumen with a laryngoscope in such cases, the asymmetry of the *rima glottidis* is striking.

Treatment is directed to a surgical dilatation of the rima glottidis, and this is obtained by a ventriculectomy and an additional laryngoplasty.

In the case of a **ventriculectomy** the mucosal lining of the laryngeal ventricle is removed and the **caudal thyroid notch** furnishes surgical access for this. By the scar-formation that follows, the outer wall of the laryngeal ventricle fuses with the inner wall, including the vocal fold, which is pulled laterally by contraction of the scar tissue with enlargement of the rima glottidis.

Laryngoplasty is directed toward compensating for the loss of contraction of the **dorsal cricoarytenoid muscle**. Corresponding to the action of the paralyzed muscle, a stout alloplastic band is

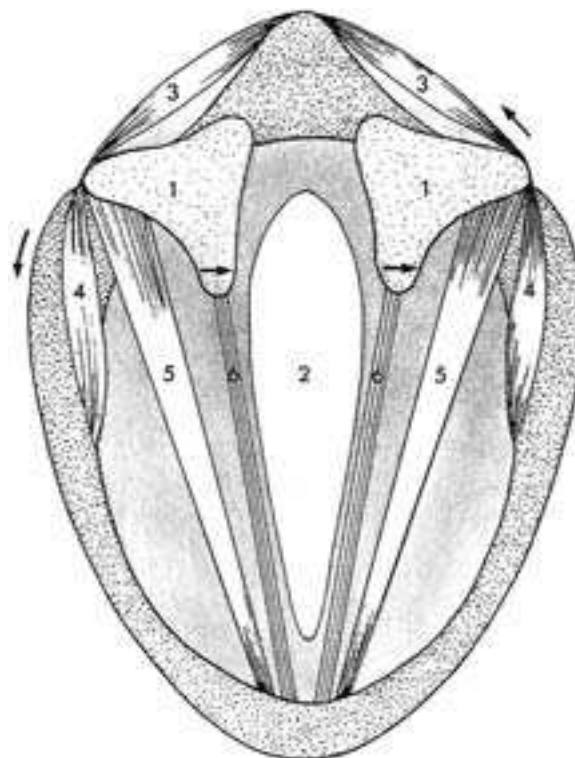


Fig. 48.1. Schematic cross-section through the larynx. 1. Position of the cricoarytenoid articulation under the arytenoid cartilage, 2. glottic cleft (rima glottidis), 3. cricoarytenoideus dorsalis muscle, 4. cricoarytenoideus lateralis muscle, 5. vocalis muscle, 6. vocal ligament muscle in the vocal fold, the arrows on the right side give the direction of pull by the cricoarytenoideus dorsalis muscle and the widening of the glottic cleft, and on the left side the direction of pull of the cricoarytenoideus lateralis muscle and the narrowing of the glottic cleft. (After Dyce/Sack/Wensing [1991])

stretched from the origin of the muscle dorsomedial on the cricoid cartilage to the attachment of the muscle on the muscular process of the arytenoid cartilage. In doing this, the muscular process is drawn caudomedially as in a natural muscular contraction. This results in a craniolateral displacement of the vocal process of the arytenoid cartilage, by which the vocal fold is put under tension for enlargement of the rima glottidis. [400] [401] [402] [403]

48.2. Epiglottic entrapment: This is understood as a “clasping” of the epiglottis. It is brought about by mucosal folds, the aryepiglottic folds, which normally lie below the epiglottis. As thick mucosal membranes they border the laryngeal inlet laterally. Ventrally they are attached to the free border of the epiglottis, in its mucosal covering. Dorsally they course to the lateral and distal surfaces of the arytenoid cartilages and unite below the entrance to the esophagus. The entrapment of the epiglottis happens by dorsal displacement of parts of the aryepiglottic folds. In doing this, these cover the typical vascular pattern, which normally lies upon the epiglottis (Fig. 48.3.).

Epiglottis: Normally the epiglottis of the horse that is not yet adult is smaller and more flabby than in the adult. It lies on the caudal free end of the soft palate. Although the size and the rigidity of the epiglottis are not the only factors that are involved in dorsal displacement of the soft palate (Fig. 46.4.), they appear yet to play a role here. With increasing age the size and rigidity of the epiglottis usually improve.

48.3. Endoscopy of the larynx (laryngoscopy): The larynx of the horse can be inspected by a rhinolaryngoscope, which is introduced through the ventral nasal meatus. In doing this, at the same time, an evaluation of the mucous membrane of the nasal cavity, ethmoturbinalia and pharynx, including the entrance to the auditory tube (EUSTACHIAN tube) is possible.

48.4. Laryngeal ventricle: In the horse it is an outpouching of the laryngeal mucous membrane, which has a depth up to 2.5 cm. It extends between the vocalis muscle and ventricularis muscle in a dorsocaudal direction along the medial surface of the thyroid cartilage. Its blind end lies deeply at the level of the muscular process of the arytenoid cartilage. The laryngeal ventricle of the horse plays a role in laryngeal hemiplegia (left-sided paralysis of the recurrent laryngeal nerve).

48.5. Endotracheal intubation: With endotracheal intubation the angle between the oral cavity and the axis of the *aditus laryngis* must be considered and compensated by lifting the head. In selection of a tube caliber for endotracheal intubation it is to be kept in mind that the glottic cleft is the narrowest place within the laryngeal cavity (Fig. 48.6.).

48.6. Palpation of the larynx: The larynx is easily accessible for palpation from the ventral side. First, one palpates the arch of the cricoid cartilage, the laminae of the thyroid cartilage (lateral and rostral to the arch), the lamina of the cricoid cartilage and on each side the muscular process of the lateral surface of the arytenoid car-

tilage. Moreover, it is to be kept in mind that the ventral surface of the thyroid cartilage is caudally deeply incised (caudal thyroid notch). In the case of the “roarer”, the muscular process is distinctly palpable, because the dorsal cricoarytenoid muscle that attaches here is atrophied.

Accessibility of the larynx: In dorsal recumbency, the larynx of the horse is reached from ventral between the palpable thyroid cartilage and the arch of the cricoid cartilage. The caudal thyroid notch, which is filled by the cricothyroid ligament, is located in the median plane between the two laminae of the thyroid cartilage. In the “roarer operation” or ventriculotomy, one incises between the two sternohyoid muscles in the median plane and cuts through the cricothyroid ligament. Here is the single surgical access. It provides ventral access to the lateral laryngeal ventricle (hemiplegia), to the arytenoid cartilages (chondritis), to the soft palate (displacement), to the oropharyngeal mucosa (entrapment), to the laryngopharyngeal mucosa (follicular pharyngitis-lymphoid hyperplasia) and to subepiglottic cysts. The lateral ventricle is invaginated and cut away at its borders to the laryngeal cavity.

Ear

50.1. Ear fistula: By an ear fistula one refers to a fistulous tract near the rostral border of the external ear from which a permanent or intermittent secretion occurs. The cause is an erratic tooth or several small malformed teeth. Their removal is indicated in sport and breeding horses for hygienic and cosmetic reasons.

50.2 Head tilt occurs in disease of the vestibular apparatus. It is characterized by a tilting of the head-axis, which begins between the ears and runs rostrally between the nostrils. The result is a lower position of the ear, eye, and nostril of one side.

Bending attitude of the head: A bending attitude of head and neck can be observed with a brain lesion. In this, the described axis in the head region remains straight. The head and neck are flexed to one side (pleurothotonus). The bending attitude of the head is not to be confused with head tilt.

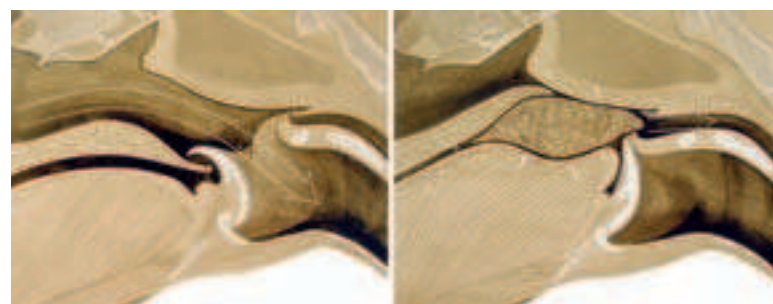
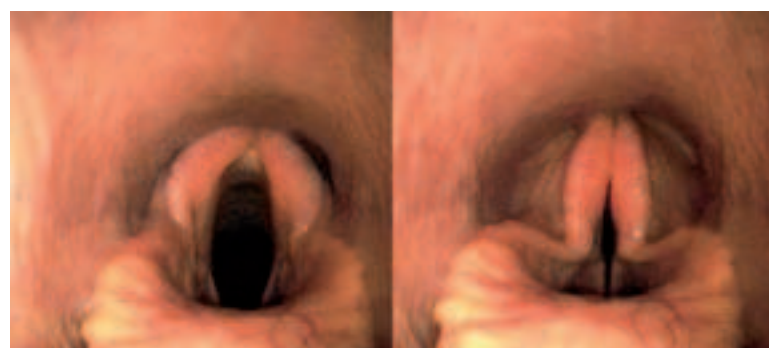
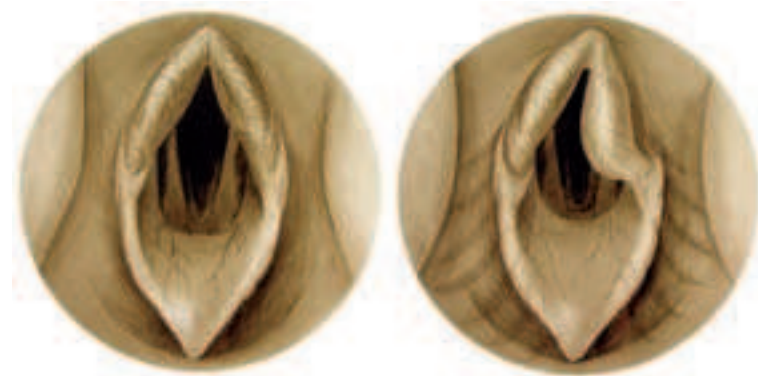


Fig. 48.2. Position of the epiglottis during breathing (left) and swallowing (right). Breathing position (left) and swallowing position (right) of the epiglottis. In breathing, the epiglottis projects through the intrapharyngeal ostium into the nasal pharynx as a part of the laryngeal “crown.” In this case, the air stream arrives from the nasal pharynx through the larynx into the trachea (large arrow). In swallowing the epiglottis, sliding out from the intrapharyngeal ostium, by its retroflexion closes the entrance to the larynx. By elevating the dorsum of the tongue, the bolus passes (small arrow) across the laryngeal entrance into the esophagus. A false passage into the nasal pharynx is prevented by elevation of the soft palate. (Courtesy of Institut f. Veterinär-Anatomie, Berlin)

Fig. 48.3. Illustration (above) and endoscopic picture (below) of the entrance to the larynx. With an opened glottic cleft (left) the vocal folds appear symmetrical and are “framed” by a symmetrical entrance to the larynx. In “roarers” (above right), the glottic cleft is asymmetrical, which is concealed by the collapsed mucosa-covered corniculate process of the arytenoid cartilage (the healthy right vocal fold is visible). The endoscopic pictures (below) reveal the opened (left) and closed (right) glottic cleft and moreover the typical vascular pattern on the surface of the epiglottis, which is concealed in the case of epiglottic entrapment. (Courtesy of Institut f. Veterinär-Anatomie, Berlin)

50.3. Site for taking the pulse—facial artery (Fig. 38.8.): The facial artery is an important structure for taking the pulse. It lies in the vascular notch (*incisura vasorum facialis*). The latter is a vascular notch at the ventral border of the mandible at the boundary between the body and ramus of the mandible (rostral border of the masseter muscle). As the name implies, here several structures coming from the intermandibular space reflect onto the face. In particular, we are dealing with the facial artery, facial vein and the excretory duct of the parotid gland. The pulse can be palpated if the fingertips press the facial artery medially against the mandible as a hard base.

Central Nervous System

52.1. Function of Cranial Nerves (see pp. 108–111)

Olfactory nerves (I): The olfactory sense of the horse is evaluated only with difficulty. It can be tested, if the horse can smell the food, e.g., the hay, or the hand of the investigator.

Optic nerve (II): The visual sense of the horse can be examined in two ways: 1) With the aid of the menace (threatening) reflex and 2) by leading in the direction of large obstacles. Foals can see already a few hours after parturition; but do not yet know the menace reflex, which they need first to learn in a few days. If a sudden movement is made with the hand in a direction toward the eye, the palpebral fissure is closed.

Oculomotor nerve (III): The function of the oculomotor nerve consists of, among others, the regulation of the size of the pupil (pupillary reflex). The parasympathetic fibers of the oculomotor nerve are responsible for the narrowing of the pupil (miosis; pupillary sphincter muscle), the sympathetic fibers of the ophthalmic nerve for the expansion (mydriasis; pupillary dilatator muscle). The diameter of the pupil permits localization and prognosis of brain injury.

Oculomotor nerve (III), trochlear nerve IV) and abducens nerve (VI): These three cranial nerves coordinate the movement of the eyes. For the examination of eye movements, the head of the patient is evaluated first at rest and then in movement.

Strabismus: abnormal position of the ocular bulb: Injury to the third, fourth and sixth cranial nerves may have strabismus as a consequence. Injury to the oculomotor nerve yields a ventrolateral strabismus (with paralysis of the levator palpebrae superioris muscle); that of the fourth cranial nerve, a rotational strabismus (the dorsal part of the eyeball is shifted laterally), and that of the abducens nerve in a medial strabismus with an inability to retract the ocular bulb. In contrast to the small animals a ventral strabismus in the horse is physiological if the head is elevated.

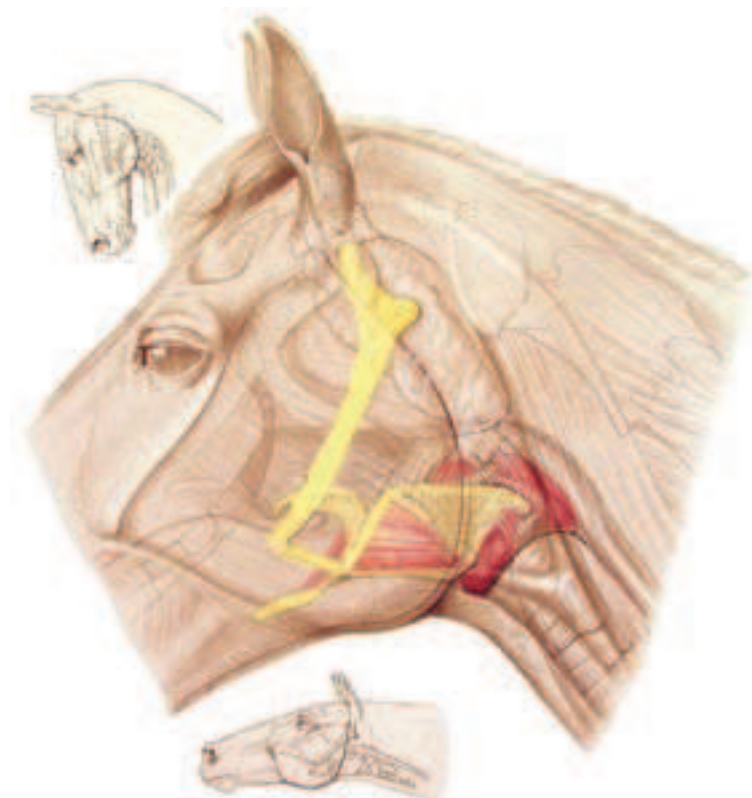


Fig. 48.6. “Glass-head” with the hyoid apparatus emphasized in yellow (cf., text-figure, p. 34) and the laryngeal muscles marked in red (cf., p. 51). (Courtesy of Institut f. Veterinär-Anatomie, Berlin)

Trigeminal nerve (V): The sensory part of the trigeminal nerve (ophthalmic nerve, maxillary nerve, and part of the mandibular nerve) is evaluated by control of the corneal and palpebral reflexes and sensibility in the head region. The latter is performed best on the nasal mucosa. Injury to the motor part of the trigeminal nerve (mandibular nerve) results in a paralysis of the lower jaw, masticatory disturbances, saliva flow, the tongue’s hanging from the mouth as well as an atrophy of the muscles, which are innervated by it (masseter, pterygoid, and temporalis muscles, and rostral part of the digastric muscle).

Abducent nerve (VI) and facial nerve (VII) (see pp. 110/111).

Vestibulocochlear nerve (VIII): Nystagmus (involuntary movement of the eye) with a peripheral lesion of the vestibular system is rare in the horse, so that its occurrence usually speaks for a central injury.

Glossopharyngeal nerve (IX), vagus nerve (X), and accessory nerve (XI): They provide sensory and motor innervation to the larynx and pharynx (IX, X) as well as parts of the muscles of the neck and shoulder. Besides brain diseases also peripheral injuries may be the cause for disturbances of pharyngeal and laryngeal function (e.g., inflammation of the guttural pouch).

Hypoglossal nerve (XII): It supplies the motor innervation to all extrinsic and intrinsic muscles of the tongue. Injury results in a deviation of the tongue to the normal side. A distinct atrophy may develop. In diffuse, severe cerebral damage a protrusion of the tongue is possible (injury to the upper motor neurons, which control the function of the hypoglossal nerve).

52.2. Brain stem and spinal cord can, following a protozoan or herpes viral infection, be altered by degeneration or by inflammation. Consequences, among others, are lameness, ataxia, and muscle atrophy. [404] [405]

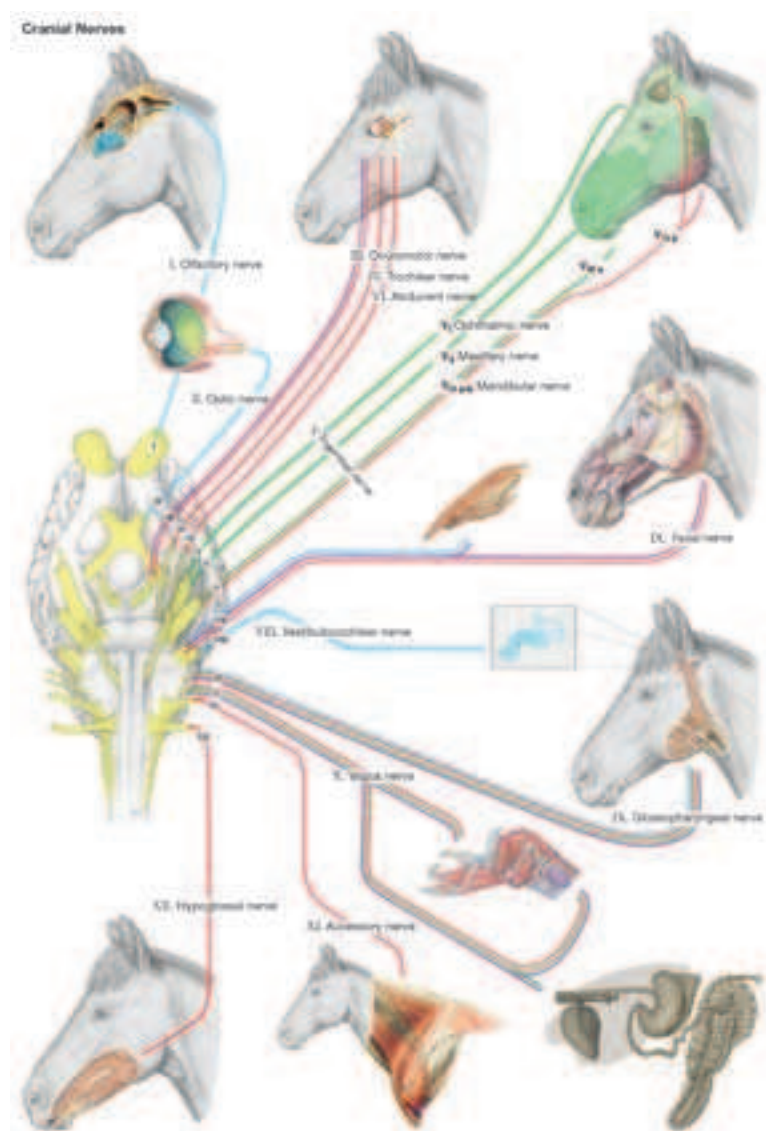


Fig. 52.1. Cranial nerves. Assignment of nerve fiber qualities to their areas of innervation.

52.3. Cerebellar ataxia occurs especially in foals. Cerebellar functions in the coordination of movement are disturbed and lead to the loss of neuromuscular reflexes. [404] [405]

52.4. Cerebrospinal fluid: A clear, colorless plasma ultrafiltrate of the brain and spinal cord. It is formed by the choroid plexuses of the ependymal lining of the cerebral ventricle, and the blood vessels of the pia mater as well as the encephalic arachnoidea. The main place of absorption is an arachnoid villus in the cerebral vein or venous sinus. Other sites of absorption are the veins and lymph vessels around the roots of the spinal nerves. The direction of flow of the cerebrospinal fluid is from the ventricles across the mesencephalic aqueduct to the central canal. The cerebrospinal fluid may be used for diagnostic purposes. The site for puncture to obtain cerebrospinal fluid (cerebellomedullary cistern, *cisterna magna*) lies on the cross-point of the dorsal midline of the head with a transverse line through both cranial borders of the atlas.

54.1. A spinal ataxia occurs especially in young horses. Owing to a spondylolisthesis (a gliding of vertebrae), compressions occur in the cervical spinal cord with interruption of motor and sensory pathways. [406] [378] [407]

54.2. Epidural hemorrhages are traumatically caused and lead to a loss of function of conduction pathways in the spinal cord. [378]

54.3. For epidural anesthesia the interarcuate space between the sacrum and the first caudal vertebra or between the first two caudal vertebrae is chosen. [408] [378] [409]

54.4. Cerebrospinal fluid is obtained for diagnostic examination from the **subarachnoid space**. To obtain larger amounts of cerebrospinal fluid, with the head lowered (bent on the neck), the atlantooccipital space is entered 6.5 cm caudal to the occipital protuberance, into the **cerebellomedullary cistern**. To obtain smaller amounts it is also possible to enter the **interarcuate lumbosacral space**, which lies median on a line between the caudal ends of the two tubera coxae. A funnel-like access to the interarcuate lumbosacral space lies between the spinous processes of the last lumbar vertebra and the first sacral vertebra, which converge at their bases. To obtain cerebrospinal fluid the needle must be introduced through the dura mater into a partial enlargement of the subarachnoid space that lies ventral to the end of the spinal cord. [383] [410]

More references related to the head: [411] [412] [413] [414]

Neck and Back

BIANCA PATAN

56.1. Because in young horses, the radiographically demonstrable **epiphyseal lines of fusion** of the **cervical vertebral column** may be confused with fracture lines, it is important for the clinician to know the time of closure of the epiphyseal lines. At the atlas an epiphyseal line is demonstrable only in dorsoventral view. It is closed at 12 months. [415] On the other hand, on cervical vertebrae vC2–7, there can be demonstrated on the vertebral body in lateral view, one cranial (closure at 2–5 years) and one caudal (closure at 4–6 years) epiphyseal line each. The axis has moreover an apophy-

seal line of fusion to the dens, which closes at the age of 7–12 months. [416] [417] Further epiphyseal lines of fusion of the atlas and axis are demonstrable only by computed tomography. [415]

On the basis of changes in form of the cervical vertebrae, occasionally there occurs a narrowing (stenosis) of the vertebral canal and, in consequence of this, compression of the spinal cord (**cervical vertebral malformation/malarticulation, cervical stenotic myelopathy, wobbler-syndrome**). [418] [419] The resulting neurological signs are expressed as a rule in a disturbance in coordination of movement (spinal ataxia). Among others, it is typically a staggering or stumbling gait, exaggerated or slackened movements of the limbs (dysmetria) and disturbed deep sensibility. [419] Depending on the effect of the attitude of the neck on compression of the spinal cord, two forms are distinguished. **Dynamic (functional) stenosis** appears only with flexion (commonly in the region of vC2–6) or extension of the cervical vertebral column (predominantly vC6–vT1); whereas, **static (absolute) stenosis** is independent of the position in which the neck is held. [420] [419] A further differentiation is possible according to causative factors. *Type I* is based on embryologically conditioned changes (in part, osteochondritic) of the cervical vertebral column, for which reason, as a rule, foals or young horses of the age of 6 months to 2 years are affected. [420] [419] In this case, dynamic as well as static stenosis can appear. [420] These are caused, among others, by an enlargement of the caudal epiphysis or by a bowing in the region of the caudal epiphysis in direction toward the spinal cord (intravertebral stenosis). [421] [420] Also, deformation of the articular processes (especially of cervical vertebrae vC3–5) is possible, which may result in an instability of the cervical vertebral column and by this in subluxations (partial luxations) of the cervical vertebrae. [421] [419] In addition, a caudal elongation of the dorsal vertebral arch may develop, so that the latter projects caudally over the cranial epiphysis of the next vertebral body. The consequence is a dynamic (intervertebral) stenosis, in which case vC2–5 are especially affected. [420] In the case of *Type II*, in which no indications of developmental changes in the area of the cervical vertebrae are present, we are presumably dealing with the late consequence of traumata. Degenerative changes of the vertebral joints (especially vC5–7) are typical. In this case, on the basis of osseous proliferations or on account of the proliferation of articular or periarticular soft tissues, there is brought about a pressure damage of the spinal cord. [420] [419] Usually it appears for the first time at an age of 1–3 years, but it has been observed also in older horses (5–10 years). [419] The usual radiographic examination of the cervical vertebral column results often only in a suspect diagnosis. Precise information concerning the extent and location of spinal cord compression is possible with the aid of myelography (radiographic examination of the cervical vertebral column after injection of radiographic contrast medium into the subarachnoid space). [420] Treatment of foals with Type I changes in the early stage can be conservative (restrictive feeding and limitation of movement). [420] [418] In advanced stages as well as in the case of Type II changes, surgical treatment is possible in selected cases. [420] In doing this both in dynamic and static stenosis a vertebral arthrodesis (surgical stiffening of the intervertebral joint) in the extension attitude of the neck can be performed. This results in a stabilization of the cervical vertebral column. In static stenosis, also a dorsal laminectomy (removal of part

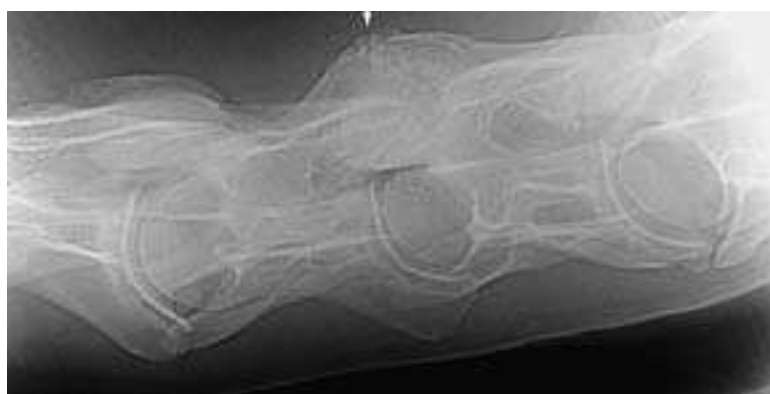

Fig. 56.1. Older vertical fracture in the region of the left cranial articular process of the 6th cervical vertebra (arrow), right = caudal, 3 years old trotter mare. (Courtesy of Klinik für Orthopädie bei Huf- u. Klautentieren, Veterinärmed. Univ. Wien)




Fig. 56.2.1. Multiple fractures of the thoracic vertebral spinous processes in the region of the withers (arrow) with displacement of several fracture-fragments; asterisk: cartilaginous caps of the spinous processes with isolated ossification centers, right = caudal, 3 years old warmblood-gelding. (Courtesy of Klinik für Orthopädie bei Huf- u. Klautentieren, Veterinärmed. Univ. Wien)

of the vertebral arch) is possible to relieve pressure on the spinal cord. [418] [419]

Luxations as well as **fractures of the cervical vertebrae** in the region of the vertebral body or vertebral arch, which are caused by traumata (for example on account of a fall, injuries after being kicked, or strangulation by a halter) may cause a compression of the spinal cord and by this clinical signs of spinal ataxia (wobbler-syndrome) or even inability to rise or respiratory paralysis. [422] In this case, the signs may appear immediately (for example, as a result of focal hemorrhage or structural instability) or they are to be observed only after a certain time, if stenosis of the vertebral canal has developed owing to a callus formation. [420] In fractures of the processes, on the other hand, rather a curvature or lateral flexion of the neck (torticollis) is to be observed. [422] The occipito-atlanto-axial region as well as the caudal neck region (vC5–vT1; Fig. 56.1.) is a predisposing location for fractures or luxations. [420] In young horses especially the epiphyseal growth plates are weak points. [422]

Occipito-atlanto-axial malformation is a relatively rare congenital anomaly of the cervical vertebral column. It is an inherited autosomal recessive and occurs most often in Arabian horses. [418] [417] The disease may have its basis in different anomalies as, for example, a fusion of the atlas and occipital bone, a hypoplasia of the dens of the axis or the development of additional vertebral parts. [420] It is expressed in an extended head/neck-attitude, dysmetria as well as incoordination of the forelimbs and hind limbs (ataxia). [418] [417] These signs are either already present at birth or develop within the first months of life. [420]

To obtain cerebrospinal fluid or the injection of radiographic contrast medium for myelography, the subarachnoid space can be punctured at the **atlanto-occipital space**. To do this, with the head-neck in the flexed position, the needle is introduced perpendicularly to the skin on the midline at the level of the cranial borders of the well palpable atlantal wings. The puncture is usually performed on the anesthetized horse in lateral recumbency. [418]

56.2. The spinous processes of the thoracic vertebrae vT3–9 form the withers, the highest point of which is located in the region of vT5 or vT6. The position of the saddle is located in the region of the caudal thoracic vertebrae (vT10–18). [423]

In young horses the spinous processes of vT2–8(-9) are covered by cartilaginous caps, each of which has its own ossification center (Fig. 56.2.1. – asterisk). The corresponding apophyseal fusion-lines close only at the age of 7–15 years and should not be confused with **fractures of the spinous processes** (Fig. 56.2.1. – arrow). Such fractures, which usually are the consequence of trauma (for example after overturning of the horse), heal frequently without surgical intervention within 4–6 months. Mostly there remains a distinct sagging of the withers, in which case the performance of the horse commonly is not affected. [425]

The interval between the spinous processes of the thoracic and lumbar vertebral column as a rule amounts to more than 4 mm. [423] Approaching (interval less than 4 mm) and finally touching or even overlapping spinous processes of the thoracic and lumbar vertebral column are a frequent cause of “back problems” in the horse (**thoracolumbar interspinal syndrome, kissing-spines syndrome**). [426] [427] [423] The spinous processes of vT10–vL4 (most often

vT13–18) are usually involved, [423] because the greatest dorso-ventral mobility of the vertebral column is found in this region. [426] To be sure, the narrowing of the intervals between the spinous processes is not always to be evaluated as pathological, for about one-third of the horses show no clinical signs. [423] A possible explanation of the cause is physiological transformational processes on the spinous processes, which are regarded as an adaptation to biomechanical loading. [426] [423] The attachment of the supraspinous ligament at the dorsocranial border of the spinous processes plays a special role in that in older horses it is often drawn out hook-like in the cranial direction. [426] Because the greatest dynamic forces on the equine back act at high speed and jumping, racehorses and jumpers are considered especially vulnerable. [428] [423] In the case of the latter, a maximal curvature of the back is observed at the jump over the obstacle; whereas, in landing the back is maximally lowered. [428] Owing to the repeated nonphysiological lowering of the back there occurs a regular pressing on each other of the spinous processes, which is regarded as the exciting cause for the development of “kissing spines” in jumpers. Dressage, western, and pleasure horses may likewise be encountered, in which case most often horses at an age of 5–9 years are affected. [423] In clinical examination typically there is observed a pressure-pain after palpation of the spinous processes as well as pain reactions with reflexly triggered dorsoflexion (lowering of the back). [428] [423] In radiographic examination, besides the closeness of the spinous processes, mostly local reactions in the form of border sclerotizations (bone condensations), osteolytic regions (areas of dissolution within the bone) as also exostosis-like form changes (bone excrescences) are observed (Fig. 56.2.2.). [423] The nonphysiological contact of the spinous processes may also lead to radiographically visible changes at other locations; thus, sometimes also arthrotic changes on the small vertebral joints are found (**spondylarthropathia deformans, spondylarthrosis**). [426] Besides treatment with medicaments, there is described a surgical procedure in the form of a partial resection of the affected spinous processes. [427] [429]

Sometimes exostotic bone formations (**spondylosis deformans**) can be demonstrated radiographically in older horses. These appear ventrally on the vertebral bodies of the thoracic vertebral column (especially between vT11–16) and in part may even cause a bridge-formation (ankylosis) between adjacent vertebrae. [430] [431] Their basis is a chronically degenerative disease of the ventral longitudinal ligament, which is especially strained by the maximal axial rotation and lateral mobility in this region of the vertebral column. [426] [431] The described changes can go along with “back problems”; however, they are usually only chance radiographic findings without clinical relevance. [425]

Intervertebral disc problems in the thoracolumbar region (discopathias) play only a secondary role in the horse. [428] [431]

On the thoracic and lumbar vertebral column different inherited or acquired deformations can be observed. A ventrally convex flexion of the vertebral column (mostly between vT5–10) is designated **lordosis**. Older breeding mares are often affected after a greater number of pregnancies. A dorsally convex curvature of the vertebral column (mostly in the region of vL1–5) is designated **kyphosis** which is most frequently observed in the foal recently separated from its mother. By **scoliosis**, one understands a lateral curvature of the vertebral column (usually between vT10–18), which as a rule is brought about by a unilaterally reinforced tonus of the back muscles (especially of the longissimus thoracis muscle; in *clinical* use, also designated longissimus dorsi muscle). [425]

56.3. The **sacrum** is connected to the pelvic girdle and accordingly with the pelvic extremity by articulation (**sacroiliac joint** or **iliosacral joint**). A tight ligamentous apparatus is present around the joint. It is formed by the ventral and dorsal (*pars brevis* and *pars longa*) interosseous sacroiliac ligaments as well as the broad sacrotuberous ligament. [176] Damage to the ligamentous apparatus and by this a relaxation of the joint may occur as a consequence of trauma. [230] Because of chronic instability exostoses often appear in the region of the iliosacral joint; whereas, subluxations (partial luxations) are observed rather seldom. [231] Racehorses as well as jumpers and dressage horses are especially frequently encountered [230], in which case apparently large warmblood horses in particular have a predisposition for disease of the iliosacral joint. [432] [425] Horses usually show a certain stiffness and a low level of thrust of the pelvic limb. [425] [230] If only the iliosacral joint is

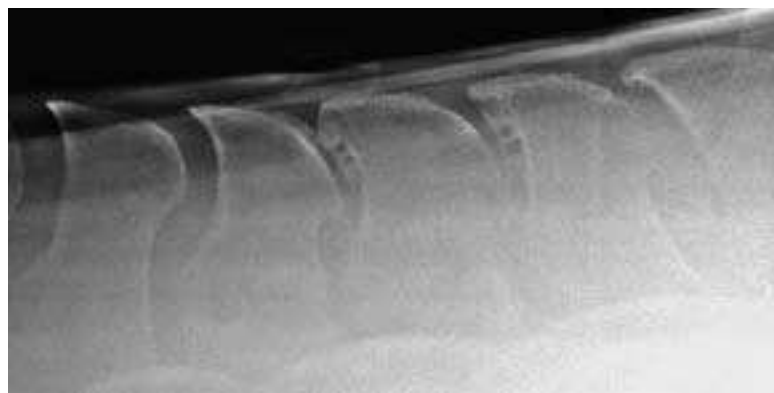


Fig. 56.2.2. “Kissing” spines in the caudal region of the saddle position with bony excrescences and osteolytic areas on the cranial contour of the spinous processes, right = caudal, 5 years old warmblood-gelding. (Courtesy of Klinik für Orthopädie bei Huf- u. Klautentieren, Veterinärmed. Univ. Wien)

involved, then the horses frequently demonstrate a unilateral muscular atrophy; however, as a rule, they exhibit no asymmetry in the region of the sacral tuber. A unilateral projection of the sacral tuber occurs rather with changes of the dorsal ligamentous structures or a thickening of the subcutaneous tissue. [432] To be sure, an asymmetry of the sacral tubers is frequently observed even in clinically healthy horses. [231] Transcutaneous and rectal sonographic investigation as well as scintigraphy provide useful information for obtaining the diagnosis. [432] To confirm the diagnosis, local regional infiltration of the iliosacral region can be performed. A 9–15 cm long spinal needle is introduced axial to the sacral tuber at an angle of about 20° directed caudally (toward the opposite iliosacral joint) and advanced between the diverging spinous processes of vL6 and vS1 (Fig. 56.3., 3). At contact with bone in the caudomedial region of the joint, 20 cc of a 2% local anesthetic solution is injected and the procedure repeated on the opposite side. [231] [432] This anesthesia is not entirely specific because of possible diffusion to the interosseous sacroiliac ligaments or to the longissimus dorsi muscle as well as to the dorsal branches of the sacral nerves. [432] A possible complication exists in the paresis of the ischiadic nerve. [231] Recently, additional approaches for per-articular injection of the iliosacral joint (partly with ultrasonographic guidance) have been described (Fig. 56.3.). [432a, 432b]

56.4. Cerebrospinal fluid may also be obtained in the standing horse from the subarachnoid space by way of the **lumbosacral interarcuate space**. Access is between the palpable spinous process of the last lumbar vertebra and the spinous process of the 1st sacral vertebra, which lies between the two palpable sacral tubers of the pelvis. The needle is advanced perpendicularly through the skin 10–12 cm deep. [377]

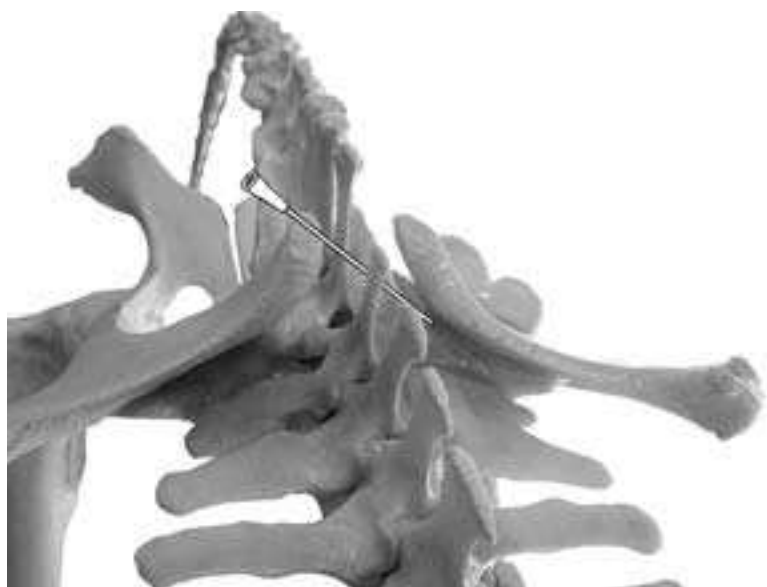

Fig. 56.3. Potential approaches to the iliosacral joint: (1) cranial approach, (2) craniomedial approach, (3) medial approach, (4) caudal approach. (Photo, Dr. Patan)

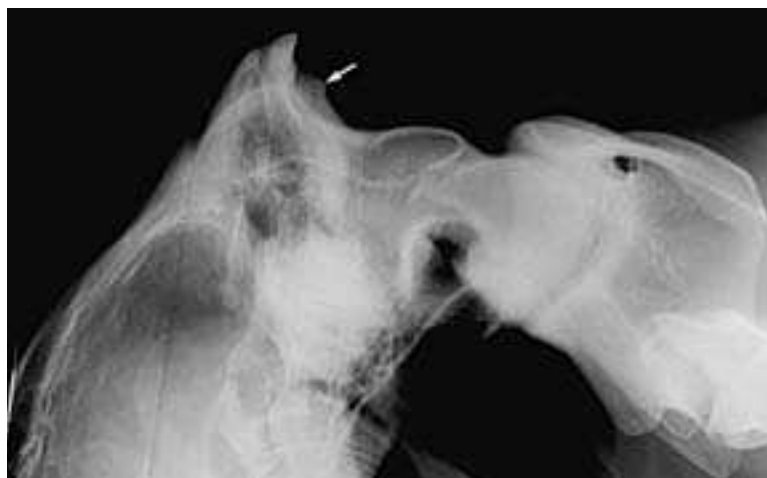

Fig. 56.5. Desmopathy in the region of the attachment of the funicular part of the nuchal ligament on the external occipital protuberance (arrow), right = caudal, 9 years old warmblood mare. (Courtesy of Klinik für Orthopädie bei Huf- u. Klauentieren, Veterinärmed. Univ. Wien)

In the horse, it is not possible to obtain cerebrospinal fluid by way of the **sacroccygeal interarcuate space**, because the subarachnoid space does not extend caudally beyond the sacrum. However, epidural anesthesia is possible (e.g., for an operation in the region of the vulva). [377]

56.5. In case of overloading of the **nuchal ligament** at its insertion (external occipital protuberance), pathological changes of the soft and bone tissues (**insertional desmopathy**) may occur. With radiographic examination, sometimes exostoses of the occipital bone (Fig. 56.5.) or calcifications in the nuchal ligament can be recognized. Affected horses often put up resistance as well as a recidivistic shaking of the head when ridden. [433]

56.6. Inflammation and infection of the **supraspinous bursa** (*bursa subligamentosa supraspinalis* or *cucullar bursa*) may result in the development of the so-called **fistulous withers**. [434] A chronic discharge of pus at the withers is typical. It is often resistant to treatment. [435] In advanced cases it can proceed to a necrosis of surrounding tissues (fascia, supraspinous ligament, cartilaginous caps) up to a suppurative fusion of the spinous processes. [434] The surgical treatment comprises the opening up of the bottom of the fistula and a removal of the synovial bursa. [434]

56.7. Inflammation of the **nuchal bursa** (*bursa subligamentosa nuchalis cranialis* or *caudalis*) comprises a typical circumscribed swelling at the back of the neck (*talpa*). If the synovial bursa is suppuratively infected, a necrosis of the nuchal ligament and development of a fistula with chronic discharge of pus may result. In this case a surgical procedure in the form of a partial resection of the nuchal ligament and removal of the nuchal bursa is indicated. [434] [435]

Neck and Thoracic Cavity

K.-D. BUDRAS, R. BERG

58.1. In the operation for prevention of wind-sucking (cribbing) the **sternomandibular muscle** is made nonfunctional by different methods. According to HUSKAMP *et al.* [436], this is realized by neurectomy of the ventral branch of the accessory nerve. In other methods, a muscular portion is cut out of the omohyoid, sternohyoid and sternothyroid muscles. [437]

58.2. The descending pectoral muscle is well suited for intramuscular injection. If infection or other incompatible situations should occur, then developing accumulations of pus can be cut open (and drained), because this is a most ventral site. [436] [438]

58.3. For venepuncture to obtain blood or for injection, the **external jugular vein** is easily accessible in the cranial third of the neck. This part is chosen for the reason that the external jugular vein is subcutaneous here and uncovered or covered only by thin strands of the cutaneous colli muscle and deeply is separated from the common carotid artery by the omohyoid muscle. Paravenous injections (injections beside the vein) should be avoided under all circumstances. Deep injections—penetrating the omohyoid muscle—may be disastrous. An unintentional injection of certain medicaments into the common carotid artery can be fatal. Whether or not the injection needle is correctly found in the external jugular vein or unintentionally in the common carotid artery is checked by means of the color of the blood and the blood pressure. Also unintentional injections into the carotid sheath may have severe consequences. The **carotid sheath** is a derivative of the deep cervical fascia and surrounds the **common carotid artery** together with the **vagosympathetic trunk** and **recurrent laryngeal nerve**. A medicament injected here in higher concentration results in damage to the nerves. The consequences could be a unilateral paralysis of the recurrent laryngeal nerve (“roarer”) or a loss of cranial sympathetic nerve function (HORNER’s syndrome). [439]

58.4. Because the **esophagus** is palpable in the left middle third of the neck, the correct position of the nasogastric tube can be checked here.

60.1. In the case of a unilateral perforation of the pleural cavity, for example, in the lateral thoracic wall, the **perforate mediastinum** brings about an extension of pneumothorax to the opposite (initially intact) side of the body, which to be sure appears here in a diminished degree. [440] [383]

60.2. In the **lung auscultation and percussion field**, if pulmonary emphysema is present, there can be observed a distinctly enlarged lung with caudal displacement of its basal border. Starting from a bronchitis with accompanying swelling of the respiratory mucous membrane, the bronchial lumen becomes narrow in an obstructive ventilation disturbance, which brings about an inflation (overexpansion) of the pulmonary alveoli. The normal retraction in the expiratory phase is no longer assured. There develops an enforced expiration with increased use of auxiliary expiratory muscles, especially the abdominal muscles. [431] [441] [442] [443]

62.1. The **equine heart**, isolated from the cadaver, can be differentiated from the bovine heart by the following characteristics:

According to age and functional condition, the **form of the heart** is rather pointed-conical in bovine and in the horse rather blunt-conical.

The **fat tissue** of the coronary grooves is almost white in the ox and more abundant and of firm crumbly consistency (a few bovine breeds on the Channel Islands have a yellowish fat tissue similar to the horse).

In the ox, the **auricles**, on their free borders, are more strongly crenated than in the horse.

The **cardiac skeleton** of the ox consists of a large and a small cardiac bone; in the horse, on the other hand, two cardiac cartilages.

The coronary arteries of the ox are arranged according to the pattern of the **left coronary supply type**; that is, both interventricular branches originate from the left coronary artery. On the other hand, in the horse a **two-sided coronary supply type** is present, whereby the paraconal interventricular branch originates from the left coronary artery and the subsinuosal interventricular branch

from the right coronary artery. As a species-specific characteristic, the ox has at the left interventricular border an additional groove, the intermediate groove (*sulcus intermedius*), which contains the caudal cardiac vein (*v. cordis caudalis*). In the horse, this groove and vein are lacking.

A **left azygos vein**, which discharges into the coronary sinus, is present in the ox. The **horse** has a **right azygos vein**, which opens into the cranial vena cava. [381] [444] [445] [446] [447] [448] [449] [450]

62.2. The **puncta maxima** are those places on the left or right thoracic wall where the cardiac valve sounds are most distinctly audible. [451]

The **mitral valve** (bicuspid valve) can be auscultated on the left side in the fifth intercostal space, three fingerbreadths caudodorsal to the olecranon tuber. For the **aortic valve**, the site of auscultation is three fingerbreadths more dorsal through the fourth intercostal space and for the **pulmonary valve** somewhat in-between in the third or fourth intercostal space.

The **tricuspid valve** is auscultated on the right thoracic wall a handbreadth dorsal to the olecranon tuber in the third or fourth intercostal space.

62.3. With increasing age, especially on the **aortic valve**, fibrous nodules appear on the free margin of the valve and degenerative fenestrations in the central valve region. However, these scarcely give rise to functional limitations. [383] [380]

62.4. The **internal cardiac relations** are connected with the **action of the heart** whose phases take place synchronously on the right and left heart. These phases are **systole** with **isometric** and **ejection phases** and **diastole** with **relaxation** and **filling phases**.

Venous blood reaches the right atrium via the cranial and caudal venae cavae as well as the right azygos vein and the coronary sinus. **Arterial blood** flows from the lung via the pulmonary veins into the left atrium. At the boundary with the ventricles of the heart the

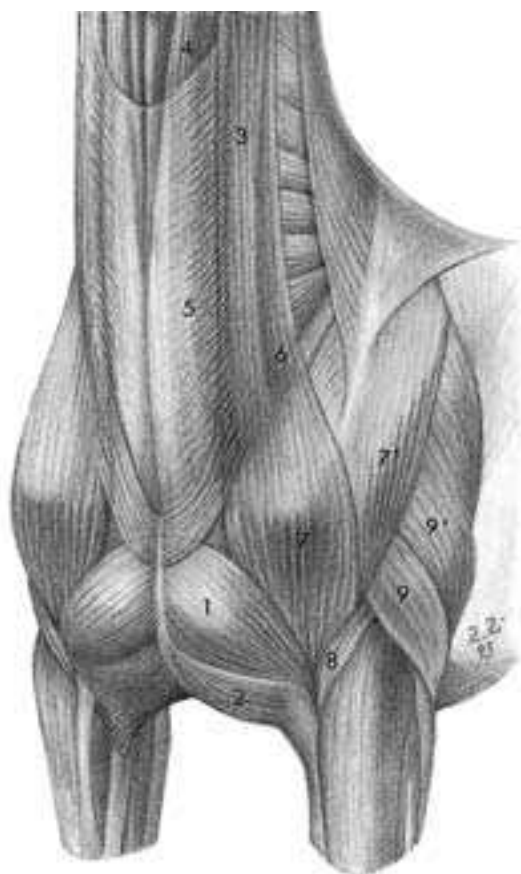


Fig. 58.1. Cranioventral thoracic region with the descending superficial pectoral muscle (1) for intramuscular injection. 2. transverse superficial pectoral muscle, 3. cleidomastoideus muscle, 4. sternomandibularis muscle, 5. cutaneous colli muscle, 6. omotransversarius muscle, 7. clavicular part of the deltoideus muscle (cleidobrachialis m.), 7'. Scapular part of the deltoideus muscle, 8. brachialis muscle, 9. lateral head of the triceps brachii muscle, 9'. long head of the triceps brachii muscle.

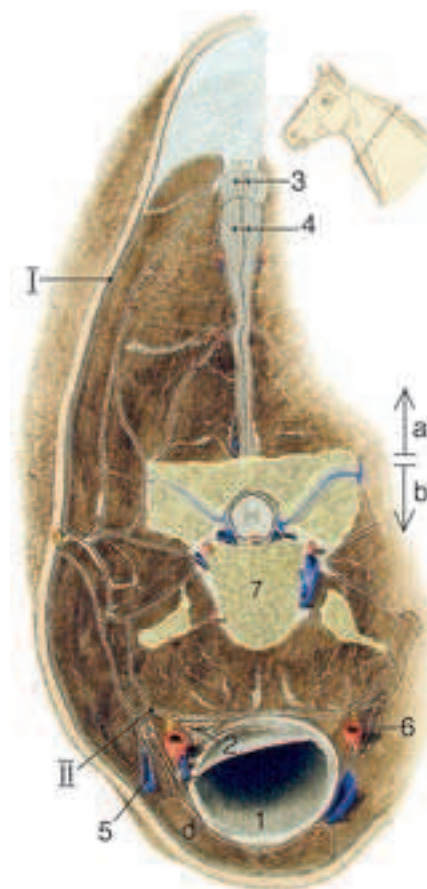


Fig. 58.3. Cross-section of the neck at the level of the border of the upper third with demonstration of the external jugular vein and the common carotid artery with the carotid sheath. I. superficial cervical fascia, II. deep cervical fascia which envelops the cervical viscera with septal laminae and, as the carotid sheath, envelops the common carotid artery (6). 1. trachea; 2. esophagus; 3. funicular part of the ligamentum nuchae; 4. lamellar part of the ligamentum nuchae; 5. external jugular vein in the jugular furrow; 6. common carotid artery with accompanying vagosympathetic trunk and recurrent laryngeal nerve; 7. fourth cervical vertebra. a, epaxial trunk and limb musculature; b, hypaxial trunk and limb musculature; c. omohyoideus muscle; d. sternomandibularis muscle. (Courtesy of Institut f. Veterinär-Anatomie, Berlin)

mitral valve (= bicuspid valve) is located left and the tricuspid valve on the right side. During **diastole** in the **relaxation phase**, all cardiac valves are closed with low or absent ventricular pressure. In the **filling phase** of **diastole** the atrioventricular valves are properly pushed open like flood gates by the surging blood stream. The filling of the cardiac ventricles is realized by three factors:

By **lowering** and **raising** of the **valve plane** (at the atrioventricular border, all valves lie in one plane), “snap” movements are carried out and by that the blood is sucked into the chambers. A low resting pressure in the feeding veins contributes to the filling of the ventricle.

Contraction of the atria by the relatively weak atrial musculature is to be sure a slight factor, but is worth mentioning.

In the following **systole**, with increasing ventricular pressure the chordae tendineae prevent a reflection of the cuspid valves back into the atrial region. Rather, with backflow of the blood, there is a tension on these tendineae and an apposition of these valvular borders at the level of the valve plane and by this closure of the valves according to the functional principle of a back-flap valve. The closure of the two atrioventricular valves in combination with the isometric vibrations of the ventricular musculature causes the **first (longer) heart sound**. This occurs during the **isometric phase** of ventricular contraction (systole). In the **ejection phase**, the second phase of systole, with increasing ventricular pressure, the blood is driven into the efferent great vessels (left: aorta; right: pulmonary trunk). At the end of the ejection phase, the three semilunar valves at the origin of the great arteries are closed. This is realized at the beginning of diastole and the lowering of the blood pressure in the ventricles below that of the great arteries. The three pocket-like valvulae of the semilunar valves are closed by their expansion due to the backward-flowing blood and the apposition of their borders. **Closure of the semilunar valves** at the origin of the great arteries generates the **second (short) heart sound (semilunar valve sound)**.

Heart murmurs are abnormal and may be caused by persistence of the **ductus arteriosus** of **BOTALLI** (current noises) or by narrowing (**stenosis**) or insufficient closure (**insufficiency**) of the valves (valvular murmurs). A **systolic murmur** occurs between the first and second heart sounds. A **diastolic murmur** occurs between the second and first heart sounds. With attention to the **puncta maxima**, valvular murmurs can be assigned to specific heart valves.

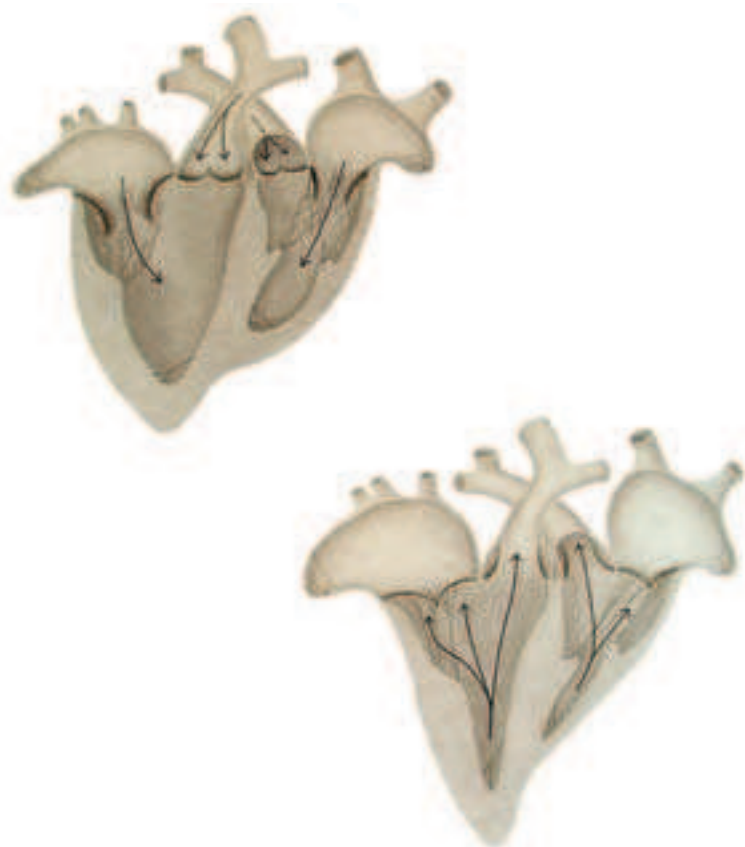

Fig. 62.4. Heart's action, represented on the opened heart with filling phase in diastole (above) and ejection phase in systole (below). (Courtesy of Institut f. Veterinär-Anatomie, Berlin)

Abdominal Wall and Abdominal Cavity

K.-D. BUDRAS, E. HENSCHEL

64.1. The **linea alba** is of substantial importance for abdominal surgery. The preumbilical part of the linea alba is frequently chosen for access to the abdominal cavity, *e.g.*, in ileus surgery. Here the linea alba is 1–2 cm wide and has characteristic longitudinal fibers. On its inner surface, there is a distinct ridge, which the surgeon cuts along to remain on the midline. With closure of the abdominal cavity, the connective tissue cord thus cut in half offers a firm and strong fixation for suture material. [452] [453] [454]

64.2. **Umbilical hernia** appears not rarely in foals as a congenital hernia. Acquired umbilical hernias may occur at any age and are of a traumatic nature. The hernial porta is the (not closed) hernial ring. The internal hernial sac consists of parietal peritoneum and transversalis fascia. The evaginated external cutis is designated as the external hernial sac. The content of the hernia consists mostly of loops of small intestine and portions of the greater omentum. [455]

64.3. For the **ventral (abdominal) hernia** a pre-formed hernial porta does not exist. It can occur in the abdominal and flank region. Often it is of traumatic origin. Scar hernias may develop several weeks after an operation. In mares in late pregnancy, a hypogastric hernia may be caused by rupture of the insertion of the rectus abdominis muscle. [452] [378]

64.4. In the case of **costal laparotomy** the last two ribs are resected with preservation of the periosteum. Access is chosen for the left side for a splenectomy and on the right side for operations on the base of the cecum, ileum, and duodenum. The suture material can be nicely fixed within the periosteum, which is made still stronger by periosteal ossification. [408] [453]

64.5. The **external abdominal oblique muscle** hypertrophies in horses with emphysema. Because of the expiratory dyspnea, these animals use more often the abdominal press for expiration. This causes a hypertrophy of the muscle, which is especially distinctly marked at the transition into its aponeurosis. This transition forms the so-called “heave line”, which runs about a handsbreadth caudoparallel to the costal arch. [456]

66.1. Knowledge of the **position of the abdominal organs** in relation to the abdominal wall are a precondition for clinical examination; *e.g.*, for differential diagnosis of colic.

Auscultation (listening to the sounds of the organs) enables the qualitative and quantitative identification of gastrointestinal sounds, which are specific for certain parts of the intestine. On the left dorsal abdominal wall, in the paralumbar fossa, sounds of the small intestine are audible. On the left ventral abdominal wall specific intestinal noises of the left dorsal and ventral ascending colon can be evaluated. In the paralumbar fossa of the right dorsal abdominal wall, between the costal arch and the tuber coxae, the diagnostically important sound of the discharge of the small intestinal content into the cecum can be realized. Since the mouth of the ileum is located on the medial side of the cecum, not far from the median plane, the faint noise of discharge of the small intestine can perhaps also be discerned in the left paralumbar fossa. Its absence is indicative of an obstruction in the small intestine.

The cecum is accessible in the right paralumbar fossa for endoscopy (typhloscopy) as well as a puncture with the trocar for the relief of pressure after gas formation. A cecal fistula is implemented farther cranially in the region of the right costal arch to obtain juice of the cecum, colon and ileum. For this, the last two ribs are resected. [378]

68.1. The **round ligament of the liver (obliterated umbilical vein)** is especially distinctly developed in horses in the ventral pre-umbilical abdominal wall. It is firmly connected to the peritoneum and, in the case of laparotomy on the linea alba, serves for this reason as the location for opening the peritoneal cavity. After blunt separation of the subserous fat, the ligament, which is about 1 cm wide, is sharply split on the midline and this gap then bluntly enlarged as desired. The firmness of the ligament later secures the peritoneal suture and prevents insufficiency of the suture. [453]

68.2. Gastrointestinal colic. Colic comprises gastrointestinal illness (especially pain) and was derived originally from colon, the historically presumed site of abdominal pain. Besides acute colic, there are also chronically recidivist colic forms, which are caused, for example, by chronic blood circulatory disturbances or disturbances of innervation.

For the necessary determination of the manifold causes of colic, a fine differential diagnostic is required.

Rectal palpation, which is not free of risk for the veterinarian and the patient (danger of rectal perforation, see 70.8.), should be repeated several times if colic is suspected. This is done to follow the course of the disease, if not contraindicated for compelling reasons (e.g., if the horses are small or foals). Depending on the size of the investigator and of the patient, rectal exploration may encompass almost the entire peritoneal cavity.

The **teniae** of the large intestine, a concentration of the external longitudinally-running muscle cells of the tunica muscularis, with their typical number in certain parts of the intestine are important aids to orientation in identification of definite parts of the gut with possible variations from the norm. Their extraordinary tension gives an indication of pathological alterations (e.g., flatulence). Rectal examination is usually very informative in regard to pathological changes in position, content, size, movability, wall-thickness and consistency of the part of the gut. It is also informative for the diagnosis of internal hernias. For this reason, in male animals, the vaginal ring is examined for the presence of an inguinal hernia. For details of the rectal palpation see page 178.

The entire intestinal tract, including the stomach, from an applied-anatomical view has several congenital or acquired sites of predilection, which are described in the following with respect to the predisposition to colic.

The **stomach** with its numerous structural predispositions for colic diseases is not accessible by rectal palpation, at least in large equine breeds. The equine stomach with its typical characteristics (low capacity, no possibility of spontaneous pressure-release) presents special problems for the veterinarian. Thus the oblique (acute-angled) implantation of the esophagus in the gastric wall and the strong cardiac sphincter prevent release of fluid, ingesta or gas by way of the esophagus. A gastric overload or overstress develops very easily. Only an immediate pressure relief by the nasogastric tube can save the animal from a fatal rupture of the stomach. With signs of colic, a failure to relieve pressure is a professional blunder. With introduction of the nasogastric tube, the hindrance of the cardiac sphincter muscle is overcome by insufflation of air.

Besides gastric relief for the prevention of a dreaded rupture of the stomach, the probe of the stomach has also a considerable diagnostic value and is principally implemented, if no compelling reasons speak against it. The ventricular ingesta obtained is examined qualitatively and quantitatively (pH value, amount, smell, color). From a typically altered stomach content obtained by reflux, intestinal obstruction can be concluded. [457] [458]

Internal hernias are considered frequent causes of colic. The congenital (preformed) or acquired hernial porta causes the hernia-content (intestine) usually to develop a partial or total strangulation-ileus (intestinal obstruction) with the danger of a necrosis of the intestinal wall.

The **hernia of the lienorenal space** (*hernia spatii lienorenalis*) arises by the displacement of the left parts of the ascending colon into the lienorenal space. This lienorenal space (end of the pointer in Fig. 68.2.1.) lies between the dorsal abdominal wall and the lienorenal ligament (blue band), which in elongation of the greater omentum connects the dorsal end of the laterally placed spleen with the medially placed left kidney. It is present only in horses. The left parts of the ascending colon normally lie distinctly ventral to the apex of the spleen. Since they are freely moveable and connected only with one another they can pass lateral to the spleen and raise themselves above its dorsal end into the lienorenal space (red-dotted line). The longitudinally directed left ascending colon crosses then over the transverse lienorenal ligament and hangs over it as if upon a clothes-line.

In the case of hernia of the omental foramen (*hernia foraminis omentalis*), the epiploic or omental foramen (foramen omentale, Fig. 68.2.2.) functions as a congenital hernial porta. Just like the examining hand in a necropsy, parts of the small intestine reach from the right side, dorsal to the descending duodenum, between the right kidney and liver via the epiploic foramen into the omental bursa. This hernia leads with certainty to a strangulation and incarceration of these intestinal parts, which can only be cured by a surgical operation. More frequently there are displacements (with incarceration) of the intestine from left to right, and in doing so the greater omentum becomes ruptured by the intestinal loops or evaginated and is pushed together with the intestine through the epiploic foramen. With atrophy of the right liver lobe, the epiploic foramen becomes enlarged with increasing age, and predisposition to the type of colic described here is increased.

Acquired or present (preformed) gaps in the different mesenteries are also considered as hernial portas for internal hernias (**mesenteric hernias**).

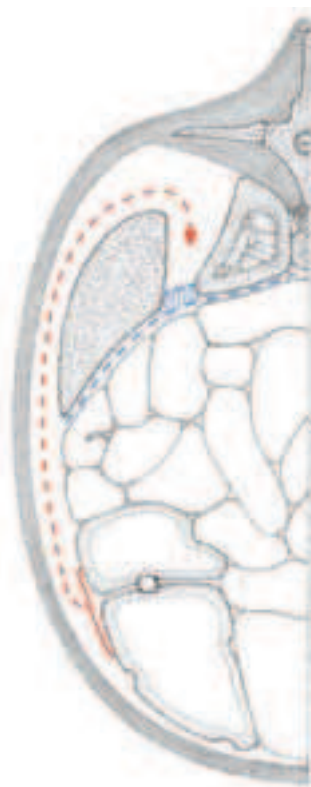

Fig. 68.2.1. Lienorenal ligament (nephrosplenic ligament). In the case of renosplenic entrapment (hernia of the lienorenal space), the left parts of the large colon are displaced into the lienorenal space (red arrow), which is bounded dorsally by the abdominal wall and ventrally by the lienorenal ligament (blue band between the laterally placed spleen and the medially placed left kidney).

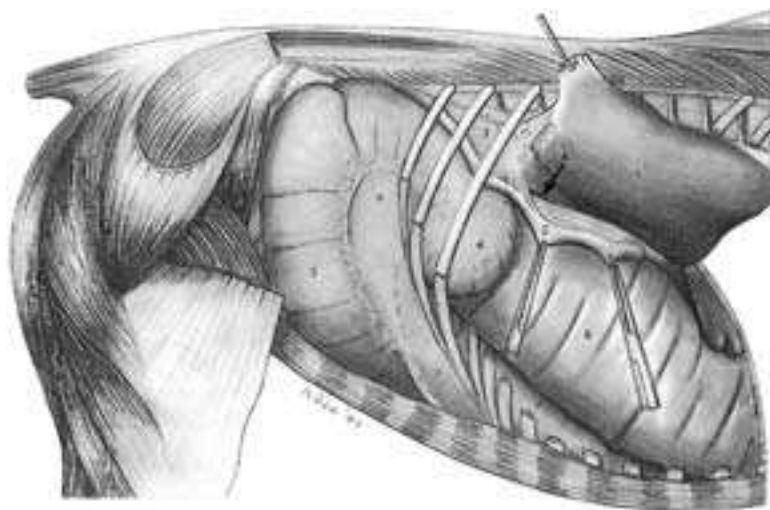


Fig. 68.2.2. Epiploic foramen (A), which can be seen by lifting the right lobe of the liver dorsally. It can function as a hernial porta for an internal hernia with incarceration of loops of small intestine. 1. right lobe of the liver, 2. descending duodenum, 3. right kidney, 4. base of the cecum, 5. body of the cecum, 6. collum coli (neck of the right ventral colon leading from the cecocolic ostium), 7. right ventral colon, 8. right dorsal colon.

In the case of **diaphragmatic hernias** portions of the small intestine reach through the diaphragm either in the preformed infracardiac bursa (SUSSDORF's space) up to the base of the heart or by a traumatically acquired hernial porta into the pleural cavity. In these cases severe dyspnea arises as the result of a pneumothorax. Also external hernias such as inguinal hernias (see 74.3.), umbilical hernias (see 64.2.), hernias of the abdominal wall (ventral hernia, see 64.3.) and hernia of the linea alba (see 76.2.) can trigger colic signs and are to be considered in the differential diagnosis.

Parts of the intestine with a narrow lumen and especially **transitional regions with a wide to narrow lumen** are a danger for obstipation by heavy, relatively dry intestinal content, which finally can result in an ileus (obstipation of the bowel). Additional dangers can arise by obturation in the presence of foreign bodies or enteroliths (intestinal calculi), predominantly made up of ammonium-magnesium-phosphate. Obturation can also come about by the presence of phytobezoars (undigested compacted vegetable fibers), the development of which is enhanced by dietary failures (e.g., after the regular feeding of bran to mill and bakery horses). Such bottlenecks are found at the pylorus, the *diverticulum caeci vitelli* (MECKEL's diverticulum) of the jejunum, the ileal ostium, the cecocolic ostium, at the pelvic flexure of the ascending colon and the transverse colon after the transition from the very wide lumen of the right dorsal colon (*ampulla coli*). Acquired narrowing of the lumen of the intestine (stenosis) develops, among other things, by edematization of the intestinal mucosa after lacerations (e.g., at parturition or improper rectal examinations) or disturbances in vascularization, including the formation of hematomas or by hypertrophy as well as

hyperplasia of the smooth muscle of the intestine with a permanently increased motility of the gut (e.g., increased peristalsis in front of a narrowing obstacle).

In the presence of extraordinarily increased gut motility, especially **long mesenteries** (*mesojejunum*, *mesocolon descendens*) can allow twisting of the mesentery (see jejunum, 70.4.). Also intestinal invaginations occur, especially at transitions from a freely movable intestinal part into one, which is more constant in position (e.g., intussusception of the end of the jejunum into the ileum). A long mesentery is favorable for veterinary activities in the diagnosis and surgery of colic. The long mesocolon descendens allows a far reaching rectal exploration (rectal palpation). At surgical operations, the affected part of the gut can be drawn out of the abdominal cavity. On the other hand, portions of the gut fused to the abdominal wall without mesentery formation are neither endangered by colic triggering displacements (ectopias) nor can they be completely displaced from the abdominal cavity.

Unattached wide-lumen portions of the gut like the left parts of the large colon and the body of the cecum with its apex can exhibit blockage as a result of torsion (twisting on the long axis),

The **blood supply** (see page 71) over very long distances (e.g., from the cranial mesenteric root to the pelvic flexure by the right colic artery and the colic branch) is interrupted by torsions. This is initially the case for the venous drainage and, after further increase of the tonus of the tissues, also for the arterial supply. The anastomoses that run transversely between the origins of the colic branch and the right colic artery are a protective mechanism, which is lacking distally at the pelvic flexure of the ascending colon. At the pelvic flexure, the named vessels (right colic artery and colic branch) pass over into one another in end-to-end anastomosis. Thrombus formations, which can be caused by parasitic larvae (*strongylus vulgaris*), result in an edematization of the intestinal wall. This brings about a narrowing of the gut lumen (stenosis) and finally to hemorrhagic necrosis (incarceration).

The **vegetative (autonomic) nervous system** regulates the motility of the intestine. Morphologically recognizable alterations can result in disturbances in motility. A failure to develop the neural myenteric plexus and submucosal plexus in the intestinal wall is one of these. Aneurysms (dilatations of blood vessels), which are caused by migrating larvae of strongylids, occur particularly often and distinctly at the origin of the cranial mesenteric artery. This can result in an irritation of the adjacent solar (celiacomesenteric) plexus and by this in motility disorders of the intestines. Autonomic irritations that are not associated with morphological change are also held responsible for colic diseases (e.g., changing weather, hypothermia or overexertion). We are dealing here with the comparatively mild course of the very frequent spastic colic with increase of tonus of the intestinal musculature, increased peristalsis and intestinal cramps, which ease after some hours or end immediately after the application of analgesics that relieve spasm. [459] [460] [461] [454] [462] [463] [464] [465] [466]

Gas colics (meteorism) arise with excessive gas formation, which results in an inflation of the gastrointestinal tract. Treatment is accomplished by probe with the nasogastric tube or trocarization, e.g., of the cecum.

In the last phase of pregnancy, **position-changes within the abdominal and pelvic cavities** brought about by the growing fetus or following parturition may cause a colic.

Iatrogenic—caused or forced by the veterinarian—colic signs can be brought about, for example, by improper rectal palpation (edema, hematoma).

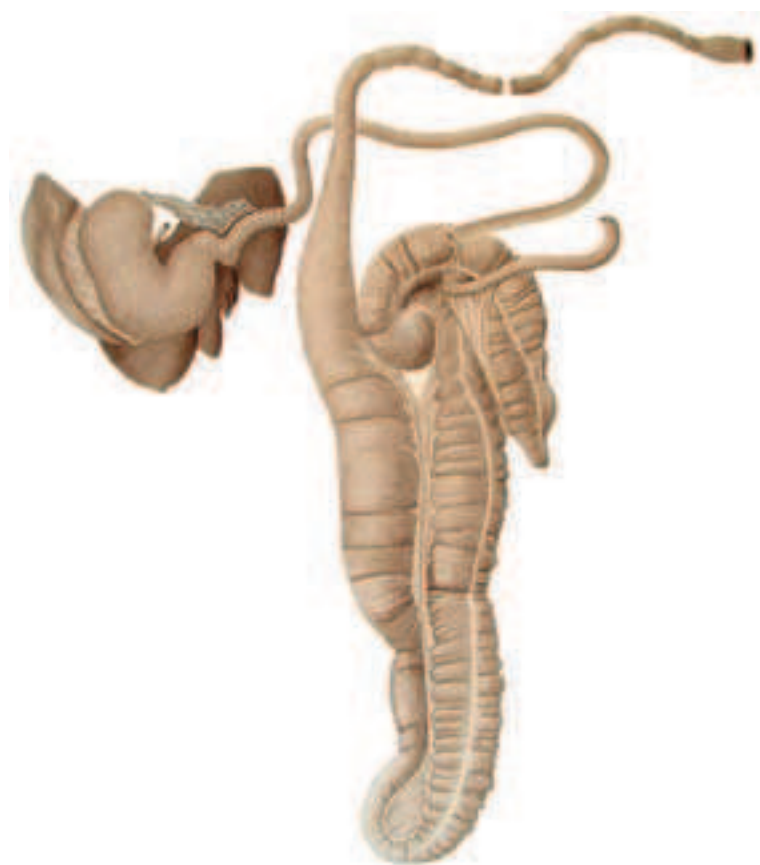

Fig. 68.3. Unfolding of the ascending colon (large colon) and displacement of the pelvic flexure to the left. Owing to the cecocolic fold, the body of the cecum with the apex is also displaced caudally and to the left. The entire jejunum was cut through at the end of the ascending duodenum and at the transition to the ileum and removed. The middle region of the descending colon was taken away. Changes in the width of the lumen are demonstrated at the transition from the stomach to the duodenum, at the opening of the ileum between the left side of the base of the cecum and the body of the cecum, at the pelvic flexure between the wide left ventral colon and the narrow left dorsal colon, and at the stomach-like dilatation of the right dorsal colon into the transverse colon. A very long band-like mesentery connects the dorsal and ventral layers of the (large) colon together and exhibits a distinct increase in width at the pelvic flexure. At different locations of the ascending colon, a torsion around the longitudinal axis can occur and from this results a torsion of the left ascending colon and also the sternal and diaphragmatic flexures or a total torsion of the entire ascending colon. The liver lies cranial to the stomach and the spleen to the left of the stomach. (Courtesy of Institut f. Veterinär-Anatomie, Berlin)

70.1. Structural predispositions to colic in individual portions of the intestine. In regard to fatal stomach ruptures, a **duodenal obstruction** (ileus) is much more dangerous the nearer it lies to the pylorus.

70.2. The descending duodenum has a topographical relationship to the base of the cecum. This has importance for the surgical intervention of gastro-duodeno-jejunitis, which recently is appearing more frequently. This disease, the etiology of which is still uncertain, results in a hindrance of passage in the entire region of the small intestine. Since, however, in the horse, the stomach and small intestine receive 70 liters of fluid daily (saliva, secretions) and these are resorbed mainly by the large intestine, the described hindrance of passage results inevitably in a reflux and thus an overload of the stomach. Only the repeated introduction of the nasogastric tube can

prevent a rupture of the stomach. On the other hand a continuous provision of fluid is necessary to protect the animal from exsiccosis. On the basis of the topographical relationship of descending duodenum and base of the cecum, HUSKAMP [467] performs a temporary duodenocecostomia in case of such a disease, thus establishing a connection between the descending duodenum and the head (base) of the cecum. By this means, the fluid (and the ingesta) no longer run back to the stomach, but over this connection into the cecum and by this into the fluid-resorbing large intestine. The special technique of the operation, which shall not be described here, leads to a spontaneous closure of the duodenocecostomia after the disease has faded away, so that the physiological flow of the ingesta is restored.

70.3. The **jejunum** exhibits an especially long mesentery and can because of its variable position be found in all possible regions of the abdominal cavity. The long mesentery of the jejunum facilitates torsions of the mesentery (volvulus with strangulation ileus). At the beginning and at the end of the jejunum the mesentery is shorter and for that reason not involved in the pathological torsions of the mesentery. [468]

70.4. Under certain pathological conditions with increased peristalsis, the **ileum** and the terminal (distal) part of the jejunum of the horse tend to intussuscept into the cecum. In this case, the mesentery of this portion of the intestine is forced to become involved. The vascular disturbance produced by these results after a short time in a life-threatening necrosis of the invaginated intestinal part. This kind of ileus is only to be eliminated by surgical intervention. HUSKAMP [469] connects the part of the intestine that is still intact with the right ventral colon as a jejunocolostomy and, after complete displacement into the cecum, leaves the necrotic invaginated part to self-digestion. This disease is predominantly observed in smaller horse-breeds.

70.5.1. In cases of digestive disturbances accompanied by gas production, the **cecum** can exhibit a tympany of the base of the cecum. In this case, the free, overhanging part of the base of the cecum, which is shaped so similar to a Jacobean cap, tips cranioventrally. By that the cecocolic ostium is displaced and spontaneous transportation of the gas prevented. Here, only puncture with a wide-lumen needle (trocar) can provide pressure-relief. [469] [470]

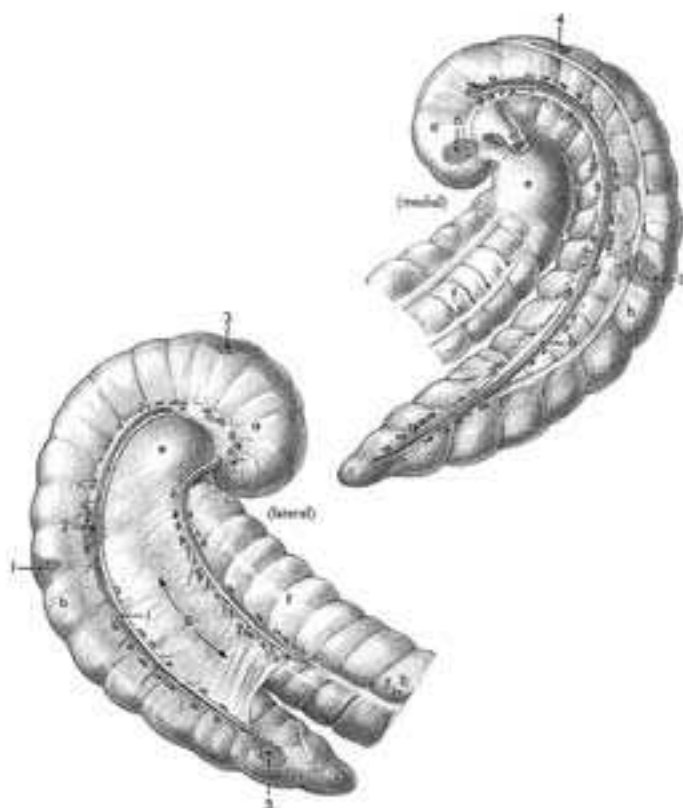


Fig. 70.5.4. Perforation-sites of the cecum in order of frequency of their occurrence (After Ross, 1985). 1. ventral body of the cecum, 2. lateral body of the cecum, 3. dorsal base of the cecum, 4. dorsomedial base of the cecum, 5. distolateral body of the cecum, 6. ventromedial base of the cecum. a. base of the cecum, b. body of the cecum, c. apex of the cecum, d. ileum, e. collum (neck) of the colon, f. right ventral colon, g. cecocolic fold, h. medial cecal a., v., and lymph nodes, i. lateral cecal a., v., and lymph nodes.

70.5.2. Typhlocolitis (colitis X) is an especially severe inflammation of the cecum and ascending colon, which is accompanied by colic signs (see textbooks of equine diseases).

70.5.3. Kinking of the relatively freely moveable body of the cecum with caudal displacement of the apex of the cecum occurs. This takes place at the junction of the body with the base of the cecum, which is firmly fused to the dorsal abdominal wall.

70.5.4. Obstipation of the cecum starts at the base of the cecum and can involve the overhanging free part of the base, by which finally, in an advanced stage of filling, the cecocolic ostium is closed. With this, the obstipation extends more and more onto the body of the cecum and finally to the tip of the cecum, in which case the danger of cecal rupture exists (sites of perforation: Fig. 70.5.4.).

70.6. The **ascending colon** is relatively and absolutely the heaviest part of the intestine of the horse, which owing to its insufficient fixation is subjected to pathological displacements. Only the initial part of the right ventral colon is stabilized by the base of the cecum and the right dorsal colon (*ampulla coli*) by the dorsal fixation of the transverse colon.

Thus, only the beginning and the end of the double horseshoe-formation of the ascending colon are indirectly or directly fixed. The portions of the ascending colon, which lie in-between are the more moveable the farther they are removed from the root of the mesentery and the longer the ligament-like mesentery between the two layers of the colon. Consequently, the longest mesentery and the greatest mobility lie at the pelvic flexure of the two left layers of the colon. A pathological torsion around the longitudinal axis can involve both left parts of the ascending colon and also the sternal and diaphragmatic flexures (*torsio coli ascendantis partialis*) or the entire ascending colon (*torsio coli ascendantis totalis*). In the latter case, the torsion is found between the fixation of the right ventral and right dorsal colon and the beginning of mobility at the beginning and end of the double horseshoe-formation. [471] [472]

70.7. The **descending colon**, which clinicians also misleadingly call the small colon, is subject to obstipation, torsion, and volvulus. If conservative treatment is of no avail, surgical intervention can also be successful here. [454] [473]

70.8. The **rectum** displays craniodorsally a predilection site for spontaneous ruptures, perforations and the formation of diverticuli. The anatomical basis for this rests on the special arrangement of the longitudinal muscle cell layers of the tunica muscularis. The 20–30 cm long rectum shows at its narrow place of transition from the descending colon a new formation of the longitudinal muscular layer of the tunica muscularis. The longitudinal muscle cell bundles, which initially run predominantly in two tenias, distribute at the beginning of the rectal ampulla around the entire circumference of the intestinal tube. Strong muscle cell bundles, which are directed dorsolateral to the caudal vertebral column, are formed immediately before the greatest circumference of the rectal ampulla, about at the level of the last sacral vertebra. They continue caudally as the

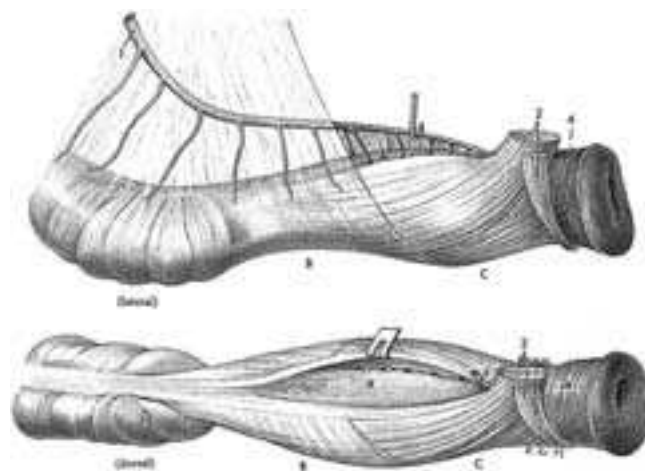


Fig. 70.8. Rectum with dorsal muscle-weak "deltoid" (A) and oval places of vessel penetration (figure below) in part intraperitoneal (B, clothed by peritoneum except at the attachment of the mesorectum), partly extraperitoneal (C, caudal to the sacrorectal pouch) in position. 1. cranial rectal a., 2. rectococcygeus muscle, 3. retractor penis muscle, 4. external anal sphincter muscle.

paired rectococcygeus muscles, which attach at the 4th caudal vertebra. Craniodorsally at the beginning of the rectum, where the dorsal (mesenteric) tenia is “lost”, a muscle-thin deltoid area of a length up to 20 cm is found in the area of reflection of the peritoneum from the sacrorectal pouch to the dorsal intestinal wall (see page 85, above g). The caudal triangular part of it lies extraperitoneally and the cranial trigonal beginning still intraperitoneally at the attachment of the mesorectum. Here the tunica muscularis is, with individual variation, about 1.5 mm, only half so thick as the rest of the rectal wall. In cases of extremely weak development with less than 1 mm thickness, spontaneous ruptures may, in rare cases, occur in the region of the muscle-thin deltoid and without any recognizable reason (increase of pressure after a strong pressing effort, at heavy work or in laying the animal down for surgical operation). Also in “unsuccessful mating” perforations may be caused by the stallion. With rectal examination, even with professional skill and without fault of the examining veterinarian a perforation of the muscle-thin deltoid of the rectum can result. In the case in which the perforation is outside of this predilection site, say in the lateral or ventral region with well-developed musculature, the perforation is usually caused by an improper rectal palpation (professional blunder—iatrogenic cause). [474]

Pelvis, Urogenital Organ

CHRISTINE AURICH, JÖRG AURICH, HARALD SIEME, K.-D. BUDRAS

72.1. Fractures of the pelvic bones are of traumatic origin and involve predominantly the iliac shaft (body of the ilium), wing of the ilium, tuber coxae, acetabulum, and the pelvic symphysis. For diagnosis, rectal palpation, among others, is indicated. [378] [475]

72.2. The sulcus for the accessory ligament of the femur (*sulcus lig. acc. ossis femoris*) is a species-specific characteristic of the equine pelvis. [389]

72.3. The neurovascular structures that run in the **obturator groove** (*sulcus obturatorius*), especially the obturator nerve, can be damaged by bruising in the course of a difficult parturition (dystocia). The resulting paralysis of the adductor muscles impairs the mother in standing. [378]

72.4. Pelvic diameter (Fig. 72.4.).

72.5. Comparison of sex-specific differences of the pelvis (Fig. 72.5.). [383]

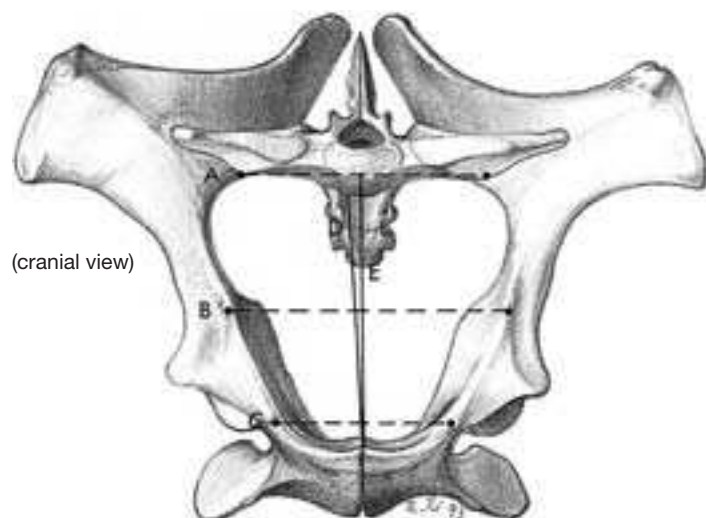


Fig. 72.4. Pelvic diameters with lines drawn between marked bony points at the level of the terminal line. A. dorsal transverse diameter between the two sacral wings, B. middle transverse diameter between the psoas minor tubercles, C. ventral transverse diameter between the two iliopubic eminences, D. vertical diameter between the cranial end of the pelvic symphysis and the vertebral column, E. conjugate diameter between the cranial end of the pelvic symphysis and the promontory of the sacrum.

72.6. The **broad sacrotuberous ligament**, under the influence of hormones, is increasingly saturated with fluid shortly before parturition and becomes then softer. Thus, besides loosening the joint capsule of the iliosacral joint, the birth canal enlarges. [476] [477] [478]

72.7. The **femoral ring** forms the hernial entrance of the rarely occurring **femoral hernia**, in which loops of small intestine are displaced into the femoral triangle. In this case, there is rupture of the transversalis fascia and the peritoneum which close off the femoral ring. The diagnosis is confirmed by palpation of the femoral triangle and by rectal examination. Treatment: reposition of the hernial content. Etiology: heavy pulling by the draft-horse. [479]

74.1. The **vaginal tunic** may be quite filled by serous fluid (**hydrocele** with resulting testicular atrophy) or by blood (**hematocele**). A hydrocele may also occur after castration, and in this case a part of the greater omentum is usually prolapsed through the vaginal ring into the vaginal tunic. Thus, an open communication remains in the vaginal ring between the vaginal tunic and the peritoneal cavity. For the stallion the occurrence of the hydrocele is described in association with seasonal effects, age, restrictive movement and exchange processes between the lumina of the vaginal tunic and the peritoneal cavity. Potency of mating and fertilization are usually not affected. [480] [378]

74.2. With different methods of castration, the **vaginal tunic** can either be opened (**castration with opening of the vaginal tunic** and section of the ligated spermatic cord) or **castration without opening the vaginal tunic** is performed, in which case the entire vaginal tunic with its content is severed after ligation. In case of **sterilization of the stallion** (preservation of libido and external attributes), the vaginal tunic is opened and the dissected tail of the epididymis severed after double ligation, one on the body of the epididymis and the other at the beginning of the spermatic cord. [481] [482] [483]

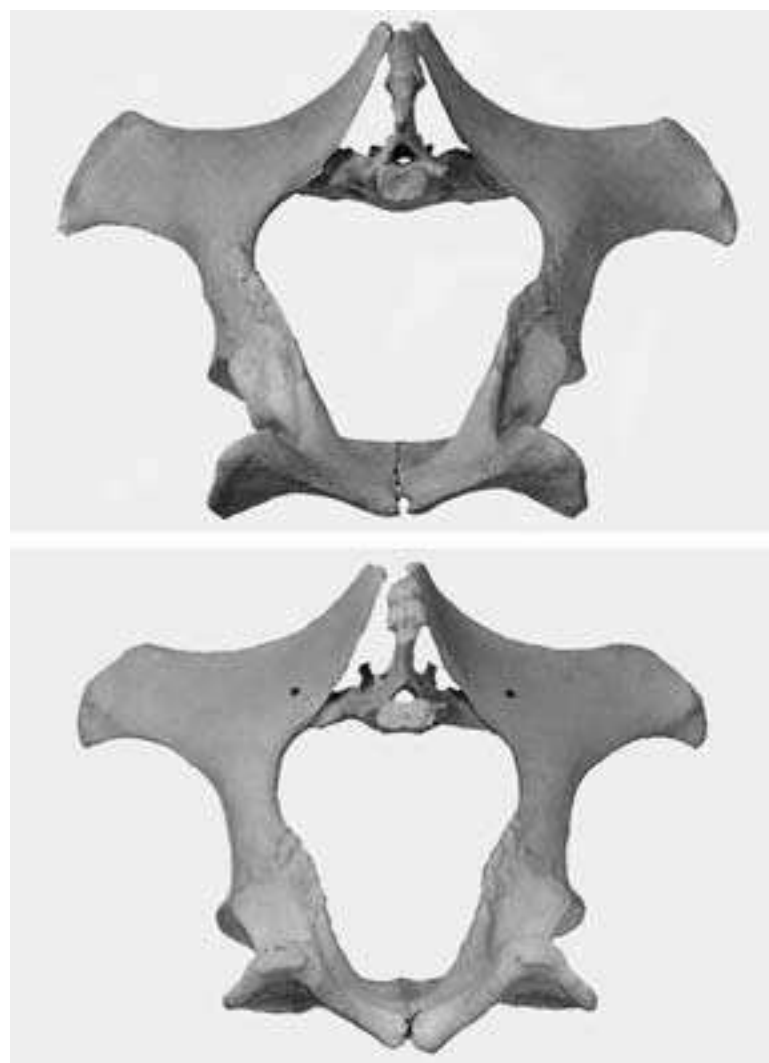

Fig. 72.5. Mare (above) and stallion (below). Caudal view.

74.3. In the clinic, **inguinal hernia** is subdivided according to the extension of the hernial content into an inguinal hernia (restricted to the region of the inguinal canal) or a scrotal hernia. Usually an **indirect inguinal hernia** is present, since the hernial content (loops of small intestine and/or parts of the greater omentum) enters through the **vaginal ring** (hernial entrance) into the **vaginal canal and cavity of the vaginal tunic** (hernial sac) and like the latter passes indirectly (on the long way) through the abdominal wall by way of the inguinal canal. A **direct inguinal hernia** occurs more rarely. In this case, tears appear beside the vaginal ring and the hernial content passes through the abdominal wall beside the vaginal tunic (on the short way). In the colt foal, **indirect inguinal hernia** is favored by a delayed testicular descent. In adult animals the hernial content is usually **incarcerated** and causes intensive colic signs. The diagnosis is confirmed by rectal examination. In inguinal hernia the two arms of an intestinal loop lie in the vaginal ring and the vaginal tunic. The part that enters the vaginal ring is filled by gas and the leaving part appears empty. About 6–10 hours after incarceration necrosis of the gut starts.

Therapeutic reposition of the hernial content is usually combined with a unilateral castration on the diseased side of the body.

In the **mare** an inguinal hernia seldom occurs. Predisposing might

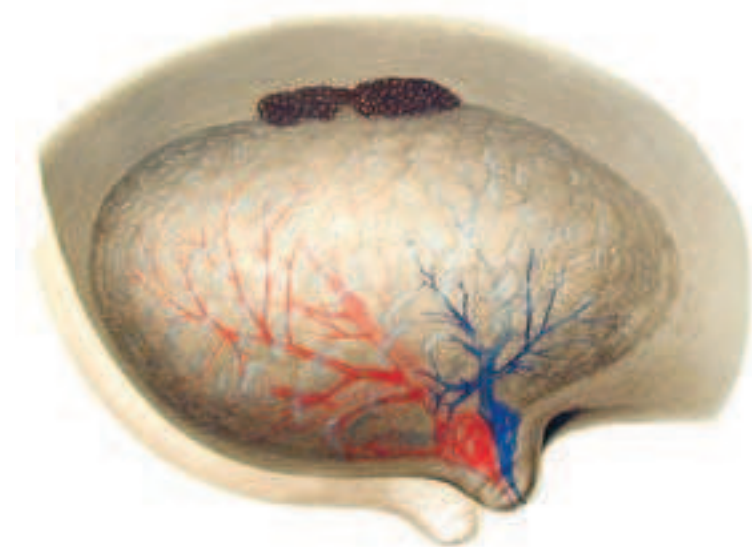


Fig. 76.3.1. Between the connective tissue boundaries of the lobules, the hemispherical udder of the young mare, reveals a yellowish-pink parenchyma. Usually two glands are present for each half of the udder. They can be distinguished by filling with artificially colored substances. At the base of the teat, the lactiferous sinus is subdivided into an upper, glandular, cistern and a lower, papillary, cistern, which passes over into the narrow papillary duct ("streak canal"). (Courtesy of Institut f. Veterinär-Anatomie, Berlin)

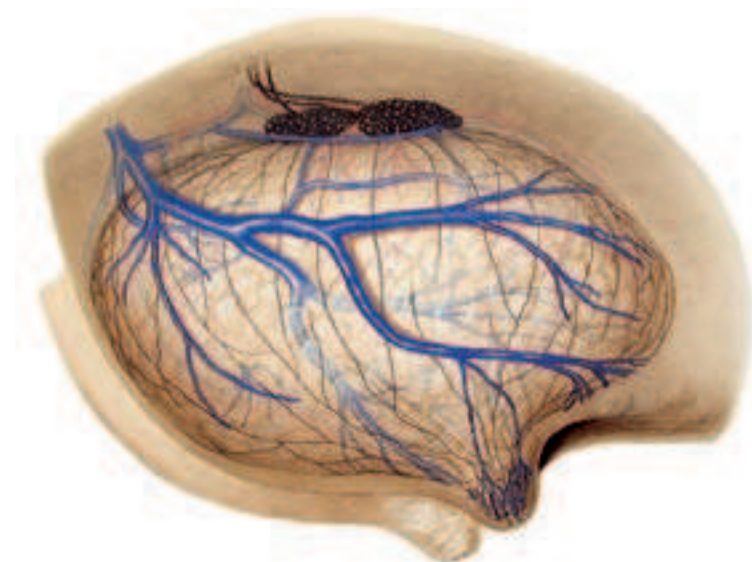

Fig. 76.3.2. The vessels extend in the gland parenchyma predominantly superficially (veins and lymph vessels) or deeply (arteries). Venous drainage is for the most part caudal in its course of direction and the lymph vessels (drawn dark brown) are directed approximately perpendicularly to the lymph nodes of the udder (superficial inguinal lymph nodes or mammary lymph nodes). For the nomenclature of the blood vessels, see p. 80. (Courtesy of Institut f. Veterinär-Anatomie, Berlin)

be an occasionally occurring (insignificant) vaginal ring and the indication of a vaginal process. [484]

76.1. The **prepubic tendon** strengthens the mechanical bond at the pelvic symphysis. A traumatically conditioned rupture of the prepubic tendon can lead to a separation of the pelvic halves at the pelvic symphysis. The prepubic tendon is rectally palpable and its lateral end marks the medial angle of both inguinal rings (internal (deep) and external (superficial) inguinal ring). [485] [486]

76.2. Rarely, a **hernia of the linea alba** occurs cranial to the umbilicus. [378]

76.3. The **development of the udder** prior to birth (mammogenesis) is realized under the influence of the estrogens and gestagens that are produced within the placenta. The onset of lactation is linked to an increased secretion of prolactin from the anterior lobe of the hypophysis. The physiological daily production of milk in large horses is between 15 and 20 liters. The clinically relevant diseases of the udder are disorders of milk production, inflammatory changes, neoplasias and mammary edema of a higher degree. In the horse, diseases of the udder can appear in each stage of reproduction. In 50% of the cases of mastitis, only one half of the udder (or only one of the two mammary complexes of the half of the udder) is affected. The proven infectious microorganisms in equine mastitis are environmental germs that are common to the environment of the animal. This lets appear probable a galactogenic infection in many cases. Inflammation of the udder usually takes its course as a catarrhal mastitis with preservation of the milk character, occasionally also as a phlegmonous mastitis. The swelling, which starts from the udder, extends to the premammary region; a swelling of the pelvic limbs is also partly present. Blood and lymph vessels in the premammary region as well as between the thighs may be congested and enlarged. In its further course, the development of abscesses and connective tissue induration of the udder may occur. Botryomycosis, which occurs nowadays only rarely, is a granulomatous inflammation caused by staphylococcus aureus. The granulomas, which develop over several months, result in a considerable increase in size of the udder. A high degree of udder edema in the mare is not rarely a problem immediately post partum. Owing to the enlargement of udder and teats and the substantial tension of the mammary skin, the udder is painful. Especially mares giving birth for the first time then reject more or less violently the foal when it tries to suck.

78.1. An **acute renal failure** occurs as a consequence of colic diseases and is caused by a destruction in the nephron, chiefly in the proximal tubule. Hemodynamic causes, predominantly a drop-off in blood pressure in combination with hypovolemia and endotoxins leads to a "shock kidney." In colic, because of the water loss due to extreme sweating and/or diarrhea, there is a reduction of the circulating amount of blood. The reduced supply of oxygen (hypoxemia), which accompanies this, destroys predominantly the proximal tubule, which in contrast to other sections of the tubule is unable to generate anaerobic energy. Shortage of energy and

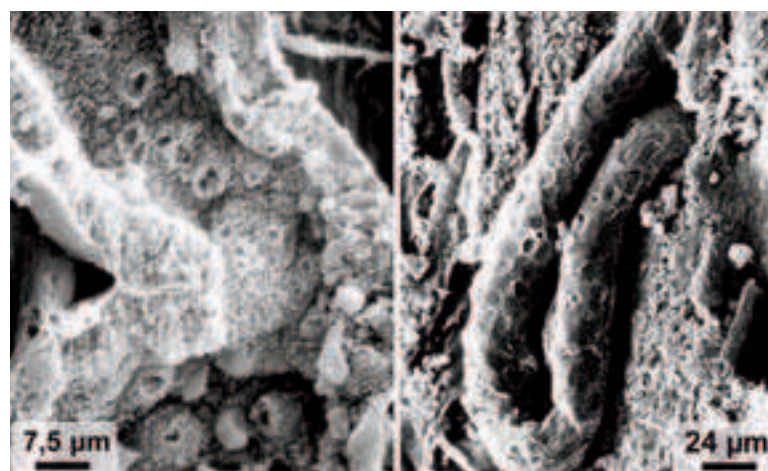


Fig. 78.1. Scanning electron micrograph of the kidney. Proximal tubule from the nephron of a horse with colic with acute renal failure. Left: longitudinally sectioned tubule. The microvilli fuse to drop-shaped swellings with an apically open crater. Right: lumen-plugging cylinder from the cell detritus.

changes in calcium metabolism are considered as causes for the breakdown of the cytoskeleton and especially the “terminal web”, which with its filaments extends into the microvilli of the brush-border epithelial cells of the proximal tubule. The destruction of the “terminal web” causes the fusion of the microvilli to drop-like cytoplasmic projections into the lumen of the tubule (Fig. 78.1, left). The rupture of these drop-like projections results in a massive release of enzymes (gamma glutamyl transferase, γ GT), which are measured in their proportion to creatinine in the urine for diagnostic purposes. The destruction of the “terminal web” accompanies the breakaway of cells from the epithelial cell association of the proximal tubule. The cell detritus that arises forms into cylinders that obstruct the lumen (Fig. 78.1, right). This chiefly leads to mechanical closure of the following distal tubule and by this to functional loss of the entire nephron. The elevated γ GT-creatinine content correlates with the degree of dehydration (reduction of body fluid) in colicky horses with renal disease. For that reason, it is considered a sensitive indicator for destruction of the epithelium of the proximal tubule. [525]

78.2. The **mucous glands** of the **renal pelvis** and the **initial part of the ureter**, by their secretion, lend to the urine a mucous, perhaps even a sticky consistency. The normally sulphur-yellow and cloudy appearing urine can assume rather a brown color if there is a high bilirubin and phenol content and even a black-brown color if there is a myoglobinuria. [487]

78.3. The **urethra** of the mare is so short, of wide lumen and stretchable that, on the one hand, prolapse of the urinary bladder into the vaginal vestibule is possible; and, on the other hand, removal of urinary calculi by the veterinarian is possible. In male animals for the removal of urinary calculi from the urinary bladder and urethra, the long and narrow-lumened ischiadic portion of the urethra is opened surgically by a longitudinal incision. Epidural anesthesia or a local block of the pudendal nerve is performed.

80.1. The **abdominal aorta** and/or the **external iliac artery** of one or both sides of the body can be more or less completely closed by thrombi. The disease starts from endothelial damage, which can be caused by parasitic larvae of *strongylus vulgaris*. The consequences of thrombus formation are disturbances in blood flow in the concerned region of supply and lameness, especially after extended activity. In the case of unilateral disease the more poorly supplied diseased limb is cooler to the touch than the healthy pelvic limb. The pulsation, which is taken in the femoral triangle, and realized by rectal palpation, is more or less reduced in dependence on the size of the thrombus. If the disease is unilateral, then a comparison with the healthy side demonstrates it distinctly. The veins on the healthy side of the body are well vascularized and, on the diseased extremity, more or less collapsed.

82.1. At the beginning of pregnancy, the **ovary** demonstrates **follicle maturation** and **ovulation**. Follicle formation and maturation can be monitored by rectal palpation and ultrasound. A corpus luteum, however, is palpable only in the first 4 days following ovulation. The size of the ovary is variable and depends on the phase of the estrous cycle. A few days after ovulation, the ovary is relatively small. With the beginning of growth of a follicle-wave in the corpus luteum-phase numerous follicles with a diameter of about 0.5–1 cm are found. Under the influence of FSH (follicle stimulating hormone) these continue to grow up to a size of 2 cm diameter. With the beginning of heat, a dominant follicle is selected from the follicles of a follicle wave. This follicle grows to pre-ovulatory size of at least 4 cm, in exceptional cases, however, even to one of 6–7 cm in diameter; whereas, the other follicles involute. The fresh **corpus luteum**, which develops from follicular cells following ovulation, has a diameter of 3–4 cm. The size of the follicle determines that it extends beyond the region of the ovulation fossa. That is also valid for the fresh corpus luteum, which reduces in size with increasing maturation and “retracts” from the ovulation fossa.

During pregnancy, besides the *corpus luteum graviditatis*, numerous **accessory corpora lutea** form in the ovary under the influence of ECG (equine chorionic gonadotropin, formerly PMSG: pregnant mare serum gonadotropin). This takes place between the 37th and 120th day of pregnancy by follicle maturation and ovulation. After this, the production of pregnancy-preserving gestagens is taken over by the placenta. The ovaries are to a large extent atrophic. Already immediately after parturition they resume again their functions. Within 5–15 days the “foal-heat” (post-partum heat) occurs.

The **gonads** (ovaries as well as the testicles) of the fetus undergo a remarkable growth during pregnancy. About day 60 of pregnancy, when (owing to the formation of accessory corpora lutea under the influence of ECG) the ovaries of the mare reach their maximum size, the fetal gonads weigh less than 1 gm. However, between day 100 and 200, there is a strong growth of the fetal gonad. With a weight of about 70 gram their size exceeds in the 7th–8th month of pregnancy the size of the maternal ovaries, which at this time are without function. The increase in girth of the fetal gonads is brought about by a massive proliferation and hypertrophy of the medullary interstitial cells. The cortex on the contrary stays behind in its growth, so that the medulla is only partially covered by the cortex. After day 250 of pregnancy, the size of the fetal gonads decreases again so that at the time of birth they have a weight of 10–20 gram. The interstitial cells of the fetal gonads, which are identical in the male and female fetus, synthesize steroid hormones, which are metabolized to gestagens and estrogens by the placenta (fetoplacental unit). Placental gestagens are synthesized from day 80 of pregnancy and from day 140 are alone responsible for the maintenance of pregnancy. Placental estrogens can be employed for pregnancy diagnosis from the 120th day, but the diagnosis of pregnancy per rectum with the aid of ultrasound technique is applicable

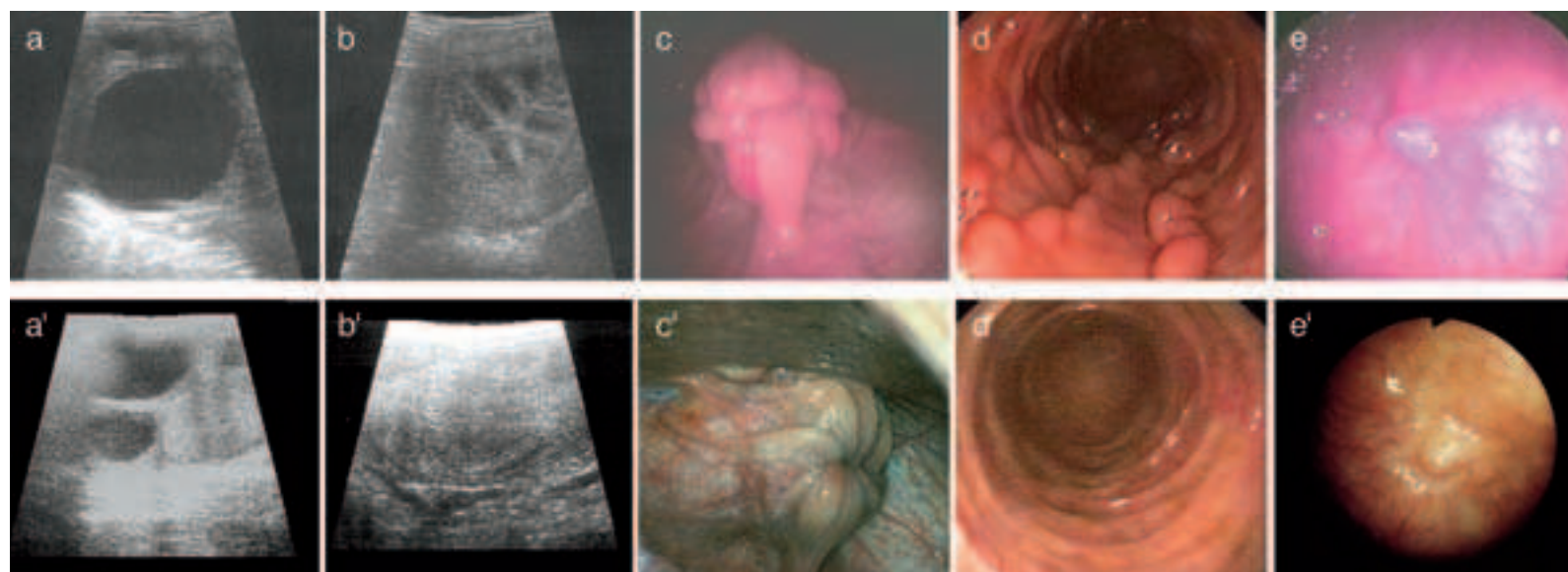


Fig. 82.1. Demonstration of the cyclic-dependent functional condition of the genitalia of the mare.

(a: sonographic cross-section of the ovary with dominant follicle during estrus, a': sonographic cross-section of the ovary with corpus luteum on the 8th day during diestrus); (b: typical “wheel-spoke structure” of the uterus in estrus, b': homogeneous ultrasound texture of a cross-section of the uterus in diestrus); (c: view of the *portio vaginalis uteri* of an estrous and c' of a diestrous mare); (d: hysteroscopic photo of the uterus [insufflated with gas] of an estrous mare and d' of a diestrous mare); (e: hysteroscopic demonstration of the uterotubal papilla (*papilla uterina*) of an estrous and e' of a diestrous mare). (Photos, Prof. Dr. Sieme, Hannover)

essentially earlier, is more reliable, and speaks out more strongly. [488] [489] [490] [491]

82.2. The **uterine tube** lies lateral to the ovary and—different from the bitch—does not course in an arch. In the mare, the caudal part of the isthmus of the uterine tube functions also as a reservoir for sperm. The site of fertilization is the ampulla of the uterine tube. Only on day 5–6 does the embryo arrive in the uterus in the morula stage. Conventionally, the semen—in the manner of a natural mating—is transferred into the uterine body. However, it is also possible, by rectal or sonographically conducted deep intracornual insemination, to deposit the semen ipsilateral to the side of the dominant mature follicle, nearer in the direction of the uterotubal connection. The aim of the deep intrauterine deposit of semen is primarily to obtain fertilization with a distinctly lower dose of sperm cells than usual. [492] [493]

82.3. The **uterus** is so much altered from the 16th–8th day after conception, that its rectal palpation permits a pregnancy diagnosis. The uterine wall exhibits an increased tonus and one uterine horn has a fluctuating vesicle-like enlargement. With the aid of sonography, the diagnosis of twin pregnancy in the early phase of pregnancy is important. Predominantly, twin-pregnancy is reduced spontaneously to a single pregnancy. Nevertheless, early veterinary intervention is afforded, because twin-pregnancies maintained to the end of pregnancy result almost always in abortion. Besides rectal palpation and vaginoscopic examination of the internal genital organs of the mare, sonography and hysteroscopy are of high diagnostic value in the framework of the gynecological examination of breeding mares. [494] [495] [496] [380]

Of the domestic animals, the horse exhibits the greatest **variability in the duration of pregnancy**. The physiological duration of pregnancy is between 320 and 360 days. **Parturition** begins with a passive opening of the cervix. After that is the active phase of parturition with the commencement of contractions. Mares can influence considerably the beginning of the active phase of parturition. Birth begins only when the environment is recognized as safe, so that more than 90% of foals are born at night. With the beginning of contractions, the fetus in its fetal membranes is pushed into the birth canal. With this, with regard for the foal, the birth canal becomes slowly widened. About two hours after the opening stage, the allantois usually ruptures first, followed by the amnion. With rupture of the fetal membranes, the expulsive phase starts. It lasts 5–10 minutes. The expansion of the cervix by the fetus triggers reflexly an increased secretion of the hormone **oxytocin**, which stimulates contractions (Ferguson reflex). In addition, stretch receptors in the roof of the vagina give rise to a neural stimulation of contractions and the abdominal press. Disturbances appear in about 4% of all equine births. Causes of dystocias are predominantly anomalies of posture, position and presentation. Equine parturitions are always emergency cases, which require immediate intervention, since within a short time it can lead to the death of the fetus; however, also to injuries to the mare.

Physiologically, foals are **anterior presentation (thoracic limbs forward with extended head and neck resting on the limbs), sacrodorsal position (the back dorsal), and in extended posture**. For obstetrical procedures, whether the fetus is alive or dead is of decisive importance. Signs of life are the retraction of the limb after

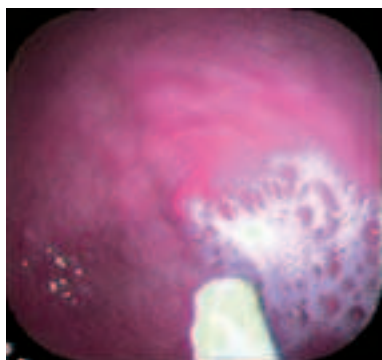


Fig. 82.2. Hysteroscopic demonstration of the uterotubal papilla (papilla uterina) ipsilateral to the preovulatory follicle of a mare in estrus. Adhesion of a small volume of inseminate at the uterotubal papilla (papilla uterina) with vesicle formation. (Photo, Dr. Sieme, Hannover)

pressure on the coronet, movement of the head after pressure on the eyeball, swallowing reflex and suction reflex as well as the anal reflex. With the foal in breech presentation (hind limbs first and directed caudally) it succeeds in part to reach the umbilical cord. A positive umbilical pulsation shows that the foal is alive. In doubtful cases demonstration of the heartbeat of the foal by ultrasound can be attempted.

Obstetrical measures are the correction of a faulty presentation, posture, or position, extraction of the fetus, fetotomy and cesarean section. Owing to the long limbs of the fetus the horse is predisposed to anomalies in posture. Because of the bending of its back and the form of the maternal pelvis, foals can only be born in a position in which the back is dorsal (sacrodorsal position). A dorsopubic position (back in ventral position) or dorsoiliac position (back in lateral position) must for this reason be corrected to a dorsal, (sacrodorsal) position. The most frequent anomaly in presentation is the breech presentation. This cannot be corrected and the foal must be born by careful extraction; where appropriate, by cesarean section. Transverse presentations represent rare and complicated obstetrical obstacles. In the case of bicornual pregnancy and transverse presentation, the thoracic limbs and the head of the foal are

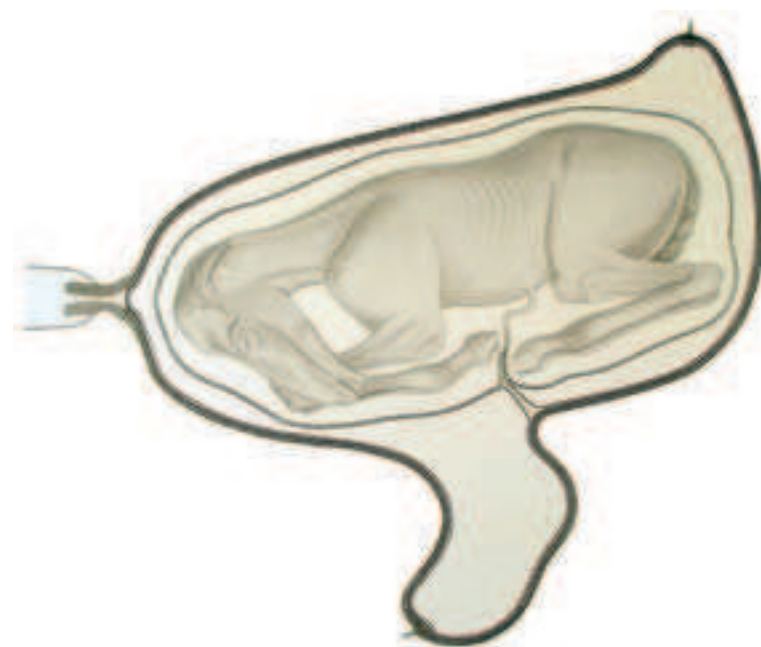

Fig. 82.3.1. A fetus from the last third of pregnancy is in the body of the uterus and the right uterine horn. In its immediate environment, it is surrounded by the amniotic vesicle and farther removed from the allantoic vesicle, which reaches into the left uterine horn. To the left, the cervical canal is loosely closed and projects into the vagina with the portio vaginalis cervicis (uteri). (Courtesy of Institut f. Veterinär-Anatomie, Berlin)

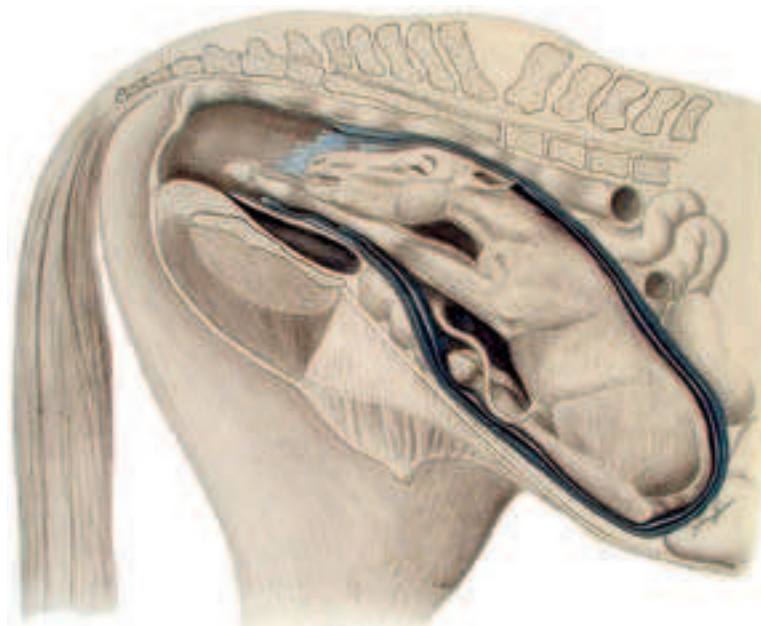


Fig. 82.3.2. At the expulsion phase of parturition, the mature fetus is in the birth canal in dorsal (normal) anterior presentation and, with that, the fetal membranes are already ruptured. (Courtesy of Institut f. Veterinär-Anatomie, Berlin)

found in one uterine horn, the pelvic limbs in the other. Bicornual pregnancy with transverse presentation of the foal is always an indication for a cesarean section.

In the last third of pregnancy as also during parturition a **uterine torsion** may occur. The diagnosis is established chiefly by the findings on rectal palpation. The most striking finding is a displacement of the broad ligaments of the uterus. The ligament on the side of the direction of the torsion runs vertically and is displaced caudally; the opposite ligament runs horizontally or obliquely. In the region of the site of the torsion a distinct constriction is palpable. Because the thin-walled veins are pinched off first, but the thick-walled arteries remain passable, in cases of a high degree of torsion there is hemorrhagic infarction with damage to the uterine wall.

Before parturition as also during parturition **rupture of the uterus** may occur. If a rupture before parturition is very large, the fetus can be displaced into the abdominal cavity. There it dies in a few days because of involution of the uterus and separation of the placenta. Ruptures of intra-abdominal blood vessels and hemorrhage into the abdominal cavity or into the broad ligaments of the uterus because of ruptures of the uterine artery, of the uterine branch or the external iliac artery are supposed to be responsible for up to 40% of all peripartum deaths in mares. Ruptures of vessels occur mostly during parturition but may occur also before birth, especially in older mares. Predisposing are changes within the wall of the arteries supplying the uterus in older mares (degenerative changes of the internal elastic membrane, fibrosis of the intima, accumulation of mucoid materials in the intima and media). [497] [498] [499]

82.4. The **cervix uteri** is about 5–7 cm long and so closed off by longitudinal folds, however without transverse folds, that it can be easily opened manually or with instruments. During estrus, the cervix is open wide and relaxed. The stallion enlarges this with the strongly erect glans penis and deposits the ejaculate directly into the uterus (uterine insemination). The looser closure signifies during pregnancy a latent danger for an abortion or for ascending infection. Scar formations due to parturitions or breeding injuries can however be the cause for narrowing of the lumen or for abnormal enlargement of the lumen. [391] [500]

82.5. **Vagina and vaginal vestibule** form functional-anatomically the first important barrier against ascending infections in the mare. Position and closure of the vulva are influenced by the duration of use for breeding (number of foalings). Normal closure of the vulva can be restored by proper surgical-plastic procedures. The vagina can exhibit perforations with opening into the peritoneal cavity dorsal or lateral to the *portio vaginalis uteri* in the dorsal vaginal fornix. These may be caused by a too vehement intromission of the penis or by oblique mounting. [501] [378] [487]

82.6. The **hymen** in its persistence may cause, in the extreme case, a closure of the vagina. By accumulation of secretion in the uterus and vagina the hymen may project balloon-like into the vulva. [378] [502]

82.7. The **vulvar cleft** (*rima pudendi*) may have a deficient closure because of former injuries in dystocia or because of a strong reduction of the perivaginal fat tissue, which occurs regularly in older thoroughbred mares. This leads to the development of a pneumovagina with a following pneumometra and chronic endometritis, which leads to sterility. [503] [380]

82.8. The **clitoris** is visible during estrus in the process of “winking.” The clitoris is erected by contraction of parts of the bulbospongiosus (constrictor vulvae, constrictor vestibuli) muscle, and is exposed after widening of the labia of the vulva (signs of estrus). [439] [504]

84.1. The **testicle** may be concealed in incomplete **testicular descent** unilaterally or bilaterally. It may remain in the abdomen (**abdominal cryptorchidism**) or in the inguinal canal (**inguinal cryptorchidism**). Affected animals are called cryptorchid colts.

The descending testicle is connected caudally to the **gubernaculum testis** (mesenchymal condensation). The gubernaculum extends through the inguinal canal to the bottom of the vaginal process, which has arrived previously into the scrotum. At certain times and certain locations the gubernaculum testis exhibits an **increase in vol-**

ume, which widens the inguinal canal for the passing testicle. In this stage of testicular descent, the gubernaculum testis has such a considerable increase in its volume that it is difficult to distinguish it from the testicle by palpation. With subsequent **regression** of the gubernaculum testis, which results in a shrinkage, testicular descent is irreversibly completed. The considerable susceptibility for disturbances of this complicated procedure is expressed in cryptorchidism. In the colt fetus and colt foal, perhaps, the (comparatively) enormous size of the testicle is an additional disruptive element. The increase in volume is based on the proliferation of the testicular interstitial cells, which is most distinct in the 7th and 8th months of pregnancy (testicular weight up to 70 gm). At the time of passage through the inguinal canal, which takes place at the time of parturition, the size of the testicle is normally so far reduced that testicular descent can take place. A causal connection to cryptorchidism does not exist. It is not possible to induce descent of the testicle by hormonal treatments of cryptorchids with HCG (human chorionic gonadotropin) or GnRH (gonadotropin releasing hormone), because these substances result in growth of the testicle and by that make descent more difficult. In case of bilateral cryptorchidism, infertility occurs because spermatogenesis is blocked at the temperatures that are found in the abdominal cavity. Fertile sperm cannot be produced. To be sure, the function of the LEYDIG’s interstitial cells is only influenced to a slight degree, so that cryptorchids almost always show stallion-like behavior. The expression of stallion-like behavior is however individually variable. The presence of abdominal testicular tissue can be established by the demonstration of androgens in blood or urine. In unilateral cryptorchidism fertility is maintained. Such stallions should, however, not be used for breeding because a genetic predisposition is present. Abdominal testicles are smaller and have a slack consistency (compare to a small mercury bag). They tend increasingly to tumorous degeneration.

Transcrotal sonography is a suitable aid in the imaging diagnostic of testicular structures, especially in the demarcation of tumorous processes. In the framework of fertility diagnostics, the testicular biopsy gives valuable clues. Testicular biopsy is performed either on the standing, sedated, stallion or on the anesthetized stallion. Puncture of the cranio-lateral region of the testicle is carried out with an automatized needle that penetrates the testicular coverings. [505] [506] [507] [508] [509] [510] [511] [383] [512]

84.2. The **testicular vein**, which forms the pampiniform plexus by its extreme tortuosity proximal to the head of the epididymis, can exhibit diseased enlargements, which bring about varicoceles and can lead to sterility. Vascularization of the testicle can be examined and evaluated by doppler sonography in the region of the pampiniform plexus. [513] [386] [514]

84.3. The **tail of the epididymis**, which is fixed to the bottom of the vaginal tunic by way of the *ligamentum caudae epididymidis* and by the proper ligament of the testis to the corresponding testicular pole, is cut off in sterilization of the stallion. Sperm from the tail of the epididymis of the stallion are fertile, so that a reserve of frozen semen is possible from sperm of the tail of the epididymis obtained immediately after castration. [515] [408]

84.4. For sterilization (vasoresection or vasectomy) the deferent duct can be resected about a length of 2–3 cm. It can be found on the medial aspect of the spermatic cord after opening the vaginal tunic. [484] [516]

84.5. The stallion has a complete set of **accessory genital glands**, concerning which, besides the bilobar prostate, the ampulla of the deferent duct, the seminal vesicle and the bulbourethral gland are each paired. The excretory ducts of the seminal vesicles and the ampullae of the deferent ducts open together (ejaculatory duct) on the dorsal surface of the proximal urethra, the so-called seminal colliculus. This can be demonstrated endoscopically and a catheterization of the ejaculatory duct is possible for diagnostic-therapeutic purposes.

Functionally the secretions of the accessory sex glands contribute to the composition of the ejaculate. For this, the bulbourethral gland, together with the urethral glands, contributes the watery, clear, sodium chloride-containing fore-secretion, which serves pre-ejaculatory neutralization and moistening of the male urethra as well as of the vagina. The main fraction of the ejaculate is rich in

sperm and essentially composed of the secretions of the testicle, tail of the epididymis, the deferent duct and the ampulla of the deferent duct. The secretion of the tail of the epididymis, which is rich in sperm, contains great amounts of glyceryl-phosphorylcholine. The spindle-shaped thickened terminal parts of the deferent ducts (ampullae of the deferent ducts) produce besides ergothionin, citrate and fructose-specific proteins, which play a role in the maturation of the sperm and the process of fertilization. The alkaline secretion of the seminal vesicle, which is rich in citrate and variable in consistency and quantity, forms the gel-fraction of the ejaculate and contains different proteins, which function as decapacitation factors of the sperm. The prostate gland furnishes a watery secretion that is rich in electrolytes. It consists only of the body (right and left lobes connected by an isthmus); a disseminate part is absent in the horse.

In azoospermia ejaculates, determination of the alkaline phosphatase may be helpful for the differentiation of a testicular or post-testicular cause of the condition (absence of mature sperm).

Only the ampullae of the deferent ducts and the deferent ducts are palpable per rectum. The prostate is extensively, and the bulbourethral gland is entirely, covered by musculature and accordingly, in the physiological condition, not directly palpable. Sonography is the means of choice for examination of the accessory sex glands.

In the clinical context, seminal vesiculitis is in the forefront. It frequently appears to persist and leads to losses of fertility. After diagnosis of an infectious cause, which stands always in the foreground, besides the prohibition of mating, specific antibiotics is as a rule successful. In case of a chronic apostematous course, seminal vesiculectomy with perineal access is indicated. [517] [518] [519] [520]

84.6. At the preputial ostium, the **prepuce** can exhibit an inherited or acquired narrowing (**phimosis**). (Phimosis: gr. = to close, to narrow, narrowness) A **paraphimosis** is caused by a narrowness of the preputial ring (anulus) of the preputial fold (internal lamina of the prepuce). The penis, which has protruded from the preputial ostium, can no longer glide back through the preputial ring and responds with development of edema. [383]

84.7. In the case of **paralysis of the penis**, the penis is permanently prolapsed (**prolapsus penis**). By this the penis is endangered by contusions and other injuries as well as by edema and phlegmon. An erection of the flaccid penis is not possible. Attempts to reposition the penis are usually unsuccessful. **Paralysis of the smooth musculature** of the walls of the cavernous spaces as well as of the trabec-

ulae of the erectile body is considered to be the cause, which is triggered by a decrease in the sympathetic tonus.

A loss of function of the sympathetic component of the **pudendal nerve** triggers the disease. Prolapse of the penis can be induced ex by application of tranquilizers, not however by resection of the retractor penis muscle. [439] [521] [perimentally by neurectomy of the pudendal nerve, blockade of sympathetic axons and 522]

84.8. For **anesthesia of the penis**, the **pudendal nerve** can be blocked. [523]

84.9. In the case of chronically obstructing urine concretions, the **urethra** of the male horse can be opened by a permanent fistula surgically-installed in its proximal penile part (in the region of the perineum). In this way, urine drainage free of disturbances can be guaranteed. With this operation, there are always seeping hemorrhages from the veins, because in every case the erectile body of the urethra is injured. [524]

84.10. The **glans penis** is distinctly enlarged in erection owing to its remarkably large cavernous spaces. The **urethral process** protrudes distinctly. The taking of swab samples is done on the protruded penis between the preputial laminae on the shaft of the penis, the fossa glandis and from the urethra. These are locations where smegma is normally found and which are naturally colonized by microorganisms. A cleaning with detergents is not recommended, since the natural germ flora would be changed. To demonstrate pathogenic microorganisms, a swab for culture and subsequent investigation is carried out, especially in view of CEM (contagious equine metritis). (Also in the mare, corresponding swabs for culture are taken from the clitoral fossa and the vaginal vestibule.) [386]

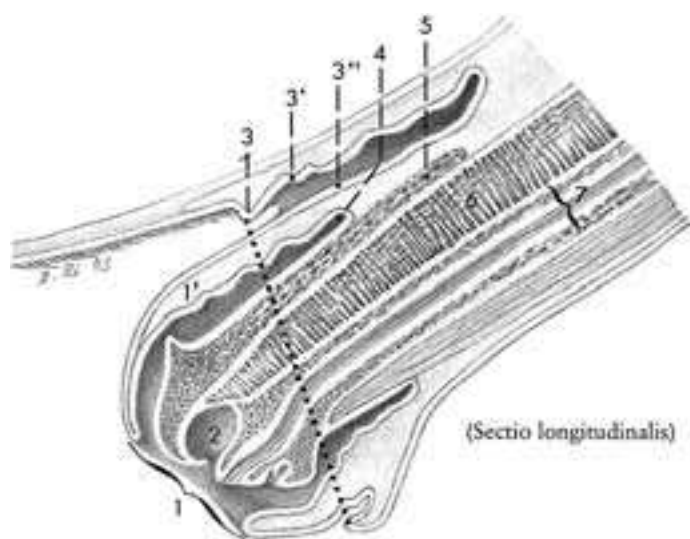


Fig. 84.6. Longitudinal section through the prepuce and the end of the penis. 1. preputial ring with preputial fold (1'), 2. urethral sinus, 3. preputial ostium with external lamina (3') and internal lamina (3''), 4. preputial fundus, 5. corpus spongiosum glandis with proc. dorsalis glandis, 6. corpus cavernosum penis, 7. urethra with surrounding corpus spongiosum penis.

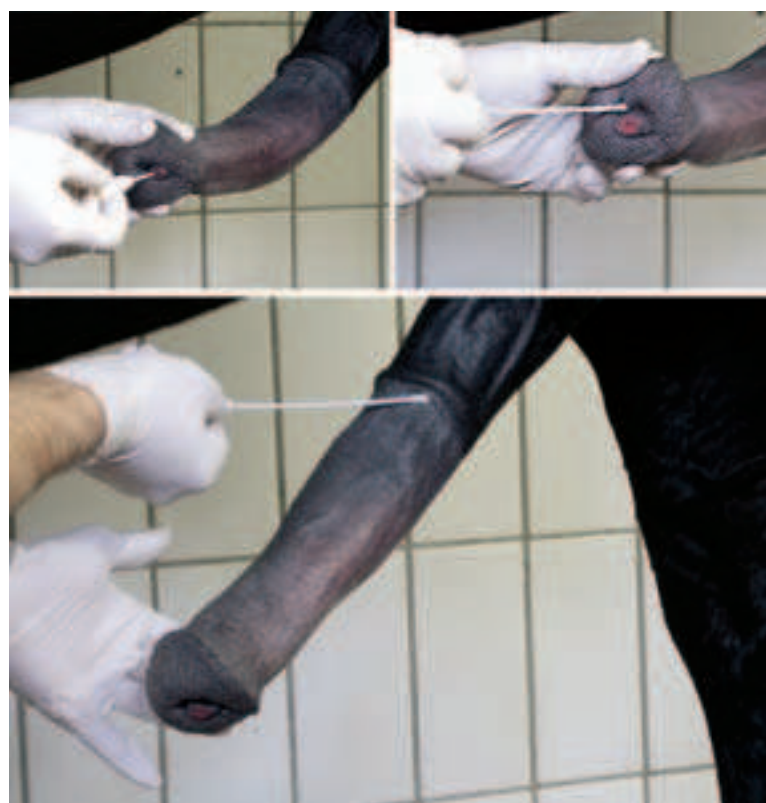

Fig. 84.10. Taking a swab-smear from the urethra, fossa glandis and the body (shaft) of the penis.

Rectal Palpation (palpatio rectalis)

PETER S. GLATZEL

In large animals, for clinical diagnosis, manual examination of organs located in the pelvic and abdominal cavities (rectal palpation) has a special importance. One is reminded of **gynecologic**, andrologic (pp. 75, 77, 81, 85) or **colic diagnosis** in surgery or of the differential diagnosis of internal diseases (p. 66f, topography and projection of abdominal organs). In the case of the horse, before manipulations, it is advisable to discuss the risks of this procedure with the owner or authorized person and in a doubtful case to have the request for examination in writing. Moreover, photo documentation may be indicated.

Preparation

The manual rectal examination is also necessary before sonography in order to have an idea of the actual situation and to be able to carry out, in a directed manner, the sonographic clarification and documentation that follows. In general, these examinations take place, apart from exceptions, on the standing horse. An optimal environment for the examination is guaranteed by the use of a special stock. With examinations in the barn or in the box, the head of the animal can be held firmly by an assistant and one forelimb raised. Vicious and nervous animals get a twitch. As a make-shift in heavy horses (cold bloods), the left or right hind limb (in examinations with the right or left hand) can be stretched or bound by a long rope. During the examination, to protect oneself from being kicked, one positions himself with the chest directly on the animal, nearly resting on the horse's rump. Additional protection can be attained by a bale of straw behind the hind feet. Anesthesia in the standing animal or an epidural anesthesia is only necessary in rare cases of intense pressing, great unrest or sensitivity. For proper hygiene and to prevent the spread of disease, the use of protective clothing is recommended. This includes covering the arm with a rubber sleeve about 70 cm long and galvanized latex gloves for serial investigations or single-use gloves, which must be inverted before the examination so that the seam will be inside. The examiner's hand, protected in this way, is made slippery by corresponding lubricants, gel, vaseline or paraffin oil. Soap is less suitable for this purpose, since it can lead to the drying out of the intestinal mucosa and by that to corresponding irritations and spasms.

Examination

During the lateral attachment of the tail to the croup by an assistant, attention is paid to the palpable resistance and flexibility of the caudal vertebral column. Alterations may indicate traumata or the status of the cycle. After inspection of the perianal and perineal region, especially checking the closure of the anus and the vulvar cleft, adhesions, neoplasms, ruptures and soilings indicative of former surgical operations or examinations, the present condition is recorded. Also, the owner or his representative should be questioned as well as perhaps photodocumentation made.

To introduce the hand into the rectum, the fingers are placed together cone-like. With slight spiral movements one attempts to overcome the resistance of the sphincter muscle. After penetration into the gut, this clings to the arm like a sleeve. The hand is pushed forward slowly and carefully, parallel to the vertebral column. At the transition between the bottle-shaped part into the suddenly narrowing part of the rectum, the accumulating feces must be grasped and removed in order to prevent an overexpansion and, at this particularly dangerous location (see 70.8), to prevent rupture of the gut. The feces are checked for color, consistency, admixture, parasites and odor. Following renewed supply of the examiner's hand with copious lubricants, the internal exploration is continued. Peristaltic waves of intestinal motor activity can be allowed to pass over the hand and arm which lie quietly resting in the intestine. If in pushing the hand farther forward, the gut wall should become more tense, then one should attempt to relieve the spasm, without applying force, by slight spreading or vibration of the finger tips. In this situation, attention should be paid, that the fingers, especially the thumb and little finger, do not make uncontrolled spreading movements, because by that the danger of rupture increases considerably. Feces that appear again will be removed before the hand is moved forward. Within the **rectum** one determines its condition of fullness, the character of its content, its spatial relationships as well as the temperature and character of the mucous membrane. Beyond

that, as one's arm is removed, it is subjected to a quick and careful check for adherent substances (mucus, blood, pseudomembranes, parasites).

A planned rectal examination is at first directed to the request for investigation. In the case of a **gynecologic** request concerning, for example, the **phase of the cycle**, the **cause of sterility**, **artificial semen transfer** or **control of pregnancy**, the female genital organs are subjected to a corresponding examination. To do this, one's hand is initially introduced into the rectum up to the wrist. The **pelvic floor** is palpated with large, pendular movements, the hand and fingertips slightly bent. The **vagina** is traced as a flabby, compressed, displaceable tube about 2–3 cm wide and 1 cm thick (page 83). This structure leads cranially—the arm is now in the intestine up to about half the forearm—to the **cervix uteri**. This is a firm, distinctly palpable cigar-shaped swelling, 1–2 fingers thick and about the length of one's thumb. It ends at the pecten ossis pubis and guides the examining hand to the **body of the uterus**, a somewhat softer structure that also lies in the midline. Depending on the status of the cycle, this is not always distinctly palpable; however, in this area, the **urinary bladder** is palpable at the cranial margin of the pelvis ventrally. Depending on its state of fullness, it is a bottle-shaped structure and sinks into the abdomen as a fluctuating thin-walled but firm structure. It is a good landmark for the investigator and in the ongoing procedure a good starting point for locating the left and right **horns of the uterus**, which go out from the body of the uterus attached to the **broad ligament of the uterus** (*lig. latum uteri*). In this way, when the fingers are drawn analward over the vertex (apex) of the urinary bladder, the bifurcation of the two uterine horns falls into the slightly flexed fingers of the investigating hand. From the body of the uterus, each of the uterine horns extends in a craniolaterodorsal direction in a concave arch. They have a variably expressed consistency, which is dependent on the estrus cycle, and controlled endocrinologically (firm, estrogen influence; – flaccid, progesterone influence or lacking body function). Normally, their length is 15–30 cm, depending on the size of the mare, and their diameter ca. 2–4 cm in the nonpregnant state. If one follows their course in the direction of the paralumbar fossa, so the investigating hand feels at the end of each the walnut to goose-egg sized **ovaries** (pages 82, 83). The **uterine tubes** are normally not palpable.

With respect to a request for an **andrological examination**, rectal examination takes place especially in the case of altered composition of the ejaculate or a purchase examination.

The procedure is at first as in the mare. After evacuation of the rectum, the hand seeks the **urethralis muscle** (page 81, 85), which is readily palpable on the floor of the pelvis. Owing to its distinct reaction to being touched, the muscle is easy to palpate as a thumb- to child's arm-sized, rapidly contracting structure, hands-deep in the pelvic cavity. At its caudal end, the **paired bulbourethral glands** are located. These are fingertip-sized and normally palpable only if changes are present. At the cranial end of the urethralis muscle, which is about the length of one's palm, is the access to the ejaculatory ducts. These are the common passage of the **paired seminal vesicles** and **ampullae of the ductus deferens**. The ducts lie beneath the **prostate gland** which, with its two lateral lobes, is applied ring-like to the cranial end of the muscle. The seminal vesicles are found to the left and right as thumb-sized, firm to slightly fluctuant, smooth structures alongside the shaft of the ilium. Beneath the seminal vesicles, the ampullae of the deferent ducts discharge also in this area into the **ejaculatory duct**. If one follows the deferent ducts into the abdominal cavity to the left and right, somewhat laterally and cranial to the pecten ossis pubis, one encounters the **vaginal ring**, the internal opening of the peritoneal outpouching of the **vaginal process**, which, as a testicular covering, has evaginated into the scrotum. At the same time, one examines the parts of the abdominal wall that can be reached, pays attention to palpable vibrations or crackle (roughness of the peritoneum), to painfulness and the surface character of the area, the width of the **internal inguinal ring**, as well as the condition and sensitivity of the soft tissue structures that pass here, as compared with both sides.

A thorough palpation of the **abdominal organs** can be important for the clarification of internal diseases or for the diagnosis of colic and making decisions for operation. In doing this, the spatial expansion of the possible intraabdominal field of operation should be thought of as part of a cone, which, depending on the length of one's arm and the animal's size, reaches variably far cranially. In medium-sized horses and at average arm's length, the craniodorsal border of this cone is formed by the cranial half of the left kidney,

on the abdominal wall by the caudal end of the costal arch, and on the ventral abdominal wall by the line of junction of the meso- and hypogastrium (page 66; 67).

For the planned examination, one palpates briefly the pelvic cavity, its configuration, especially the internal pelvic symphysis on the pelvic floor as well as the form of the bony parts of the pelvis. On the cranial border of the pelvis one orients oneself at first dorsally, below the lumbosacral joint, at the distinctly palpable, finger-sized, pulsating **termination of the aorta**. If one follows the **vertebral column** cranially, one palpates to the left in the area of the cranial angle of the paralumbar fossa, the caudal pole of the **left kidney**, elevated tumor-like from the abdominal wall. If the investigating hand slides from here to the right side across the coil of intestine, it encounters the **cranial mesenteric root**, the touch of which usually triggers a sensible reaction of the animal. The tension, demonstrability, and perhaps pulsation of this structure are important for the colic diagnostic. After bypassing this structure and pressing further forward to the right, to the right of the vertebral column, the caudal pole of the **right kidney** can also be reached. Both kidneys are examined for circumference, consistency, sensitivity and condition of the surface. At the same time, the renal hilus is palpated with attention to the renal arteries. Starting from the renal hilus, one directs the finger about three fingerbreadths removed from the abdominal aorta, alongside the dorsal abdominal wall, to the neck of the urinary bladder to ascertain possible changes of the ureter. The **ureter** is normally not palpable. After further retraction of the hand, the fluctuating urinary bladder is found as a structure lying centrally in front of the pelvic inlet, which will serve as a landmark for orientation.

The **spleen** may be reached either by pushing the hand forward along the left abdominal wall to the caudal end of the costal arch or by sliding down from the ventral surface of the left kidney. The dorsal half of the spleen can often be found under the left paralumbar fossa. It is palpated by sliding the fingers along its medial and lateral surfaces, grasping its dorsal and caudal borders in several places and in that way determining its thickness, the sharpness of its borders and swelling.

From the horizontal plane of the pubic border, the caudal two-thirds of the **left ascending colon** can be palpated. At first one searches the **teniae**, which are always palpable, and identifies with their guidance, the position and expansion, the course, the tension and filling state as well as the consistency of the content. After this the hand is led craniodorsally up to the left kidney and moves then horizontally to the right half of the abdominal cavity, to find the stomach-like dilatation of the **right colon (ampulla coli)** in order to determine its position, girth, and consistency as well as its palpable and respiratory mobility (even possible in horses with a height of 175 cm). In association with that, one searches the initial portion of the **small colon**, which goes out from the ampulla coli in the left half of the abdominal cavity about 10 cm removed from the vertebral column. In small animals the **blind sac of the stomach**, if strongly filled, can be reached here. Starting from the hilus of the left kidney or following the course of the abdominal aorta, the hand encounters a soft, elastic, sensible, ventrally fan-like expanding cord with pulsating arteries, the **cranial mesenteric root**. On its caudal surface, about 20 cm distal to the abdominal aorta, one finds the **duodenum**. It is normally soft, runs transversely, and (owing to its short mesentery) can be displaced only a little. With this, the transrectal examination of the most cranially reachable parts of the abdomen is concluded. For these investigations the examiner must shove one's arm maximally into the intestine, nearly to the armpit. In doing this, in the case of left-right, to and fro, movements of the hand, attention must be paid that sudden movements of the arm-joints are avoided and the matching cranio-caudal movements in the search for corresponding structures by cranio-caudal, to and fro, movements of the arm, which follow the line of the vertebral column, must be realized much as one would move the arm in playing the trombone.

After withdrawing the arm up to about the upper arm-cubital joint, the hand is advanced into the area of the right paralumbar fossa, and finds here the **cecum**, which is easily recognized by its teniae. The cecum is also examined in its individual parts: head or base of the cecum (which includes its overhanging part) and body, for pain, position, state of filling, and consistency. Besides that, attention is paid to the course of direction of its teniae. On the cecum's medial surface, about at the level last rib, one finds the site of discharge of the ileum into the cecum (the two parts of the gut are

to be distinguished only by consistency and/or tension conditions). Beneath the contralateral left paralumbar fossa are found loops of **small colon** and **jejunum**. These lie between the layers of the left colon and the cecum as well as caudal to the latter up to the pelvic inlet. In healthy animals only the more dorsally and caudally placed loops of small colon can be recognized by the palpable fecal balls which they contain as well as the teniae on their free wall. The loops of small intestine normally cannot be clearly identified by palpation.

With movement from the left paralumbar fossa across to the cecum the **caudal mesenteric root** (mesentery arising at the origin of the caudal mesenteric artery) renders only little resistance and is for this reason only recognizable in case of colic.

For the sake of completeness, the **liver** may be mentioned. Only in case of significant increase in girth is it palpable in the right renal area and in the median plane.

Sonography in Equine Reproduction

PETER S. GLATZEL

Increased attention to equine reproduction in veterinary practice has awakened the need for a concentrated clinical, scientifically sound and applications-oriented presentation of sonography in this area. This applies especially to the uses of this technique that, over time, has matured, is cost-effective, objective, reproducible, can be documented and, after a corresponding co-signing by the owner or animal caretaker, perhaps also can be used as a legal resource. For this reason it was the intention of this contribution, already during the study of anatomy and as near to practice as possible, to introduce image analysis and documentation of ultrasonographic images. With the help of corresponding representations and interpretations, this diagnostic procedure should be broken down to the extent that, in addition to practicing veterinarians, students also can benefit.

For this reason emphasis was laid on studies of the uterus and ovaries before and after ovulation in the practical monitoring of fertility of the mare. In this way, physiological findings are compared and form the basis of corresponding clinical judgments.

In particular, the most favorable time for mating or insemination is discussed in the context of the use of liquid or frozen semen. The establishment of pregnancy serves as a control.

In seasonal anestrus (days growing shorter) the horse shows an indifferent sexual behavior, without an appreciable release of gonadal hormones or the formation of **larger follicles on the ovaries**.

In the cyclic mare, the changeover of the hormonal household takes place during the mating period (days growing longer). The mating period is characterized by the regularly occurring progesterone-secretion pattern with high values from the 7th–9th day post-ovulation and a corresponding estradiol secretion during the heat (estrus period). This basic pattern of gonadal hormone action triggers on the one hand the typical signs of estrus and on the other hand the sexually indifferent behavior of mares in anestrus. Otherwise they cause the morphological changes of the external genitalia. Owing to the increasing estradiol concentration at the beginning of estrus, the **vulva** of the mare in heat is edematously swollen, flabby, and the mucosa of the vestibule exhibits a slight degree of hyperemia.

The altered behavior of the mare as compared to the stallion can be established best by testing with a stallion. This test of the mating behavior by the teaser-stallion should precede every other diagnostic procedure because, on the one hand, it contributes an important partial finding in the diagnosis of the stage of the cycle. On the other hand, owing to a limited hormone release (LH) from the hypophysis, the test acts to stimulate the endocrine system and in that way acts on the genital functions of the mare.

Size, symmetry and preparedness for conception with the eventual content of the uterus as well as the size and functional status of the ovaries, including their functional structures, are perceived by transrectal palpation, recorded and considered in the evaluation of the stage of the cycle.

In general, the **uterus** of the mare during estrus is of edematous consistency and has a moderate tonus.

Seventy-two hours before ovulation the consistency of the follicles is firm in about 30% of the cases, soft in about 60% and very

soft in about 10% of the mares. Contrary to this, 12 hours before ovulation, 9% of the follicles still exhibit a firm consistency, about 51% a soft consistency, and about 40% a very soft consistency. The preovulatory follicle reaches a diameter of 35–55 mm, in exceptional cases a diameter of up to 100 mm.

Palpation of the ovaries of the mare in the peri-ovulatory period may trigger sensible reactions, which are expressed by unrest and readiness for defense by the mare. Transrectal palpation of the ovaries permits determination of an ovulation that has recently taken place; however, not a precise forecast, because this takes place in general on the last day of estrus, which from heat to heat can be variably long.

At ovulation the follicle collapses and the formation of a crater is palpable in the area of the ovulation fossa of the ovary. This is filled by a blood coagulum, which is designated, including the follicle wall, as a **corpus hemorrhagicum**. This soft corpus hemorrhagicum can be confused with a follicle, ready for ovulation, but is differentiated by its “crunching like a snowball” under gentle pressure and especially with the help of sonography. Only in exceptional cases is the corpus luteum of the mare palpable in the first postovulatory days. This is because it does not project over the surface of the ovary, but owing to anatomic peculiarities of the ovary of the mare develops in the interior of the ovary.

Equipment

For sonographic examination of the internal sex organs of large animals, predominantly ultrasound instruments with a veterinary real-time linear head or sector-scanner of 3.5 MHz or, and chiefly, 5.0 MHz (Fig. 1) are used. The 3.5 MHz ultrasoundhead (US-head) has a greater depth of penetration (up to 279 mm, depending on the texture of the tissue) at the cost of a slight loss of resolution (less clear images). It is also used for transcutaneous study, for example, in the dog. The 5 MHz head is employed in transrectal investigation. It has slightly less depth of penetration (about 50 mm), but better resolution (sharper images). We reach the genital organs most closely through the gut wall. For this reason, a sharp image is possible with the 5 MHz head.

The Sonographic Examination

Immediately after completing the transrectal palpation, the probe (ultrasoundhead or transducer) is placed in the hollow of one's palm so that the tip of the system lies under the index finger and its cable, the connection to the computer, under the wrist. Now the sound emitting/receiving surface (about 56 mm long, 9 mm wide) of the probe is covered with a layer of ultrasound gel or good lubricant about the thickness of the back of a knife. Covered by the fingers on the sides and with the protection of the fingers, the instrument is introduced into the empty ampulla of the rectum with a slight twisting movement. The fingers are drawn away from the ventral emitting surface of the probe and stabilize the probe on the sides, so that, held between the thumb and ring finger, it can be guided from above by the index or middle finger. For orientation, the hand is moved cranially as in rectal palpation until, cranial to the pelvic inlet, the **urinary bladder** appears. The bladder appears dark and homogeneous. Cranial to the pecten ossis pubis the probe is tilted slightly cranioventrally. In the mare in breeding condition, there now appears applied to the **broad ligament of the uterus (lig. latum uteri)** a whitish-grey structure about little-finger to thumb-size, the uterus. After rotating the US-head about 45° in the direction of the tuber coxae, the **bifurcation of the uterus** becomes visible in cross-section as a grey, homogeneous structure. Starting from this orientation point, the **uterine horns** can now be followed in a dorsolateral direction along the shaft of the ilium and, after that,



Fig. 1. Ultrasound apparatus; above left, linear scanner placed in the hand for examination.

the ovaries. The latter lie about 1 – 3 handbreadths (depending on the size of the mare) beside the bifurcation at the end of the uterine horns. The horns are somewhat concave and ascend laterodorsally from the bifurcation. Often the ovaries are hidden by the ovarian bursa, so that this has to be first cautiously pushed aside.

On the ovaries special attention has to be paid to functional formations, dark round, vesicular or polygonal greyish-white structures. Their expansion or diameter can be demonstrated by changing the sound-plane and quantified with the help of standard imaging equipment (freeze-function) plus the application of an integrated measuring unit. One retains the findings recorded as individual frames, or they become records with the help of a Polaroid camera, a thermophotocopier or video apparatus.

In withdrawing the probe lightly across the pelvic floor the **uterine body, cervix and vagina** can be recognized caudal to the uterine bifurcation, especially in the case of alterations, for example, filling. Altogether, one must realize that the sections produced here are two-dimensional images. For this reason it is important, to probe the entire organ in different planes of section, to understand also a spatial dimension and localized limited events. Only under these conditions are corresponding conclusions and diagnoses possible.

For studies of the **uterus** the microscopic structure of its wall is of central interest for the interpretation of the light-dark contrast changes of the images (Fig. 2). According to the density of the corresponding histological layers, especially of the endometrium, there are present, depending on the degree of its filling with fluid, whitish-grey stripes or rings (longitudinal section, cross-section). These show the endocrine-influenced secretory activities and with them the structural alterations of the parts of the mucosa that are dependent on the cycle. These structures are normally inconspicuous in the ultrasound image. During estrus, they are subjected to estrogen-dependent deposits of fluid, which lead to considerable increases in volume in the tissues and, during high heat, they are expressed in the ultrasound image in the form of so-called wheel-spokes (Fig. 82.1b).

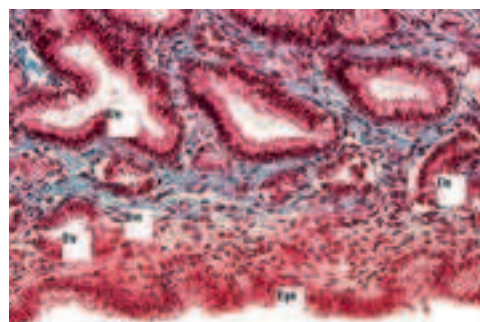
Conclusions from the sonographic examination

The **fertility of a mare**, her ability to conceive and maintain pregnancy up to the birth of a live foal, is decisively influenced by the **functional morphology of the endometrium**. Also, in this direction, the ultrasound examination can give corresponding hints to possible diseases, which is important for the prognosis of fertility.

A decisive factor for the quality of the endometrium seems to be the age of the particular mare. In older mares, more often a persistence of an endometritis is established, which can lead to decreased fertility up to infertility. Endometrial biopsies from older mares (≥ 15 years) show an increase in inflammatory cell infiltrates and fibroses as well as a reduced density of glands in comparison to younger mares (5–7 years). Although in the mare the sexual cycle is unlimited up to old age, with increasing age (> 14 years) or with increasing parity an increase in histological changes of the endometrium can be observed.

The ovaries are well suited for ultrasound examination owing to their size (up to the size of a fist), their fluid-filled (for example, follicles) and firm structures (for example **corpora lutea**), as well as their easy accessibility per rectum.

The gynecological ultrasound examination is to be associated with the rectal palpation of the internal genitalia of the mare in order to objectify and document the findings on palpation. Thus,



Epi = luminal epithelium; Dr = uterine gland; Bw = connective tissue

Fig. 2: Histological work-up of an unsuspicious uterine biopsy of a mare at the beginning of the season. The epithelia of the uterine glands as well as of the uterine mucosa appear uniform and conform to the cycle.

follicles already with a diameter of < 30 mm can be demonstrated. Furthermore it is possible to show double ovulations, follicular atresia, tumors, hematomas, corpora lutea, and so on.

To grasp the **dynamics of follicular development**, sonographic examinations are conducted and documented at 12–24 hour intervals. In this way, the maturation of the dominant follicle can be followed and the timing of ovulation predicted.

In general, during diestrus (Fig. 82.1a'), three to four small (< 2.0 cm) follicles can be observed on both ovaries. Besides that, a distinct *corpus albicans* is found on one of the two ovaries. About this time, selection of the dominant follicle begins, the divergence of follicular dynamics. The divergence is followed by the dominant phase in the follicular dynamics. This is recognized by the fact that from the 15th day of the cycle (post-ovulation) one follicle out of the population, sometimes even on each ovary, shows an accelerated growth. This dominant follicle increases rapidly in size and prevents the growth of the remaining cohorts (Fig. 82.1a).

From about the 16th day of the cycle, a strong increase in size of the largest follicle and a relative decrease in the size of the second largest follicle is recognized. From a size of about 3–3.5 cm the external and internal signs of heat begin to develop in the mare. The largest follicle becomes a GRAAFIAN follicle and prepares itself for ovulation by corresponding internal reconstruction processes. On the day before the ovulation, the diameter of the GRAAFIAN follicle is between 35 and 70 mm, against which the second largest remains at about 25–30 mm. In this process, there exists the possibility, especially under the influence of exogenous stressors (severe weather change, change of food, change of personnel, change of location, physical and psychological stress), that it comes to a complete regression of all formed follicles or that suddenly the concurring second largest follicle, usually on the contralateral ovary, takes over the dominance and ovulates.

Double ovulations occur in horses in about 16–18% of the cases. In general, they are not wanted. For this reason their forecast is important and possible by ultrasound investigation. In double-ovulation, two roughly equal-sized follicles mature, often on the same ovary. That such an event is developing is predictable, if from the 16th to 18th day of the cycle two follicles experience parallel changes.

Up to two days before ovulation, there is observed an increase in the echogenicity of the follicular fluid at the periphery of the follicle that is approaching ovulation. Besides that, the follicle increases significantly in size and its internal pressure decreases. It loses its circular shape in favor of an oval, easily impressible shape of fluctuating consistency. At first the follicular wall increases in thickness to become thin and pliant at its pole about 12–6 hours before ovulation. Accordingly there exists the possibility of defining the perimeter of the time of ovulation by ultrasound diagnostics. By detailed checking of the size of the follicle, its form, the strength of its wall, and the increase in echogenicity of its borders, this is quite possible with ultrasound (Fig. 3).

It is of prime practical importance to distinguish in the ultrasound image a follicle ready for ovulation (echo-poor, fluid-filled vesicle) from a corpus hemorrhagicum, which is uniformly echogenic or with an anechogenic center (the central blood coagulum with an irregularly circumscribed surface; Fig. 4). In addition to evaluation of follicular growth, the stage of the cycle, and prediction of ovulation, also the texture of the uterine lumen, which is

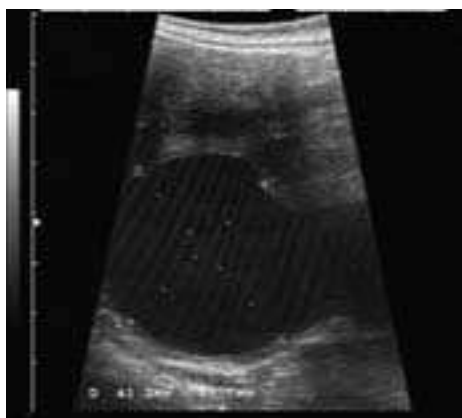

Fig. 3. Freshly ovulating (rupturing) GRAAFIAN follicle. (Courtesy of Prof. Glatzel, Berlin)

demonstrable by ultrasound, can be discussed. In this regard, the disappearance of the wheel-spoke structure (Fig. 82.1b), which is typical of the mare in heat, about 12 hours before ovulation represents an almost certain sign of impending ovulation.

With so-called problem-mares, tenuous clinical diagnoses can be made on the basis of the clinical findings and with these especially the results of ultrasound investigations and documentations. Therapeutic possibilities of ovarian-conditioned fertility disturbances can then be worked out. Disorders of ovulation due to endocrine derailments are regarded as causes of such disturbances. These express themselves either in thin-walled large cystic structures, which are frequently estrogen producing and which can lead to permanent heat (nymphomania) or in thick-walled, firm progesterone-secreting structures, which cause an anestrus (Figs. 5a, b). Another cause can be seen in a disturbed run-off of follicular dynamics in which the divergence phase does not proceed in a regular fashion and the ovary appears as a small cystic structure.

The large benefits of the ultrasound technique consist also in the fact that the success of the therapeutic measures introduced can be followed up and documented.

Use of ultrasound in artificial insemination

A further important field of application is artificial insemination ("a.i.").

Naturally the best chance for conception exists if the mating or insemination takes place close to ovulation. In the mare, this is the interval from 12 hours before to 6–8 hours after ovulation (Figs. 3, 4). Whether the mating should be done before or after ovulation depends mostly on the time between examinations, which is determined by practical conditions and is decided with the help of the ultrasound findings.

With insemination of fresh semen, to guarantee a good fertility, the insemination amount should be at least 500 million motile sperm cells. With insemination of cooled semen, however, the recommendations are 1 billion sperm per insemination, because the vitality of the sperm decreases by cooling. The insemination volume has a significant influence on the rate of fertilization. A volume between 10 and 25 ml is considered optimal. A larger insemination volume, diluted semen, has a negative impact on the rate of pregnancy. The insemination interval is directed on the one hand to the duration of the fertilization capability of the sperm cells in the female genital tract and on the other hand to the life span of the ovulated ovum. Furthermore the duration of sperm transport and the capacitation of the sperm cells have to be borne in mind. These facts have to be considered in the selection of the manner of insemination, in order that the sperm cells can reach the site of fertilization before or immediately after ovulation.

With the help of ultrasound, the **planning of insemination** can be carried out very precisely. In this regard, it is important to know that sperm can survive up to one week in the female genital tract. For these processes, the uterotubal papilla (Figs. 82.1e, e') is obviously an important structure in its function in the storage and selection of sperm. In addition, it must be borne in mind that, on the other hand, the maximal life span of the ovocyte is limited only to about 12 hours post-ovulation.

For these reasons, in most insemination programs, insemination will be carried out every two days beginning with the second or third day of heat up to the wearing off of external signs of heat or the observation of ovulation. Altogether, this is a fairly expensive procedure, entirely apart from the logistic problems of the permanent availability of semen.

These problems can be minimized with the help of sonographic examination. To do this, ultrasound examination is conducted at two-day intervals from about the 16th–17th day of the cycle up to the beginning of heat and the **follicular dynamics** are followed after that in daily studies. In this way, ovulation and the time of fertilization can, to a large extent, be predicted with certainty. Furthermore, induction of ovulation is still possible by means of HCG injected intravenously with the formation of a preovulatory follicle of 35 mm diameter and insemination 24 hours post-injection. If an ovulation has not taken place, perhaps a second insemination should be performed 36–48 hours post-injection.

With inseminations that were performed later than 12 hours post-ovulation only a low rate of success of pregnancy was recorded.

The presence of **deep-frozen semen**, owing to its practically unlimited storage capability in the deep frozen condition, brings the

advantage that the semen can be shipped anytime and accordingly is available at the insemination station already before the mating season. Consequently its transport need not be coordinated with the timing of the ovulation of the mare. Moreover, the presence of deep frozen semen makes possible the increased availability of international stallions, the unlimited tournament-commitment of breeding stallions even during the mating season as well as the installation of sperm banks. There are considerable individual variations with regard to the capability of deep-freezing and thawing of stallion sperm, so that the quality of the semen of some stallions after the freezing and thawing process can be considerably lowered and no satisfactory rate of pregnancy can be reached.

Examination for pregnancy

In the mare a transrectal clinical examination (TU) for pregnancy is possible from the third week. The first two weeks post-conception present a stage without result by rectal examination. The embryo can be demonstrated by ultrasonography from day 9 or 10 post-ovulation (Fig. 6). The examination for certain pregnancy about

day 18 is of practical importance. At this time the **embryonic vesicle** is found as a symmetrically round sphere at the base of the uterine horn or in the body of the uterus. From about day 16 post-conception through the so-called sensibilizing stage, the uterus is well palpable as a firm structure. On the 20th day, the embryonic vesicle assumes a more asymmetrical, polygonal form. On the 23rd day the embryo can be recognized. At this point in time, it has a length of about 6 mm. From this time on, even the activity of the heart can be observed.

Ultrasound investigations are indicated in the framework of **early pregnancy diagnosis** in the case of unclear results of uterine palpation, for the demonstration or exclusion of risky pregnancies such as twin pregnancies, especially identical twins, as well as when there is a suspicion of embryo resorption (Fig. 7).

If an, in general, undesirable **twin-pregnancy** is observed in due time, up to day 23–30, successful removal of an embryo is possible by the so-called manual pinch (Fig. 8). After such a procedure, the viability of the remaining embryo should be checked about 1 week later. **Sex determination** is the “high school” of ultrasound diagnos-

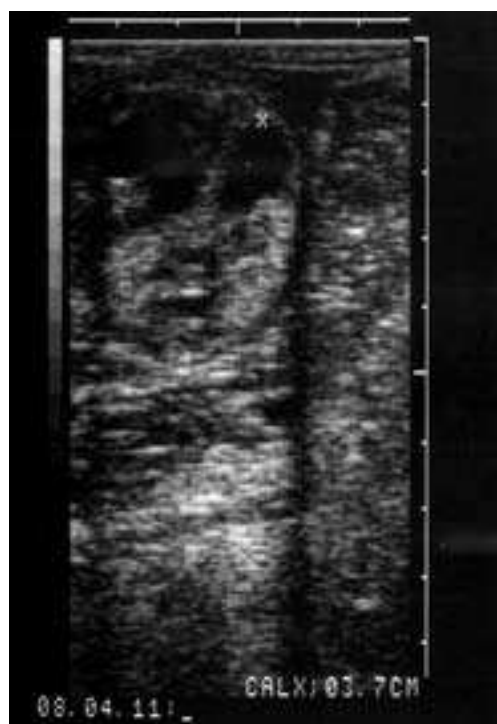


Fig. 4. Organized late corpus hemorrhagicum/early corpus luteum. (Courtesy of Prof. Glatzel, Berlin)

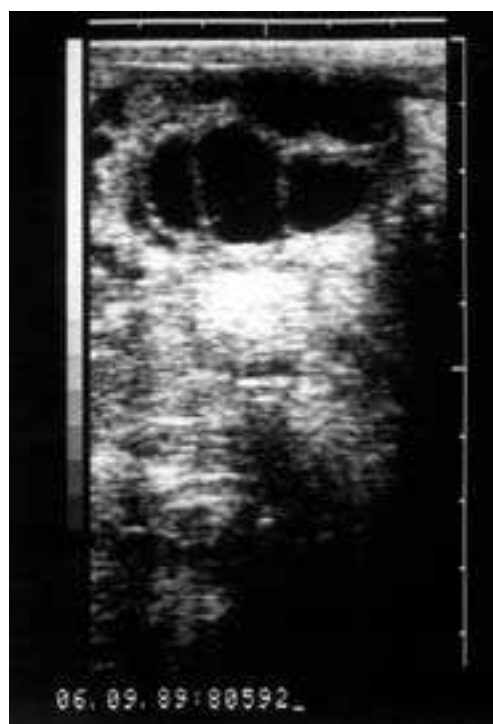

Fig. 5a. Thin-walled, chambered large cyst. (Courtesy of Prof. Glatzel, Berlin)

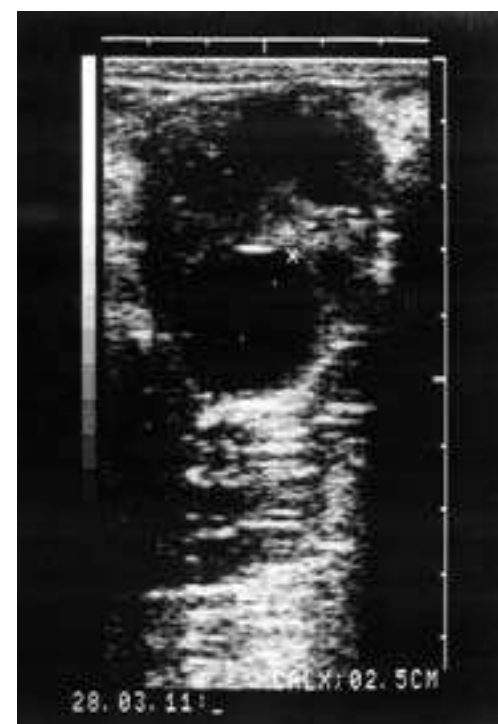

Fig. 5b. Thick-walled, small persisting cysts. (Courtesy of Prof. Glatzel, Berlin)

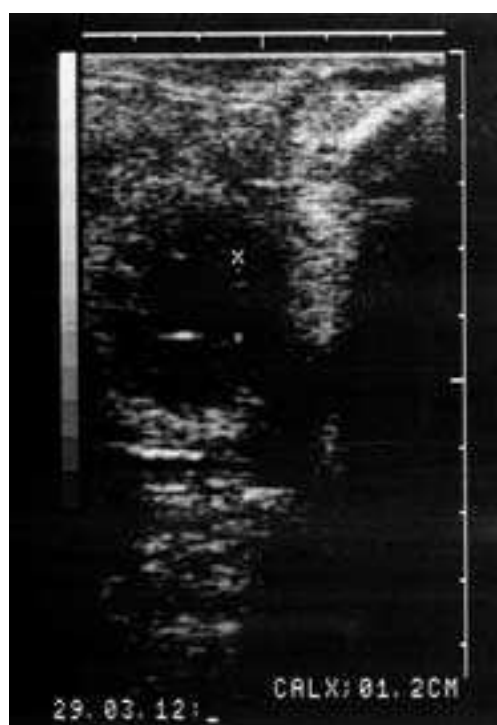

Fig. 6. Early gestation, day 12. (Courtesy of Prof. Glatzel, Berlin)

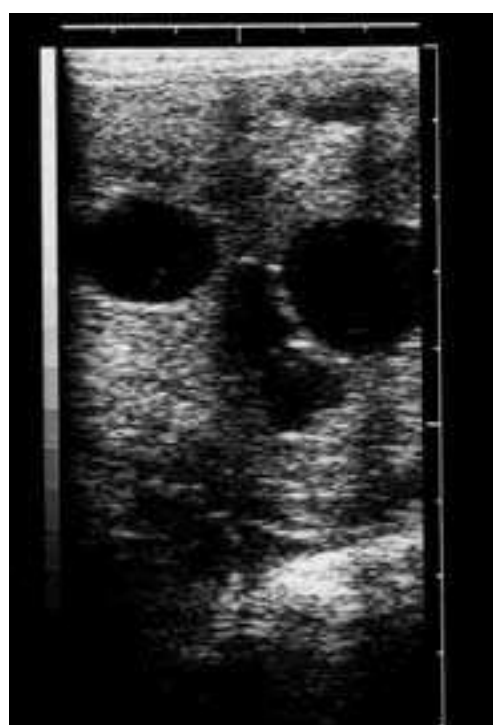

Fig. 7. Twin pregnancy, day 16. (Courtesy of Prof. Glatzel, Berlin)

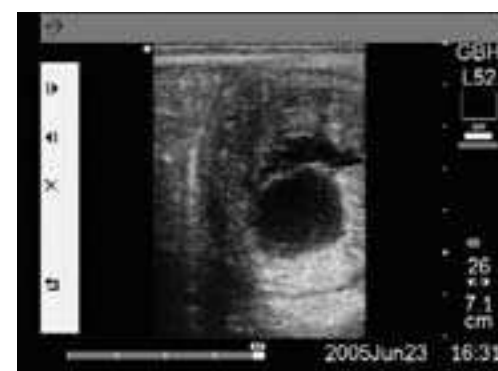

Fig. 8. Following removal of the upper embryonic vesicle (strong fold-formation of the damaged fetal membranes), surviving embryo distinctly shown. (Courtesy of Prof. Glatzel, Berlin)

tics. It is possible from the 6th to the 8th week of pregnancy. In doing this, the position of the sex hillock is checked and, for this, the pelvic girdle (hind limb) and the umbilical cord are sought. If the sex hillock, a dense, about 0.5 cm long swelling is found between the umbilical cord and pelvis, then it is a colt foal. If this structure is found caudal to the pelvic girdle below the root of the tail, then we are dealing with a filly foal. To be safe, an image should always be documented and in case of doubt no statement should be made.

List of References

Arthroscopy and Endoscopy in Veterinary Medicine

1. McIlwraith, C.W., *Experiences in diagnostic and surgical arthroscopy in the horse*. Equine Vet. J., 1984. 16(1): p. 11–19.
2. Trotter, G.W., McIlwraith, C.W., *Advances in equine arthroscopy*. Vet. Clin. North Am. (Equine Pract.), 1996. 12(2): p. 261–281.

Thoracic Limb

3. Butler, J.A., Colles, C.M., Dyson, S.J., Kold, S.E., Poulos, P.W., *Clinical radiology of the horse*. 2 ed. Fusion times of physes and suture lines. 2000, Oxford: Blackwell Science. 585–587.
4. Embertson, R.M., Bramlage, L.R., Herring, D.S., Gabel, A.A., *Physeal fractures in the horse. I. Classification and incidence*. Vet. Surg., 1986. 15(3): p. 223–229.
5. Wagner, P.C., Watrous, B.J., *Equine pediatric orthopedics: part 5 – physeal fractures*. Equine Pract., 1990. 12(9): p. 21–25.
6. Embertson, R.M., Bramlage, L.R., Gabel, A.A., *Physeal fractures in the horse. II. Management and outcome*. Vet. Surg., 1986. 15(3): p. 230–236.
7. Auer, J.A., *Beitrag zur Frühdiagnose und Behandlung einer speziellen Stelungsanomalie beim Pferd*. Pferdeheilkunde, 1989. 5(4): p. 201–205.
8. Greet, T.R.C., *Managing Flexural and Angular Limb Deformities: The Newmarket Perspective*. Proc. Am. Assoc. Equine Pract., 2000. 46: p. 130–136.
9. Leitch, M., *Musculoskeletal disorders in neonatal foals*. Vet. Clin. North Am. (Equine Pract.), 1985. 1(1): p. 189–207.
10. Brauer, T.S., Booth, T.S., Riedesel, E., *Physeal growth retardation leads to correction of intracarpal angular deviations as well as physeal valgus deformity*. Equine Vet. J., 1999. 31(3): p. 193–196.
11. Read, E.K., Read, M.R., Townsend, H.G., Clark, C.R., Pharr, J.W., Wilson, D.G., *Effect of hemi-circumferential periosteal transection and elevation in foals with experimentally induced angular limb deformities*. J. Amer. Vet. Med. Assoc., 2002. 221(4): p. 536–540.
12. Bleyaert, H.F., Madison, J.B., *Complete biceps brachii tenotomy to facilitate internal fixation of supraglenoid tubercle fractures in three horses*. Vet. Sur., 1999. 28(1): p. 48–53.
13. Dyson, S., *Sixteen fractures of the shoulder region in the horse*. Equine Vet. J., 1985. 17(2): p. 104–110.
14. Carter, B.G., Schneider, R.K., Hardy, J., Bramlage, L.R., Bertone, A.L., *Assessment and treatment of equine humeral fractures: retrospective study of 54 cases (1972–1990)*. Equine Vet. J., 1993. 25(3): p. 203–207.
15. Mackey, V.S., Trout, D.R., Meagher, D.M., Hornof, W.J., *Stress fractures of the humerus, radius, and tibia in horses. Clinical features and radiographic and/or scintigraphic appearance*. Vet. Radiol., 1987. 28(1): p. 26–31.
16. O'Sullivan, C.B., Lumsden, J.M., *Stress fractures of the tibia and humerus in Thoroughbred racehorses: 99 cases (1992–2000)*. J. Amer. Vet. Med. Assoc., 2003. 222: p. 491–498.
17. Shamis, L.D., Auer, J., *Complete ulnas and fibulas in a pony foal*. J. Amer. Vet. Med. Assoc., 1985. 186(8): p. 802–804.
18. Denny, H.R., Barr, A.R.S., Waterman, A., *Surgical treatment of fractures of the olecranon in the horse: A comparative review of 25 cases*. Equine Vet. J., 1987. 19(4): p. 319–325.
19. Murray, R.C., Debowes, R.M., Gaughan, E.M., Bramlage, L.R., *Application of a hook plate for management of equine ulnar fractures*. Vet. Surg., 1996. 25(3): p. 207–212.
20. Donecker, J.M., Bramlage, L.R., Gabel, A.A., *Retrospective analysis of 29 fractures of the olecranon process of the equine ulna*. J. Amer. Vet. Med. Assoc., 1984. 185(2): p. 183–189.
21. Auer, J.A., Watkins, J.P., *Treatment of radius fractures in the horse. An analysis of 15 clinical cases*. Equine Vet. J., 1987. 19: p. 103–110.
22. Sanders-Shamis, M., Bramlage, L.R., Gable, A.A., *Radius fractures in the horse: a retrospective study of 47 cases*. Equine Vet. J., 1986. 18(6): p. 432–437.
23. McIlwraith, C.W., *Incomplete ossification of carpal and tarsal bones in foals*. Equine Vet. Educ., 2003. 15(2): p. 79–81.
24. McLaughlin, B.G., Doige, C.E., Fretz, P.B., Pharr, J.W., *Carpal bone lesions associated with angular limb deformities in foals*. J. Amer. Vet. Med. Assoc., 1981. 178(3): p. 224–230.
25. Ruohoniemi, M., Tulamo, R.M., Hackzell, M., *Radiographic evaluation of ossification of the collateral cartilages of the third phalanx in Finnhorses*. Equine Vet. J., 1993. 25(5): p. 453–455.
26. Adams, R., Poulos, P., *A skeletal ossification index for neonatal foals*. Vet. Radiol., 1988. 29: p. 217–222.
27. Wong, D.M., Scarratt, W.K., Maxwell, V., Moon, M., *Incomplete ossification of the carpal, tarsal and navicular bones in a dysmature foal*. Equine Vet. Educ., 2003. 15(2): p. 72–78.
28. Palmer, S.E., *Prevalence of carpal fractures in Thoroughbred and Standardbred racehorses*. J. Amer. Vet. Med. Assoc., 1986. 188(10): p. 1171–1173.
29. Stephens, P.R., Richardson, D.W., Spencer, P.A., *Slab fractures of the third carpal bone in Standardbreds and Thoroughbreds: 155 cases (1977–1984)*. J. Amer. Vet. Med. Assoc., 1988. 193: p. 353–358.
30. Bramlage, L.R., Schneider, R.K., Gabel, A.A., Blake-Caddel, L., *A clinical perspective on lameness originating in the carpus*. Equine Vet. J., 1988. 6 (Suppl): p. 12–18.
31. Auer, J., *Diseases of the carpus*. Vet. Clin. North Am. Large Anim. Pract., 1980. 2: p. 81–99.
32. Lucas, J.M., Ross, M.W., Richardson, D.W., *Post operative performance of racing Standardbreds treated arthroscopically for carpal chip fractures: 176 cases (1986–1993)*. Equine Vet. J., 1999. 31(1): p. 48–52.
33. Schneider, R.K., Bramlage, L.R., Gabel, A.A., Barone, L.M., Kantrowitz, B.M., *Incidence, location and classification of 371 third carpal bone fractures in 313 horses*. Equine Vet. J., 1988. 6 (Suppl.): p. 33–42.
34. McIlwraith, C.W., Yovich, J.V., Martin, G.S., *Arthroscopic surgery for the treatment of osteochondral chip fractures in the equine carpus*. J. Amer. Vet. Med. Assoc., 1987. 191(5): p. 531–540.
35. Auer, J.A., Watkins, J.P., White, N.A., Taylor, T.S., Rooney, J.R., *Slab fractures of the fourth and intermediate carpal bones in five horses*. J. Amer. Vet. Med. Assoc., 1986. 188: p. 595–601.
36. Nixon, A.J., Wilke, M., *Fractures of the palmar aspects of the carpal bones – A debilitating problem*. Proc. Am. Assoc. Equine Pract., 2000. 46: p. 104–106.
37. Lewis, R.D., *Carpal arthrodesis – indications and techniques*. Proc. Am. Assoc. Equine Pract., 2001. 47: p. 480–483.
38. Katzenmeier, K., *Präparatorische, röntgenologische und klinische Befunde am Karpal- und Metakarpalskelett des Pferdes im Hinblick auf das Vorkommen und die Pathogenese der medialen Überbeine*. 1994, Tierärztl. Hochschule Hannover.
39. Losonsky, J.M., Kneller, S.K., Pijanowski, G.J., *Prevalence and distribution of the first and fifth carpal bones in Standardbred horses as determined by radiography*. Vet. Radiol., 1988. 29(5): p. 236–238.
40. Stover, S.M., Pool, R.R., Morgan, J.P., Martin, R.B., Sprayberry, K., *A review of bucked shins and metacarpal stress fractures in the thoroughbred racehorse*. Proc. Am. Assoc. Equine Pract., 1988. 34: p. 129–134.
41. Boston, R.C., Nunamaker, D.M., *Gait and speed as exercise components of risk factors associated with onset of fatigue injury of the third metacarpal bone in 2-year-old Thoroughbred racehorses*. Am. J. Vet. Res., 2000. 61(6): p. 602–608.
42. Riggs, C.M., Whitehouse, G.H., Boyde, A., *Pathology of the distal condyles of the third metacarpal and third metatarsal bones of the horse*. Equine Vet. J., 1999. 31(2): p. 140–148.
43. Zekas, L.J., Bramlage, L.R., Embertson, R.M., Hance, S.R., *Characterisation of the type and location of fractures of the third metacarpal/metatarsal condyles in 135 horses in central Kentucky (1986–1994)*. Equine Vet. J., 1999. 31(4): p. 304–308.
44. Ellis, D.R., *Some observations on condylar fractures of the third metacarpus and third metatarsus in young Thoroughbreds*. Equine Vet. J., 1994. 26(3): p. 178–183.
45. Pleasant, R.S., Baker, G.J., Muhlbauer, M.C., Foreman, J.H., Boero, M.J., *Stress reactions and stress fractures of the proximal palmar aspect of the third metacarpal bone in horses: 58 cases (1980–1990)*. J. Amer. Vet. Med. Assoc., 1992. 201(12): p. 1918–1923.
46. Ross, M.W., Ford, T.S., Orsini, P.G., *Incomplete longitudinal fracture of the proximal palmar cortex of the third metacarpal bone in horses*. Vet. Surg., 1988. 17(2): p. 82–86.
47. Ross, M.W., Martin, B.B., *Dorsomedial articular fracture of the proximal aspect of the third metacarpal bone in Standardbred racehorses: seven cases (1978–1990)*. J. Amer. Vet. Med. Assoc., 1992. 201(2): p. 332–335.
48. Booth, T.M., *Proximal suspensory ligament desmitis with suspensory ligament avulsion fractures*. Equine Vet. Educ., 2003. 15(3): p. 132–133.
49. Bramlage, L.R., Gabel, A.A., Hackett, R.P., *Avulsion fractures of the origin of the suspensory ligament of the horse*. J. Amer. Vet. Med. Assoc., 1980. 176(10): p. 1004–1010.
50. Launois, T., Desbrosse, F., Perrin, R., *Percutaneous osteostixis as treatment for avulsion fractures of the palmar/plantar third metacarpal/metatarsal bone cortex at the origin of the suspensory ligament in 29 cases*. Equine Vet. Educ., 2003. 15(3): p. 126–131.
51. Grondahl, A.M., *The incidence of bony fragments and osteochondrosis in the metacarpal- and metatarsophalangeal joints of Standardbred trotters*. J. Equine Vet. Sci., 1992. 12(2): p. 81–85.
52. Yovich, J.V., McIlwraith, C.W., Stashak, T.S., *Osteochondritis dissecans of the sagittal ridge of the third metacarpal and metatarsal bones in horses*. J. Amer. Vet. Med. Assoc., 1985. 186(11): p. 1186–1191.
53. Wissdorf, H., Otto, B., Hertsch, B., Keller, H., Stadtbäumer, G., *Schultergliedmaße – Fesselgelenkbereich/Vordermittelfußbereich*. 2 ed. Anatomie und Propädeutik des Pferdes, ed. H. Wissdorf, Gerhards H., Huskamp, B., Deegen, E. 2002, Hannover: Verlag M. u. H. Schaper Alfeld. 412–413, 426, 431.
54. Bramlage, L.R., Bukowiecki, C.W., Gabel, A.A., *The effect of training on the suspensory apparatus of the horse*. Proc. Am. Assoc. Equine Pract., 1989. 35: p. 245–247.
55. Verschooten, F., Gasthuys, F., de Moor, A., *Distal splint bone fractures in the horse: an experimental and clinical study*. Equine Vet. J., 1984. 16(6): p. 532–536.
56. Allen, D., White, A., *Management of fractures and exostosis of the metacarpals and metatarsals II and IV in 25 horses*. Equine Vet. J., 1987. 19: p. 326–330.
57. Barber, S.M., Caron, J.P., Pharr, J.W., *Surgical removal of metacarpal/metatarsal exostosis*. Proc. Am. Assoc. Equine Pract., 1986. 32: p. 371–383.
58. Keune, C., Grenz, G., Keller, H., *Metacarpale Exostosen als Lahmheitsursache des Pferdes und eine Möglichkeit ihrer operativen Behandlung*. Pferdeheilkunde, 1997. 13(2): p. 117–127.
59. Holcombe, S.J., Schneider, R.K., Bramlage, L.R., Gabel, A.A., Bertone, A.L., Beard, W.L., *Lag screw fixation of noncomminuted sagittal fractures of the proximal phalanx in racehorses: 59 cases (1973–1991)*. J. Amer. Vet. Med. Assoc., 1995. 206(8): p. 1195–1199.

60. Markel, M.D., Richardson, D.W., *Noncommittuted fractures of the proximal phalanx in 69 horses*. J. Amer. Vet. Med. Assoc., 1985. 186(6): p. 573–582.
61. Fortier, L.A., Foerner, J.J., Nixon, A.J., *Arthroscopic removal of axial osteochondral fragments of the plantar/palmar proximal aspect of the proximal phalanx in horses: 119 cases (1988–1992)*. J. Amer. Vet. Med. Assoc., 1995. 206(1): p. 71–74.
62. Sandgren, B., *Bony fragments in the tarsocrural and metacarpo- or metatarsophalangeal joints in the Standardbred horse – a radiographic survey*. Equine Vet. J., 1988. 6 (Suppl.): p. 66–70.
63. Dalin, G., Sandgren, B., Carlsten, J., *Plantar osteochondral fragments in the metatarsophalangeal joints in Standardbred trotters; result of osteochondrosis or trauma?* Equine Vet. J., 1993. 16 (Suppl.): p. 62–65.
64. Nixon, A.J., Pool, R.R., *Histologic appearance of axial osteochondral fragments from the proximoplantar/proximopalmar aspect of the proximal phalanx in horses*. J. Amer. Vet. Med. Assoc., 1995. 207(8): p. 1076–1080.
65. Sandgren, B., Dalin, G., Carlsten, J., *Osteochondrosis in the tarsocrural joint and osteochondral fragments in the fetlock joints in Standardbred trotters. I. Epidemiology*. Equine Vet. J., 1993. 16 (Suppl.): p. 31–37.
66. Bukowiecki, C.F., Bramlage, L.R., Gabel, A.A., *Palmar/plantar process fractures of the proximal phalanx in 15 horses*. Vet. Surg., 1986. 15(5): p. 383–388.
67. Colon, J.L., Bramlage, L.R., Hance, S.R., Embertson, R.M., *Qualitative and quantitative documentation of the racing performance of 461 Thoroughbred racehorses after arthroscopic removal of dorsoproximal first phalanx osteochondral fractures (1986–1995)*. Equine Vet. J., 2000. 32(6): p. 475–481.
68. Kawcak, C.E., McIlwraith, C.W., *Proximodorsal first phalanx osteochondral chip fragmentation in 336 horses*. Equine Vet. J., 1994. 26(5): p. 392–396.
69. Elce, Y.A., Richardson, D.W., *Arthroscopic removal of dorsoproximal chip fractures of the proximal phalanx in standing horses*. Vet. Surg., 2002. 31(3): p. 195–200.
70. Litzke, L.F., Dietz, O., *Handbuch Pferdepraxis*. 2 ed. Krankheiten an Fesselgelenk und Fessel, ed. O. Dietz, Huskamp B. 1999, Stuttgart: Ferdinand Enke Verlag. 879–900.
71. Rose, P.L., Seeherman, H., O'Callaghan, M., *Computed tomographic evaluation of comminuted middle phalangeal fractures in the horse*. Vet. Radiol. Ultrasound, 1997. 38(6): p. 424–429.
72. Tnibar, M., Auer, J.A., Hmidouch, A., Azrib, R., Bzioui, A., *La transfixation dans le traitement des fractures chez le cheval: cas d'une fracture comminutive de la deuxième phalange*. Pratique Vet. Equine, 1996. 28(4): p. 303–309.
73. Németh, F., Back, W., *The use of walking cast to repair fractures in horses and ponies*. Equine Vet. J., 1991. 23(1): p. 32–36.
74. Scott, E.A., McDole, M., Shires, M.H., *A review of third phalanx fractures in the horse: sixty-five cases*. J. Amer. Vet. Med. Assoc., 1979. 174(12): p. 1337–1343.
75. Honnas, C.M., O'Brien, T.R., Linford, R.L., *Distal phalanx fractures in horses. A survey of 274 horses with radiographic assessment of healing in 36 horses*. Vet. Radiol., 1988. 29(3): p. 98–107.
76. Schneider, J., *Zur Ätiologie und Therapie der Hufbeinfraktur*. Monatsh. Vet. Med., 1987. 42(13): p. 472–475.
77. Johnson, K.A., Smith, F.W., *Axial compression generated by cortical and cancellous lag screws in the equine distal phalanx*. Vet. J., 2003. 166(2): p. 159–163.
78. Hertsch, B., Höppner, S., *Zur Fraktur des Processus extensorius des Hufbeines beim Fohlen*. Pferdeheilkunde, 1998. 14(1): p. 11–18.
79. Hertsch, B., Neuberth, M., *Die isolierte Ossifikation am Hufbeinast des Pferdes – eine differentialdiagnostische Abgrenzung zu Hufbeinastfraktur und Hufknorpelverknöcherung*. Pferdeheilkunde, 1991. 7(3): p. 169–174.
80. Dechant, J.E., Trotter, G.W., Stashak, T.S., Hendrickson, D.A., *Removal of large fragments of the extensor process of the distal phalanx via arthrotomy in horses: 14 cases (1992–1998)*. J. Amer. Vet. Med. Assoc., 2000. 217(9): p. 1351–1355.
81. Haynes, P.F., Adams, O.R., *Internal fixation of fractured extensor process of third phalanx in a horse*. J. Amer. Vet. Med. Assoc., 1974. 164: p. 61–63.
82. Budras, K.D., Patan, B., Schiel, C., *Entwicklung und Struktur des verhornten Sohlensporns samt Sohlenrandeinkerbung (Crena) des Hufbeins sowie der Hornsäule samt Hufbeinrinne (Usur)*. Tierärztl. Monatsschr. Wien., 1998. 85(11): p. 369–376.
83. Smallwood, J.E., Albright, S.M., Metcalf, M.R., Thral, D.E., Harrington, B.D., *A xeroradiographic study of the developing equine foredigit and metacarpophalangeal region from birth to six months of age*. Vet. Radiol., 1989. 30(3): p. 98–110.
84. Melo E Silva, S.R.A., Vulcano, L.C., *Collateral cartilage ossification of the distal phalanx in the Brazilian Jumper horse*. Vet. Radiol. Ultrasound, 2002. 43(5): p. 461–463.
85. Verschooten, F., van Waerebeek, B., Verbeeck, J., *The ossification of cartilages of the distal phalanx in the horse: an anatomical, experimental, radiographic and clinical study*. J. Equine Vet. Sci., 1996. 16(7): p. 291–305.
86. Honnas, C.M., Ragle, C.A., Meagher, D.M., *Necrosis of the collateral cartilage of the distal phalanx in horses: 16 cases (1970–1985)*. J. Amer. Vet. Med. Assoc., 1988. 193(10): p. 1303–1307.
87. Hill, A.E., Stover, S.M., Gardner, I.A., Kane, A.J., Whitcomb, M.B., Emerson, A.G., *Risk factors for and outcomes of noncatastrophic suspensory apparatus injury in Thoroughbred racehorses*. J. Amer. Vet. Med. Assoc., 2001. 218(7): p. 1136–1144.
88. Honnas, C.M., Snyder, J.R., Meagher, D.M., Ragle, C.A., *Traumatic disruption of the suspensory apparatus in foals*. Cornell Vet., 1990. 80(2): p. 123–133.
89. Parente, E.J., Richardson, D.W., Spencer, P., *Basal sesamoid fractures in horses: 57 cases (1980–1991)*. J. Amer. Vet. Med. Assoc., 1993. 202(8): p. 1293–1297.
90. Torre, F., Motta, M., *Incidence and distribution of 369 proximal sesamoid bone fractures in 354 standardbred horses (1984–1995)*. Equine Pract., 1999. 21(8): p. 6–12.
91. Henninger, R.W., Bramlage, L.R., Schneider, R.K., Gabel, A.A., *Lag screw and cancellous bone grafts fixation of transverse proximal sesamoid bone fractures in horses: 25 cases (1983–1989)*. J. Amer. Vet. Med. Assoc., 1991. 199(5): p. 606–612.
92. Bertone, A.L., *Equine fracture repair*. Fractures of the proximal sesamoid bones., ed. A.J. Nixon. 1996, Philadelphia: W.B. Saunders Company, S. 163–171.
93. Fretz, P.B., Barber, S.M., Bailey, J.V., McKenzie, N.T., *Management of proximal sesamoid bone fractures in the horse*. J. Amer. Vet. Med. Assoc., 1984. 185(3): p. 282–284.
94. Barclay, W.P., Foerner, J.J., Phillips, T.N., *Axial sesamoid injuries associated with lateral condylar fractures in horses*. J. Amer. Vet. Med. Assoc., 1985. 186(3): p. 278–279.
95. Ellis, D.R., *Fractures of the proximal sesamoid bones in thoroughbred foals*. Equine Vet. J., 1979. 11(1): p. 48–52.
96. Southwood, L.L., McIlwraith, C.W., *Arthroscopic removal of fracture fragments involving a portion of the base of the proximal sesamoid bone in horses: 26 cases (1984–1997)*. J. Amer. Vet. Med. Assoc., 2000. 217(2): p. 236–240.
97. Southwood, L.L., McIlwraith, C.W., Trotter, G.W., Stashak, T.S., Baxter, G.M., Hendrickson, D.A., *Arthroscopic removal of apical fractures of the sesamoid bone in horses: 98 cases (1989–1999)*. Proc. Am. Assoc. Equine Pract., 2000. 46: p. 100–101.
98. Woodie, J.B., Ruggles, A.J., Litsky, A.S., *In vitro biomechanical properties of 2 compression fixation methods for midbody proximal sesamoid bone fractures in horses*. Vet. Surg., 2000. 29(4): p. 358–363.
99. Jaugstetter, H., Jacobi, R., Litzke, L.F., Dietz, O., *Perivaskuläre Sympathektomie, eine Therapiemöglichkeit beim Podotrochlose-/Sesamoidose-Syndrom: Eine Übersicht*. Tierärztl. Praxis (G), 2003. 31(1): p. 46–51.
100. Cornelissen, B.P.M., Rijkenhuizen, A.B.M., Barneveld, A., *The arterial shift features in the equine proximal sesamoid bone*. Vet. Quarterly 18 (Suppl.), 1996: p. 110–116.
101. Hardy, J., Marcoux, M., Breton, L., *Clinical relevance of radiographic findings in proximal sesamoid bones of two-year-old Standardbreds in their first year of race training*. J. Amer. Vet. Med. Assoc., 1991. 198(12): p. 2089–2094.
102. Spike-Pierce, D.L., Bramlage, L.R., *Correlation of racing performance with radiographic changes in the proximal sesamoid bones of 487 Thoroughbred yearlings*. Equine Vet. J., 2003. 35: p. 350–353.
103. Poulos, P.W., *Radiographic and histologic assessment of proximal sesamoid bone changes in young and working horses*. Proc. Am. Assoc. Equine Pract., 1988. 34: p. 347–358.
104. Dik, K.J., van den Belt, A.J.M., Enzerink, E., van Weeren, P.R., *The radiographic development of the distal and proximal double contours of the equine navicular bone on dorsoproximal-palmarodistal oblique (upright pedal) radiographs, from age 1 to 11 months*. Equine Vet. J., 2001. 33(1): p. 70–74.
105. Colles, C.M., *How to repair navicular bone fractures in the horse*. Proc. Am. Assoc. Equine Pract., 2001. 47: p. 270–278.
106. Németh, F., Dik, K.J., *Lag screw fixation of sagittal navicular bone fractures in five horses*. Equine Vet. J., 1985. 17(2): p. 137–139.
107. Dietz, O., *Krankheiten des Nervensystems. 1. Nichtinfektiöse Krankheiten*. Handbuch Pferdepraxis, ed. O. Dietz, Huskamp, B. Vol. 2. 1999, Stuttgart: Ferdinand Enke Verlag. 623–636.
108. Dyson, S., *Shoulder lameness in horses: an analysis of 58 suspected cases*. Equine Vet. J., 1986. 18(1): p. 29–36.
109. Duncan, I.D., Schneider, R.K., *Equine suprascapular neuropathy (sweeny): clinical and pathologic observations*. Proc. Am. Assoc. Equine Pract., 1985. 31: p. 415–428.
110. Baumgartner, W., *Applikation von Arzneimitteln und Diagnostika*. 5 ed. Klinische Propädeutik der inneren Krankheiten und Hautkrankheiten der Haus- und Heimtiere., ed. W. Baumgartner. 2002, Berlin: Parey Verlag. 358–361.
111. Wissdorf, H., Otto, B., Hertsch, B., Keller, H., *Schultergliedmaße – Hufbereich*. 2 ed. Anatomie und Propädeutik des Pferdes, ed. H. Wissdorf, Gerhards H., Huskamp, B., Deegen, E. 2002, Hannover: Verlag M. u. H. Schaper. 382, 392.
112. Rijkenhuizen, A.B.M., *Die diagnostischen Anästhesien an der Vordergliedmaße des Pferdes*. Pferdeheilkunde, 2001. 17(4): p. 330–338.
113. Carter, G.K., Hogan, P.M., *Use of Diagnostic Nerve Blocks in Lameness Evaluation*. Proc. Am. Assoc. Equine Pract., 1996. 42: p. 26–32.
114. Bassage II, L.H., Ross, M.W., *Diagnostic Analgesia*. Diagnosis and Management of Lameness in the horse, ed. M.W. Ross, Dyson, S.J. 2003, Philadelphia: Saunders. 93–124.
115. Stanek, C., Girtler, D., *Diagnostische Leitungsanästhesien an der Vorderextremität des Pferdes: ein Vorschlag zur Standardisierung*. Pferdeheilkunde, 2002. 18: p. 617–621.
116. Cornelissen, B.P.M., Rijkenhuizen, A.B.M., Barneveld, A., *The diagnostic nerve block of the sesamoid nerve: desensitised structures and possible clinical applications*. Vet. Quarterly 18 (Suppl.), 1996: p. 97–102.
117. Keg, P.R., Schamhardt, H.C., van Weeren, P.R., Barneveld, A., *The effect of the high palmar nerve block and the ulnar nerve block on lameness provoked by a collagenase-induced tendonitis of the lateral branch of the suspensory ligament*. Vet. Quarterly 18 (Suppl.), 1996. 18 (Suppl.): p. 103–105.

118. Muylle, S., Desmet, P., Simoens, P., Lauwers, H., Vlamincx, L., *Histological study of the innervation of the suspensory ligament of the forelimb of the horse*. Vet. Rec., 1998. 142(22): p. 606–610.
119. Ford, T.S., Ross, M.W., Orsini, P.G., *A comparison of methods for proximal palmar metacarpal analgesia in horses*. Vet. Surg., 1989. 18(2): p. 146–150.
120. Dabareiner, R.M., White, N.A., Sullins, K.E., *Comparison of current techniques for palmar digital neurectomy in horses*. Proc. Am. Assoc. Equine Pract., 1997. 43: p. 231–232.
121. Stashak, T.S., *The foot*. 5 ed. Adams' Lameness in horses., ed. T.S. Stashak. 2002, Baltimore: Lippincott Williams and Wilkins. 664–680, 718–720.
122. Textor, J.A., Nixon, A.J., Fortier, L.A., *Tenoscopic release of the equine carpal canal*. Vet. Surg., 2003. 32(3): p. 278–284.
123. Mackay-Smith, M.P., Cushing, L.S., Leslie, J.A., „Carpal canal“ syndrome in horses. J. Amer. Vet. Med. Assoc., 1972. 160(7): p. 993–997.
124. Dik, K.J., van den Belt, A.J.M., Keg, P.R., *Ultrasonographic evaluation of fetlock annular ligament constriction in the horse*. Equine Vet. J., 1991. 23(4): p. 285–288.
125. Rothlisberger, U., Kaegi, B., Geyer, H., Auer, J.A., *Das Fessel tunnelsyndrom beim Pferd: Literaturübersicht und retrospektive Untersuchung*. Schweiz. Arch. Tierheilk., 2001. 143(6): p. 285–293.
126. Torre, F., Benazzi, C., Potschka, R., *Constriction of the fetlock annular ligament: relationship between clinical and histopathological findings*. Pferdeheilkunde, 1998. 14(6): p. 461–468.
127. Stanek, C., Edinger, H., *Röntgendiagnostik bei der Strikatur des Fesselringbandes bzw. durch das Fesselringband beim Pferd*. Pferdeheilkunde, 1990. 6: p. 125–128.
128. Fortier, L.A., Nixon, A.J., Ducharme, N.G., Mohammed, H.O., Yeager, A., *Tenoscopic examination and proximal annular ligament desmotomy for treatment of equine „complex“ digital sheath tenosynovitis*. Vet. Surg., 1999. 28(6): p. 429–35.
129. Booth, T.M., *Lameness associated with the bicipital bursa in an Arab stallion*. Vet. Rec., 1999. 145(7): p. 194–198.
130. Crabill, M.R., Chaffin, M.K., Schmitz, D.G., *Ultrasonographic morphology of the bicipital tendon and bursa in clinically normal Quarter Horses*. Am. J. Vet. Res., 1995. 56(1): p. 5–10.
131. Estberg, L., Stover, S.M., Gardner, I.A., Johnson, B.J., Case, J.T., Ardans, A., Read, D.H., Anderson, M.L., Barr, B.C., Daft, B.M., Kinde, H., Moore, J., Stoltz, J., Woods, L.W., *Fatal musculoskeletal injuries incurred during racing and training in Thoroughbreds*. J. Amer. Vet. Med. Assoc., 1996. 208(1): p. 92–96.
132. Richardson, D.W., *The metacarpophalangeal joint*. Diagnosis and Management of Lameness in the horse, ed. M.W. Ross, Dyson, S.J. 2003, Philadelphia: Saunders. 348–362.
133. Bowman, K.F., Leitch, M., Nunamaker, D.M., Fackelman, G.E., Tate Jr., L.P., Park, M.I., Boles, C.L., Raker, C.W., *Complications during treatment of traumatic disruption of the suspensory apparatus in Thoroughbred horses*. J. Amer. Vet. Med. Assoc., 1984. 184(6): p. 706–715.
134. Seiferle, E., Frewein, J., *Aktiver Bewegungsapparat, Muskelsystem, Myologia. Bewegungsapparat*. 7 ed. Lehrbuch der Anatomie der Haustiere., ed. R. Nikkel, Schummer, A., Seiferle, E., Frewein, J., Wille, K.-H., Wilkens, H. Vol. Band I. 2001, Berlin: Verlag Paul Parey. 489–492, 515–516, 552–553.
135. Ueltschi, G., *Zur Diagnose von Interosseusläsionen an der Ursprungsstelle*. Pferdeheilkunde, 1989. 5(2): p. 65–69.
136. Denoix, J.M., Crevier, N., Azevedo, C., *Ultrasound examination of the pastern in horses*. Proc. Am. Assoc. Equine Pract., 1991. 37: p. 363–380.
137. Dyson, S.J., Denoix, J.M., *Tendon sheath, and ligament injuries in the pastern*. Vet. Clin. North Am. (Equine Pract.), 1995. 11: p. 217–233.
138. Schneider, R.K., Tucker, R.L., Habegger, S.R., Brown, J., Leathers, C.W., *Desmitis of the straight sesamoid ligament in horses: 9 cases (1995–1997)*. J. Amer. Vet. Med. Assoc., 2003. 222(7): p. 973–977.
139. Ross, M.W., *Surgical Management of Superficial Digital Flexor Tendinitis*. Proc. Am. Assoc. Equine Pract., 1997. 43: p. 291–296.
140. Genovese, R., Longo, K., Berthold, B., Jorgenson, J., *Quantitative sonographic assessment in the clinical management of superficial digital flexor injuries in thoroughbred racehorses*. Proc. Am. Assoc. Equine Pract., 1997. 43: p. 285–290.
141. Gillis, C.L., *Rehabilitation of Tendon and Ligament Injuries*. Proc. Am. Assoc. Equine Pract., 1997. 43: p. 306–309.
142. Smith, R.K.W., Birch, H.L., Patterson-Kane, J., Goodman, S., Cauvin, E.R., Goodship, A.E., *A review of the etiopathogenesis, and current proposed strategies for prevention, of superficial digital flexor tendonitis in the horse*. Proc. Am. Assoc. Equine Pract., 2000. 46: p. 54–58.
143. Mickelthwaite, L., Wood, A.K.W., Sehgal, C.M., Polansky, M., Dowling, B.A., Dart, A.J., Rose, R.J., Hodgson, D.R., *Use of quantitative analysis of sonographic brightness for detection of early healing of tendon injury in horses*. Am. J. Vet. Res., 2001. 62(8): p. 1320–1327.
144. Kasashima, Y., Kuwano, A., Katayama, Y., Taura, Y., Yoshihara, T., *Magnetic resonance imaging application to live horse for diagnosis of tendinitis*. J. Vet. Med. Sci., 2002. 64(7): p. 577–582.
145. Rand, T., Bindeus, T., Alton, K., Voegelé, T., Kukla, C., Stanek, C., Imhof, H., *Low-field magnetic resonance imaging (0.2 T) of tendons with sonographic and histologic correlation. Cadaveric study*. Invest. Radiol., 1998. 33(8): p. 433–438.
146. Dowling, B.A., Dart, A.J., Hodgson, D.R., Smith, R.K.W., *Superficial digital flexor tendonitis in the horse*. Equine Vet. J., 2000. 32(5): p. 369–378.
147. Denoix, J.M., Busoni, V., *Ultrasonographic anatomy of the accessory ligament of the superficial digital flexor tendon in horses*. Equine Vet. J., 1999. 31(3): p. 186–191.
148. Denoix, J.M., Guizien, I., Perrot, P., *Injuries of the accessory ligament of the superficial digital flexor tendon (proximal check ligament) in sport and race horses*. Pferdeheilkunde, 1996. 12: p. 613–616.
149. Southwood, L.L., Stashak, T.S., Kainer, R.A., Wrigley, R.H., *Desmotomy of the accessory ligament of the superficial digital flexor tendon in the horse with use of a tenoscopic approach to the carpal sheath*. Vet. Surg., 1999. 28(2): p. 99–105.
150. Auer, J.A., *Flexural deformities*. 2 ed. Equine surgery, ed. J.A. Auer, Stick, J.A. 1999, Philadelphia: W.B. Saunders Company. 752–765.
151. Dyson, S.J., *Proximal metacarpal and metatarsal pain: a diagnostic challenge*. Equine Vet. Educ., 2003. 15(3): p. 134–138.
152. Adams, S.B., Santschi, E.M., *Management of Congenital and Acquired Flexural Limb Deformities*. Proc. Am. Assoc. Equine Pract., 2000. 46: p. 117–125.
153. Köhler, M., *Therapie des Sehnenstellsfußes bei Fohlen und wachsenden Pferden*. Tierärztl. Praxis, 2002. 30 (G): p. 51–57.
154. Hunt, R.J., *Flexural Limb Deformity in Foals*. Diagnosis and Management of Lameness in the horse, ed. M.W. Ross, Dyson, S.J. 2003, Philadelphia: Saunders. 562–565.
155. Hertsch, B., *Zur Pathogenese des Strahlbeinsyndroms*. Swiss Vet., 1993. 11(Suppl.): p. 127–130.
156. Rijkenhuizen, A.B.M., *Die arterielle Blutgefäßversorgung des Strahlbeins und ihre Beziehung zur Podotrochlose*. Pferdeheilkunde, 1990. 6: p. 253–260.
157. Hertsch, B., Höppner, S., *Zur Diagnostik des Podotrochlose-Syndroms in der Praxis*. Pferdeheilkunde, 1999. 15(4): p. 293–308.
158. Seyrek-Intas, D., Tellhelm, B., Reckels, F.J., *Interpretation und diagnostischer Wert verschiedener Röntgenbefunde am Strahlbein*. Pferdeheilkunde, 1999. 15(5): p. 406–418.
159. Wright, I.M., Kidd, L., Thorp, B.H., Gross, *histological and histomorphometric features of the navicular bone and related structures in the horse*. Equine Vet. J., 1998. 30(3): p. 220–234.
160. Clercq de, T., Verschooten, F., Ysebaert, M., *A comparison of the palmaro-proximal-palmarodistal view of the isolated navicular bone to other views*. Vet. Radiol. Ultrasound, 2000. 41(6): p. 525–533.
161. Ueltschi, G., *Zur Röntgendiagnostik des Strahlbeins*. Pferdeheilkunde, 2002. 18(3): p. 217–224.
162. Busoni, V., Denoix, J.M., *Ultrasonography of the podotrochlear apparatus in the horse using a transcutaneous approach: technique and reference images*. Vet. Radiol. Ultrasound, 2001. 42(6): p. 534–540.
163. Ueltschi, G., *Stellenwert der Knochenszintigraphie und der Röntgenuntersuchung beim Problemkreis der Podotrochlose*. Pferdeheilkunde, 1999. 15(2): p. 122–128.
164. Mair, T.S., Kinns, J., Jones, R.D., Bolas, N.M., *Magnetic resonance imaging of the distal limb of the standing horse: Technique and review of 40 cases of foot lameness*. Proc. Am. Assoc. Equine Pract., 2003. 49: p. 29–41.
165. Ruohoniemi, M., Tervahartiala, P., *Computed tomographic evaluation of Finn horse cadaver forefeet with radiographically problematic findings on the flexor aspect of the navicular bone*. Vet. Radiol. Ultrasound, 1999. 40(3): p. 275–281.
166. Widmer, W.R., Buckwalter, K.A., Fessler, J.F., Hill, M.A., van Sickle, D.C., Ivancevich, S., *Use of radiography, computed tomography and magnetic resonance imaging for evaluation of navicular syndrome in the horse*. Vet. Radiol. Ultrasound, 2000. 41(2): p. 108–116.
167. Denoix, J.M., Thibaud, D., Riccio, B., *Tiludronate as a new therapeutic agent in the treatment of navicular disease: a double-blind placebo-controlled clinical trial*. Equine Vet. J., 2003. 35(4): p. 407–413.
168. Turner, A.S., Tucker, C.M., *Die Wirkung von Isoxsuprinhydrchlorid bei der Behandlung der Hufrollenerkrankung: Eine Blindstudie*. Pferdeheilkunde, 1990. 6(2): p. 11–15.
169. Willemen, M.A., Savelberg, H.H.C.M., Barneveld, A., *The effect of orthopaedic shoeing on the force exerted by the deep digital flexor tendon on the navicular bone in horses*. Equine Vet. J., 1999. 31(1): p. 25–30.
170. Bar, K., Weiler, M., Bodamer, J., Rupprecht, H., Schramm, M., Carbon, R., *Extrakorporale Stosswellentherapie (ESWT) – eine Möglichkeit zur Therapie der Podotrochlose*. Tierärztl. Praxis, 2001. 29(3): p. 163–167.
171. Grenz, G., Eversfield, S., *Beschreibung einer Operationsmethode zur Behandlung der Podotrochlose des Pferdes*. Prakt. Tierarzt, 1985. 66: p. 221–223.
172. Wright, I.M., *A study of 118 cases of navicular disease: treatment by navicular suspensory desmotomy*. Equine Vet. J., 1993. 25(6): p. 501–509.
173. Doyle, P.S., White, N.A., *Diagnostic findings and prognosis following arthroscopic treatment of subtle osteochondral lesions in the shoulder joint of horses: 15 cases (1996–1999)*. J. Amer. Vet. Med. Assoc., 2000. 217(12): p. 1878–1882.
174. Boswell, J.C., Schramme, M.C., Wilson, A.M., May, S.A., *Radiological study to evaluate suspected scapulohumeral joint dysplasia in Shetland ponies*. Equine Vet. J., 1999. 31(6): p. 510–514.
175. Clegg, P.D., Dyson, S.J., Summerhays, G.E.S., Schramme, M.C., *Scapulohumeral osteoarthritis in 20 Shetland ponies, miniature horses and falabella ponies*. Vet. Rec., 2001. 148(6): p. 175–179.
176. Nickel, R., Schummer, A., Wille, K.H., Wilkens, H., *Passiver Bewegungsapparat, Skelettsystem: Bänderlehre, Syndesmologia*. 7 ed. Lehrbuch der Anatomie der Haustiere, ed. R. Nickel, Schummer, A., Seiferle, E., Frewein, J., Wille, K.-H., Wilkens, H. Vol. 1. 2001, Berlin: Verlag Paul Parey. 258–260, 263–268.
177. Lewis, R.D., *Techniques for arthrocentesis of equine shoulder, elbow, stifle, and hip joint*. Proc. Am. Assoc. Equine Pract., 1996. 42: p. 55–63.
178. Bertone, A.L., McIlwraith, C.W., *Osteochondrose of the equine shoulder: Treatment with arthroscopic surgery*. Proc. Am. Assoc. Equine Pract., 1987. 33: p. 683–688.

179. McIlwraith, C.W., *Diagnostic and surgical arthroscopy in the horse*. 2 ed. 1990, Philadelphia: Lea and Febiger. 22, 33–43, 85–90, 113–158, 195–202, 220–221.
180. Bertone, A.L., McIlwraith, C.W., Powers, B.E., Stashak, T.S., Aanes, W.A., Turner, A.S., *Subchondral osseous cystic lesions of the elbow of horses: conservative versus surgical treatment*. J. Amer. Vet. Med. Assoc., 1986. 189(5): p. 540–546.
181. Hoppen, L.A., Colahan, P.T., Turner, T.A., Nixon, A.J., *Nonsurgical treatment of cubital subchondral cyst-like lesions in horses: seven cases (1983–1987)*. J. Amer. Vet. Med. Assoc., 1992. 200(4): p. 527–530.
182. McIlwraith, C.W., *Subchondral cystic lesions in the horse – the indications, methods and results of surgery*. Equine Vet. Educ., 1990. 2(2): p. 75–80.
183. Sams, A.E., Honnas, C.M., Sack, W.O., Ford, T.S., *Communication of the ulnar lateral bursa with the equine elbow joint and evaluation of caudal arthrocentesis*. Equine Vet. J., 1993. 25(2): p. 130–133.
184. Rose, R.J., Frauenthal, H.C., *Arthrocentesis in the horse*. Equine Vet. J., 1982. 14(2): p. 173–177.
185. Nixon, A.J., *Arthroscopic approaches and intraarticular anatomy of the equine elbow*. Vet. Surg., 1990. 19(2): p. 93–101.
186. Bowker, R.M., van Wulpen, K., Perry, R.L., Linder, K.L., *Anatomy of the equine synovial joint cavities of the forelimb and the hindlimb*. Proc. Am. Assoc. Equine Pract., 1996. 42: p. 33–47.
187. Ford, T.S., Ross, M.W., Orsini, P.G., *Communications and boundaries of the middle carpal and carpometacarpal joints in horses*. Am. J. Vet. Res., 1988. 49(12): p. 2161–2164.
188. Moyer, W., Carter, G.K., *Techniques to facilitate intra-articular injection of equine joints*. Proc. Am. Assoc. Equine Pract., 1996. 42: p. 48–54.
189. Gough, M.R., Mayhew, G., Munroe, G.A., *Diffusion of mepivacaine between adjacent synovial structures in the horse. Part 1: Forelimb foot and carpus*. Equine Vet. J., 2002. 34(1): p. 80–84.
190. McIlwraith, C.W., Robertson, J.T., *McIlwraith and Turner's equine surgery: advanced techniques*. 2 ed. 1998, Baltimore: Williams and Wilkins. 150–174.
191. Wilke, M., Nixon, A.J., Malark, J., Myhre, G., *Fractures of the palmar aspect of the carpal bones in horses: 10 cases (1984–2000)*. J. Amer. Vet. Med. Assoc., 2001. 219(6): p. 801–804.
192. Denoix, J.M., Jacot, S., Bousseau, B., Perrot, P., *Ultrasonographic anatomy of the dorsal and abaxial aspects of the equine fetlock*. Equine Vet. J., 1996. 28(1): p. 54–62.
193. Yovich, J.V., Turner, A.S., Stashak, T.S., McIlwraith, C.W., *Luxation of the metacarpophalangeal and metatarsophalangeal joints in horses*. Equine Vet. J., 1987. 19(4): p. 295–298.
194. van Kruiningen, H.J., *Practical techniques for making injections into joints and bursae of the horse*. J. Amer. Vet. Med. Assoc., 1963. 143: p. 1079–1083.
195. Misheff, M.M., Stover, S.M., *A comparison of two techniques for arthrocentesis of the equine metacarpophalangeal joint*. Equine Vet. J., 1991. 23(4): p. 273–276.
196. Hogan, P.M., McIlwraith, C.W., Honnas, C.M., Watkins, J.P., Bramlage, L.R., *Surgical treatment of subchondral cystic lesions of the third metacarpal bone: results in 15 horses (1986–1994)*. Equine Vet. J., 1997. 29(6): p. 477–482.
197. Kold, S., Hickman, J., *Three cases of subchondral bone cysts in the distal limb of the horse treated by bone grafting via an extra-articular approach*. Equine Vet. Educ., 1990. 2(2): p. 70–74.
198. Dabareiner, R.M., White, N.A., Sullins, K.E., *Metacarpophalangeal joint synovial pad fibrotic proliferation in 63 horses*. Vet. Surg., 1996. 25(3): p. 199–206.
199. Kannegieter, N.J., *Chronic proliferative synovitis of the equine metacarpophalangeal joint*. Vet. Rec., 1990. 127(1): p. 8–10.
200. Mosimann, W., *Über die Bewegungsmöglichkeit in den Zehengelenken des Pferdes*. Schweizer Archiv Tierheilk., 1958. 100: p. 7–14.
201. Miller, S.M., Stover, S.M., Taylor, K.T., Zarucco, L.A., *Palmaroproximal approach for arthrocentesis of the proximal interphalangeal joint in horses*. Equine Vet. J., 1996. 28(5): p. 376–380.
202. Caron, J.P., Fretz, P.B., Bailey, J.V., Barber, S.M., *Proximal interphalangeal arthrodesis in the horse a retrospective study and a modified screw technique*. Vet. Surg., 1990. 19(3): p. 196–202.
203. Schaer, T.P., Bramlage, L.R., Embertson, R.M., Hance, S., *Proximal interphalangeal arthrodesis in 22 horses*. Equine Vet. J., 2001. 33(4): p. 360–365.
204. Fleig, J., Hertsch, B., *Zur Differenzierung von Huf- und Kronengelenkschale beim Pferd unter besonderer Berücksichtigung der röntgenologischen Untersuchung*. Pferdeheilkunde, 1992. 8(2): p. 63–76.
205. MacLellan, K.N.M., Crawford, W.H., MacDonald, D.G., *Proximal interphalangeal joint arthrodesis in 34 horses using two parallel 5.5-mm cortical bone screws*. Vet. Surg., 2001. 30(5): p. 454–459.
206. Watt, B.C., Edwards III, R.B., Markel, M.D., McCabe, R., Wilson, D.G., *Arthrodesis of the equine proximal interphalangeal joint: a biomechanical comparison of two 7-hole 3.5-mm broad and two 5-hole 4.5-mm narrow dynamic compression plates*. Vet. Surg., 2002. 31(1): p. 85–93.
207. Denoix, J.M., *Functional anatomy of the equine interphalangeal joints*. Proc. Am. Assoc. Equine Pract., 1999. 45: p. 174–177.
208. Knezevic, P., *Hufabszess, Steingallen. Therapie und Prognose*. Tierärztl. Praxis, 1975. 3(2): p. 205–214.
209. Mercado de, R.V., Stover, S.M., Taylor, K.T., Zarucco, L., Willits, N.H., *Lateral approach for arthrocentesis of the distal interphalangeal joint in horses*. J. Amer. Vet. Med. Assoc., 1998. 212(9): p. 1413–1418.
210. Bowker, R.M., Rockershouer, S.J., Vex, K.B., Sonea, I.M., Caron, J.P., Kotyk, R., *Immunocytochemical and dye distribution studies of nerves potentially desensitized by injections into the distal interphalangeal joint or the navicular bursa of horses*. J. Amer. Vet. Med. Assoc., 1993. 203(12): p. 1708–1714.
211. Keegan, K.G., Wilson, D.A., Kreeger, J.M., Ellersieck, M.R., Kuo, K.C., Li, Z., *Local distribution of mepivacaine after distal interphalangeal joint injection in horses*. Am. J. Vet. Res., 1996. 57(4): p. 422–426.
212. Sardari, K., Kazemi, H., Mohri, M., *Effects of analgesia of the distal interphalangeal joint and navicular bursa on experimental lameness caused by solar pain in horses*. J. Vet. Med. A, 2002. 49(9): p. 478–481.
213. Schumacher, J., Steiger, R., Schumacher, J., de Graves, F., Schramme, M., Smith, R., Coker, M., *Effects of analgesia of the distal interphalangeal joint or palmar digital nerves on lameness caused by solar pain in horses*. Vet. Surg., 2000. 29(1): p. 54–58.
214. Boening, K.J., von Saldern, F.Ch., Leendertse, I., Rahlenbeck, F., *Diagnostische und operative Arthroskopie am Hufgelenk des Pferdes*. Pferdeheilkunde, 1988. 4(4): p. 155–160.
215. Haack, D., Hertsch, B., Baez, C., *Zystoide Defekte im Hufbein des Pferdes*. Pferdeheilkunde, 1988. 4(4): p. 143–153.
216. Verschooten, F., de Moor, A., *Subchondral cystic and related lesions affecting the equine pedal bone and stifle*. Equine Vet. J., 1982. 14(1): p. 47–54.
217. Adams, M.N., Turner, T.A., *Endoscopy of the intertubercular bursa in horses*. J. Amer. Vet. Med. Assoc., 1999. 214(2): p. 221–225.
218. Wintzer, H.-J., *Krankheiten des Pferdes. Ein Leitfaden für Studium und Praxis*. 1999, Berlin: Verlag Paul Parey. 376.
219. Schramme, M.C., Boswell, J.C., Hamhougias, K., Toulson, K., Viitanen, M., *An in vitro study to compare 5 different techniques for injection of the navicular bursa in the horse*. Equine Vet. J., 2000. 32(3): p. 263–267.
220. Schumacher, J., Schumacher, J., Gillette, R., de Graves, F., Schramme, M., Smith, R., Perkins, J., Coker, M., *The effects of local anaesthetic solution in the navicular bursa of horses with lameness caused by distal interphalangeal joint pain*. Equine Vet. J., 2003. 35(5): p. 502–505.
221. Wright, I.M., Phillips, T.J., Walmsley, J.P., *Endoscopy of the navicular bursa: A new technique for the treatment of contaminated and septic bursae*. Equine Vet. J., 1999. 31(1): p. 5–11.
222. Southwood, L.L., Stashak, T.S., Kainer, R.A., *Tenoscopic anatomy of the equine carpal flexor synovial sheath*. Vet. Surg., 1998. 27: p. 150–157.
223. Nixon, A.J., Schachter, B.L., Pool, R.R., *Exostoses of the caudal perimeter of the radial physis as a cause of carpal synovial sheath tenosynovitis and lameness in horses: 10 cases (1999–2003)*. J. Amer. Vet. Med. Assoc., 2004. 224(2): p. 264–270.
224. König, H.E., Breit, S., Schleip, D., *Zur Anatomie der Fesselbeugegelenkschleimhaut des Pferdes*. Wien. Tierärztl. Monatsschr., 1995. 82(1): p. 10–15.
225. Wilderjans, H., Boussauw, B., Madder, K., Simon, O., *Tenosynovitis of the digital flexor tendon sheath and annular ligament constriction syndrome caused by longitudinal tears in the deep digital flexor tendon: a clinical and surgical report of 17 cases in Warmblood horses*. Equine Vet. J., 2003. 35(3): p. 270–275.
226. Neumeier, W., Waibl, H., Meyer, W., *Topographie und Struktur des Vinculum tendinis in der Fesselbeugegelenkschleimhaut des Pferdes*. Pferdeheilkunde, 2004. 20: p. 37–41.
227. Hassel, D.M., Stover, S.M., Yarbrough, T.B., Drake, C.M., Taylor, K.T., *Palmar-plantar axial sesamoid approach to the digital flexor tendon sheath in horses*. J. Amer. Vet. Med. Assoc., 2000. 217(9): p. 1343–1347.
228. Edinger, J.K., *Correlation between tenoscopic and ultrasonographic findings of the digital flexor tendon sheath in horses*. Proc. Europ. College Vet. Surg., 2002. 11: p. 183–184.
229. Nixon, A.J., *Endoscopy of the digital flexor tendon sheath in horses*. Vet. Surg., 1990. 19(4): p. 266–271.

Pelvic Limb

230. Nowak, M., Tietje, S., *Krankheiten der Kreuzbeinregion und des Beckens*. 2 ed. Handbuch Pferdepraxis., ed. O. Dietz, Huskamp, B. 1999, Stuttgart: Ferdinand Enke Verlag. 770–776.
231. Dyson, S.J., *Lameness associated with the stifle and pelvic regions*. Proc. Am. Assoc. Equine Pract., 2002. 48: p. 387–411.
232. Hance, S.R., Bramlage, L.R., Schneider, R.K., Embertson, R.M., *Retrospective study of 38 cases of femur fractures in horses less than one year of age*. Equine Vet. J., 1992. 24(5): p. 357–363.
233. Blikslager, A.T., Bristol, D.G., *Avulsion of the origin of the peroneus tertius tendon in a foal*. J. Am. Vet. Med. Assoc., 1994. 204(9): p. 1483–1485.
234. Holcombe, S.J., Bertone, A.L., *Avulsion fracture of the origin of the extensor digitorum longus muscle in a foal*. J. Am. Vet. Med. Assoc., 1994. 204(10): p. 1652–1654.
235. Dyson, S., Wright, I., Kold, S., Vatisas, N., *Clinical and radiographic features, treatment and outcome in 15 horses with fracture of the medial aspect of the patella*. Equine Vet. J., 1992. 24(4): p. 264–268.
236. Marble, G.P., Sullins, K.E., *Arthroscopic removal of patellar fracture fragments in horses: five cases (1989–1998)*. J. Am. Vet. Med. Assoc., 2000. 216: p. 1799–1801.
237. Hunt, R.J., Baxter, G.M., Zamos, D.T., *Tension-band wiring and lag screw fixation of a transverse, comminuted fracture of a patella in a horse*. J. Am. Vet. Med. Assoc., 1992. 200(6): p. 819–820.
238. Ruggles, A.J., Moore, R.M., Bertone, A.L., Schneider, R.K., Bailey, M.Q., *Tibial stress fractures in racing standardbreds: 13 cases (1989–1993)*. J. Am. Vet. Med. Assoc., 1996. 209(3): p. 634–637.
239. Wright, I.M., *Fractures of the lateral malleolus of the tibia in 16 horses*. Equine Vet. J., 1992. 24(6): p. 424–429.

240. Mueller, P.O., Allen, D., Watson, E., Hay, C., *Arthroscopic removal of a fragment from an intercondylar eminence fracture of the tibia in a two-year-old horse*. J. Am. Vet. Med. Assoc., 1994. 204(11): p. 1793–1795.
241. Walmsley, J.P., *Fracture of the intercondylar eminence of the tibia treated by arthroscopic internal fixation*. Equine Vet. J., 1997. 29(2): p. 148–150.
242. Arnold, C.E., Schaer, T.P., Baird, D.L., Martin, B.B., *Conservative management of 17 horses with nonarticular fractures of the tibial tuberosity*. Equine Vet. J., 2003. 35(2): p. 202–206.
243. Wright, I.M., Montesso, F., Kidd, L.J., *Surgical treatment of fractures of the tibial tuberosity in 6 adult horses*. Equine Vet. J., 1995. 27(2): p. 96–102.
244. Dyson, S., *Proximal suspensory desmitis in the forelimb and the hindlimb*. Proc. Am. Assoc. Equine Pract., 2000. 46: p. 137–142.
245. Dutton, D.M., Watkins, J.P., Walker, M.A., Honnas, C.M., *Incomplete ossification of the tarsal bones in foals: 22 cases (1988–1996)*. J. Am. Vet. Med. Assoc., 1998. 213(11): p. 1590–1594.
246. Lindsay, W.A., McMartin, R.B., McClure, J.R., *Management of slab fractures of the third tarsal bone in 5 horses*. Equine Vet. J., 1982. 14(1): p. 55–58.
247. Winberg, F.G., Pettersson, H., *Outcome and racing performance after internal fixation of third and central tarsal bone slab fractures in horses: a review of 20 cases*. Acta Vet. Scand., 1999. 40(2): p. 173–180.
248. Murphy, E.D., Schneider, R.K., Adams, S.B., Santschi, E.M., Stick, J.A., Rugles, A.J., *Long-term outcome of horses with a slab fracture of the central or third tarsal bone treated conservatively: 25 cases (1976–1993)*. J. Am. Vet. Med. Assoc., 2000. 216(12): p. 1949–1954.
249. Baird, D.H., Pilsworth, R.C., *Wedge-shaped conformation of the dorsolateral aspect of the third tarsal bone in the Thoroughbred racehorse is associated with development of slab fractures in this site*. Equine Vet. J., 2001. 33(6): p. 617–620.
250. Kane, A.J., Park, R.D., McIlwraith, C.W., Rantanen, N.W., Morehead, J.P., Bramlage, L.R., *Radiographic changes in Thoroughbred yearlings. Part 1: Prevalence at the time of the yearling sales*. Equine Vet. J., 2003. 35(4): p. 354–365.
251. Jakovljevic, S., Gibbs, C., Yeats, J.J., *Traumatic fractures of the equine hock: a report of 13 cases*. Equine Vet. J., 1982. 14(1): p. 62–68.
252. Hammer, E.J., Ross, M.W., Parente, E.J., *Incomplete sagittal fractures of the talus in 11 racehorses*. Proc. Am. Assoc. Equine Pract., 1999. 45: p. 162–163.
253. Roethlisberger, R., Ueltschi, G., *Ein Beitrag zur radiologischen Untersuchung am krankhaft veränderten Sprunggelenk des Pferdes*. Pferdeheilkunde, 1989. 5(4): p. 181–189.
254. Churchill, E.A., *The diagnosis and treatment of lameness of the pelvic limb*. Proc. Am. Assoc. Equine Pract., 1987. 33: p. 849–854.
255. Adams, O.R., *Fibrotic myopathy and ossifying myopathy in the hindlegs of horses*. J. Am. Vet. Med. Assoc., 1961. 139(10): p. 1089–1092.
256. Magee, A.A., Vatisstas, N.J., *Standing semitendinosus myotomy for the treatment of fibrotic myopathy in 39 horses (1989–1997)*. Proc. Am. Assoc. Equine Pract., 1998. 44: p. 263–264.
257. Gomez-Villamandos, R., Santisteban, J., Ruiz, I., Avila, I., *Tenotomy of the tibial insertion of the semitendinosus muscle of two horses with fibrotic myopathy*. Vet. Rec., 1995. 136(3): p. 67–68.
258. Turner, A.S., Trotter, G.W., *Fibrotic myopathy in the horse*. J. Am. Vet. Med. Assoc., 1984. 184(3): p. 335–338.
259. Valentine, B.A., Rousselle, S.D., Sams, A.E., Edwards, R.B., *Denervation atrophy in three horses with fibrotic myopathy*. J. Am. Vet. Med. Assoc., 1994. 205(2): p. 332–336.
260. Clayton, H.M., *Cinematographic analysis of the gait of lame horses. V: Fibrotic myopathy*. J. Equine Vet. Sci., 1988. 8(4): p. 297–301.
261. Pickersgill, C.H., Kriz, N., Malikides, N., *Surgical treatment of semitendinosus fibrotic myopathy in an endurance horse – management, complications and outcome*. Equine Vet. Educ., 2000. 12(5): p. 242–246.
262. Nixon, A.J., *Luxation of the superficial flexor tendon at the calcaneal tuber*. Current practice of equine surgery, ed. N.A.I. White, Moore, J.N. 1990, Philadelphia: J.B. Lippincott Company. 465–466.
263. Scott, E.A., Breuhäus, B., Gertsen, K.E., *Surgical repair of dislocated superficial digital flexor tendon in a horse*. J. Am. Vet. Med. Assoc., 1982. 181(2): p. 171–172.
264. Bogner, B., Böck, P., Stanek, Ch., *Korrelation radiologischer Befunde und histologische Veränderungen an der medialen Endsehne und der Bursa subtendinea des M. tibialis cranialis bei der Späterkrankung des Pferdes*. Pferdeheilkunde, 1998. 14(3): p. 197–204.
265. Crabill, M.R., Honnas, C.M., Taylor, D.S., Schumacher, J., Watkins, J.P., Snyder, J.R., *Stringhalt secondary to trauma to the dorsoproximal region of the metatarsus in horses: 10 cases (1986–1991)*. J. Am. Vet. Med. Assoc., 1994. 205(6): p. 867–869.
266. Gay, C.C., Fransen, S., Richards, J., Holler, S., *Hypochoeris-associated stringhalt in North America*. Equine Vet. J., 1993. 25(5): p. 456–457.
267. Huntington, P.J., Jeffcott, L.B., Friend, S.C.E., Luff, A.R., Finkelstein, D.I., Flynn, R.J., *Australian stringhalt – epidemiological, clinical and neurological investigations*. Equine Vet. J., 1989. 21(4): p. 266–273.
268. Gerhards, H., Rosenbruch, M., *Intermittierendes Hinken beim Pferd – Diskussion ätiologischer und therapeutischer Aspekte an Hand eines Fallbeispiels*. Prakt. Tierarzt, 1984. 65(8): p. 645–654.
269. Edwards, G.B., Allen, W.E., *Aorto-iliac thrombosis in two horses: clinical course of the disease and use of real-time ultrasonography to confirm diagnosis*. Equine Vet. J., 1988. 20(5): p. 384–387.
270. Brama, P.A.J., Rijkenhuizen, A.B.M., van Swieten, H.A., Warmerdam, E.P.L., *Thrombosis of the aorta and the caudal arteries in the horse; additional diagnostics and a new surgical treatment*. Vet. Quarterly, 1996. 18 (Suppl.): p. 85–89.
271. Warmerdam, E.P.L., *Ultrasonography of the femoral artery in six normal horses and three horses with thrombosis*. Vet. Radiol. Ultrasound, 1998. 39(2): p. 137–141.
272. Waibl, H., Wilkens, H., Münster, W., *Arterien am Hinterfuß des Pferdes*. 3 ed. Lehrbuch der Anatomie der Haustiere. Kreislaufsystem. Haut und Hautorgane., ed. R. Nickel, Schummer, A., Seiferle, E., Habermehl, K.-H., Vollmerhaus, B., Wilkens H., Waibl, H. Vol. 3. 1996, Berlin: Verlag Paul Parey. 162.
273. Wissdorf, H., Hertsch, B., Keller, H., Stadtbäumer, G., *Beckengliedmaße: Hintermittelfuß-, Tarsal- und Kniebereich*. 2 ed. Anatomie und Propädeutik des Pferdes, ed. H. Wissdorf, Gerhards H., Huskamp, B., Deegen, E. 2002, Hannover: Verlag M. u. H. Schaper Alfeld. 528, 546, 570.
274. Richardson, D.W., *Fractures of the small metacarpal and metatarsal bones*. Current practice of equine surgery, ed. M. White N.A. II, J.N. 1990, Philadelphia: J.B. Lippincott Company. 636–641.
275. Müller-Kirchenbauer, D., Fürst, A., Geissbühler, U., Kaegi, B., Auer, J., *Die Desmotomie des medialen Kniescheibenbandes zur Therapie der pathologischen proximalen Patellafixation – Eine Studie bei Pferden und Ponys*. Pferdeheilkunde, 2001. 17(3): p. 208–216.
276. Tnibar, A., *Treatment of upward fixation of the patella in the horse: an update*. Equine Vet. Educ., 2003. 15(5): p. 236–242.
277. Jeffcott, L.B., Kold, S.E., *Stifle lameness in the horse: a survey of 86 referred cases*. Equine Vet. J., 1982. 14(1): p. 31–39.
278. Tnibar, M.A., *Medial patellar ligament splitting for the treatment of upward fixation of the patella in 7 equids*. Vet. Surg., 2002. 31(5): p. 462–467.
279. Finocchio, E.J., Guffy, M.M., *Congenital patellar ectopia in a foal*. J. Am. Vet. Med. Assoc., 1970. 156(2): p. 222–223.
280. van Pelt, R.W., Keahey, K.K., Dalley, J.B., *Congenital bilateral patellar ectopia in a foal*. Vet. Med. Small Anim. Clin., 1971. 66(5): p. 445–447.
281. Edinger, H., Stanek, C., *Operative Behandlung einer beidseitigen kongenitalen stationären Luxation der Patella nach lateral bei einem Shetlandfohlen durch Keilosteotomie im Bereich der Trochlea ossis femoris*. Pferdeheilkunde, 1991. 7(4): p. 197–203.
282. Hermans, W.A., Kersjes, A.W., van der Mey, G.J.W., Dik, K.J., *Investigation into the heredity of congenital lateral patellar (sub)luxation in the Shetland pony*. Vet. Quarterly, 1987. 9(1): p. 1–8.
283. Rieland, E., Nowak, M., Toth, J., Neuschäfer, A., *Die chirurgische Behandlung der kongenitalen lateralen Patellaluxation bei Shetlandfohlen mittels einer Teilsteotomie der Femurrolffurche*. Prakt. Tierarzt, 2002. 83(3): p. 246–253.
284. Granacher, A., *Der klinische Fall. Ruptur des Musculus fibularis tertius*. Tierärztl. Praxis, 1994. 22(3): p. 208 u. 295.
285. Leveille, R., Lindsay, W.A., Biller, D.S., *Ultrasonographic appearance of ruptured peroneus tertius in a horse*. J. Am. Vet. Med. Assoc., 1993. 202(12): p. 1981–1982.
286. Cowles, R.R., *Proximal suspensory desmitis – a qualitative survey*. Proc. Am. Assoc. Equine Pract., 2000. 46: p. 143–144.
287. Gibson, K.T., Snyder, J.R., Spier, S.J., *Ultrasonographic diagnosis of soft tissue injuries in horses competing at the Sydney 2000 Olympic Games*. Equine Vet. Educ., 2002. 14(3): p. 149–156.
288. Balch, O., White, K., Butler, D., *Factors involved in the balancing of equine hooves*. J. Am. Vet. Med. Assoc., 1991. 198(11): p. 1980–1989.
- 288a. Spillner, M., Buda, S., Jacobi, R., Jauchstetter, H., Budras, K.-D., *Die perivaskuläre Sympathektomie beim Pferd*. Tierärztl. Prax. 2008, 35G: p. 55–2.

The Hoof

289. Hermans, W.A., *Hufpflege und Hufbeschlag*. 1992, Stuttgart: Verlag Eugen Ulmer. 36–38. 45–50, 185–188.
290. Ruthe, H., Müller, H., Reinhard, F., *Der Huf. Lehrbuch des Hufbeschlages*. 5 ed. 1997, Stuttgart: Ferdinand Enke Verlag. 30–36, 59–61, 177–197.
291. Schnitker, P., *Der Selbstregulationsmechanismus der Huflänge und Hufform beim Przewalskipferd (Equus ferus Przewalskii)*. in *Fachbereich Veterinärmedizin*. 2004, Freie Universität Berlin: Berlin.
292. Schnitker, P., Budras, K.D., Patan, B., *The mechanism of self-regulation of the length of the hoof capsule related to the horn quality in Przewalski horses*. Acta Veterinaria Suppl., 2003. 72(7): p. 47–48.
293. Patan, B., *Saisonaler Einfluß auf Hornbildungsrate, Hornabrieb und Hornqualität in der Hufwand von Przewalskipferden (Equus ferus Przewalskii)*. in *Fachbereich Veterinärmedizin*. 2001, Freie Universität Berlin: Berlin.
294. Dabareiner, R.M., Moyer, W., Carter, G.K., *Trauma to the sole and wall*. Diagnosis and Management of Lameness in the horse., ed. M.W. Ross, Dyson, J.S. 2003, Philadelphia: Saunders. 275–282.
295. Wilson, D.G., Mays, M.B.C., Colahan, P.T., *Treatment of canker in horses*. J. Am. Vet. Med. Assoc., 1989. 194(12): p. 1721–1723.
296. Pollitt, C., *Farbatlas Huf. Anatomie und Klinik*. 1999, Hannover: Schlütersche. 132–133, 150–153.
297. Sherman, K., Ginn, P.E., Brown, M., *Recurrent canker in a Shire mare*. J. Equine Vet. Sci., 1996. 16(8): p. 322–323.
298. Hinterhofer, C., Stanek, C., Binder, K., *Elastic modulus of equine hoof horn, tested in wall samples, sole samples and frog samples at varying levels of moisture*. Berl. Münch. Tierärztl. Wochenschr., 1998. 111(6): p. 217–221.
299. Patan, B., Budras, K.-D., *Segmentpezifitäten am Pferdehuf – Teil II: Zusammenhang zwischen Hornstruktur und mechanisch-physikalischen Horneyigenschaften in den verschiedenen Hufsegmenten*. Pferdeheilkd., 2003. 19: p. 177–184.

300. Hashimoto, Y., Reese, S., Bragulla, H., Budras, K.D., *Eine lectinhistochemische Untersuchung der Epidermis von Haut und Huf des Pferdes*. Anat. Histol. Embryol., 1992. 21: p. 238–245.
301. Budras, K.D., Schiel, Ch., Mülling, Ch., Patan, B., *Method for preparing thin sections of untreated equine hoof horn for electron microscopic examination*. Microsc. Res. Tech., 2002. 58: p. 114–120.
302. Anthauer, K., *Der segmentspezifische Aufbau des Interzellularkittes in der Hufepidermis des Pferdes*, in *Fachbereich Veterinärmedizin*. 1996, Freie Universität Berlin: Berlin.
303. Budras, K.D., Huskamp, B., *Normalisierung von Struktur und Qualität der Hufkapsel nach orthopädischer Behandlung der chronischen Hufrehe des Pferdes*. Arbeitstagung D. Vet. med. Ges., 1990. 11: p. 174–180.
304. Frohnes, A.-K., Budras, K.D., *Endogene Einflussfaktoren auf die Hornqualität im Sohlen- und Ballensegment des Pferdehufes. Teil 2: Intra- und Interzelluläre Faktoren*. Pferdeheilkunde, 2001. 17: p. 437–443.
305. König, B., Budras, K.D., *Struktur und klinisch-funktionelle Bedeutung der Kronhornstratifikation unter besonderer Berücksichtigung von Hornreifung, -alterung und -zerfall am Pferdehuf*. Deutsche Tierärztl. Wochenschr., 2003. 110(11): p. 438–444.
306. Budras, K.D., Schiel, Ch., Mülling, Ch., *Horn tubules of the white line: an insufficient barrier against ascending bacterial invasion*. Equine vet. Educ., 1998. 10: p. 81–85.
307. Higami, A., *Occurrence of white line disease in performance horses fed on low-zinc and low-copper diets*. J. Equine Sci., 1999. 10(1): p. 1–5.
308. Turner, T.A., *White line disease*. Equine Vet. Educ., 1997. 9(6): p. 313–316.
309. O'Grady, S.E., *White line disease – an update*. Equine Vet. Educ., 2002. 14(1): p. 51–55.
310. Kuwano, A., Yoshihara, T., Takatori, K., Kosuge, J., *Onychomycosis in white line disease in horses: pathology, mycology and clinical features*. Equine Vet. J., 1998. 26 (Suppl.): p. 27–35.
311. Honnas, C.M., *Keratomas of the equine digit*. Equine Vet. Educ., 1997. 9(4): p. 203–207.
312. Pardoe, C.H., Wilson, A.M., *In vitro mechanical properties of different equine hoof wall crack fixation techniques*. Equine Vet. J., 1999. 31(6): p. 506–509.
313. Henke, F., *Hufbeinträger und Hufmechanismus im Seiten-, Trachten- und Eckstrebenanteil des Pferdehufes*, in *Fachbereich Veterinärmedizin*. 1997, Freie Universität Berlin: Berlin.
314. Pellmann, R., Budras, K.D., Bragulla, H., *Struktur und Funktion des Hufbeinträgers beim Pferd und seine Bedeutung bei der Hufrehe*. Pferdeheilkunde, 1996. 13: p. 53–64.
315. Marks, G., *Makroskopische, licht- und elektronenoptische Untersuchung zur Morphologie des Hyponychiums bei der Hufrehe des Pferdes*, in *Med. vet*. 1984, Freie Universität Berlin: Berlin.
316. Budras, K.D., Huskamp, B., *Belastungshufrehe – Vergleichende Betrachtungen zu anderen systemischen Hufreheerkrankungen*. Pferdeheilkunde, 1999. 15: p. 89–110.
317. Bailey, S.R., Baillon, M.-L., Rycroft, A. N., Harris, P. A., Elliott, J., *Identification of Equine Cecal Bacteria Producing Amines in an In Vitro Model of Carbohydrate Overload*. Applied and Environmental Microbiology, 2003. 69(4): p. 2087–2093.
318. Hood, D.M. *The principles of equine hoof wall conformation*. in *6th Geneva Congress of Equine Medicine and Surgery*. 1999. Geneva.
319. Pollitt, C. *The anatomy and physiology of the hoof wall*. in *6th Geneva congress of equine medicine and surgery*. 1999. Geneva.
320. Budras, K.D., Scheibe, K., Patan, B., Streich, W.J., Kim, K., *Laminitis in Przewalski horses kept in a semireserve*. J. Vet. Science, 2001. 2: p. 1–7.
321. Riggs, C.M., Knottenbelt, D.C., *Acute and subacute laminitis*. Metabolic and endocrine problems of the horse., ed. Watson. 1998, Philadelphia: Saunders Comp. 1–22.
322. Budras, K.D., Assmann, G., Bragulla, H., Huskamp, B. *Hormonelle Hufrehe, verursacht durch Hypophysentumore*. in *XIII. Fachtagung für Pferdekrankheiten anlässlich der Equitana*. 1999. Essen.
323. Buda, S., Budras, K.D. *Nature of innervation of dermal blood vessels in the claw suggests a central and local co-regulation of microcirculation*. in *13th Symposium and 5th Conference on Lameness in ruminants*. 2004. Maribor, Slovenija.
324. Eustace, R.A. *The treatment of chronic founder*. in *6th Geneva congress of equine medicine and surgery*. 1999. Geneva.
325. Malark, J.A., Nixon, A.J., Haughland, M.A., Brown, M.P., *Equine coxofemoral luxations: 17 cases (1975–1990)*. Cornell Vet., 1992. 82(1): p. 79–90.
- 325a. Schulze, T., Budras, K.D., *Zur klinisch-funktionellen Anatomie des M. interosseus medius der Hintergliedmaße im Hinblick auf die Insertionsdesmopathie des Pferdes*. Pferdeheilkunde, 2008, 24: p. 343–350.
330. Dik, K.J., Enzerink, E., van Weeren, P.R., *Radiographic development of osteochondral abnormalities in the hock and stifle of Dutch Warmblood foals, from age 1 to 11 months*. Equine Vet. J., 1999. 31 (Suppl.): p. 9–15.
331. Foland, J.W., McIlwraith, C.W., Trotter, G.W., *Arthroscopic surgery for osteochondritis dissecans of the femoropatellar joint of the horse*. Equine Vet. J., 1992. 24(6): p. 419–423.
332. van Oldruitenborgh-Oosterbaan, M.M.S., Mol, J.A., Barneveld, A., *Hormones, growth factors and other plasma variables in relation to osteochondrosis*. Equine Vet. J., 1999. 31 (Suppl.): p. 45–54.
333. van Weeren, P.R., Barneveld, A., *The effect of exercise on the distribution and manifestation of osteochondrotic lesions in the Warmblood foal*. Equine Vet. J., 1999. 31 (Suppl.): p. 16–25.
334. van Weeren, P.R., van Oldruitenborgh-Oosterbaan, M.M.S., Barneveld, A., *The influence of birth weight, rate of weight gain and final achieved height and sex on the development of osteochondrotic lesions in a population of genetically predisposed Warmblood foals*. Equine Vet. J., 1999. 31 (Suppl.): p. 26–30.
335. McIntosh, S.C., McIlwraith, C.W., *Natural history of femoropatellar osteochondrosis in three crops of Thoroughbreds*. Equine Vet. J., 1993. 16 (Suppl.): p. 54–61.
336. Ray, C.S., Baxter, G.M., McIlwraith, C.W., Trotter, G.W., Powers, B.E., Park, R.D., Steyn, P.F., *Development of subchondral cystic lesions after articular cartilage and subchondral bone damage in young horses*. Equine Vet. J., 1996. 28(3): p. 225–232.
337. Textor, J.A., Nixon, A.J., Lumsden, J., Ducharme, N.G., *Subchondral cystic lesions of the proximal extremity of the tibia in horses: 12 cases (1983–2000)*. J. Am. Vet. Med. Assoc., 2001. 218(3): p. 408–413.
338. Walmsley, J.P., Phillips, T.J., Townsend, H.G.G., *Meniscal tears in horses: an evaluation of clinical signs and arthroscopic treatment of 80 cases*. Equine Vet. J., 2003. 35(4): p. 402–406.
339. Walmsley, J.P., *Vertical tears of the cranial horn of the meniscus and its cranial ligament in the equine femorotibial joint: 7 cases and their treatment by arthroscopic surgery*. Equine Vet. J., 1995. 27(1): p. 20–25.
340. Edwards, R.B.L., Nixon, A.J., *Avulsion of the cranial cruciate ligament insertion in a horse*. Equine Vet. J., 1996. 28(4): p. 334–336.
341. Prades, M., Grant, B.D., Turner, T.A., Nixon, A.J., Brown, M.P., *Injuries to the cranial cruciate ligament and associated structures: summery of clinical, radiographic, arthroscopic and pathological findings from 10 horses*. Equine Vet. J., 1989. 21(5): p. 354–357.
342. van Pelt, R.W., *Intra-articular injection of the equine stifle for therapeutic and diagnostic purposes*. J. Am. Vet. Med. Assoc., 1965. 147: p. 490–498.
343. Hendrickson, D.A., Nixon, A.J., *Comparison of the cranial and a new lateral approach to the femoropatellar joint for aspiration and injection in horses*. J. Am. Vet. Med. Assoc., 1994. 205(8): p. 1177–1179.
344. Gough, M.R., Munroe, G.A., Mayhew, I.G., *Diffusion of mepivacaine between adjacent synovial structures in the horse. Part 2: Tarsus and stifle*. Equine Vet. J., 2002. 34(1): p. 85–90.
345. McIlwraith, C.W., Foerner, J.J., *Diagnostic and surgical arthroscopy of the tarsocrural (tibiotarsal) joint*. 2 ed. Diagnostic and surgical arthroscopy in the horse., ed. C.W. McIlwraith. 1990, Philadelphia: Lea and Febiger. 161–175.
346. White, N.A., Turner, T.A., *Hock lameness associated with degeneration of the talocalcaneal articulation: report of two cases in horses*. Vet. Med. Small Anim. Clin., 1980. 75(4): p. 678–681.
347. Bell, B.T., Baker, G.J., Foreman, J.H., Abbott, L.C., *In vivo investigation of communication between the distal intertarsal and tarsometatarsal joints in horses and ponies*. Vet. Surg., 1993. 22(4): p. 289–292.
348. Dyson, S.J., Romero, J.M., *An investigation of injection techniques for local analgesia of the equine distal tarsus and proximal metatarsus*. Equine Vet. J., 1993. 25(1): p. 30–35.
349. Baxter, G.M., Southwood, L.L., Dechant, J.E., *Diagnosis of distal tarsal osteoarthritis in horses*. Comp. Cont. Educ. Pract. Vet., 2003. 25(2): p. 138–146.
350. Wyn-Jones, G., May, S.A., *Surgical arthrodesis for the treatment of osteoarthritis of the proximal intertarsal, distal intertarsal and tarsometatarsal joints in 30 horses: a comparison of four different techniques*. Equine Vet. J., 1986. 18(1): p. 59–64.
351. Eksell, P., Uhlhorn, H., Carlsten, J., *Evaluation of different projections for radiographic detection of tarsal degenerative joint disease in Icelandic horses*. Vet. Radiol. Ultrasound, 1999. 40(3): p. 228–232.
352. Dechant, J.E., Southwood, L.L., Baxter, G.M., Crawford, W.H., *Treatment of distal tarsal osteoarthritis using 3-drill tract technique in 36 horses*. Proc. Am. Assoc. Equine Pract., 1999. 45: p. 160–161.
353. Gabel, A.A., *Treatment and prognosis for cunean tendon bursitis-tarsitis of Standardbred horses*. J. Am. Vet. Med. Assoc., 1979. 175(10): p. 1086–1088.
354. Baxter, G.M., Dechant, J.E., Southwood, L.L., *Treatment of horses with distal tarsal osteoarthritis*. Comp. Cont. Educ. Pract. Vet., 2003. 25(2): p. 148–155.
355. McCarroll, G.D., McClure, S., *Extracorporeal shock wave therapy for treatment of osteoarthritis of the tarsometatarsal and distal intertarsal joints of the horse*. Proc. Am. Assoc. Equine Pract., 2000. 46: p. 200–202.
356. Adkins, A.R., Yovich, J.V., Steel, C.M., *Surgical arthrodesis of distal tarsal joints in 17 horses clinically affected with osteoarthritis*. Aust. Vet. J., 2001. 79(1): p. 26–29.
357. Jansson, N., Sonnichsen, H.V., Hansen, E., *Bone spavin in the horse: fenestration technique. A retrospective study*. Pferdeheilkunde, 1995. 11(2): p. 97–100.
358. Imschoot, J., Seenhaut, M., de Moor, A., Verschooten, F., *Partial tibial neurectomy and neurectomy of the deep peroneal nerve as a treatment of bone spavin in 24 horses*. Equine Practice, 1995. 17(2): p. 8–13.

Joints of the Pelvic Limb

326. Speirs, V.C., Wrigley, R., *A case of bilateral hip dysplasia in a foal*. Equine Vet. J., 1979. 11(3): p. 202–204.
327. Nixon, A.J., *Diagnostic and operative arthroscopy of the coxofemoral joint in horses*. Vet. Surg., 1994. 23(5): p. 377–385.
328. Vacek, J.R., Ford, T.S., Honnas, C.M., *Communication between the femoropatellar and medial and lateral femorotibial joints in horses*. Am. J. Vet. Res., 1992. 53(8): p. 1431–1434.
329. Cauvin, E.R.J., Munroe, G.A., Boyd, J.S., Paterson, C., *Ultrasonographic examination of the femorotibial articulation in horses: imaging of the cranial and caudal aspects*. Equine Vet. J., 1996. 28(4): p. 285–296.
357. Jansson, N., Sonnichsen, H.V., Hansen, E., *Bone spavin in the horse: fenestration technique. A retrospective study*. Pferdeheilkunde, 1995. 11(2): p. 97–100.

359. Brehm, W., Staecker, W., *Osteochondrosis (OCD) in the tarsocrural joint of Standardbred trotters – correlation between radiographic findings and racing performance*. Pferdeheilkunde, 2000. 16(6): p. 590–593.
360. Sandgren, B., Dalin, G., Carlsten, J., Lundeheim, N., *Development of osteochondrosis in the tarsocrural joint and osteochondral fragments in the fetlock joints of Standardbred trotters. II. Body measurements and clinical findings*. Equine Vet. J., 1993. 16 (Suppl.): p. 48–53.
361. McIlwraith, C.W., Foerner, J.J., Davis, D.M., *Osteochondritis dissecans of the tarsocrural joint: result of treatment with arthroscopic surgery*. Equine Vet. J., 1991. 23(3): p. 155–162.
362. Torre, F., Toniato, M., *Osteochondral fragments from the medial malleolus in horses: A comparison between radiographic and arthroscopic findings*. Proc. Am. Assoc. Equine Pract., 1999. 45: p. 167–171.
363. Tomlinson, J.E., Redding, W.R., Sage, A., *Ultrasonographic evaluation of tarsocrural joint cartilage in normal adult horses*. Vet. Radiol. Ultrasound, 2000. 41(5): p. 457–460.
364. Sack, W.O., Orsini, P.G., *Distal intertarsal and tarsometatarsal joints in the horse: communication and injection sites*. J. Am. Vet. Med. Assoc., 1981. 179(4): p. 355–359.
365. Kraus-Hansen, A.E., Jann, H.W., Kerr, D.V., Fackelman, G.E., *Arthrographic analysis of communication between the tarsometatarsal and distal intertarsal joints of the horse*. Vet. Surg., 1992. 21(2): p. 139–144.
366. Sullins, K.E., *The tarsus: Curb*. 5 ed. Adams' Lameness in horses., ed. T.S. Stashak. 2002, Baltimore: Lippincott Williams and Wilkins. 972–973.
367. Grant, B.D., *Bursal injections*. Proc. Am. Assoc. Equine Pract., 1996. 42: p. 64–68.
368. van Pelt, R.W., *Inflammation of the tarsal synovial sheath (thoroughpin) in horses*. J. Am. Vet. Med. Assoc., 1969. 155(9): p. 1481–1488.
369. Torre, F., Becker, R., *Chirurgische Behandlung einer Kurbengalle (Sprunggelenksbeugegelenke) bei einem Quarter Horse*. Pferdeheilkunde, 1996. 12(1): p. 7–10.

Head

370. Habermehl, K.H., *Die Altersbestimmung bei Haus- und Labortieren*. 2nd ed. 1975, Berlin: Parey.
371. Joest, E., *Handbuch der speziellen pathologischen Anatomie der Haustiere*. Bd. 1–8; 3. Aufl. 1969–1971, Berlin und Hamburg: Parey.
372. Quick, C.B., Rendano, V.R., *The equine teeth*. Mod. Vet. Pract., 1979. 60: p. 561–567.
373. Weber, W., *Röntgen – anatomische Untersuchungen am Gesichtsschädel des Pferdes*, in *Med. vet.* 1963, Hannover: Hannover.
374. Wegner, M., *Untersuchungen zur Zahnaltersbestimmung beim Traber*, in *Med. vet.* 1984, Freie Universität Berlin: Berlin.
375. Wissdorf, H., Kassianoff, I., Sack, W.O., *Bumbs – Physiologische Umfangersvermehrung am Margo ventralis mandibulae*. Waltham Report, 1990. 31: p. 15–22.
376. King, A.S., Riley, V.A., *A Guide to the physiological and clinical anatomy of the head*. 4th ed. 1980, Liverpool: Dept. of Veterinary Anatomy.
377. Wissdorf, H., Gerhards, H., Huskamp, B., Deegen, E., *Anatomie und Propädeutik des Pferdes*. 2 ed. 2002, Hannover: Verlag M. u. H. Schaper Alfeld. S. 95–97.
378. Dietz, O., Schaetz, F., Schleiter, H., Teuscher, R., Hrsg.: Dietz, O., Henschel, E., *Anästhesie und Operationen bei Groß- und Kleintieren*. 4 ed. 1988, Stuttgart: Enke.
379. Montané, L., Bourdelle, E., Bressou, C., *Anatomie regionale des animaux domestiques*. 1964, Paris: J.-B. Baillière et Fils.
380. Wintzer, H.J., *Krankheiten des Pferdes*. 1982, Berlin u. Hamburg: Parey.
381. Barone, R., *Osteologie*. Anatomie comparée des mammifères domestiques. Vol. 1. 1976, Paris: Vigot Frères.
382. Nickel, R., Schwarz, R., *Vergleichende Betrachtung der Kopfarterien der Haussäugetiere (Katze, Hund, Schwein, Rind, Schaf, Ziege, Pferd)*. Zbl. Vet. Med. A, 1963. 10: p. 89–120.
383. Dyce, K.M., Sack, W.O., Wensing, C.J.G., *Anatomie der Haustiere*. 1991, Stuttgart: Enke.
384. Schaller, O.E., *Illustrated Veterinary Anatomical Nomenclature*. 1992, Stuttgart: Enke.
385. Bolz, W., Hrsg.: Dietz, O., *Lehrbuch der allgemeinen Chirurgie*. 5. Aufl. 1985, Stuttgart: Enke.
386. Budras, K.D., Fricke, W., *Atlas der Anatomie des Hundes*. 6. Aufl. 2000, Hannover: Schlütersche Verlagsanstalt.
387. Gelatt, K.N., *Textbook of Veterinary Ophthalmology*. 1981, Philadelphia: Lea and Febiger.
388. Zietzschmann, O., *Traubenkörner der Haussäugetiere*. Arch. mikrosk. Anat., 1906. 65: p. 611–622.
389. Nickel, R., Schummer, A., Seiferle, E., *Lehrbuch der Anatomie der Haustiere*. Vol. 1–4. 1982–1987, Berlin und Hamburg: Parey.
390. Hebel, R., *Distribution of retinal ganglion cells in five mammalian species (pig, sheep, ox, horse, dog)*. Anat. Embryol., 1976. 159: p. 45–51.
391. Schnorr, B., Kressin, M., *Embryologie der Haustiere*. 4 ed. 2001, Stuttgart: Enke.
392. Smollich, A., Michel, G., *Mikroskopische Anatomie der Haustiere*. 1985, Jena: Fischer.
393. Gerdell, *Nahtsterne in der Linse des Pferdeauges*. Z. Vet. kde, 1899. 10: p. 533–534.

394. Cook, W.R., Campbell, R.S.F., Dawson, C., *The pathology and aetiology of guttural pouch mycosis in the horse*. Vet. Rec., 1968. 83: p. 422–428.
395. Freeman, D.E., Donawick, W.J., *Occlusion of internal carotid artery in the horse by means of a balloon – tipped catheter: clinical use of a method to prevent epistaxis caused by guttural pouch mycosis*. J. Amer. Vet. Med. Assoc., 1980. 176: p. 236–240.
396. Kipar, A., Frese, K., *Zungenlähmung infolge Luftsackmykose des Pferdes*. Dtsch. vet. med. Ges./Fachgr. Pferdekrankheiten, 1992. 12: p. 84–88.
397. König, H.E., *Zur Topographie des Luftsackes (Diverticulum tubae auditivae) beim Pferd*. Tierärztl. Prax., 1984. 12: p. 219–227.
398. McCarthy, P.H., *The Triangle of Viborg (Trigonum Viborgi) and its Anatomical Relationship in the Normal Standing Horse*. Anat. Histol. Embryol., 1990. 19: p. 303–313.
399. Rüedi, M., *Topographie, Bau und Funktion der A. carotis int. des Pferdes*, in *Med. vet.* 1922, Zürich: Zürich.
400. Baker, G.J., *Laryngeal hemiplegia in the horse*. Comp. Cont. Ed., 1983. 5: p. 61–66.
401. Huskamp, B., Böckenhoff, G., *Ergebnisse der Kehlkopfperforation nach Marks*. Prakt. Tierarzt, 1978. 59: p. 302.
402. Marks, D., Mackay-Smith, M.P., Cushing, L.S. et al., *Use of a prosthetic device for surgical correction of laryngeal hemiplegia in horses*. J. Amer. Vet. Med. Assoc., 1970. 157: p. 157–163.
403. Marks, D., Mackay-Smith, M.P., Cushing, L.S. et al., *Etiology and diagnosis of laryngeal hemiplegia in horses*. J. Amer. Vet. Med. Assoc., 1970. 157: p. 429–436.
404. King, A.S., *Physiological and clinical anatomy of the Domestic Mammals – Central nervous system*. 1987: Oxford University Press.
405. Seiferle, E., *Zur makroskopischen Anatomie des Pferdegehirns*. Acta anat., 1957. 30: p. 775–786.
406. Braun, A., *Der segmentale Feinbau des Rückenmarks des Pferdes*. Acta Anat. 10, 1950(Suppl. 12).
407. Seiferle, E., *Zur Rückenmarkstopographie von Pferd und Rind*. Z. Anat. Entwicklungsgesch., 1939. 110: p. 371–384.
408. Berg, R., *Angewandte und topographische Anatomie der Haustiere*. 4 ed. 1995, Stuttgart Jena: Gustav Fischer.
409. Hopkins, G.S., *The correlation of anatomy and epidural anesthesia in the domestic animals*. Cornell Vet., 1935. 25: p. 263–270.
410. Ziegler, H., *Zur Anatomie der Liquorpunktionsstellen bei Haustieren*. Schweiz. Arch. Tierheilkd., 1945. 87: p. 247.
411. Jaggy, A., Tipold, A., *Die neurologische Untersuchung beim Kleintier und beim Pferd, Opuscula veterinaria*. 1999: wak Verlag.
412. Getty, R., Sisson and Grossman's *Anatomy of the Domestic Animals*. 5 ed. 1975, Philadelphia, London, Toronto: W. B. Saunders Comp.
413. Messonier, S.P., *Veterinary neurology*. 2000, Boston: Butterworth and Heine-mann.
414. White and Moore, *Current techniques in equine surgery and lameness*. 2 ed. 1988, Philadelphia: Saunders.

Neck and Back

415. Maierl, J., Zechmeister, R., Schill, W., Gerhards, H., Liebich, H.G., *Röntgenologische Darstellung der Wachstumsfugen an Atlas und Axis beim Fohlen*. Tierärztl. Praxis (G), 1998. 26: p. 341–345.
416. Hertsch, B., Salam Ragab, A.E., *Röntgenologische Untersuchung der Epiphysenfugenschließung an den Halswirbeln beim Pferd*. Berl. Münch. Tierärztl. Wochenschr., 1977. 90: p. 172–176.
417. Whitwell, K.E., Dyson, S., *Die Röntgenologie der Halswirbelsäule beim Pferd*. Pferdeheilkunde, 1987. 3(4): p. 203–212.
418. Pujol, B., Mathon, D., *Le Wobbler Syndrome chez le cheval. Spondylomyéopathie cervicale ou „Mal de chien“. Etude bibliographique. Deuxième partie*. Revue Méd. Vét., 2003. 154(4): p. 289–306.
419. Wagner, P.C., Grant, B.D., Reed, S.M., *Cervical vertebral malformations*. Vet. Clin. North Am. Equine Pract., 1987. 3(2): p. 385–396.
420. Mayhew, I.G.J., *The equine spinal cord in health and disease. II. The diseased spinal cord*. Proc. Am. Assoc. Equine Pract., 1999. 45: p. 67–84.
421. Douglas, J., *The pathogenesis and clinical manifestation of equine osteochondrosis*. Vet. Med., 1992. 87(8): p. 826–833.
422. Hertsch, B., Lieske, R., *Halswirbelfrakturen beim Pferd*. Tierärztl. Praxis, 1978. 6: p. 209–224.
423. Ranner, W., Gerhards, H., *Vorkommen und Bedeutung von Rückenerkrankungen – insbesondere des „Kissing Spine“-Syndroms – bei Pferden in Süddeutschland*. Pferdeheilkunde, 2002. 18(1): p. 21–33.
424. Hertsch, B., Grimmelmann, E., *Röntgenologische Untersuchungen der Ossifikationsvorgänge am Widerrist beim Pferd*. Zbl. Vet. Med. A, 1979. 26: p. 191–200.
425. Jeffcott, L.B., *Rückenprobleme beim Athleten Pferd. 2. Mögliche Differentialdiagnosen und Therapiemethoden*. Pferdeheilkunde, 1993. 9(4): p. 223–236.
426. Dämmrich, K., Randelhoff, A., Weber, B., *Ein morphologischer Beitrag zur Biomechanik der thorakolumbalen Wirbelsäule und zur Pathogenese des Syndroms sich berührender Dornfortsätze (Kissing Spines-Syndrom) bei Pferden*. Pferdeheilkunde, 1993. 9(5): p. 267–281.
427. Lauk, H.D., Kreling, I., *Behandlung des Kissing spines-Syndroms beim Pferd – 50 Fälle. Teil 2: Ergebnisse*. Pferdeheilkunde, 1998. 14(2): p. 123–130.
428. Jeffcott, L.B., Dalin, G., *Natural rigidity of the horse's backbone*. Equine Vet. J., 1980. 12(3): p. 101–108.

429. Walmsley, J.P., Pettersson, H., Winberg, F., McEvoy, F., *Impingement of the dorsal spinous processes in two hundred and fifteen horses: case selection, surgical technique and results.* Equine Vet. J., 2002. 34(1): p. 23–28.
430. Klein, H.J., Hertsch, B., Dieckmann, M., Wissdorf, H., *Spondylosis ankylosans und Spondylarthrose bei einer 11jährigen Kleinpferdestute.* Pferdeheilkunde, 1989. 5(2): p. 115–118.
431. Townsend, H.G.G., Leach, D.H., Doige, C.E., Kirkaldy-Willis, W.H., *Relationship between spinal biomechanics and pathological changes in the equine thoracolumbar spine.* Equine Vet. J., 1986. 18(2): p. 107–112.
432. Dyson, S., Murray, R., *Pain associated with the sacroiliac joint region: a clinical study of 74 horses.* Equine Vet. J., 2003. 35(3): p. 240–245.
433. Huskamp, B., Nowak, M., *Insertionsdesmopathien beim Pferd und einige ihrer Lokalisationen.* Pferdeh., 1988. 4: p. 3–12.
434. Dietz, O., *Krankheiten des Genicks und des Widerristes.* 2 ed. Handbuch Pferdepraxis, ed. O. Dietz, Huskamp, B. 1999, Stuttgart: Ferdinand Enke Verlag. 267–272.
435. Rashmir-Raven, A., Gaughan, A.M., Modransky, P., Clem, M.F., *Fistulous Withers.* Comp. Cont. Educ., 1990. 12(11): p. 1633–1641.

Neck and Thoracic Cavity

436. Huskamp, B., Henschel, E., Arenhoevel, A., *Technik und Ergebnisse einer modernen Kopperoperation.* Der prakt. Tierarzt, 1983. 64: p. 110–119.
437. Donat, K., *Der sog. M. brachiocephalicus des Pferdes.* Berl. Münchn. Tierärztl. Wschr., 1968. 81: p. 71–72.
438. Loeffler, K., *Anatomie und Physiologie der Haustiere.* 1970, Stuttgart: E. Ulmer.
439. De Lahunta, A., Habel, R.E., *Applied Veterinary Anatomy.* 1986: W. B. Saunders Comp., Philadelphia, London, Toronto.
440. Agduhr, E., *Morphologische Beweise für das Vorhandensein intravitraler Kommunikation zwischen den Kavitäten der Pleurasäcke bei einer Reihe von Säugetieren.* Anat. Anz., 1927. 64: p. 276–298.
441. Jones, T.C., Hunt, R.D., *Veterinary Pathology.* 5th ed. 1983, Philadelphia: Lea and Febiger.
442. Schmaltz, R., *Atlas der Anatomie des Pferdes.* T. 1: Das Skelett. 4. u. 5. Aufl. (1924)
T 2: Topographische Myologie. 5. Aufl. (1939)
T 3: Die Lage der Eingeweide. (1914)
T 4: Die Eingeweide. (1927)
T 5: Der Kopf. (1929). 1914–1939, Berlin: Schoetz, Berlin.
443. Steck, W., *Lungenschallperkussion und Brustwandschallperkussion bei Großtieren.* Schweiz. Arch. Tierheilkd., 1962. 104: p. 59–66.
444. Hausotter, E., *Das Herzskelett der Haussäuger Pferd, Rind, Schaf, Schwein, Hund und Katze.,* in *Med. vet.* 1923, Wien: Wien. p. 311.
445. Hoffmann, V., *Die Blutgefäßversorgung des Pferdeherzens.,* in *Med. vet.* 1960, Gießen: Gießen.
446. Preuß, F., *Zur Nomenklatur am Herzen.* Anat. Anz., 1955. 103: p. 20–37.
447. Quiring, D.P., Baker, R.J., *The equine heart.* Amer. J. Vet. Res., 1953. 14: p. 62–67.
448. Schaller, O., *Korrosionsanatomie des Pferdeherzens.* Zbl. Vet. Med., 1958. 5: p. 152–170.
449. Schmack, K.H., *Die Ventilebene des Herzens bei Pferd, Rind und Hund.,* in *Med. vet.* 1974, Gießen: Gießen.
450. Simoons, P., de Vos, N.R., Lauwers, H., *Illustrated anatomical nomenclature of the heart and the arteries of the head and neck in the domestic mammals.* Mededel. Fakult. Diergeneskd. Rijksuniv. Gent, 1984.
451. Littlewort, M.C.G., *The clinical auscultation of the equine heart.* Vet. Rec., 1962. 74: p. 1247–1259.
452. Adams, S.B., *Surgical approaches to the exploration of the equine abdomen.* Vet. Clin. North Am. (Large Anim. Pract.), 1982. 4: p. 89–104.

Abdominal Wall and Cavity

453. Huskamp, B., *Die mediane Laparotomie beim Pferd – Technik und Ergebnisse.* Dtsch. tierärztl. Wschr., 1976. 83: p. 276.
454. Huskamp, B., *Krankheiten des Verdauungsapparates und des Bauchfells.* Handbuch der Pferdekrankheiten für Wissenschaft und Praxis., ed. O. Dietz, Wiesner, E. 1982, Basel: Karger.
455. Hickman, J., *Equine surgery and medicine.* Vol. 1/2. 1985 und 1986, London: Acad. Press.
456. Bradley, O.C., *The topographical anatomy of the thorax and abdomen of the horse.* 1922, Edinburgh: W. Green and Son.
457. Barone, R., *Splanchnologie.* Anatomie comparée des mammifères domestiques. Vol. 3. 1976, Lyon: Lab.d'Anat. Ecole Nat. Vét.,
458. Neumann-Kleinpaul, K., Schützler, G., *Untersuchungen über Druckmessungen, Ruptur, Fassungsvermögen und Gewicht am Magen des Pferdes.* Arch. wiss. prakt. Tierheilkd., 1940. 75: p. 370–386.
459. Barone, R., *La topographie des viscères abdominaux, chez les équidés domestiques.* Bull. Soc. Sci. Vét. Lyon, 1952/53: p. 3–26.
460. Boom de, H.P.A., *Functional anatomy an nervous control of the equine alimentary tract.* J. S. Afr. Vet. Assoc., 1975. 46: p. 5–11.
461. Dobberstein, J., Hartmann, H., *Über die Anastomosenebildung im Bereich der Blind- und Grimmdarmarterien des Pferdes und ihre Bedeutung für die Entstehung der embolischen Kolik.* Berl. tierärztl. Wschr., 1932. 48: p. 397–402.

462. Kadletz, M., *Anatomische Grundlagen der rektalen Untersuchung beim Pferd.* Wien. tierärztl. Mschr., 1930. 17: p. 765.
463. König, H.E., Amselgruber, W., *Funktionelle Anatomie der Eingeweidearterien in der Bauchhöhle des Pferdes.* Tierärztl. Prax., 1985. 13: p. 191–198.
464. Kopf, N., *Anatomischer Leitfaden für die Exploration der Bauchhöhle des Pferdes durch die mediane Laparotomie.* Zentralbl. Vet. Med. A, 1980. 27: p. 437–451.
465. McCarthy, P.H., *Eyes et the tip of your fingers: The anatomy of the abdominal and pelvic viscera of the narcotized horse as perceived by palpation during exploratory laparotomy.* The Australian Equine Research Foundation, 1986.
466. Schmaltz, R., *Über die Plica gastropancreatica oder das Ligamentum gastroduodenale und das Foramen epiploicum beim Pferde.* Berl. tierärztl. Wschr., 1897. 13: p. 385–389.
467. Huskamp, B., *Diagnosis of gastroduodeno-jejunitis and its surgical treatment by a temporary duodenocaecostomy.* Equine Vet., 1985. 17: p. 314–316.
468. Schmaltz, R., *Anatomie des Pferdes.* 2. Aufl. 1928, Berlin: Schoetz.
469. Huskamp, B., *Über einige Operationstechniken im Blinddarmbereich des Pferdes.* Pferdeh., 1988. 7: p. 185–188.
470. Huskamp, B., Schwabenbauer, K., Pferdekamp, M., *Anlage und Wartung von Zäkumfisteln beim Pferd.* Fortschr. Tierphysiol. und Tierernähr., 1982. 13: p. 7–12.
471. Barclay, W.P., Foerner, J.J., Phillips, T.N., *Volvolus of the large colon in the horse.* J. Amer. Vet. Med. Assoc., 1980. 177: p. 629–630.
472. Martin, P., *Zur Blind- und Grimmdarmentwicklung beim Pferd.* Beitr. path. Anat. allg. Path. (Festschr. E. Bostroem), 1921. 69: p. 512–516.
473. Koch, T., Berg, R., *Lehrbuch der Veterinär-Anatomie.* Bd. 1–3. 1981–1993, Jena: Fischer.
474. Oberlojer, H.G., *Untersuchungen zur Frage des Auftretens von Spontanrupturen des Mastdarmes beim Pferd und zur Frage von deren rechtlicher Beurteilung.,* in *Med. vet.* 1984, Wien: Wien.

Pelvis, Urogenital Organ

475. Preuß, F., Budras, K.D., *Zur Homologie des Hüfthöckers und anderer Knochenpunkte des Darmbeins.* Berl. Münchn. tierärztl. Wschr., 1969. 82: p. 141–143.
476. Bourdelle, E., Bressou, C., *Anatomie regionale animaux domestiques.* T1: Equides. 1949, Paris: Bailliere et Fils.
477. Ellenberger, W., Baum, H., *Handbuch der vergleichenden Anatomie der Haustiere.* 18. Auflage. 1943, Berlin: Springer.
478. Teller, H., *Die Architektur des breiten Beckenbandes beim Pferde.,* in *Med. vet.* 1945, Hannover: Hannover.
479. Dietz, O., Wiesner, E., *Handbuch der Pferdekrankheiten für Wissenschaft und Praxis.* T. 1–3. 1982, Basel, München, Paris: S. Karger.
480. Henry, M., Amaral, D., Tavares, F.F., Santos, N.R., *Hydrocoele of the vaginal cavity of stallions.* J. Reprod. Fert. (Suppl), 2000. 56: p. 13–21.
481. Budras, K.D., *Die Mm. compressor mammae und fixator fundi uteri der Stute, zugleich ein Beitrag zur Abkunft des M. cremaster ext. des Hengstes.* Zbl. Vet. Med., 1972. C 1: p. 350–362.
482. Lowe, J.E., Dougherty, R., *Castration of horses and ponies by a primary closure method.* J. Amer. Vet. Med. Assoc., 1972. 160: p. 183–185.
483. Schebitz, H., Brass, W., *Allgemeine Chirurgie.* 1975, Berlin und Hamburg: Parey.
484. Budras, K.D., Preuß, F., Traeder, W., Henschel, E., *Der Leistenpalt und die Leistenringe unserer Haussäugetiere in neuer Sicht.* Berl. Münchn. Tierärztl. Wschr., 1972. 85: p. 427–431.
485. Habel, R.E., Budras, K.D., *Anatomy of the prepubic tendon in the horse, cow, sheep, goat and dog.* Am. J. Res., 1992. 53: p. 2183–2195.
486. Preuß, F., Budras, K.D., Traeder, W., *Arcus inguinalis und Tendo praepubicus des Pferdes und deren vergleichend – anatomische Bedeutung.* Acta anat., 1972. 82: p. 47–74.
487. Mosimann, W., Kohler, T., *Zytologie, Histologie und mikroskopische Anatomie.* 1990, Berlin und Hamburg: Parey.
488. Allen, W.R., *Fetomaternal interactions and influences during equine pregnancy.* Reproduction, 2001. 121: p. 513–527.
489. Hay, M., Allen, R.W., *An ultrastructural and histochemical study of the interstitial cells in the gonads of the female horse.* J. reprod. fertile. (Suppl.), 1975. 23: p. 557–561.
490. Ginther, O.J., *Reproductive biology of the horse. Basic and applied aspects.* 2. Auflage. 1992: Equiservices, Cross Plains (WI), USA.
491. Pierson, R.A., *Folliculogenesis and ovulation.* Equine Reproduction., ed. A.O. McKinnon, Voss, J.L. 1993, Philadelphia, London: Lea and Febiger. 161–171.
492. Morris, L.H.A., Allen, W.R., *An overview of low dose insemination in the mare.* Reprod Dom Anim, 2002. 37: p. 206–210.
493. Sieme, H., Bonk, A., Ratjen, J., Klug, E., Rath, D., *Effect of sperm number and Site/Technique of insemination on pregnancy in mares.* Pferdeheilkd., 2003. 19: p. 677–683.
494. Ginther, O.J., *Ultrasonic imaging and reproductive events in the mare.* 1986: Verlag Equiservices, Cross Plains, Wisconsin, USA.
495. Bartmann, C.P., Schöning, A., Brickwedel, I., Ohnesorge, B., Klug, E., *Hysteroskopie und minimal invasive endouterine Chirurgie bei der Stute.* Pferdeheilkd., 1997. 13: p. 474–482.
496. MacPherson, M.L., Reimer, J.M., *Twin reduction in the mare: current options.* Anim Repro Sci, 2000. 60–61: p. 233–244.
497. Fowden, A., Silver, M., *Development of the pituitary-adrenal axis in the fetal foal and lamb.* Reproduction in Domestic Animals., 1995. 30: p. 170–177.

498. Vandeplasseche, M., *Obstetrician's view of the physiology of equine parturition and dystocia*. Equine Veterinary Journal, 1980. 12: p. 45–49.
499. Vandeplasseche, M., *pathogenesis of dystocia and fetal malformation in the horse*. Journal of Reproduction and Fertility Supplement, 1987. 35: p. 547–552.
500. Zietzschmann, O., Krölling, O., *Lehrbuch der Entwicklungsgeschichte der Haustiere*. 2. Aufl. 1955, Berlin: Parey.
501. Merkt, H., Merkt, J.C., *Plastische Operation von Vulva und Scheidenvorhof bei der Stute*. Pferdeheilkunde, 1986. 2: p. 55–58.
502. Zinnbauer, M., *Untersuchungen über den Hymen bei Pferd, Ziege, Schwein und Hund.*, in *Med. vet.* 1927, Wien: Wien.
503. Powell, D.G., David, J.D.S., Frank, C.J., *Contagious equine metritis: the present situation reviewed and revised code of practice for its control*. Vet. Rec., 1978. 103: p. 399–402.
504. Wissdorf, H., Poulsen-Nautrup, C., *Beitrag zur Nomenklatur von Klitoris und Präputium bei der Stute im Hinblick auf die Klitorissinusektomie gemäß CEM-Bestimmungen*. Tierärztl. Prax., 1986. 14: p. 371–375.
505. Bartmann, C.P., Schoon, H.A., Lorber, K., Brickwedel, I., Klug, E., *Testicular sonography and biopsy in the stallion – Indication, techniques and diagnostic relevance*. Pferdeheilkd., 1999. 15: p. 506–514.
506. Hillmann, R.B., Casey, P.J., Kennedy, P.C., Hughe, J.P., Liu, I.K.M., *Testicular biopsy in the stallion*. Proc. 6th Int Symp. Equine Reprod., 1994: p. 145–146.
507. Cox, J.E., Edwards, G.B., Neal, P.A., *An analysis of 500 cases of equine cryptorchism*. Equine Vet. J., 1979. 11: p. 113–116.
508. Cox, J.E., *Testosterone concentrations in normal and cryptorchid horses. Response to human chorionic gonadotrophin*. Animal Reprod. Sci., 1989. 18: p. 43–50.
509. Cox, J.E., *Developmental abnormalities of the male reproductive tract*. Equine Reproduction., ed. A.O. McKinnon, Voss, J.L. 1993, Philadelphia, London: Lea and Febiger. 915–920.
510. Adams, O.R., *An improved method of diagnosis and castration of cryptorchid horses*. J. Amer. Vet. Med. Assoc, 1964. 145: p. 439–446.
511. Amann, R., Johnson, L., Pickett, B.W., *Connection between the seminiferous tubules and efferent ducts in the stallion*. Am. J. Vet. Res., 1977. 38: p. 1571–1579.
512. Geiger, G., *Die Hodenhüllen des Pferdes, ein ergänzender Beitrag zum Prinzip des Schichtenaufbaues der Skrotalwand*. Berl. Münchn. tierärztl. Wschr., 1956. 69: p. 330–333.
513. Pozor, M., McDonnell, S.M., *Testicular bloodflow in the stallion*. Theriogenology, 2004. 61.
514. Collin, B., *La vascularisation artérielle du testicule chez le cheval*. Zbl. Vet. Med., 1973. C 2: p. 46–53.
515. Brümmer, J.E., Reger, H., Zinbinski, R., Squires, E.L., *Effect of storage and 5°C on the motility and cryopreservation of stallion epididymal spermatozoa*. Theriogenology, 2002. 58: p. 405–407.
516. Pascoe, J.R., Ellenburg, T.V., Culbertson, M.R. et al., *Torsion of the spermatic cord in the horse*. J. Amer. Vet. Med. Assoc., 1981. 178: p. 241–245.
517. Varner, D.D., Blanchard, T.L., Brinsko, S.P., Love, C.C., Taylor, T.S., Johnson, L., *Techniques for evaluation selected reproductive disorders of stallions*. Anim. Reprod. Sci., 2000. 60–61: p. 493–509.
518. Töpfer-Petersen, E., Waberski, D., Hess, O., Bellair, S., Schambony Ekhlesi-Hundrieser, M., Genzel, M., Reineke, A., *Bedeutung des Seminalplasmas für die Befruchtung*. Tierärztl. Umschau, 1998. 53: p. 447–454.
519. Jude, R., Giese, A., Piumi, F., Guérin, G., Sieme, H., Töpfer-Petresen, E., Distl, O., Leeb, T., *Molecular characterization of the CRISP-1 Gene—a candidate gene for stallion fertility*. Theriogenology, 2002. 58: p. 417–420.
520. Weber, J.A., Woods, G.L., *Transrectal ultrasonography for the evaluation of stallion accessory sex glands*. Stallion Management, The Vet. Clin. North America, 1992. 8 (1): p. 183–190.
521. Küst, D., Schaetz, F., *Fortpflanzungsstörungen bei Haustieren*. 6. Aufl. 1983, Stuttgart: Enke.
522. Preuß, F., *Die Tunica albuginea penis und ihre Trabekel bei Pferd und Rind*. Anat. Anz., 1954. 101: p. 64–83.
523. Magda, J.J., *Local anesthesia in operations on the male perineum in horses (Abstr.)*. J. Amer. Vet. Med. Assoc., 1948. 113: p. 559.
524. Habel, R.E., *The perineum of the mare*. Cornell Vet., 1953. 43: p. 247–278.
525. Schulze, S.W., Budras, K.-D., Schusser, G.F., *Licht- und elektronenmikroskopische Darstellung des proximalen Tubulus bei gesunden Pferden und kolikkranken Pferden mit hämodynamisch induziertem akuten Nierenversagen*. Pferdeheilkd., 2004. 20: p. 118–126.

Index

The items in this index are listed under the nouns.

A

Aging by teeth 145
Ampulla coli 70
Ampulla of deferent duct 84
Angle, iridocorneal 42
Ansa cervicalis 50
Aorta 80
Aperture, nasomaxillary 30, 148
Apparatus
Hyoid 34
lacrimal 40, 154
suspensory of fetlock 12, 125
suspensory of udder 76
stay of forelimb 12
stay of hindlimb 24, 134
Arch, costal 64
inguinal 74
palatoglossal 44
ischial 72
terminal 22
Artery(ies), Arteria(ae), Vessels
antebrachial 8
aorta 80, 168
axillary 8
brachial 8, 168
brachiocephalic trunk 62
carotid common 48, 58, 62, 166
carotid external 46
carotid internal 46
caudal 86
cecal 70
celiac 70
cervical deep 62
cervical supf. 62
ciliary 42
circumflex femoral 20
circumflex humeral 8
circumflex iliac 64, 76, 78
colic branch 70
colic right 70
collateral ulnar 8
coronary 62
costocervical trunk 62
cubital transverse 8
digital 10, 22, 118
facial 50
femoral 20, 72
femoral, caudal 20
femoral, deep 20
gastric left 70
gluteal 20
hepatic 70
iliac external 20, 174
iliac internal 20
interlobar of kidney 78
interosseous 8
lingual 50
linguofacial trunk 50
mammary 80
maxillary 46
median 8
mesenteric caudal 70
mesenteric cranial 70
metatarsal 22, 133
metatarsal dorsal 20, 133
metatarsal plantar 22
occipital 62
of brain 52
of eye 42
of penis 80
ophthalmic 42
palmar 8, 10
palmar medial 8
pedal dorsal 20, 22
plantar 20, 22

popliteal 20
Artery(ies), Arteria(ae), Vessels
(continued)
pudendal external 72, 84
pudendoepigastric trunk 20
pulmonary 60
radial 8
retinal 42
saphenous 20
scapular dorsal 62
splenic 70
subclavian 8, 62
subscapular 8
suprascapular 8
supreme intercostal 62
testicular 74, 84
thoracic internal 62
thoracic external 8
thoracodorsal 8
tibial caudal 20
tibial cranial 22
transverse cubital 8
ulnar collateral 8
vertebral 62
Arthroscopy 112
Ataxia, cerebellar 164
Ataxia, spinal 164
Axis, optic 42

B

Bands of large intestine 66, 70, 179
Bands of cecum 179
Bars of hoof 26
Birkeland fractures 117
Bladder, urinary 78
Blood supply
of brain 52
of gastrointestinal tract 70
of udder 80
Body, See also Corpus(ora)
ciliary 42
perineal 86
vitreous 42, 157
Bone(s), See also (Os(sa)).
calcaneus 16
cannon 4
carpal 2
coffin 117
femur 6
fibula 16
hip 72
humerus 4, 114
hyoid 34
ilium 72
ischium 72
manubrium sterni 56
metacarpal 4
metatarsal 16
navicular 4, 12, 24
patella 16, 24, 28
pelvis 172
phalanges 4
phalanx distal 135
pubis 72
radius 4, 115
ribs 56
sacral 165
scapula 4
sesamoid 4
sesamoid prox. 12
sesamoid distal 12
splint 4, 116
sternum 56
stylohyoid 46
talus 16
tarsal 16
tibia 16

ulna 4
Brain 52
Brainstem 163
Branch, communicating 22
Bronchus principal 60
Bulb(s), Bulbus(i)
of penis 84
of heels 26
olfactory 52
Bulla, tympanic 30
Bump 145
Bursa(ae)
calcanean 18, 28, 145
cucullar 166
cunean 28, 145
infrapatellar 28, 143
infraspinatus 14
intertubercular 14, 125, 128
navicular 14, 24, 28, 128
nuchal 56, 166
olecranon 14, 128
omental 68
ovarian 82
precarpal 14, 128
subcutaneous olecranon 128
subtendinous of comm. dig.
extensor 14
subtendinous of lat. dig. extensor 14
supraspinous 56, 166
testicular 84
trochanteric 28, 141, 144

C

Calcaneus 16, 143
Canal(s), Canalis(es)
carpal 122
central of brain 54
cervical 82
femoral 72
inguinal 74
pyloric 68
Canaliculi, lacrimal 40
Canine 34
Cardia 68
Carpus 126
Cartilage(s)
arytenoid 48
cardiac 62
cricoid 48
epiglottic 48
laryngeal 48
lingual 44
manubrial 56
of hoof 4, 24, 137
scapular 4
thyroid 48
tubal 46
Caruncle(s)
lacrimal 40
sublingual 44
Castration 172
Cauda equina 54
Cavity(ies)
abdominal 66
infraglottic 48
nasal 44
oral 44, 159
thoracic 60
vaginal 74
Cecum 66, 70, 171, 179
Cerebellum 52
Cerebrospinal fluid 164
Cervix 82
Chambers of eye 42
Chin 44
Chorda tympani 38
Choroid 42

Cisterna chyli 60, 78
Cleft, glottic 48
Clitoris 82, 176
Clubfoot 135
Cochlea of tibia 16
Colic 169
Colliculus(i)
seminalis 84
Collum coli 70
Collum glandis 84
Colon 70, 178
ascending 66, 70, 179
descending 66, 70, 179
small 70
transverse 70
Column, vertebral 56
Comissure of vulva 82
Conchae, ethmoidal 44
nasal 44
Conjunctiva 40, 153
Conus medullaris 54
Cord, spermatic 74
spinal 54
Cornea 154
Corona glandis 84
Corpus cavernosum 84
Corpus hemorrhagicum 180
Corpus luteum 174
Corpus spongiosum 84
Cremaster 74, 78
Crest(s)
facial 32
nuchal 32
renal 78
Crib-biting 148
Cryptorchid 176
Crown, clinical 32
Crown of tooth 32
Crus (leg) 18
Crus(ra) of penis 84
Cuneus 26
Cup 146
Cushion, coronary 26
Cushion, digital 26

D

Dentin, secondary 34
Dentition 32
Dermis
coronary 26
laminar 26
of frog 26
of sole 26
perioplic 26
Diameters of pelvis 72
Diaphragm 60, 97
pelvic 88, 99
urogenital 88
Diastema 44
Diastole 168
Diencephalon 52
Disc(s)
Articular 38
intervertebral 156
optic 42
Diverticulum, nasal 44, 159
Duct(s), Ductus(us)
Arteriosus of BOTALLI 160
deferent 74, 84, 179
ejaculatory 84
hepatic common 68
lactiferous 76
mandibular 38
nasolacrimal 40, 152
pancreatic 68
papillary 76
parotid 38
thoracic 60

tracheal 58
Duodenum 70, 170

E

Ear 50
Ectropion 153
Eminence, iliopubic 76
Eminence, intercondylar 16
Endoscopy 113
Entropion 153
Epididymis 84
Epidural anaesthesia 164
Epiglottic entrapment 162
Esophagus 58, 62
Examination for pregnancy 182
Eye examination 150
Eyelid, third 153

F

Fascia(ae)
deep of carpus 10
iliac 74
lata 74
of forelimb 122
of trunk 64
spermatic 74
transverse 64, 74
Femur 16
Fibers, zonular 42
Fibrocartilage
complementary of middle phalanx 4, 12
patellar 16
Fibula 16
Filum terminale 54
Fimbriae 82
Flehmen 159
Flexure
diaphragmatic 70
pelvic 66, 70
Foramen(ina)
caval 60
epiploic 68, 169
infraorbital 32
ischial 72
jugular 32
lacerum 32
magnum 32
obturator 72
supraorbital 32
vertebral lateral 56
Fold(s)
alar 44
basal 44
caval 60
cecocolic 66, 70, 179
duodenocolic 70
ileocecocolic 70, 179
of flank 64
prepuccial 84
straight 44
vestibular 48
Follicle of ovary 181
Formula, dental 32
Formula, vertebral 56
Fornix, vaginal 82
Fossa(ae)
clitoral 82
for symphyseal tendon 72
glandis 84
intercondylar 16
olecranon 4
ovulation 82
paralumbal 64
radial 4
supracondylar 16
trochanteric 16

temporal 145
Frenulum, lingual 44
Frog 26
Funiculus nuchae 56

G

Galvayne's groove 146
Ganglion, cervical, cranial 46, 50
Ganglion, mesenteric, caudal 80
Gland(s), Glandula(ae)
adrenal 78
buccal 38
bulbourethral 84
mammary 76
mandibular 38
of third eyelid 40
parathyroid 50
parotid 38
prostate 84
reproductive, accessory 84, 176
salivary 38, 150
sublingual 38
thyroid 50
vesicular 84
Glans 84
Globe 42
Glottis 48
Granules, iridic 42, 156
Groove(s)
Galvayne's 146
intertubercular 4
jugular 58
lateral pectoral 58
for accessory lig. 72, 172
for obturator structures 72, 172
intermammary 76
median pectoral 58
paracuneal 26
Gubernaculum testis 176
Guttural pouch 46, 160

H

Haustra of large intestine 70
Heart 62, 167
Heart valves 168
Heat, foal 174
Heels of hoof 26
Hematocele 172
Hemispheres, cerebral 52
Hernia(s) 169
femoral 72, 172
foraminomentalis 169
inguinal 173
mesenteric 169
spatii lieni renalis 169
umbilical 168
ventral 168
Hiatus
aortis 60
esophageal 60
High four point block 133
High two point block 121
High palmar block 121
Hoof 24, 26
Hoof capsule 26
Hoof cartilages 118
Hoof, laminitis 139
Hoof wall 26
Hook, 7-year 146
Horn
cap 26
connecting 26
intertubular 26
of hoof, quality 136
terminal 26
tubular 26
tubules 26

Horner's syndrome 153
Humerus 4
Humor, aqueous 42
Hydrocele 172
Hymen 82, 176
Hypophysis 52
Hypothalamus 52

I

Ileum 70
Ilium 72
Incisor 34, 146
Infundibulum(a)
of tooth 32, 34
of uterine tube 82
of diencephalon 52
Inlet, pelvic 72
Insemination 181
Intervertebral disc problems 165
Intersections, tendinous 64
Intestine(s) 70
Iris 42
Ischium 72

J

Jejunum 66, 70, 171
Joint(s)
antebrachiocondylar 126
condylar 12, 14, 126
coffin 12, 14, 128
digital 14
elbow 12, 14, 126
femoropatellar 28, 141
femorotibial 141
fetlock 12, 14, 24, 127
hip 28, 140
hock 26, 142
iliosacral 166
interphalangeal 14
intertarsal 28, 142
metacarpophalangeal 14
pastern 12, 14, 127
phalangeal 24
shoulder 12, 14, 125
stifle 26, 142, 143
tarsal 142, 143
tarsometatarsal 28, 142, 144
talocrural 144
temporomandibular 38, 149
tibiofibular 28
Junction, corneoscleral 42

K

Kidney 66, 78, 173
Kissing spines 165
Kyphosis 165

L

Labium(a) 82
Lacerations, perineal 88
Lacertus fibrosus 12
Lacuna, muscular 72
Lacuna, vascular 72
Lake, lacrimal 40
Lamellae dermales 26
Lamina(ae)
dermal 26
epidermal 26
femoral 72
femorals fascialis 74
Lamina(ae) (Continued)
horny 26
nuchae 56
Laminitis 139
Laparotomy, transcostal 58, 168

Laryngopharynx 46
Larynx 48
Leg 18
Lens 42, 157
Ligament(s), Ligamentum(a)
accessory of femur 28, 64, 72, 76, 172
accessory of digital flexors 12, 123
annular digital 10
annular of fetlock 10, 122
broad 82
coronary 68
cricothyroid 48
cruciate 28, 142
falciiform 68
femoropatellar 28
femorotibial 28
gastrosplenic 68
inguinal 64, 74, 76
navicular 24
nuchal 56
of bladder 78
of femoral head 28, 76, 172
of tail of epididymis 84
patellar 18, 24, 28
phrenicosplenic 169
proper of ovary 82
proper of testis 84
renosplenic 68, 78
round of bladder 78
round of liver 68, 168
round of uterus 74, 76, 82
sacrosciatic 72, 86, 165
scrotal 84
sesamoidean 24, 123
supraspinous 56
suspensory of ovary 82
suspensory of penis 74
tarsocrural 28
transverse acetabular 28
triangular of liver 68
vestibular 48
vocal 48
Line(s), Linea(ae)
alba 64, 74, 76, 168
of pleural reflection 60
terminal 72
white of hoof 26, 137
Lips 44
Liver 66
Lobe(s) renal 78
Locking of stifle 24
Lordosis 165
Lung 60, 167
Lung field 60, 167
Lymph node(s)
axillary 8
cecal 70, 102
celiac 70
cervical deep 58
cervical supf. 8, 58, 102
colic 70, 102
cubital 8
gastric 70
general 101—103 enter after sort.
hepatic 70
iliac 20, 78
inguinal deep 20, 72
inguinal supf. 20, 78
intercostal 62
jejunal 70, 102
lumbar aortic 78
mammary 78
mandibular 38
mediastinal 60
mesenteric caudal 70, 103
pancreaticoduodenal 70, 102

parotid 38
 Lymph node(s) (Continued)
 popliteal 20
 pulmonary 60
 renal 78
 retropharyngeal 38, 46, 161
 sacral 78
 scrotal 78
 splenic 70
 sternal 60
 subiliac 20
 thoracic aortic 60
 tracheobronchial 60

M

Malleolus(i) 16
 Manubrium sterni 56
 Margo plicatus 68
 Meatus, nasal 44
 Mechanism, reciprocal 24
 Mediastinum 60, 102, 167
 Mediastinum testis 84
 Meniscus(i) of stifle 28
 Mesencephalon 52
 Mesentery 102
 Mesocolon 70, 179
 Mesometrium 82
 Mesorchium 84
 Mesosalpinx 82
 Mesovarium 82
 Midbrain 52
 Molars 34, 145
 Mouth 44
 Muscle(s), Musculus(i)
 abdominal 99
 abdominal oblique 64, 74, 99
 abductor pollicis longus 89
 adductor 18, 90
 adductor longus 76
 anconeus 88
 articularis humeri 88
 arytenoideus transversus 94
 biceps brachii 6, 88
 biceps femoris 18, 90
 brachialis 6, 88
 brachiocephalicus 58
 buccinator 92, 139
 bulboglandularis 84
 bulbospongiosus 84, 86, 100
 caninus 36, 92
 ceratohyoideus 95
 cervicoauricularis medius 92
 cervicoauricularis profundus 92
 cervicoauricularis sup. 36, 92
 cervicoscultularis 92
 ciliary 42
 cleidobrachialis 88
 cleidomastoideus 58, 98
 coccygeus 86, 99
 constrictor vestibuli 86, 100
 constrictor vulvae 86, 100
 coracobrachialis 88
 cremaster 74, 76
 cricoarytenoideus 94, 161
 cricopharyngeus 48, 94
 cricothyroideus 94
 cutaneous 58, 95
 cutaneous of face 92, 95
 cutaneous of trunk 64
 cutaneus colli 58, 95
 cutaneus omobrachialis 64, 96
 cutaneus trunci 58, 64, 95
 deltoideus 88
 depressor labii inferioris 36, 92
 diaphragm 60, 98
 digastricus 40, 93
 extensor carpi obliquus 6, 89
 extensor carpi radialis 6, 89

extensor carpi ulnaris 6, 89
 extensor dig. common 6, 89
 extensor dig. lateral 6, 18, 89, 91, 133
 extensor dig. long 18, 91
 extensor dig. brevis 91
 Muscle(s), Musculus(i) (Continued)
 flexor carpi radialis 6, 89
 flexor carpi ulnaris 6, 89
 flexor dig. deep of forelimb 6, 12, 89
 flexor dig. deep of hindlimb 18, 91
 flexor dig. lateral 18, 89
 flexor dig. medial 18, 89
 flexor dig. supf. of forelimb 12, 89
 flexor dig. supf. of hindlimb 18, 24, 91
 frontoscutularis 92
 gastrocnemius 18, 91
 gemelli 18, 90
 genioglossus 50, 95
 geniohyoideus 50, 95
 gluteal accessory 18, 90, 132
 gluteal deep 18, 90
 gluteal middle 18, 90
 gluteal supf. 18, 90
 gluteus 19
 gracilis 76, 90
 hamstring 18
 hyoepiglotticus 95
 hyoglossus 50, 95
 hyoideus transversus 95
 hyopharyngeus 46, 94
 iliacus 99
 iliocostalis 96
 iliopsoas 72
 infraspinatus 88
 intercostal 98
 interosseus 24, 89, 122, 135
 interscutularis 92
 intertransversarii 96
 ischiocavernosus 85, 100
 ischiourethralis 85
 laryngeal 48
 latissimus dorsi 58, 97
 levator anguli oculi 36, 93
 levator ani 93, 106
 levator labii superioris 86, 99
 levator nasolabialis 36, 92
 levator veli palatini 36, 93
 levatores costarum 46, 94
 lingualis proprius 95
 longissimus 96
 longus capitis 97
 longus colli 97
 malaris 36, 93
 masseter 38, 93
 mimetic 36
 multifidus 96
 mylohyoideus 38, 93, 95
 oblique ventral of eye 40
 obliquus capitis 97
 obturator 18, 76, 90
 occipitohyoideus 95
 occipitomandibularis 38
 ocular 40
 of arm 88
 of croup 90
 of eye 40
 of eyelids 36
 of face 92
 of facial expression 36
 of forearm 87
 of hip joint 87
 of larynx 94
 of leg 91
 of mastication 38, 93, 150

of perineum 99
 of pharynx 94
 of respiration 98
 of shoulder 88
 of shoulder girdle 58, 97
 of thigh 90
 of vertebral column 96
 of tongue 50
 omohyoideus 58, 95,
 omotransversarius 58, 97
 orbicularis oculi 36, 93
 Muscle(s), Musculus(i) (Continued)
 obicularis oris 32, 85
 palatopharyngeus 42, 87
 parotidoauricularis 32, 85
 pectineus 16, 66, 70, 83
 pectoral 52, 91
 pectoralis descendens 52, 91
 pectoralis profundus 52
 pectoralis transversus 52, 91
 peroneus tertius 16, 22, 84, 22.1
 pharyngeal 42
 Phillip's 82
 platysma 89
 popliteus 16, 84
 psoas major and minor 92
 pterygoideus 34, 86
 pterygopharyngeus 42, 87
 quadratus femoris 16, 83
 quadratus lumborum 92
 quadriceps femoris 16, 84
 rectococcygeus 80, 93
 rectus abdominis 58, 68, 92
 rectus capitis 90
 rectus femoris 84
 rectus of eye 36
 rectus thoracis 91
 retractor bulbi 36
 retractor clitoridis 80, 93
 retractor costae 91
 retractor penis 78, 80, 93
 rhomboideus 52, 90
 sacrocaudales 80, 89, 90
 sartorius 16, 66, 84
 scalenus 90
 scutuloauricularis supf. 85
 semimembranosus 16, 83
 semispinalis capitis 89
 semitendinosus 16, 83
 serratus dorsalis 91
 serratus ventralis 52, 91
 soleus 16, 84
 sphincter anal 80, 93
 sphincter colli 85
 spinalis 89
 splenius 89
 sternoccephalicus 52, 91, 52.2
 sternohyoideus 52, 88
 sternomandibularis 42, 52, 91
 sternothyroideus 2, 88
 styloauricularis 85
 styloglossus 44, 88
 stylohyoideus 34, 88
 stylopharyngeus 42, 87
 subclavius 52, 91
 sublumbar 92
 subscapularis 81
 supraspinatus 81
 temporalis 34, 86
 tensor fasciae antebrachii 81
 tensor fasciae latae 16, 82
 tensor veli palatini 42, 87
 tenesor ventriculi laryngis 87
 teres major 81
 teres minor 81
 Thierness' 82
 thyroarytenoideus 87
 thyroarytenoideus accessorius 87
 thyrohyoideus 44, 88

thyropharyngeus 42, 87
 tibialis caudalis 16, 84
 tibialis cranialis 16, 84
 tarsus versus abdominis 58, 68, 92
 transversus thoracis 91
 trapezius 90
 triceps brachii 10, 81
 triceps surae 84
 ulnaris lateralis 4, 82
 vastus intermedius 84
 vastus lateralis 84
 vastus medialis 84
 ventricularis 42, 87
 vocalis 42, 87
 Muscle(s), Musculus(i) (Continued)
 zygomaticoauricularis 85
 zygomaticus 85
 Mydriasis 158

N

Nasal Septum 159
 Nasopharynx 46
 Neck 52
 Nerve(s), Nervus(i)
 abducent 40, 52, 163
 accessory 46, 52, 110, 163
 alveolar 38, 149
 auricular 36
 auriculopalpebral 36, 110, 153
 auriculotemporal 38, 108
 axillary 6, 105
 blocks diagnostic 119
 buccal 38, 108
 chorda tympani 38, 110
 ciliary long 40, 42, 108
 cranial 163
 cutaneous antebrachial 6, 8
 cutaneous femoral 20, 64, 76, 80, 106
 cutaneous sural 18, 20, 22, 107
 cutaneous of forelimb 8, 105
 cutaneous of hindlimb 20, 107
 digital 10, 20, 105
 ethmoidal 108
 facial 36, 110, 163
 femoral 18, 72, 106
 general 104—107
 genitofemoral 20, 72, 74, 76, 108
 glossopharyngeal 46, 50, 110, 163
 gluteal 18, 80, 106
 hypogastric 80
 hypoglossal 46, 48, 52, 110, 163
 iliohypogastric 106
 ilioinguinal 106
 infraorbital 38, 108, 156
 infratrochlear 40
 intercostobrachial 8
 ischadic 107
 lacrimal 40
 larngal 48, 110
 laryngeal (recurrent) 48, 58, 62, 166
 lingual 38, 108
 lumbar 74, 76, 104
 mandibular 38, 108, 149
 masseteric 38, 108
 maxillary 38, 40, 108, 150
 median 6, 105
 mental 34, 108, 150
 metatarsal 22
 metatarsal, dorsal 20, 107
 musculocutaneous 6, 105, 121
 mylohyoid 38
 nasociliary 40, 108
 obturator 18, 106, 132

oculomotor 40, 50, 108, 163
 olfactory 52, 108, 163
 ophthalmie 40, 108
 optic 42, 52, 108, 163
 palmar 6, 10, 105, 119
 pelvic 80
 perineal 80, 86, 107
 peroneal 18, 22, 107
 phrenic 56
 plantar 18, 20, 22, 107
 pudendal 80, 86, 107
 radial 6, 105
 rectal 80, 86, 107
 recurrent laryngeal 48, 58, 62, 166
 saphenous 18, 22, 72, 106
 sciatic 18, 80, 107, 132
 spinal 54, 64, 104
 splanchnic 62, 70
 subscapular 6, 105, 118
 supply of intestines 70
 supraorbital 40, 108
 suprascapular 6, 105, 118
 sympathetic trunk 50, 62
 temporal deep 38, 108
 thoracodorsal 6
 tibial 18, 107, 133
 trigeminal 38, 52, 108, 163
 Nerve(s), Nervus(i) (Continued)
 trochlear 52, 108, 163
 ulnar 6, 118
 vagal trunks 70
 vagosympathetic trunk 58
 vagus 46, 50, 62, 156, 163
 vestibulocochlear 52, 110, 156
 zygomatic 40, 108
 zygomaticofacial 40, 108
 zygomaticotemporal 40
 Nose 44
 Notch
 acetabular 72
 cardiac 60
 carotid 30
 nasoincisive 30
 thyroid 48

O
 Obstetrical measures 175
 Ophthalmoscopy 157
 Orifice(s), See also Opening, Ostium.
 cecocolic 70
 nasolacrimal 38
 of nasolacrimal duct 44
 preputial 84
 teat 76
 urethral 82, 84
 uterine 82
 Obturator groove 72
 Omentum(a) 68
 Opening; See also Ostium.
 frontomaxillary 34
 pharyngeal of auditory tube 46
 Ora serrata 42
 Organ, vomeronasal 44
 Oropharynx 46
 Os(ossa) coxarum 72, 172
 Ossification, incomplete 115
 Ostium, See also Opening.
 intrapharyngeal 46
 pharyngeal of auditory tube 160
 uterine 82
 Outlet, pelvic 72
 Ovary 76, 174, 180

P
 Palate, hard 44, 160
 Palate, soft 46, 160
 Pancreas 68
 Papilla(ae)
 duodenal 68, 70
 ileal 70
 dermal accessory 26
 dermal of hoof 26
 of tongue 44
 terminal 26
 uterotubal 181
 Paralysis of penis 177
 Parametrium 82
 Patella 16, 24, 28, 134
 Peduncles olfactory 52
 Pelvic bone, fractures 172
 Pelvis, bony 72, 172
 Pelvis, renal 78, 174
 Penis 84, 177
 Perineum 86
 Periople 26
 Periorbita 40
 Phalanx(anges) 4, 26
 Phimosis 177
 Pharynx 46
 Pleura 60
 Plexus(us)
 brachial 6, 118
 choroid 52
 lumbar of nerves 76
 pelvic of nerves 80
 sacral of nerves 80
 testicular of nerves 74
 venous of hoof 22
 Podotrochlea 124
 Pouch guttural 46
 Pouch rectogenital 82
 Pouch vesicogenital 82
 Premolars 32, 145
 Prepuce 84, 177
 Prepuce of clitoral glans 82
 Process(es)
 corniculate 48
 cuneiform 48
 spinous 56
 styloid 4
 urethral 84, 177
 vaginal 64, 74
 vocal 48
 Promontory of sacrum 56
 Prostate 84
 Protrusion of third eyelid 153
 Protuberance occipital external 30
 Pubis 72
 Puncta maxima 168
 Pupil 40
 Pylorus 68

R
 Radial paralysis 118
 Radius 4
 Radii lentis 42
 Recess(es)
 costodiaphragmatic 60
 renal 78
 suprapatellar 142
 Rectal palpation 178
 Rectum 70
 Reflex
 corneal 42
 palpebral 153
 pupillary 156
 Region, perineal 72, 86
 Rete testis 84
 Retina 42, 157
 Retinaculum(a)
 extensor 10

 flexor 10
 Rhombencephalon 52
 Ribs 56
 Ring
 femoral 72, 172
 inguinal 64, 74
 inguinal supf. 72
 preputial 84
 vaginal 74

S
 Sac(s), Saccus(i)
 blind, of stomach 68
 cecus 68
 conjunctival 40
 lacrimal 40
 pleural 60
 Sacculations of large intestine 70
 Scapula 4
 Scrotum 74
 Scoliosis 165
 Septum(a)
 nasal 44, 159
 penis 84
 scrotal 74
 Sex determination, ultrasound 183
 Sheath(es)
 Carotid 166
 carpal 14, 129
 digital 10, 14
 synovial at hock 145
 synovial 14, 145
 Sinus(s)
 conchal 34
 conchofrontal 34
 frontal 34
 lactiferous 76
 maxillary 34, 148
 paranasal 34, 148, 149
 renal 78
 sagittal of brain 52
 sphenopalatine 34
 venous of brain 52
 Slub fractures 115
 Sonography 143, 176, 179
 Spavin 142
 Space
 epidural 164
 lumbosacral 56, 166
 sacrococcygeal 166
 subarachnoid 164
 visceral of neck 58
 Spine, ischial 72
 Spines, kissing 164
 Spleen 66, 68
 Star, dental 34
 Stay-apparatus of hindlimb 24
 Stay-apparatus of forelimb 12
 Stenosis, static, dynamic 164
 Sternum 56
 Stifle lock 24
 Stomach 66, 68, 169
 Stratum externum of hoof 26
 Stratum internum of hoof 26
 Stratum medium of hoof 26
 Sustentaculum tali 16
 Symphysis, pelvic 72
 System, central nervous 52
 System, ventricular of brain 52
 Systole 167

T
 Tail 86
 Talus 16
 Tapetum lucidum 42
 Tarsus 144
 Teat 76

Tectum 52
 Teeth 30, 32
 Teeth, aging by 145
 Telencephalon 52
 Tendon
 abdominal of ext.oblique 74
 calcanean common 18
 cunean 18
 pelvic of ext.oblique 74
 prepubic 74, 76, 172, 173
 sheaths 14
 supf. digital flexor 4, 123
 symphyseal 72
 Tenia(ae) 66, 70
 Teniae cecae 179
 Testis(es) 84, 176
 Thorax 56
 Thymus 62
 Tibia 16, 131
 Tongue 44
 Tonsil(s)
 lingual 46
 palatine 46
 pharyngeal 46
 of soft palate 46
 tubal 46
 Tooth, Teeth 34
 canine 34
 molars 34
 premolars 34
 surfaces 32
 Wolf 32, 34
 Trachea 50, 58
 Tractus, olfactory 52
 Triangle
 femoral 18, 72
 olfactory 52
 Viborg's 46, 161
 Trochanter, greater 16, 130
 Trochlea of femur 16, 24
 Trunk
 linguofacial 50
 pudendoepigastric 20
 sympathetic 46, 50, 62
 vagal 70, 166
 vagosympathetic 58, 166
 tracheal lymph 58
 Tube auditory 50, 160
 Tube uterine 82, 175
 Tuber
 calcanean 16
 coxal 72
 ischial 72
 olecranon 4
 Tubercle
 for psoas minor 72
 intermediate 4
 pubic 72
 supraglenoid 114
 Tuberosity
 deltoid 4
 teres major 4
 tibial 16, 131
 Tunic(s), Tunica(ae)
 albuginea 84
 abdominal 64, 74
 dartos 74
 fibrous of globe 42
 vaginal 74
 vascular of eye 158
 Twin pregnancy 182

U
 Udder 76, 173
 Ulna 4
 Umbilicus 168
 Ungula 26, 135ff
 Ureter 78, 174

Urethra, female 78, 174
Urethra, male 84
Uterus 82, 175
Uterus, rupture 176
Uveitis 157

V

Vagina 82, 176
Vagus 48, 50, 62
Valve, aortic 160
Valve, mitral 167
Valve, tricuspid 167
Vein(s), Vena(ae)
azygos, left 167
auricular, caudal 36
buccal 36
caudal vena cava 60
cava 60
cephalic 8, 58, 118
cephalic, accessory 8

cervical, supf. 58
cubital median 8
digital 10, 22
digital, dorsal common II 20
digital, common II 20
facial 36
facial deep 36
facial transverse 36
iliac external 20
jugular 36, 58
linguofacial 36
mammary 80
masseteric 36
maxillary 36
median 8
obturator 20, 80
occipital 36
of stifle descending 20
palmar 8, 10
plantar 20, 22
portal 68

pudendal 80
pudendal, external accessory 72, 80
pulmonary 60
saphenous 20, 134
spur 8, 64
temporal, supf. 36
testicular 176
thoracic, supf. 8, 64
tibial, caudal 20
Ventricles, laryngeal 48, 162
Ventriculus terminalis 54
Vertebra(ae) 56, 164
anticlinal 56
caudal 56
cervical 56, 164
lumbar 56
sacral 56
thoracic 56, 165
Vesicle, seminal 84
Vestibule

laryngeal 48
nasal 44
oral 44
vaginal 82, 176
Vulva 82, 176

W

Wall
abdominal 64, 168
of hoof 26
thoracic 58, 62
Windswept foal 130
Wolf tooth 32, 34

Z

Zona alba 26
Zones of autonomous innervation
forelimb 6.1

Klaus-Dieter Budras · Patrick H. McCarthy · Wolfgang Fricke · Renate Richter

Anatomy of the Dog

An Illustrated Text

Fifth, revised edition


With Aaron Horowitz and Rolf Berg

2007. 224 pp., 71 largesized color plates including several illustrations, radiographs, drawings and photographs, 9 3/4 x 13 1/2", hardcover

ISBN 978-3-89993-018-4

€ 86,- / \$ 137,99 (US) / £ 69,-

Already acknowledged by students and teachers as an essential resource for learning and revision, this book will also be a valuable reference for qualified practitioners.



- Fully illustrated with color line diagrams, including unique three-dimensional cross-sectional anatomy, together with radiographs and ultrasound scans
- Includes topographic and surface anatomy
- Tabular appendices of relational and functional anatomy
- New section on computed tomography

Authors

Klaus-Dieter Budras, DVM, PhD, professor em., University of Berlin, Germany

Patrick H. McCarthy, DVM, PhD, professor em., University of Sydney, Australia

Rolf Berg, DVM, PhD, professor, Ross University, St. Kitts, West Indies

Aaron Horowitz, DVM, PhD, JD, professor, Ross University, St. Kitts, West Indies

Wolfgang Fricke, medical illustrator, University of Berlin, Germany

Renate Richter, medical illustrator, University of Berlin, Germany

"If the practicing veterinarians have not bought an anatomy book since veterinary school, this book is highly recommended; this is a book that one would be proud to use as a teaching tool with clients."

JAVMA

"A region with which I was very familiar from a surgical standpoint thus became more comprehensible.

[...] Showing the clinical relevance of anatomy in such a way is a powerful tool for stimulating students' interest. [...] In addition to putting anatomical structures into clinical perspective, the text provides a brief but effective guide to dissection."

The Veterinary Record

Anatomy of the Horse has been accepted as a highly successful text-atlas of equine anatomy. The chapters on functional anatomy of this present 5th edition have been totally revised and include new chapters on the eye, abdomen, female reproduction, ultrasonography, and especially orthopedics.

- Fully illustrated with color line diagrams, including unique three-dimensional cross-sectional anatomy, together with radiographs and ultrasound scans
- Includes topographic and surface anatomy
- Tabular appendices of relational and functional anatomy

"The aim of the authors has been admirably achieved. The textbook is already acknowledged as an essential resource for students and teachers and will be an essential reference book for veterinary practitioners and horse lovers in the English-speaking world."

American Veterinary Medical Association – JAVMA

"This book would be a valuable reference book for students of anatomy and surgery. The practising surgeon should find many of the descriptions and diagrams extremely useful."

Irish Veterinary Journal

ISBN 978-3-89993-044-3



9 783899 930443

vet

vet
S